

Case Report: Subcortical Prosopagnosia and Anosognosia

BY DANIEL E. JACOME, MD

ABSTRACT: A 59-year-old right-handed woman with acute hemorrhage affecting the head of the left caudate nucleus exhibited prosopagnosia and anosognosia. It is suggested that these symptoms are due to a disconnection syndrome affecting a putative cortico-limbic reticular loop involved in attention. Prosopagnosia can occur with lesions outside the main central visual pathways and is a material-specific motivational neglect to faces; alternatively prosopagnosia in this patient may represent abnormal gating sensory limbic activity since sensory (visual) modulated memory related cholinergic fibers arising from the nucleus basalis of the substantia innominata (Meynert's) were likely involved by surrounding edema. **KEY INDEXING TERMS:** Attention Disorder; Prosopagnosia (Visual Agnosia, Agnosia to Faces); Anosognosia (Neglect); Caudate Nucleus; Intracerebral Hemorrhage; Nucleus Basalis of Meynert; Substantia Innominata. [*Am J Med Sci* 1986; 292(6):386-388.]

Prosopagnosia is a clinical symptom characterized by isolated facial agnosia.¹ The primary disorder is incapacity of patients to recognize people known to them on the basis of visual perception of faces. The individual with this condition typically recognizes familial people by visual clues such as gait, clothing, or hair color, sometimes only recognizing relatives after listening to their voices. Visual recognition of familial and unfamiliar faces can be clinically dissociated.² Often other neurobehavioral deficits are detectable in patients with prosopagnosia including topographic disorientation, disturbances of body schema, dressing, and constructional apraxia.³ The severity of the agnostic process also varies in patients to the extent that some cannot

distinguish the sex of the person speaking or are unable to recognize animal or human faces.⁴ Visual disturbances of the nature of visual field defects, achromatopia,⁵ and metamorphopsia are common. The metamorphopsic form of prosopagnosia (ie, faces appear "distorted" or disorganized making identification impossible) has been associated to ictal prosopagnosia occurring in patients with paroxysmal disorders such as migraine or epilepsy.³ Prosopagnosia is not the result of primary visual disturbances as it does not happen in every patient with visual field deficits. Conversely, it can occur in patients with normal visual fields.⁶ Prosopagnosia is the incapacity to perceive individuality within a single class of objects (ie, faces, fruits) according to one postulate. An alternative explanation suggests agnosia to familial faces represents a material-specific defect in memory integrating current facial percepts with past experiences of them.² It implicates a defect in the contextual evocation of memories for faces or in the retrieval of "emotional memories" required for the act of identifying faces previously known.

Anosognosia is the denial of any defect or illness often occurring in the content of a generalized disturbance of behavior. The aspects of illness that can be denied include hemiplegia, involuntary movement, blindness, memory loss, urinary or fecal incontinence, sexual impotence, and vomiting, or it can simply present itself as a total denial of illness.⁷ Anosognosia can occur in association to prosopagnosia.^{3,8}

Case Report

A 59-year-old right-handed woman was admitted to the hospital because of sudden onset of left-sided headaches. Her past medical history was unremarkable. Her physical examination was normal except for basilar rales in the right lung, and she was normotensive and afebrile. She had a mild hypochromic anemia secondary to alpha thalassemia. The day after admission, relatives reported the patient was weak on her right side. They became very concerned once they noticed she could not recognize them by their faces. On neurologic examination, she was alert and oriented and denied any symptoms. Her speech was fluent but slow and lacked the normal intonation and melody. She could read silently and aloud and write spontaneously and to dictation. She did elementary calculations with no difficulties and had no topographic disorientation and no right-to-left confusion. She could name parts of faces but had difficulties on recognizing close relatives unless spoken to. Sensory examination was normal, and she had no sensory extinction. She could recognize different objects in

From the Department of Medicine, Palmetto General Hospital and Hialeah Hospital, Hialeah, Florida; and the Department of Neurology, University of Miami School of Medicine, Miami, Florida.

Reprint requests: Daniel E. Jacome, MD, 7100 West 20th Avenue, Suite 401, Hialeah, FL 33016.

the room. She had minimal difficulties with long-term memory but greater difficulties with immediate recall of objects or words. Her attention span was normal. She had no apraxia but exhibited hypokinesia of right-sided limbs on associated movements greatly disproportionate to the amount of weakness. Confrontational visual fields were normal, and she had no subjective visual complaints. She had mild right hemiparesis, but she denied weakness of her limbs. Reflexes were equal, but there were bilateral Babinski signs. Computed tomography (CT) of the head disclosed a left head caudate nucleus hemorrhage with surrounding edema impinging on the anterior limb of the internal capsule (Figure 1). One electroencephalogram (EEG) showed irregular theta slowing on the left hemisphere with no paroxysmal activity.

The patient was able to recognize family members a few days after onset of her symptoms but remained with right-sided weakness and hypokinesia for 2 weeks. She declined further testing including outside referral for psychometrics. Three years after her acute illness, she recalls only having a headache at the time of her hospitalization. She had not had any additional medical problems.

Discussion

The hypothesis that prosopagnosia resulted from a single right (nondominant) hemispherical posterior lesion³ was based on incomplete data. A recent review of the available postmortem and CT data on patients with this clinical symptom concluded prosopagnosia is associated with bilateral, functionally symmetric, mesial occipito-temporal lesions affecting the central visual pathways.⁹ Initial accounts of anosognosia were reported resulting from lesions of various kinds located at different parts of the cerebral hemispheres, diencephalon, or posterior fossa.⁷ Anosognosia, however, was classically considered a clinical expression of a nondominant parietal lobe lesion.¹⁰ Currently, this symptom is classified as an-

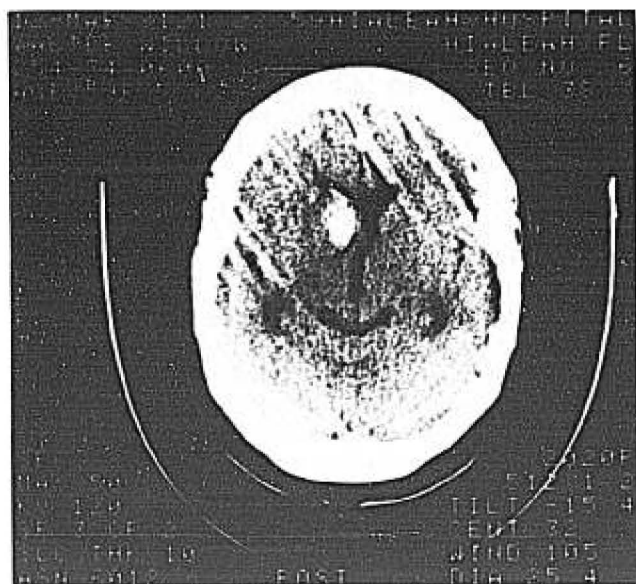


Figure 1. CT scan of the head. The visible hyperdense lesion of the head of the left caudate nucleus corresponds to a hematoma with secondary edema.

other manifestation of neglect secondary to lesions interrupting a putative cortico-limbic reticular loop that includes the prefrontal, inferior parietal, and superior temporal gyri, cingulate gyrus, thalamus, and mesencephalic reticular formation.^{11,12} Anosognosia has been recently reported in association to caudate nucleus hemorrhage.^{13,14} The patient herein discussed had also unilateral limb hypokinesia and motor aprosodia, both findings described in patients with lesions involving the caudate nucleus.^{15,16}

The caudate nucleus is a high level integrative anatomic structure receiving connections from major sensory areas including important visual and auditory, and from the limbic cortex (cingulate gyrus).^{17,18} The data implicate the caudate nucleus as also forming part of the cortico-limbic reticular loop involved in attention. The limbic cingulate station of the loop is involved in the motivational relevance aspect of selective attention.^{11,12} I suggest prosopagnosia can occur in patients with lesions in the cortico-limbic reticular loop outside the central main visual pathways due to disconnection of cingulate caudate fibers. Cortico-fugal and cortico-petal memory related cholinergic fibers of the nucleus basalis of the substantia innominata, regulate the access of information to the limbic system.¹⁹ The activity of these fibers is modified by the behavioral relevance of sensory events.^{20,21} Alternatively, since these fibers (dominant?) were likely involved by surrounding edema, it is possible to speculate prosopagnosia is the result of abnormal gating sensory (visual) limbic interactions.¹⁹

References

1. Bodamer J: Die Prosop-Agnosie. *Arch Psychiatr Nervenkr* 179:6-54, 1947.
2. Benton AL: The neuropsychology of facial recognition. *Am Psychol* 35:176-186, 1980.
3. Hecaen H, Angelergues R: Agnosia for faces (prosopagnosia). *Arch Neurol* 7:92-100, 1962.
4. Bornstein B, Stroka H, Munitz H: Prosopagnosia with animal face agnosia. *Cortex* 5:164-169, 1969.
5. Meadows JC: Disturbed perception of colours associated with localised cerebral lesions. *Brain* 97:615-632, 1974.
6. Levin HS, Peters BH: Neuropsychological testing following head injuries: Prosopagnosia without visual field defect. *Dis Nerv Sys* 37:68-71, 1976.
7. Weinstein EA, Kahn RL: The syndrome of anosognosia. *Arch Neurol Psychiat* 64:772-791, 1950.
8. Weinstein M: Prosopagnosia. *Clini Pearls* 4:7-8, 1981.
9. Damasio AR, Damasio H, Hoesen GW: Prosopagnosia: Anatomic basis and behavioral mechanisms. *Neurology* 32:331-341, 1982.
10. Critchley M: *The Parietal Lobes*. London, E. Arnold Co, 1953.
11. Watson RT, Heilman KM, Miller BD, King FA: Neglect after mesencephalic reticular formation lesions. *Neurology* 24:294-298, 1974.
12. Mesulam MM: A cortical network for directed attention and unilateral neglect. *Ann Neurol* 10:309-325, 1981.
13. Heaton EB, Navarro C, Bressman S, Brust JCM: Subcortical neglect. *Neurology* 32:776-778, 1982.
14. Stein RW, Kase C, Hier DB, Caplan LR, Mohr JP, Hemmati M: Caudate hemorrhage. *Neurology* 34:1549-1554, 1984.

Subcortical Prosopagnosia and Anosognosia

15. Valenstein E, Heilman KM: Unilateral hypokinesia and motor extinction. *Neurology* 31:445-448, 1981.
16. Damasio AR, Damasio H, Rizzo M, Varney N, Gersh F: Aphasia with nonhemorrhagic lesions in the basal ganglia and internal capsule. *Arch Neurol* 39:15-20, 1982.
17. Yeterian EH, Van Hoesen GW: Corticostriate projections in the rhesus monkey: The organization of certain cortico-caudate connections. *Brain Res* 139:43-63, 1978.
18. Kemp JM, Powell TPS: The cortico-striate projection in the monkey. *Brain* 93:525-546, 1970.
19. Mesulam M-M, Volicer L, Marquis JK, Mutson EJ, Green RC: Systemic regional differences in the cholinergic innervation of the primate cerebral cortex: distribution of enzyme activities and some behavioral implications. *Ann Neurol* 19:144-151, 1986.
20. DeLong MR: Activity of pallidal neurons during movement. *J Neurophysiol* 34:414-427, 1971.
21. Rolls ET, Sanghera MK, Roper-Hall A: The latency of activation of neurons in the lateral hypothalamus and substantia innominata during feeding in the monkey. *Brain Res* 164:121-135, 1979.