



Contents lists available at ScienceDirect

## Journal of Stroke and Cerebrovascular Diseases

journal homepage: [www.elsevier.com/locate/jstroke](http://www.elsevier.com/locate/jstroke)

## Case Report

Pulmonary abscess combined with pulmonary vein thrombosis and stroke:  
A case reportPingping Zheng<sup>a</sup>, Ning Zhang<sup>b</sup>, Zixi Chen<sup>a,\*</sup><sup>a</sup> Department of Emergency, The Affiliated Hangzhou First People's Hospital, College of Medicine, Westlake University, No. 261 Huansha Road, Shangcheng District, Hangzhou, Zhejiang Province 310006, PR China<sup>b</sup> Department of Cardiology, The Affiliated Hangzhou First People's Hospital, College of Medicine, Westlake University, No. 261 Huansha Road, Shangcheng District, Hangzhou, Zhejiang Province 310006, PR China

## ARTICLE INFO

## Keywords:

Stroke  
Pulmonary abscess  
Pulmonary vein thrombosis  
Air embolism  
Sepsis

## ABSTRACT

**Background:** Although most stroke patients have underlying vascular risk factors, it is important to consider infectious causes of stroke in young adults without traditional risk factors or patients with cryptogenic stroke. Pulmonary vein thrombosis and air embolism can potentially cause cerebral infarction. However, the association between infection and pulmonary vein thrombosis or air embolism is often overlooked. In this case, we present a rare infectious cause of stroke and air embolism involving a pulmonary abscess and pulmonary vein thrombosis.

**Case presentation:** A 37-year-old male patient initially presented with right-sided pneumonia. During treatment at a local hospital, he developed headaches and left limb weakness. Subsequently, he was transferred to our hospital due to septic shock. Neurological evaluations revealed multiple brain foci and thrombosis in the right superior pulmonary vein. Following treatment with broad-spectrum antibiotics and anticoagulants, the patient's clinical symptoms and inflammatory markers showed improvement. However, a computed tomography scan revealed the formation of a pulmonary abscess, and the patient experienced coma and epilepsy after severe coughing with massive hemoptysis. Multiple air embolisms were observed in the brain computed tomography. Eventually, the patient's family chose to discharge him from the hospital.

**Conclusions:** This case highlights the rare and complex etiologies of stroke associated with infection in a young patient. Early detection, diagnosis, and appropriate treatment of infected systemic embolism in young patients are crucial to prevent serious complications.

## Case presentation

A 37-year-old male patient was admitted to the Emergency Intensive Care Unit with a four-day history of cough, fever, and left limb weakness that had persisted for 18 hours. An emergency head magnetic resonance imaging (MRI) scan revealed multiple foci (Fig. 1A–D), while CT angiography (CTA) of the head and neck at admission did not indicate any obvious large vessel occlusion. However, it incidentally revealed pulmonary vein thrombosis (PVT) in the right superior pulmonary vein (Fig. 1E). Three days after admission, the patient's clinical symptoms and inflammatory markers improved significantly following treatment with broad-spectrum antibiotics and low-molecular-weight heparin. However, the patient continued to have a persistent productive cough, and a repeated chest CT confirmed the formation of an abscess in the middle and upper lobes of the right lung (Fig. 1F). A repeated head MRI

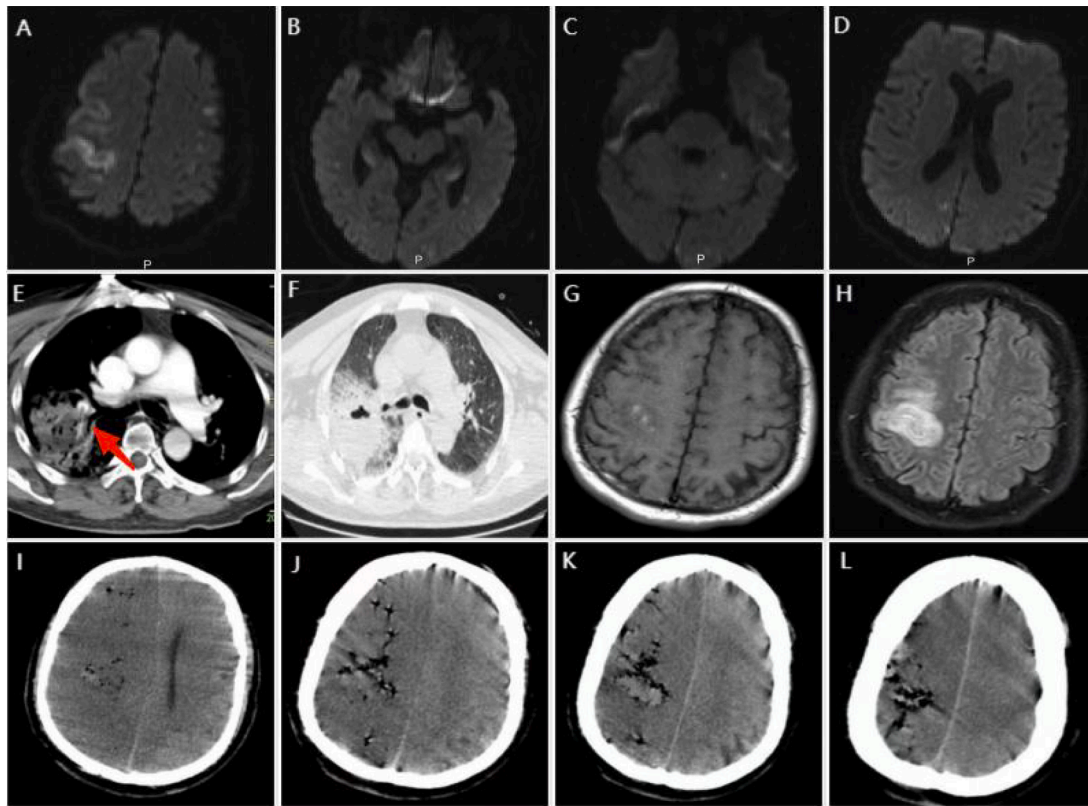
revealed hemorrhagic transformation (HT) in one of the lesions (Fig. 1G and H). Unfortunately, on the 5th day of admission, the patient experienced severe coughing, resulting in massive hemoptysis. Nine hours later, the patient suddenly lost consciousness and had a convulsive episode. A head CT scan revealed diffuse cerebral air embolism with significant brain edema (Fig. 1I–L). The patient was intubated with an 8mm endotracheal tube and administered high concentrations of oxygen. Given the substantial medical expenses and unfavorable prognosis, the patient's family chose to discharge him from the hospital shortly after.

## Discussion

This case report describes a rare occurrence of pulmonary infection associated with PVT, followed by two sequential stroke events in a

\* Corresponding author.

E-mail address: [czxixi148@163.com](mailto:czxixi148@163.com) (Z. Chen).



**Fig. 1.** A–D: Diffusion-weighted images showed multiple ischemic lesions involving bilateral frontoparietal and occipitotemporal lobes, left cerebellar hemisphere, and splenium of the corpus callosum. E: CTA of the chest showed a filling defect within the right superior pulmonary vein (arrow). F: Chest CT revealed consolidation and cavity formation in the middle and upper lobe of the right lung, suggesting pulmonary abscess. G and H: T1-weighted MRI showed a mixed signal (G) in the right parietal lobe, whereas fluid-attenuated inversion recovery (H) showed hyperintense signal, suggestive of hemorrhagic transformation. I–L: Diffused air emboli were seen prominently in the right hemisphere and resulted in cerebral edema on head CT.

young patient. Based on the available medical history and imaging findings, including the proximity of the affected pulmonary vein to the infectious focus and HT, the potential mechanism of the initial stroke was severe pulmonary infection causing damage to the adjacent pulmonary vein, resulting in local PVT. Subsequently, the thrombus and/or septic emboli spread to the brain through the injured pulmonary vein, leading to multiple ischemic strokes.

The second stroke resulting from air embolism is particularly uncommon. Cerebral air embolism is typically caused by iatrogenic factors, such as cardiothoracic surgeries, interventional radiology procedures, catheter manipulation, and occasionally non-iatrogenic trauma.<sup>1</sup> The etiology of air embolism in this case may have been attributed to the elevated intrathoracic and transpulmonary pressure resulting from coughing, that subsequently propelled air into the pulmonary vein, which rendered permeable due to an underlying infection.<sup>2</sup> As a result, the gas diffused into the systemic circulation via the left heart, leading to cerebral air embolism. The presence of hemoptysis, indicative of pulmonary abscess and further lung tissue destruction, may have facilitated the entry of air into the circulation as well. Furthermore, the presence of air in the brain with a multifocal distribution, particularly in the right hemisphere, substantiates its arterial origin. This occurrence can be attributed to the tendency of air bubbles, owing to their specific weight, to traverse through the brachiocephalic artery, which is the primary branch of the aortic arch and follows an upward oblique trajectory.<sup>3</sup>

This case highlights the complexity of stroke etiology in young patients with systemic infections. Prompt identification and treatment of the underlying infection are crucial in preventing and managing neurological complications. Despite the positive impact of broad-spectrum antibiotics on clinical symptoms and inflammatory markers, the progression of pulmonary abscess was still evident on imaging.

Bronchoscopy may be considered necessary to identify the causative agent and facilitate abscess drainage<sup>4</sup>, thereby significantly mitigating the inflammatory response and preventing potential complications. The use of anticoagulation for PVT should be reevaluated in the present patient with suspected septic emboli. Anticoagulation is not recommended for similar embolic strokes related to infective endocarditis due to the high risk of HT.<sup>5</sup> Furthermore, a double-lumen tube is recommended to isolate the affected lung rather than a large-bore endotracheal tube in the present case. This approach serves to prevent blood pooling in the unaffected lung, which could lead to asphyxiation, while also providing non-ventilation on the affected side, thereby avoiding further gas entry into circulation through the pulmonary vein.

This case report underscores the importance of early detection, diagnosis, and appropriate treatment in young patients with infected systemic embolism to prevent serious complications.

#### Grant support

This work was supported by The Construction Fund of Medical Key Disciplines of Hangzhou (OO20200485), Zhejiang Provincial Medical and Health Technology Project (2022KY251 and 2023RC226).

#### Declaration of Competing Interest

We declare that we have no financial and personal relationships with other people or organizations that can inappropriately influence our work, there is no professional or other personal interest of any nature or kind in any product, service and/or company that could be construed as influencing the position presented in, or the review of, the manuscript entitled.

## Acknowledgments

Not applicable.

## References

1. Brown AE, Rabinstein AA, Braksick SA. Clinical characteristics, imaging findings, and outcomes of cerebral air embolism. *Neurocrit Care*. 2023;38:158–164. <https://doi.org/10.1007/s12028-022-01664-3>.
2. Ono R, Kushi Y. Cerebral air embolism caused by persistent cough. *Intern Med*. 2018; 57:1329–1330. <https://doi.org/10.2169/internalmedicine.9805-17>.
3. Griese H, Seifert D, Koerfer R. Cortical infarction following cardiosurgical procedures - air embolism as a probable cause. *Eur Neurol*. 2009;61:343–349. <https://doi.org/10.1159/000210546>.
4. Kuhajda I, Zarogoulidis K, Tsirgogianni K, Tsavlis D, Kioumis I, Kosmidis C, Tsakiridis K, Mpakas A, Zarogoulidis P, Zissimopoulos A, et al. Lung abscess-etiology, diagnostic and treatment options. *Ann Transl Med*. 2015;3:183. <https://doi.org/10.3978/j.issn.2305-5839.2015.07.08>.
5. Baddour LM, Wilson WR, Bayer AS, Fowler VG, Tleyjeh IM, Rybak MJ, Barsic B, Lockhart PB, Gewitz MH, Levison ME, et al. Infective endocarditis in adults: diagnosis, antimicrobial therapy, and management of complications. *Circulation*. 2015;132:1435–1486. <https://doi.org/10.1161/cir.0000000000000296>.