

Subcortical neglect

Graveleau Ph., Viader F., Cambier J.

Clinique Neurologique, Hôpital Beaujon, Clichy, France

The unilateral neglect syndrome is defined as a lack of directed attention to one half of the space or the body. It has been reported mainly after cortical lesions of the right parietal or frontal lobe in man. However, there is strong experimental and clinical evidence for the existence of neglect syndromes of subcortical origin. The unilateral neglect syndrome is not the result of elementary sensory deficits. The failure in directed attention is dependent on an imbalance of hemispheric activation.

Key-Words: subcortical neglect - sensory deficit - hemi-inattention - motor neglect

Introduction

In the past few years attention has been paid increasingly neuropsychological effects of subcortical pathology. This has been the case with aphasia following left thalamic lesions [7, 9, 35], as well as for the so-called subcortical dementia of progressive supranuclear palsy [1, 8]. Similarly, unilateral neglect syndromes may follow subcortical lesions, mainly of the right cerebral hemisphere.

The unilateral neglect syndrome is defined as a lack of directed attention to one-half of the space or body [25]. It may involve one or more following elements:

1 — Hemi-inattention, that is, failure to respond to sensory stimulation, whether visual, auditory or somesthetic from one side of the space or body. In the least severe cases, there is only extinction on bilateral simultaneous stimulation. In principle, the failure to respond must not be ascribable to any elementary sensory disturbance.

2 — Failure to orientate towards one side or to explore one-half of extra-personal space, either visually or manually (hemispacial akinesia). In severe cases there is also a strong active tendency to deviate to the side of the lesion. Hemi-inattention and hemispacial akinesia are commonly associated, leading to unilateral spatial agnosia.

3 — Motor neglect, or unilateral hypokinesia (without major motor weakness).

Several behavioral disorders may be associated to the neglect syndrome: anosognosia, asomatognosia, disorientation, spatial delusions, motor impersistence and constructional apraxia.

The unilateral neglect syndrome has been reported mainly after cortical lesions of the right parietal

[13, 32] or frontal [11, 24] lobes in man. However, there is at present strong experimental and clinical evidence for the existence of neglect syndromes of subcortical origin.

As far back as 1934, Van Bogaert [3] reported one case of right thalamic infarct with disturbances of the body image. In 1938, De Morisier [16] observed a right thalamic hemorrhage with features of the non-dominant hemisphere syndrome. Since then, several other cases have been reported [31, 46], but the term "thalamic neglect" was coined by Watson and Heilman with three additional cases of right thalamic hemorrhage [49].

In animals unilateral neglect has been shown to occur not only after cortical [47, 52] but also after discrete subcortical lesions. In cats, visual neglect was obtained by Orem and co-workers [36] with destruction of the intralaminar nuclei of the thalamus. In monkeys, Watson and co-workers induced unilateral multimodal neglect through mesencephalic reticular formation lesions [48] and unilateral motor neglect by destruction of the intralaminar nuclei, centrum medianum and parafascicular [50]. In man, the consequences of stereotactic thalamic surgery on higher cerebral function have been extensively studied, and they provide some information about the mechanisms of subcortical neglect [54]. Coagulation of ventrolateral nuclei has mostly induced contralateral motor neglect whichever the side operated. However, selective impairments of visuo-spatial activities have been observed after right-sided ventrolateral thalamotomy [44, 45] for parkinsonism. Similarly, Hécaen and his associates reported disturbances of the body image following a right thalamotomy

partly involving the median nuclei [22]. All these changes were usually transient, perhaps because the thalamic target was limited.

In human pathology unilateral neglect has been observed following damage to either the thalamus or the juxtathalamic structures (including both basal ganglia and white matter) or both. A hitherto unpublished case will illustrate this topic.

Case report

A 71 year-old hypertensive man was admitted for left-sided weakness of sudden onset. He had a left hemiplegia with left hypoesthesia, but full visual fields on confrontation. He completely denied his illness. He was desoriented for time and place and believed he was travelling in Moscow. Despite a slight tendency to look to the right, he could orient leftwards on verbal commands. He could not keep his eyes closed for more than a few seconds. CT scan showed a right thalamic hemorrhage (Fig. 1). Formal testing disclosed left neglect in target cancellation (Fig. 2), picture description (Fig. 3) and reading words or sentences. When locating cities on a map of France or monuments on a map of Paris, he showed a tendency to upward and rightward deviation (Fig. 4). In drawings, constructional apraxia was marked, together with

omission of the left half of models (Fig. 5). There was left visual extinction, as well as left ear extinction on verbal dichotic testing. Finally, despite a definite motor improvement, he failed to use his left limbs spontaneously, showing left motor neglect. These findings are consistent with the reports of multimodal neglect in three cases of thalamic hemorrhage by Watson and Heilman [49], in one case of median thalamic infarction by Watson et al [51] and in two cases of hemorrhage and one infarction of the thalamus by Cambier et al [4]. In most cases, anatomical and/or CT data revealed that the whole thalamus was involved, sometimes together with neighboring white matter. However, in two instances at least, the global neglect syndrome was associated with partial thalamic involvement: a thalamic infarction including the medial nuclear group and portions of the posterior/ventral nucleus and of the pulvinar in Watson's case [51] (CT — clinical correlation), and, an infarction of the pulvinar, VPL and dorso medial nuclei in the case 1 of Cambier et al [4] (anatomical data). Predominantly motor neglect has also been shown to occur in thalamic lesions. Schott et al [37] reported a case of right thalamic hemorrhage with left motor neglect and left sensory extinction. Only the posterior thalamic region was involved. Likewise, Laplane et al [29] reported two cases of pure motor neglect following right thalamic damage, predominantly involving lateral nuclei. In those cases, most of the medial nuclei seem to have been spared. These observations emphasize the possibility of dissociated neglect in thalamic lesions. As shown by Cambier et al [5], patients with right posterior cerebral artery infarcts involving both the thalamus (deep territory) and the occipital cortex (superficial territory) also have an even more conspicuous left neglect syndrome. The comparison with isolated superficial territory infarcts demonstrates that neglect arises from the thalamic lesion. The cortical lesion only appears to enhance the neglect syndrome and to worsen it, especially in its visuo-spatial aspects.

Neglect syndromes may also occur after subcortical white matter and/or basal ganglia involvement. Left visual-spatial neglect has been reported by Cambier et al [6] and Ferro and Kertesz [18] following ischemia of the posterior limb of the right internal capsule. One of these patients also had left ear extinction on verbal dichotic testing, but none of them had anosognosia, or asomatognosia. It could not be determined whether motor or somesthetic neglect was present because of severe motor weakness and dense hypoesthesia. An interesting feature of these patients was that they performed better in spontaneous drawings than in copying or in cancellation tasks [6], a finding which supports an «attentional» mechanism for that type of neglect syndrome.

Pure motor neglect has been observed following


Fig.1. Right thalamic hemorrhage.

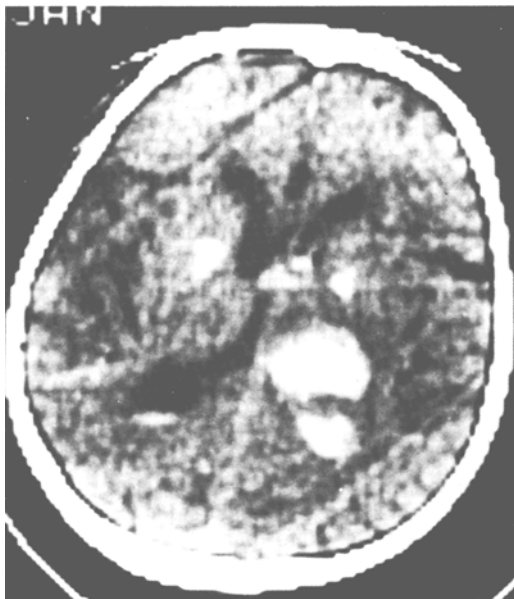



Fig. 2. *Left neglect in target cancellation.*

Fig. 3. *Picture description. The patient described only the right side of the picture.*



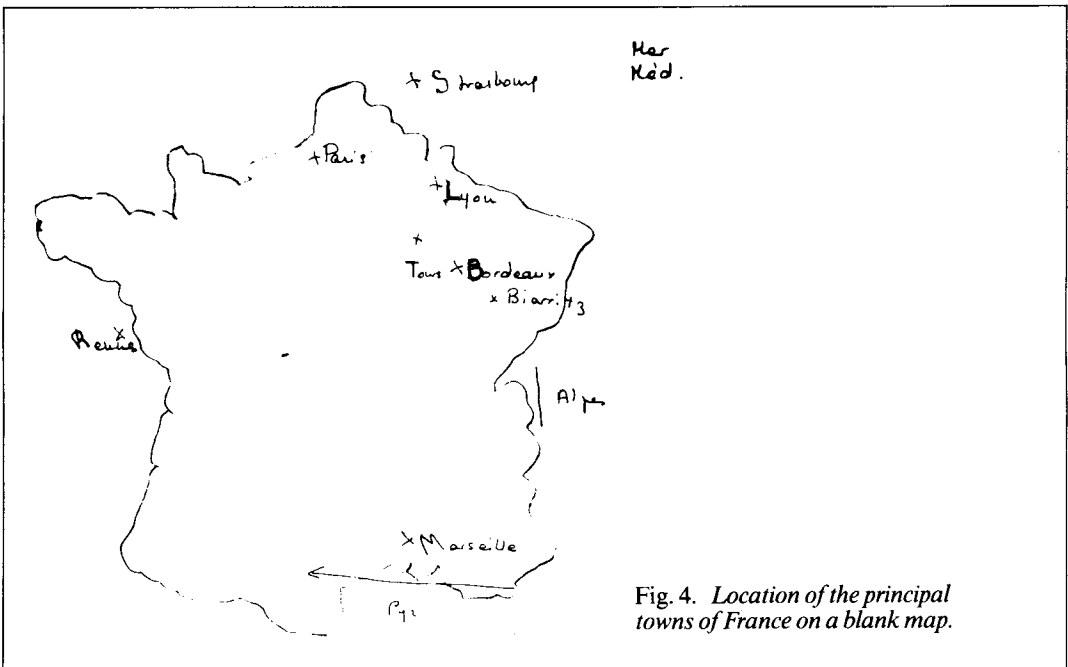


Fig. 4. Location of the principal towns of France on a blank map.

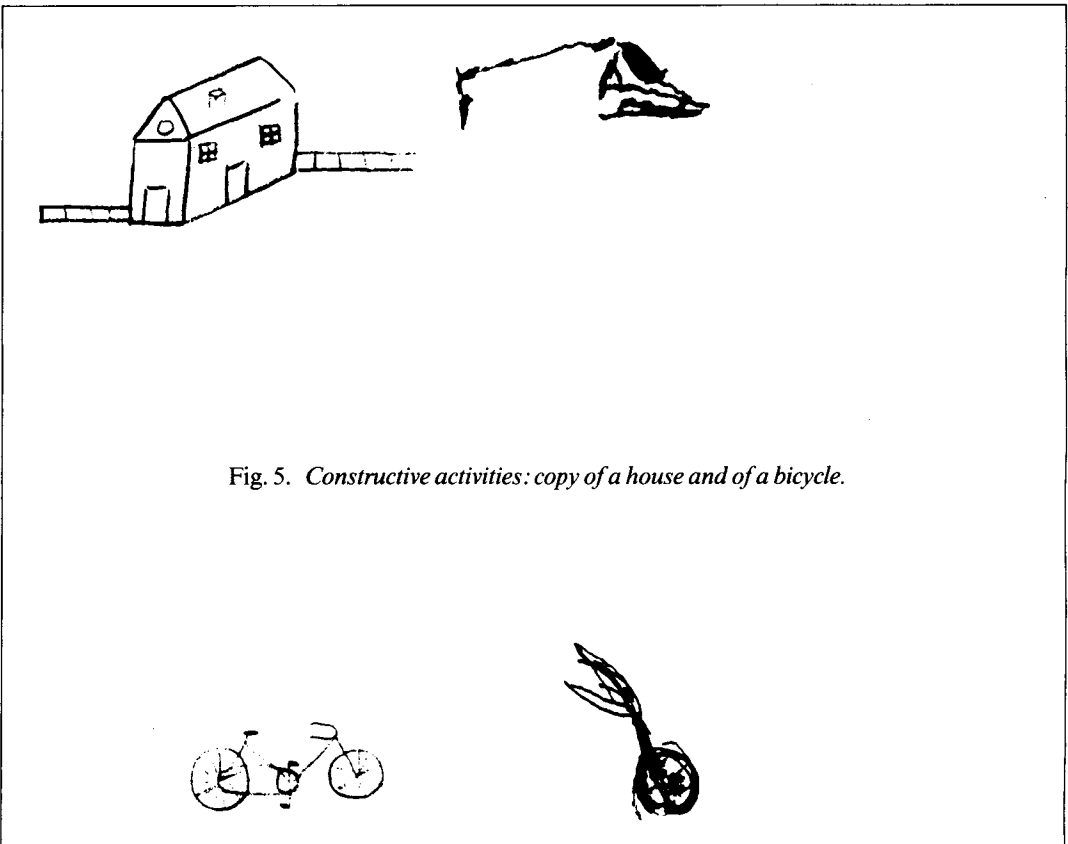


Fig. 5. Constructive activities: copy of a house and of a bicycle.

ischemia of the anterior limb of the internal capsule [52] and hemorrhage of the caudatus nucleus [41]. Left limb hypokinesia was associated with left motor extinction, that is enhancement of akinesia with simultaneous movement on both sides. Infarction of basal ganglia and/or deep frontal white matter has been followed by visual spatial neglect [14, 39]. Finally, Heaton et al [21] reported a case of unilateral left multimodal neglect with asomatognosia and anosognosia caused by an infarction of striatum and deep white matter, including both limbs of the internal capsule, but sparing the thalamus.

Subcortical hemispheric lesions may give rise to a variety of unilateral neglect syndromes. Dissociated types of neglect may occur, either motor or sensory, which are reminiscent of what has been observed in frontal [11, 24] or limited parietal cortical lesions respectively [15]. Similarly, extensive damage to the thalamus or surrounding white matter and basal ganglia may result in a global neglect syndrome, together with anosognosia and asomatognosia, that is hardly distinguishable from the classical «parietal» neglect syndrome.

Both pathways and nuclei involved in transmission of sensory impulses are frequently damaged in patients with neglect syndromes from subcortical lesions. Thus, the role of elementary sensory deficits in neglect symptoms has been put forward. Pure sensory stroke, a condition which usually includes heavy sensory disturbances on one side of the body, does not result in unilateral neglect [10].

Lateral homonymous hemianopia does not result either in visual-spatial neglect by itself; Willanger et al [53] found that, in 55 patients with rightsided cerebral lesions visual neglect was as frequent in patients with as in patients without visual field defects.

Finally, central nervous system lesions cannot induce unilateral deafness, and dichotic extinction in neglect syndromes must be interpreted as an imbalance at a level far higher than of elementary sensory input. On the other hand, unilateral spatial neglect may occur without any visual field defect or gaze paralysis. Moreover, the hyperactivity displayed by some neglect patients in or towards the hemispace ipsilateral to their lesions could not be explained solely in terms of reduced sensory input.

Thus, unilateral neglect following subcortical lesions is a specific phenomenon. The relatively few well-documented cases do not allow definitive clinico-anatomical correlations. However, it appears that multimodal neglect is usually observed after either lesions, or disruption of the thalamo-cortical connections [21]. Isolated visual-spatial neglect appears to be rare, and so far has been observed only after discrete lesions of the posterior limb of the internal capsule. Neglect has been in-

terpreted as being the consequence of a disconnection between the posterior thalamus and the inferior parietal lobule [18], the involvement of which has been documented in purely attentional neglect syndromes [15]. However, the thalamic starting point(s) of the supposedly disrupted pathways remain to be defined. Although it has been suggested that it could be the pulvinar [18] there is no documented case to date of lasting visual spatial neglect after isolated pulvinar damage. Motor neglect is far more common and may be observed after damage to a variety of subcortical structures [14, 20, 23, 29, 37, 41, 42], all of which are known to be involved in motor control and activation. Whereas in thalamic surgery, coagulation of VA or VL has resulted in motor neglect whichever the side operated [20], virtually all documented cases of motor neglect in human pathology involve lesions of the non-dominant hemisphere, either cortical or subcortical. Thus, the mechanisms that are disrupted in motor neglect seem to be integrated at different levels, one of which at least belongs more specifically to the non-dominant hemisphere. Besides the thalamotomy cases, it is logical to discuss the pathophysiology of motor neglect together with the other aspects of neglect syndrome.

Pathophysiology

It is admitted that the unilateral neglect phenomenon reflects a failure in directed attention [25]. This failure impairs both attendance to actual stimuli and mental representation of temporally reconstructed structures [2]. The organization of cerebral structures mediating directed attention is debated. According to Watson et al [51], sensory attention on the one hand, and motor activation and preparation to respond on the other, are served by reticulo-cortico-limbic loops, involving the mesencephalic reticular formation, the nucleus reticularis and the medial thalamic nuclei, and parts of the cortex including cingulate gyrus, inferior parietal lobule and prefrontal cortex. Mesulam [33] favors the network model, with three cortical components (frontal, parietal and limbic) and a reticular component which provides for tonic arousal. In both models, the medial thalamic nuclei play a central part in directed attention, a view which is consistent with most clinical cases of thalamic neglect. Intralaminar thalamic nuclei receive input from the midbrain reticular formation and project primarily to the striatum and frontal cortex [27, 40] but their stimulation involves widespread cortical areas, including frontal, cingulate and parietal cortical association areas. Thalamic neglect provides a dramatic clinical demonstration of the physiological importance of these structures. The cases of disso-

ciated neglect with different subcortical lesion sites may stem from selective disruption of distinct thalamocortical activation pathways. The importance of subcortical structures in neglect has been further stressed by Deuel and Collins [17], who have shown by quantitative 2—deoxyglucose autoradiographic studies that unilateral neglect induced in monkeys by dorsolateral frontal cortex removal was consistently associated with metabolic depression in selected subcortical areas, including basal ganglia, parts of nucleus medialis dorsalis of the thalamus and ventral anterior nucleus of the thalamus. Moreover, these subcortical metabolic changes disappeared after recovery from neglect. These data indicate that several brain areas, both cortical and subcortical, work together to serve attentional processes, and that clinical symptoms observed after a single lesion may result from more widespread brain dysfunction. Recovery may be linked to the possibility of using alternate connections, which have been spared, to re-activate the metabolically depressed distant structures, as observed by Deuel and Collins.

Unilateral neglect is far more common and more marked [7, 12, 19, 23, 38] after right than left brain damage in man. This assumption holds good for subcortical as well as for cortical cases, and implies that the right cerebral hemisphere is in some way dominant for the function that is failing in the neglect syndrome, i.e. directed attention [26]. According to this hypothesis, the right hemisphere is able to process stimuli from both sides of space, but the left hemisphere only contralateral stimuli. The same is true for preparation to act within or towards one side of space or with one half of body. After left brain damage, the bilateral attentional abilities of the intact right hemisphere would explain the absence or mildness of the neglect phenomena. In right-sided lesions, left stimuli cannot be processed any more and neglect appears. It may even be enhanced by the unopposed

activity of the healthy left hemisphere, which is further stimulated by the activating role of language [28], thereby worsening the interhemispheric imbalance. There is a substantial amount of experimental evidence to support the model of right attentional dominance [32]. This asymmetry for directed attention processes had not been observed in experimental neglect in animals [52]. It could result indirectly from the development in the left cerebral hemisphere of linguistic abilities, with the corresponding structures taking over directed attention on the right side [30]. This attentional specialization of the right hemisphere, however, depends on extensive connections, both inter — and intra — hemispheric. Although directed attention may be more corticalized in humans than in monkeys or cats [33], it has also been observed that the more lasting cases of neglect follow subcortical lesions in man [34]. Furthermore, the typical cases of thalamic [4, 49, 51] or juxtathalamic neglect [21] are virtually indistinguishable from the «classical» cortical cases. This does not appear to be the rule for subcortical and particularly thalamic, aphasia [35]. It is tempting to compare the left hemispheric dominance for language and right dominance for directed attention. In fact, the directed attention processes seem both to be less corticalized and to depend more on global hemispheric activation than language functions. We have compared the cortical cerebral blood flow (CBF) in patients with either right or left thalamic lesions, and we have observed that only right thalamic lesions with a left neglect syndrome led to a significant asymmetry of CBF, with a diffuse cortical lowering on the side of the lesion [43]. It will be interesting to find out whether patients with unilateral neglect secondary to parietal damage have subcortical metabolic depression, especially in the thalamus and/or basal ganglia. More clinical studies are needed to refine CT—clinical correlations in neglect syndromes and to clarify the neural basis of directed attention.

Sommario

La sindrome di inattenzione è definita come una mancanza di attenzione diretta, su una metà dello spazio o sull'emicorpo. È stata descritta soprattutto in relazioni a lesioni corticali situate a destra, in sede parietale o frontale nell'uomo. Tuttavia vi sono molti elementi sperimentali e clinici sull'esistenza di sindrome di inattenzione di origine sottocorticale. Infatti questa sindrome non è conseguenza di deficit sensoriali elementari, ma dipende da uno squilibrio di attivazione emisferica.

Address reprint requests to: Gravelleau Ph.
Clinique Neurologique - Hôpital Beaujon
100 bd du Général Leclerc - 92110 Clichy - France

References

- [1] D'ANTONA R., BARON JC., SAMSON Y., VIADER F., AGID Y., CAMBIER J.: *Subcortical dementia*. Brain 108, 785-799, 1985.
- [2] BISIACH E., LUZZATTI C., PERANDI D.: *Unilateral neglect, representational schema and consciousness*. Brain, 102, 609-618, 1979.
- [3] BOGAERT L. V.: *Sur la pathologie de l'image de soi*. Ann. Méd. Psychol., 92 519-555, 744-759, 1934.
- [4] CAMBIER J., ELEGHOZI D., STRUBE E.: *Lésion du thalamus droit avec syndrome de l'hémisphère mineur. Discussion du concept de négligence thalamique*. Rev. Neurol., 136, 106-166, 1980.
- [5] CAMBIER J., MASSON M., GRAVELEAU Ph., ELGOZI D.: *Sémiologie de négligence lors de lésions ischémiques dans le territoire de l'artère cérébrale postérieure droite. Rôle de la lésion thalamique*. Rev. Neurol., 138, 631-648, 1982.
- [6] CAMBIER J., GRAVELEAU Ph., DECROIX JP., ELGHOZI D., MASSON M.: *Le syndrome de l'artère choroïdienne antérieure. Etude neuropsychologique de 4 cas*. Rev. Neurol., 139, 553-559.
- [7] CAMBIER J., GRAVELEAU Ph.: *Thalamic syndromes*. In: Vinken PJ, Bruyn GW, Klawans HL (Eds), Handbook of Clinical Neurology, Vol (1) 45, Clinical Neuropsychology, PP 87-98. Elsevier Amsterdam (1985).
- [8] CAMBIER J., MASSON M., VIADER F., LIMODIN J., STRUBE A.: *Le syndrome frontal de la paralysie supranucléaire progressive*. Rev. Neurol. (Paris) 141, 528-536, 1985.
- [9] CAPPAS SF., VIGNOLO LA.: *«Transcortical» features of aphasia following left thalamic hemorrhage*. Cortex 15, 121-130, 1979.
- [10] CASTAIGNE P., CAMBIER J.: *La sémiologie des lésions thalamiques*. La Presse Médicale, 77, 1101-1103, 1969.
- [11] CASTAIGNE P., LAPLANE D., DEGOS JD.: *Trois cas de négligence motrice par lésion frontale prérolandique*. Rev. Neurol. 126, 5-15, 1972.
- [12] CHAIN F., LEBLANC M., CHEDRU F., LHERMITTE F.: *Négligence visuelle dans les lésions postérieures de l'hémisphère gauche*. Rev. Neurol. (Paris) 135, 105-126, 1979.
- [13] CRITCHLEY M.: *The parietal lobes* London, Edward Arnold Publ, 1953.
- [14] DAMASIO AR., DAMASIO H., CHANG CHUI H.: *Neglect following damage to frontal lobe or basal ganglia*. Neuropsychologia, 18, 123-132, 1980.
- [15] DEHEN H., CAMBIER J.: *Négligence somesthésique visuelle auditive et impersistence motrice par lésion ischémique limitée hémisphérique droite*. Nouv. Presse Méd., 9, 249, 1980.
- [16] DE MORSIER G.: *Les hallucinations*. Rev Oto-neuro-ophthalmol., 16 241-352.
- [17] DEUEL RK., COLLINS RC.: *The functional anatomy of frontal lobe neglect in the monkey: behavioral and quantitative 2-deoxyglucose studies*. Ann. Neurol., 15, 521-529, 1984.
- [18] FERRO JM., KERTESZ A.: *Posterior internal capsule infarction associated with neglect* Arch. Neurol., 41, 422-424, 1984.
- [19] GAINOTTI G., MESSERLI P., TISSORT R.: *Qualitative analysis of unilateral spatial neglect in relation to laterality of cerebral lesions*. J. Neurol. Neurosurg. Psychiat., 35, 545-550, 1972.
- [20] HASSLER R., MUNDIGER F., RIECHERT T.: *Stereotaxis in parkinson syndrome*. Berlin, Springer Verlag, Vol. 1.
- [21] HEALTON EB., NAVARRO C., BRESSMAN S., BRUST JCM.: *Subcortical neglect*. Neurology (NY) 32, 776-778, 1982.
- [22] HECAEN H., TALAIRACH J., DAVID M., DELL MB.: *Coagulations limitées du thalamus dans les algies du syndrome thalamique. Résultats thérapeutiques et physiologiques*. Rev. Neurol., 81, 917-931, 1949.
- [23] HEILMAN KM., BOWERS D., COSLETT HB., WHELAN H., WATSON RT.: *Directional hypokinesia: prolonged reaction times for leftward movement in patients with right hemisphere lesions and neglect*. Neurology, 35, 855-859, 1985.
- [24] HEILMAN KM., VALENSTEIN E.: *Frontal lobe neglect in man*. Neurology, 22, 660-664, 1972.
- [25] HEILMAN KM., VALENSTEIN E., WATSON RT.: *The neglect syndrome*. In J. A. M. Fredericks (ed.) Handbook of Clinical Neurology, Vol. 1 (45) Clinical Neuropsychology, Elsevier Science Publishers Bv (the Netherlands) 1985.
- [26] HEILMAN KM., VAN DEN ABELL T.: *Right hemisphere dominance for attention: the mechanism underlying hemispheric asymmetries of inattention (neglect)*. Neurology 30, 327-330, 1980.
- [27] JONES E., LEAVITT RY.: *Retrograde axonal transport and the demonstration of non specific projection to the cerebral cortex and striatum from the thalamic intralaminar nuclei in the rat, cat and monkey*. J. Comp. Neurol., 154, 349-378, 1974.
- [28] KINSBOURNE M.: *Hemineglect and hemisphere rivalry*. In: EA Weinstein and RP Friedland (Eds), Advances in Neurology, Vol. 18, Raven Press, New-York, PP 41-49.
- [29] LAPLANE D., ESCOUROLLE R., DEGOS JD., SAURON B., MASSIOU H.: *La négligence motrice d'origine thalamique — A propos de deux cas*. Rev. Neurol., 138, 201-211, 1982.
- [30] LEDOUX T., WILSON DH., GAZZANIGA MS.: *Manipulo-spatial aspects of cerebral lateralization*. Neuropsychologia 15, 743-750, 1977.
- [31] LHERMITTE F., CAMBIER J.: *Les perturbations somatognosiques en pathologie nerveuse*. LVIII^e Cong. Psychiat. Neurol. Langue Franc., Masson, Paris, 1980.
- [32] Mc. FIE J., PIERCY MF., ZANGWILL O.: *Visual-spatial agnosia associated with lesions of the right cerebral hemisphere*. Brain, 73, 167-190, 1950.
- [33] MESULAM MM.: *A cortical network for directed attention and unilateral neglect*. Ann. Neurol., 10, 309-325, 1981.
- [34] MESULAM MM.: *Attention, confusional states and neglect in Mesulam MM (Ed)*. Principles of Behavioral Neurology, p 125-168, FA Davis Company Philadelphia, 1985.
- [35] NAESER MA.: *CT scan lesion size and lesion locus in cortical and subcortical aphasias*. In Kertesz A (Ed.) Localization in Neuropsychology. Academic Press (London, UK) 1983.
- [36] OREM J., SCHLAG-REY M., SCHLAG J.: *Unilateral visual neglect and thalamic intralaminar lesions in the cat*. Exp. Neurol. (Paris) 40, 784-797, 1973.
- [37] SCHOTT B., LAURENT B., MAUGUIÈRE F., CHAZOT G.: *Négligence motrice par hématomate thalamique droit*. Rev. Neurol. (Paris) 137, 447-455, 1981.
- [38] SCHWARTZ AS., MARCHOK PL., KREINICK CJ., FLYNN RE.: *The asymmetric lateralization of tactile*

- extinction in patients with unilateral cerebral dysfunction. *Brain* 102, 669-684, 1979.
- [39] STEIN S., VOLPE BT.: *Classic «parietal» neglect syndrome after subcortical right frontal lobe infarction* *Neurology (Cl.)* 33, 797-799, 1983.
- [40] STERIADE M., GLENN L.: *Neocortical and caudate projection of intralaminar thalamic neurons and their synaptic excitation from the midbrain reticular core*. *J. Neurophysiol.* 48, 352-370, 1982.
- [41] VALENSTEIN E., HEILMAN KM.: *Unilateral hypokinesia and motor extinction*. *Neurology (Ny)* 31, 445-448, 1981.
- [42] VIADER F., CAMBIER J., PARISER P.: *Phénomène d'extinction motrice gauche*. *Rev. Neurol.*, 138, 213-217, 1982.
- [43] VIADER F., CAMBIER J., LUFT A., PONSIN JC., MERIC P., MAMO H.: *Etude du débit sanguin cérébral par inhalation de 133 Xe chez des patients atteints de lésions thalamiques et juxta-thalamiques*. «Le Thalamus-Physiologie et Pathologie» Paris 6-7 Juin 1985.
- [44] VILKKI J., LAITINEN LV.: *Differential effects of left and right ventrolateral thalamotomy on receptive and expressive verbal performances and face-matching*. *Neuropsychologia*, 12, 11-19, 1974.
- [45] VILKKI J.: *Effects of thalamic lesion on complex perception and memory*. *Neuropsychologia*, 16, 427-437, 1978.
- [46] WALSH J.M., DAVIS K.R., FISCHER C.H.: *Thalamic hemorrhage: a computed tomographic clinical correlation* *Neurology*, 27, 217-222, 1977.
- [47] WATSON RT., HEILMAN KM., CAUTHEN JC., KING FA.: *Neglect after cingulectomy* *Neurology*, 1003-1007, 1973.
- [48] WATSON RT., HEILMAN KM., MILLER BD., KING FA.: *Neglect after mesencephalic reticular formation lesions* *Neurology*, 24, 294-298, 1974.
- [49] WATSON RT., HEILMAN KM.: *Thalamic neglect*. *Neurology*, 29, 690-694, 1979.
- [50] WATSON RT., MILLER BD., HEILMAN KM.: *Non-sensory neglect*. *Ann. Neurol.*, 3, 505-508, 1978.
- [51] WATSON RT., VALENSTEIN F., HEILMAN KM.: *Thalamic neglect* *Arch. Neurol.*, 38, 501-506, 1981.
- [52] WELCH K., STUTEVILLE P.: *Experimental production of unilateral neglect in monkeys*. *Brain*, 81, 341-347, 1958.
- [53] WILLANGER R., TARP DANIELSEN U., ANKERHUS J.: *Visual neglect in right-sided apoplectic lesions*. *Acta Neurol. Scand.*, 61, 327-336, 1981.
- [54] ZOLL J.G.: *Transient anosognosia associated with thalamotomy: is it caused by proprioceptive loss*. *Confin. Neurol.*, 31, 48-55, 1969.