

Aneurysms of the Posterior Cerebral Artery: Report of Ten Cases

Han Soo Chang, M.D., Takanori Fukushima, M.D., D.M.Sc., Kintomo Takakura, M.D., D.M.Sc., Tsuneo Shimizu, M.D.

Department of Neurological Surgery, Mitsui Memorial Hospital, Tokyo (HSC, TF); Department of Neurosurgery, Faculty of Medicine, University of Tokyo (KT); and The Kantoh Neurosurgical Hospital, Saitama (TS), Japan

Ten cases of posterior cerebral artery (PCA) aneurysm are presented. There were 13 aneurysms in the 10 patients: 6 saccular, 5 fusiform, 1 broad-based, and 1 giant fusiform serpentine aneurysm. Eight patients underwent operation: clipping for 2 saccular aneurysms, trapping for 1 saccular and 3 fusiform aneurysms, and coating for 2 fusiform or broad-based aneurysms. Microsurgical cerebral revascularization techniques were attempted in 2 cases: after a fusiform aneurysm had been excised, end-to-end anastomosis of the residual two ends of the PCA was performed and, after a giant serpentine aneurysm had been trapped, the superficial temporal artery was anastomosed transcortically to the distal PCA. Two patients died before operation because of rebleeding and vasospasm. Postoperative neurological deficits include contralateral hemiparesis, homonymous hemianopsia, hemihypesthesia, and ipsilateral 3rd nerve palsy. Our results suggest that, despite the good collateral circulation of the PCA, some ischemic events may occur after trapping procedures and that cerebral revascularization techniques may have some benefit in the treatment of unclippable aneurysms in this region. (*Neurosurgery* 19:1006-1011, 1986)

Key words: Cerebral aneurysm, Cerebral revascularization, Posterior cerebral artery

INTRODUCTION

Aneurysms of the posterior cerebral artery (PCA) are rare, making up about 0.7 to 2.2% of all cerebral aneurysms (12, 18). The usual saccular type accounts for about 80% of PCA aneurysms, with fusiform and giant aneurysms accounting for about 10% each (6, 15). Yasargil subdivided these aneurysms into four groups according to the location of the lesion: P_1 , P_1/P_2 junction, P_2 , and P_3 aneurysms (20). Although clipping is the treatment of choice for saccular aneurysms, trapping is preferred for fusiform or giant aneurysms because one can expect the good collateral circulation of the PCA to perfuse the area distal to the occluded site. In fact, many reported cases have demonstrated that trapping can be safely performed in this region (1, 2, 4, 7, 9-11, 13, 17, 20). However, trapping is potentially dangerous and may sometimes cause severe neurological deficits, as described in some of our cases.

To prevent ischemic complications after trapping procedures, we used microsurgical cerebral revascularization techniques in two cases of a fusiform or giant aneurysm. These cases are presented, and the effectiveness of these techniques is discussed.

SUMMARY OF CASES

Case records of the Tokyo University Hospital, Mitsui Memorial Hospital, and the Kantoh Neurosurgical Hospital from January 1970 to July 1985 were reviewed. There were 10 cases of PCA aneurysms (1.3%) among a total of 754 cerebral aneurysms. The clinical courses of these patients are summarized in Table 1. Patients' ages ranged from 18 to 63, with a mean of 45. There were 5 men and 5 women. Of the 13 aneurysms, 6 were saccular, 5 were fusiform, 1 was broad-based, and 1 was giant and fusiform. Eight patients presented with subarachnoid hemorrhage (SAH), and 1 patient (Case 9) presented with progressive hemiparesis and homonymous hemianopsia due to the mass effect of the giant aneurysm. One patient (Case 10) had nonruptured fusiform and saccular

aneurysms at the P_1/P_2 junction that were found incidentally during her stroke examination.

Two patients died before operation, one because of rebleeding (Case 5) and the other because of vasospasm (Case 8). In Case 5, autopsy revealed an aneurysm in the P_2 segment of the dilated right PCA, which fed a large arteriovenous malformation (AVM) in the right occipital lobe. The aneurysms in one patient (Case 8) were associated with moyamoya disease, and the right internal carotid artery was totally occluded just above the bifurcation (Fig. 1A). Vertebral angiography showed numerous moyamoya vessels (Fig. 1B, arrowheads) and also three aneurysms, one in the basilar tip and two in the right PCA (Fig. 1B, arrows).

Two patients early in the series (Cases 1 and 2) were treated with coating of the aneurysmal dome. Other saccular type aneurysms were treated with clipping. Four patients (Cases 3, 4, 6, and 9) were treated with trapping, and cerebral revascularization was also performed in two of these cases (Cases 6 and 9). These four cases are described in detail.

ILLUSTRATIVE CASE REPORTS

Case 3

This 18-year-old girl with a history of chronic glomerulonephritis experienced a sudden onset of severe headache and nausea on May 17, 1980. She was immediately admitted to our hospital, and SAH was diagnosed (Hunt and Kosnik Grade 2). Angiography revealed a saccular aneurysm at the P_1/P_2 junction of the right PCA (Fig. 2). Operation was delayed until June 10. The aneurysm was exposed through a right pterional approach. During dissection of the aneurysmal dome, massive bleeding occurred and the lesion had to be trapped by clipping the PCA and the posterior communicating artery. Left hemiplegia, right oculomotor palsy, and left homonymous hemianopsia were evident postoperatively and persisted. The patient was transferred to a rehabilitation hospital 1 month later.

TABLE 1
Summary of Cases

Case	Sex, Age (yr)	Aneurysm			Clinical Presentation	Grade (Hunt & Kosnik)	Surgery			Postoperative Neurological Status	Results	Associated diseases
		Location	Type	Side			Timing	Approach	Procedure			
1	49, F	P ₁ /P ₂ jct ^a	Fusiform	R	SAH	II	Delayed	Subtemporal	Clipping & coating	L hemiparesis	Good	
2	51, M	P ₂	Broad-based	R	SAH	III	Delayed	Subtemporal	Coating	Transient R 3rd nerve palsy, L hemiparesis, confusion	Fair	
3	18, M	P ₁ /P ₂ jct	Saccular	R	SAH	II	Delayed	Pterional	Trapping	L hemiplegia, R 3rd nerve palsy, L hemianopsia	Poor	
4	43, F	P ₂ P ₃	Fusiform Saccular	R	SAH	I	Delayed	Subtemporal	Trapping clipping	Transient L hemiparesis, L hemihypesthesia, L homonymous hemianopsia	Excellent	
5	67, M	P ₂	Saccular	L	SAH	I					Death	AVM
6	24, M	P ₂	Fusiform	R	SAH	III	Delayed	Subtemporal	Excision & end-to-end anastomosis	Transient L hemiparesis, confusion	Excellent	
7	63, F	P ₃	Saccular	R	SAH	I	Delayed	Subtemporal	Clipping	No deficit	Excellent	Moyamoya disease
8	67, F	P ₂ P ₃ (basilar tip)	Fusiform	R	SAH	II					Death	
9	20, M	P ₁	Giant fusiform	R	Progressive hemiparesis	0		Pterional	Trapping & transcortical STA-PCA anastomosis	Transient confusion, L hemiparesis, L homonymous hemianopsia	Excellent	
10	52, F	P ₁ /P ₂ jct	Fusiform saccular	L	Nonruptured incidental	0		Pterional	Clipping	None	Excellent	

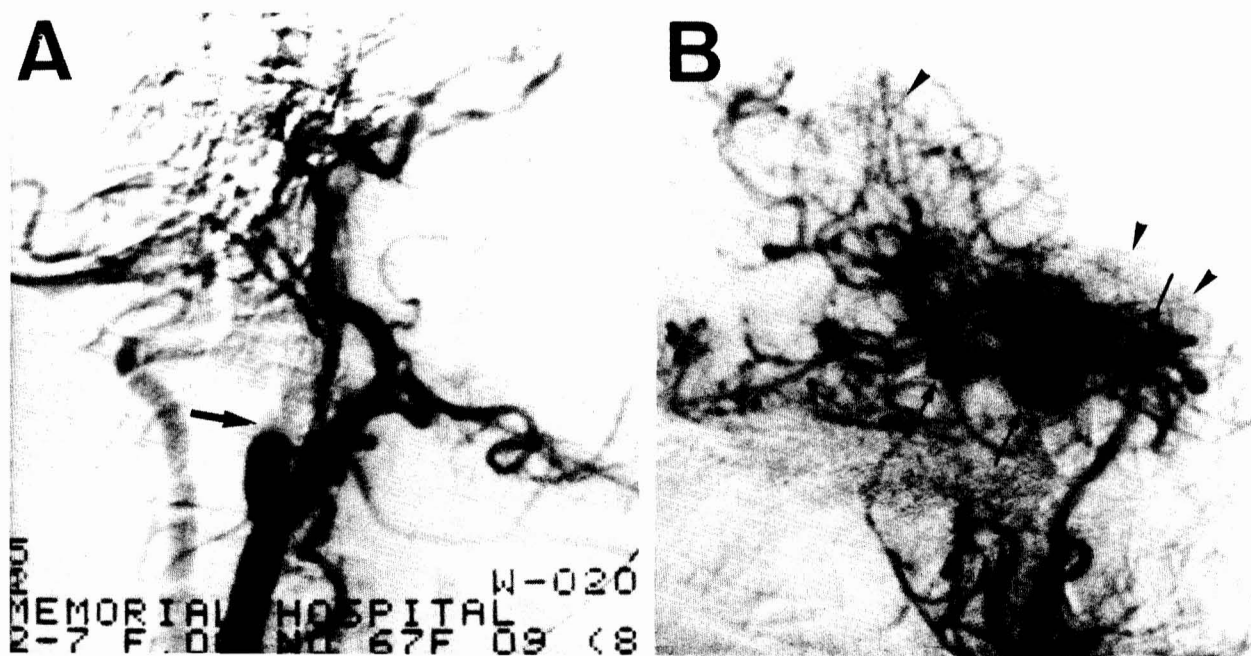
^a Abbreviations: jct, junction

FIG. 1. Case 8. *A*: Right common carotid angiogram, lateral view. The right internal carotid artery is completely occluded just above the bifurcation (arrow). *B*: Vertebral angiogram, right anterior oblique view, showing numerous moyamoya vessels (arrowheads) and three aneurysms, one in the basilar tip (downward arrow) and two in the right PCA (upward arrows).

Case 4

This 43-year-old woman was admitted to our hospital on April 1, 1985, after SAH on the previous day. On admission, she was alert with no neurological deficit (Hunt and Kosnik Grade 1). A fusiform aneurysm was found in the P₂ segment

of the right PCA (Fig. 3*A*). Operation was performed on April 9. The right PCA was exposed subtemporally. First, a small saccular aneurysm was incidentally found in the P₃ segment and was clipped. Then the fusiform aneurysm in the P₂ segment was visualized and trapped. Postoperatively, there were left hemiparesis, left hemihypesthesia, and left homony-

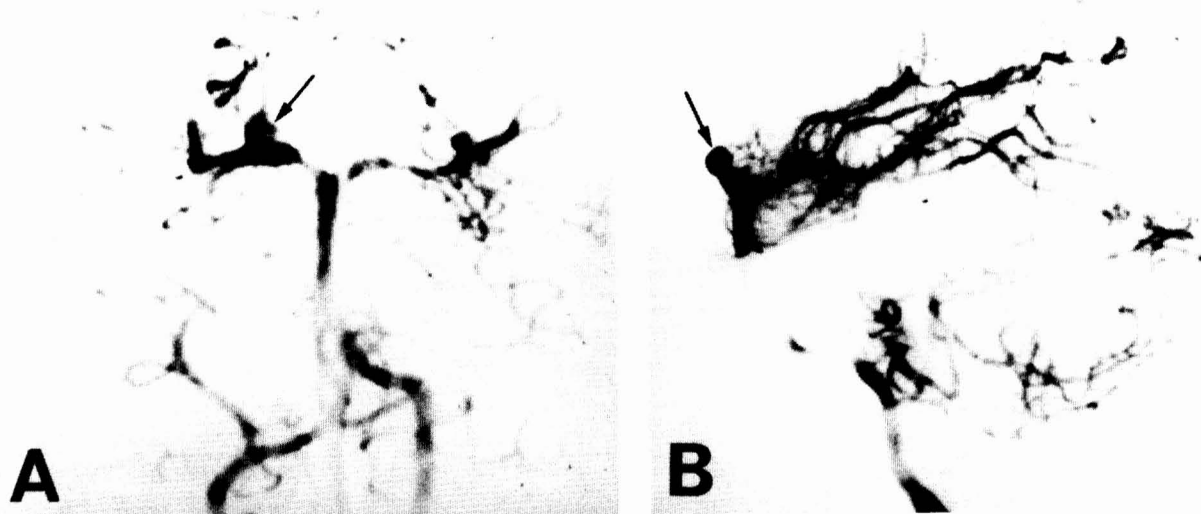


FIG. 2. Case 3. Vertebral angiograms, anteroposterior (A) and lateral (B) views, showing a saccular aneurysm (arrows) at the P₁/P₂ junction of the right PCA.

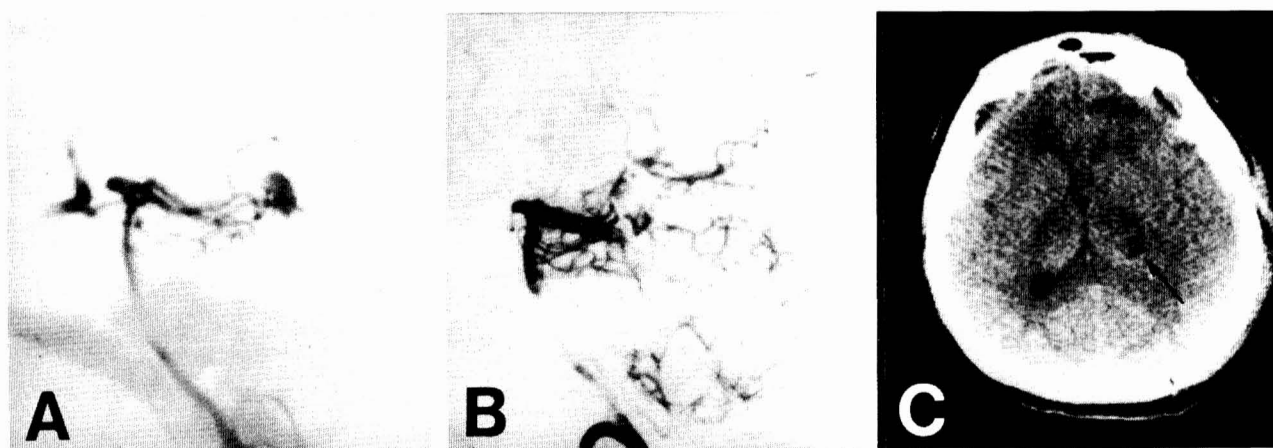

FIG. 3. Case 4. Preoperative (A) and postoperative (B) vertebral angiogram, lateral view. A fusiform aneurysm in the right PCA was treated with trapping. C: Postoperative CT scan showing a small low density area in the right thalamus.

mous hemianopsia, all of which disappeared completely in a week. A computed tomographic (CT) scan 3 days after operation revealed a small low density area in the right thalamus (Fig. 3C, arrow), possibly due to ischemia in the area of the thalamogeniculate artery. Postoperative angiography on April 17 showed that the aneurysm was completely occluded (Fig. 3B) and that the collateral circulation from the right internal carotid artery perfused the area of the occluded PCA. The patient was discharged on May 2.

Case 6

Details of this case were presented in our previous report (3). A 24-year-old left-handed man suddenly fell while walking along the street on July 21, 1984, and complained of severe headache. On admission to our hospital on the next day, he was stuporous, but had no focal neurological deficit (Hunt and Kosnik Grade 3). A CT scan revealed diffuse SAH. An aneurysm was found in the P₂ segment of the right PCA (Fig.

4, A and A'). Operation was intentionally delayed until August 19, waiting for his consciousness to recover. Through a subtemporal approach, the right PCA was exposed. As the aneurysm was completely fusiform and unclippable, it was excised. An end-to-end anastomosis was carried out between the residual two ends of the PCA to reconstruct the normal PCA circulation. After operation, the patient had dysphasia and slight right hemiparesis due to swelling of the right temporal lobe, but the symptoms regressed in 2 weeks. Postoperative angiography showed the patent anastomosis (Fig. 4, B and B'). The patient was discharged home on October 22 without any neurological deficit and returned to his previous job as an office clerk.

Case 9

This 20-year-old man was admitted to our hospital on March 25, 1985, with a 6-month history of progressive left hemiparesis, left homonymous hemianopsia, throbbing head-

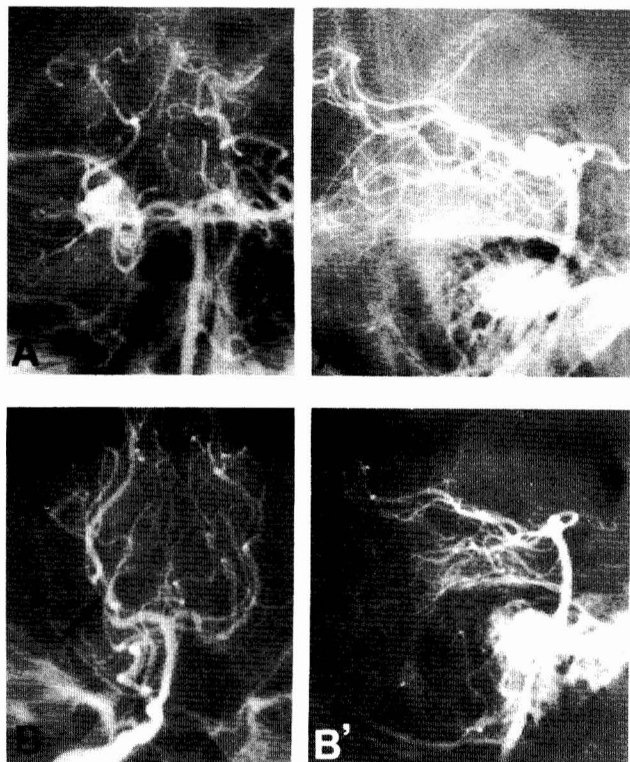


FIG. 4. Case 6. Vertebral angiograms, anteroposterior (left) and lateral (right) views. Top, postoperative angiograms showing an aneurysm in the right P₂ segment. Bottom, postoperative angiograms showing preservation of the normal circulation of the right PCA. Some narrowing at the anastomosis site (arrows) is seen.

ache, and mental obtundation. A CT scan demonstrated a large elongated mass with contrast enhancement, extending from the suprasellar cistern to the right temporoparietal region (Fig. 5C). Vertebral angiography revealed an irregular and tortuous vascular channel beginning from the P₁ segment of the right PCA, making large upward and downward loops, and finally ending in the distal PCA (Fig. 5, A and B). A diagnosis of a giant fusiform serpentine aneurysm of the right PCA was made. On April 2, a large right frontotemporal craniotomy was performed. First, through a pterional approach, the P₁ segment of the right PCA was exposed, and a 22-mm-long clip was placed on the PCA just proximal to the aneurysm, preserving the perforating arteries originating from this segment. Exposure of the distal portion of the aneurysm was attempted through a subtemporal approach, but it was impossible to reach the distal PCA segment subtemporally because of the large mass in the temporal lobe. A small corticotomy was placed on the posterior temporal gyrus and, with the guidance of an ultrasound scanner, the trigonum of the right lateral ventricle was reached. The aneurysmal dome and the distal PCA were exposed via the transventricular route. After the distal PCA had been clipped and separated from the aneurysm, a transcortical-transventricular end-to-end anastomosis was carried out between the superficial temporal artery (STA) and the distal PCA. During closure, the STA was pulsating very well. Postoperatively, the patient was stuporous, and his left hemiparesis worsened temporarily. However, in 2 weeks, he became alert with mild left hemiparesis. Postoperative angiography on April 3 demonstrated that the aneurysm was completely occluded (Fig. 5, A' and B') and that the distal PCA circulation was supplied mainly through the collateral channels from the anterior and middle

cerebral arteries, with minimal flow through the STA-PCA anastomosis (Fig. 5C'). The patient was discharged home after 3 months with no neurological deficit and returned to his previous work.

DISCUSSION

In the treatment of PCA aneurysms, the greatest problem is how to manage unclippable aneurysms. According to a report of 40 cases of PCA aneurysms by Pia and Fontana (15), as much as 20% of the lesions were of the fusiform or giant type, considered to be unclippable or difficult to clip. In such cases, the usual treatment of choice is trapping or proximal clipping. These procedures are considered to be relatively safe because of the remarkable collateral circulation of the PCA.

Previously reported cases of PCA aneurysms treated with trapping or proximal clipping are summarized in Table 2. The results seem to be generally good, although some patients had transient postoperative neurological deficits such as hemiparesis, hemihypesthesia, hemianopsia, or 3rd nerve palsy. Those cases of giant aneurysms in children reported by Amacher et al. are conspicuous in their excellent results (1). This may be due to the youth of the patients or the sufficient collateral circulation to the distal PCA area.

However, there are cases in which persistent neurological deficits occur postoperatively, such as our Case 3. Drake stated that, "A good indication for the collateral is brisk bleeding from a needle hole in the aneurysm after a temporary clip has been placed just proximally on the posterior cerebral artery" (4). Nevertheless, it is actually impossible to predict accurately whether a patient can tolerate abrupt occlusion of the PCA. Neurological deficits such as hemiparesis, hemihypesthesia, or hemianopsia during the postoperative period, even though they are transient, suggest that ischemic events do take place in the area perfused by the perforating arteries from the PCA. In fact, the postoperative CT scan in our Case 4 showed a small, low density area in the right thalamus, possibly due to the decreased circulation from the thalamogeniculate artery.

We think that cerebral revascularization techniques can be beneficial in the treatment of unclippable aneurysms in this region. Although STA-middle cerebral artery anastomosis with carotid ligation is now a standard technique in the management of giant aneurysms of the internal carotid artery (14, 16), only a few cases of cerebral revascularization associated with the treatment of vertebrobasilar circulation aneurysms have been reported. Sundt reported two cases of posterior circulation aneurysms treated with revascularization (17). In one patient with a fusiform aneurysm of the vertebral artery, he constructed an interposition saphenous vein graft between the external carotid artery and the proximal PCA through a subtemporal approach before proximal clipping of the vertebral artery aneurysm. In another patient, after a giant PCA aneurysm had been trapped and excised, the residual distal PCA was anastomosed end-to-side to the superior cerebellar artery. Hopkins et al. reported two cases of basilar tip aneurysms (8) in which the STA was anastomosed end-to-side to the proximal PCA through a subtemporal approach before basilar artery ligation. These cases demonstrated that a saphenous vein graft or STA-PCA anastomosis can provide sufficient blood to the posterior circulation after occlusion of the basilar or vertebral artery. In our two cases treated with cerebral revascularization, the intracranial PCA anastomosis in Case 6 was successful, but the STA-PCA anastomosis in Case 9 did not develop well because of the good collateral circulation from the anterior and middle cerebral arteries.

Although many reported cases suggest the relative safety of a trapping procedure on PCA aneurysms without cerebral

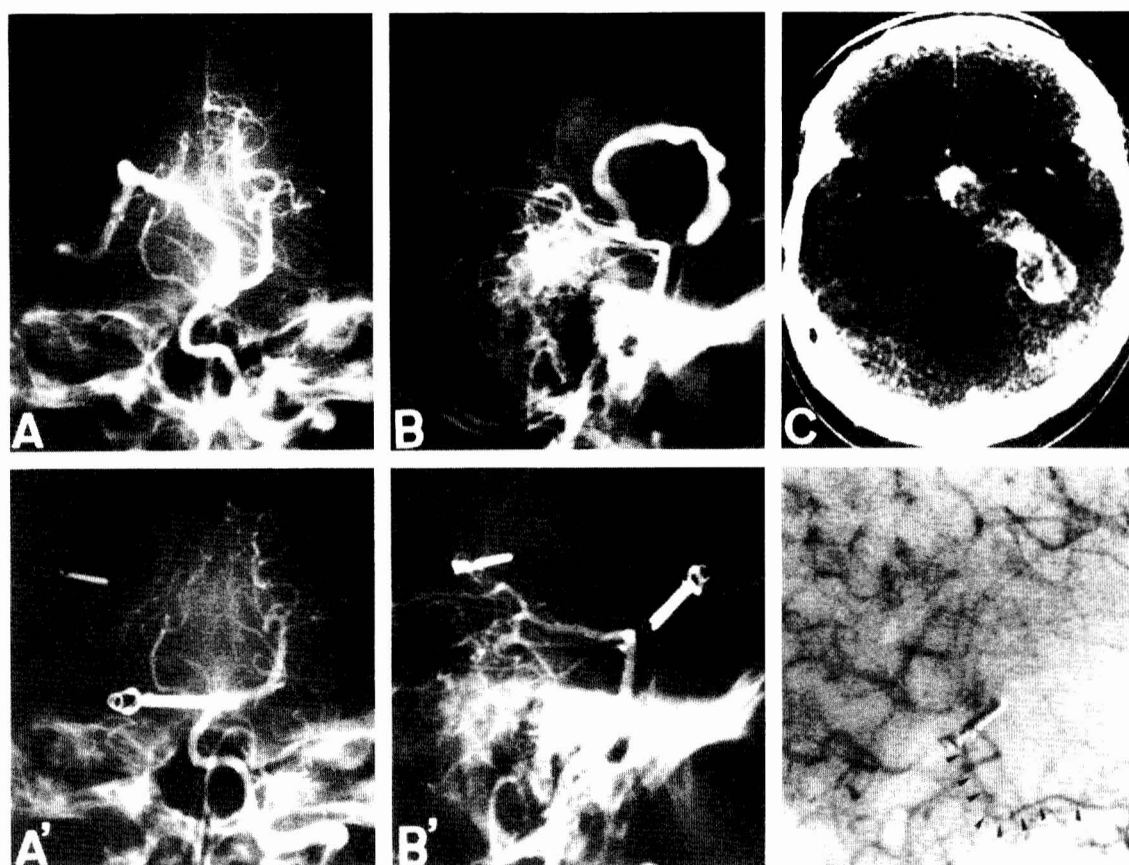


FIG. 5. Case 9. *A* and *B*: Preoperative vertebral angiograms showing an irregular vascular channel originating from the P_1 segment of the right PCA. Anteroposterior (*A*) and lateral (*B*) views. *A'* and *B'*: Postoperative vertebral angiograms, anteroposterior (*A'*) and lateral (*B'*) views. The aneurysm is completely occluded from the circulation. *C*: Preoperative CT scan with contrast enhancement showing a large enhanced mass extending from the suprasellar cistern into the right temporoparietal region. *C'*: Postoperative right common carotid angiogram, lateral view. Anastomosed STA (arrowheads) showing minimal blood supply to the distal PCA.

TABLE 2
PCA Aneurysms Treated with Trapping or Proximal Ligation

Case	Author, Year	No. Cases	Operation	Postoperative Deficits	Results
1	Hanafee & Jannetta, 1966	1	Trapping	None	Excellent
2	Hunt & Hess, 1966	1	Trapping	Dysphasia, Hemiparesis, Hemihypesthesia	Full recovery
3	Obrador et al., 1967	1	Proximal clipping	Hemiparesis, astereognosis	?
4	Drake, 1969	1	Trapping		Death (intraoperative rupture)
5	Kondo et al., 1978	1	Proximal clipping	Diplopia	Full recovery
6	Ventureyra et al., 1980	1	Resection	None	Excellent
7	Little et al., 1981	1	Excision	Hemiparesis, homonymous hemianopsia	Persistent deficits
8	Amacher et al., 1981	7	6 proximal clippings, 1 resection	None	Excellent
9	Sundt, 1982	1	Excision & revascularization	3rd nerve palsy	Full recovery
10	Yeşargil, 1984	6	5 trappings, 1 proximal clipping	Increased preoperative deficits or no change	5 full recoveries, 1 improvement
11	Chang et al., 1986	4	Trapping (revascularization in 2 cases)	Dysphasia, hemiparesis, hemihypesthesia, homonymous hemianopsia	3 full recoveries, 1 persistent deficits

revascularization, there are some risks for postoperative ischemic complications. We think that PCA revascularization, if the anastomosis can be safely performed without additional operative risk, should be used when treating unclippable aneurysms in this territory.

Received for publication, April 8, 1986; accepted, July 6, 1986.

Reprint requests: Han Soo Chang, M.D., Department of Neurological Surgery, Mitsui Memorial Hospital, 1 Kanda Izumicho, Chiyodaku, Tokyo, Japan 110.

REFERENCES

1. Amacher AL, Drake CG, Ferguson GG: Posterior circulation aneurysms in young people. *Neurosurgery* 8:314-320, 1981.
2. Ammerman BJ, Smith DR: Giant fusiform middle cerebral aneurysm: Successful treatment utilizing microvascular bypass. *Surg Neurol* 7:255-257, 1977.
3. Chang HS, Fukushima T, Miyazaki S, Tamagawa T: Fusiform posterior cerebral artery aneurysm treated with excision and end-to-end anastomosis: Case report. *J Neurosurg* 64:501-504, 1986.
4. Drake CG: The surgical treatment of vertebral-basilar aneurysms, in Sano K, Ishii S, Le Vay D (eds): *Recent Progress in Neurological Surgery: Proceedings of the Symposia of the Fifth International Congress of Neurological Surgery*. Amsterdam, Excerpta Medica, 1974, pp 183-190.
5. Drake CG, Amacher AL: Aneurysms of the posterior cerebral artery. *J Neurosurg* 30:468-474, 1969.
6. Fukamachi A, Hirato M, Wakao T, Kawafuchi J: Giant serpentine aneurysm of the posterior cerebral artery. *Neurosurgery* 11:271-276, 1982.
7. Hanafee W, Jannetta PJ: Aneurysm as a cause of stroke. *AJR* 98:647-652, 1966.
8. Hopkins LN, Budny JL, Castellani D: Extracranial-intracranial bypass and basilar artery ligation in the treatment of giant basilar artery aneurysms. *Neurosurgery* 13:189-194, 1983.
9. Hunt WE, Hess RM: Aneurysm of the posterior cerebral artery with unexpected postoperative neurological deficit: Case report. *J Neurosurg* 26:633-635, 1967.
10. Kondo T, Higashi H, Murakami T, Goto T, Sugawara T, Tsukubokawa T, Moriyasu N: A case of giant aneurysm at the posterior cerebral artery. *No Shinkei Geka* 6:907-911, 1978 (in Japanese).
11. Little JR, Louis PS, Weinstein M, Dohn DF: Giant fusiform aneurysm of the cerebral arteries. *Stroke* 12:183-188, 1981.
12. Locksley HB: Report of the Cooperative Study of Intracranial Aneurysms and Subarachnoid Hemorrhage: Section 5, Part 1. Natural history of subarachnoid hemorrhage, intracranial aneurysms and arteriovenous malformations based on 6368 cases in the Cooperative Study. *J Neurosurg* 26:413-416, 1966.
13. Obrador S, Dierssen G, Hernandez JR: Giant aneurysm of the posterior cerebral artery: Case report. *J Neurosurg* 26:413-416, 1967.
14. Peerless SJ, Ferguson GG, Drake CG: Extracranial-intracranial (EC/IC) bypass in the treatment of giant intracranial aneurysms. *Neurosurg Rev* 5:77-81, 1982.
15. Pia HW, Fontana H: Aneurysms of the posterior cerebral artery: Locations and clinical pictures. *Acta Neurochir (Wien)* 38:13-35, 1977.
16. Spetzler RF, Carter LP: Revascularization and aneurysm surgery: Current status. *Neurosurgery* 16:111-116, 1985.
17. Sundt TM Jr: Surgical technique for giant intracranial aneurysms. *Neurosurg Rev* 5:161-168, 1982.
18. Suzuki J, Hori S, Sakurai Y: Intracranial aneurysms in the neurosurgical clinics in Japan. *J Neurosurg* 35:34-39, 1971.
19. Ventureyra ECG, Choo SH, Benoit BG: Super giant globoid intracranial aneurysm in an infant. *J Neurosurg* 53:411-416, 1980.
20. Yaşargil MG: *Microneurosurgery*. Stuttgart, Georg Thieme Verlag, 1984, vol 2, pp 260-269.

COMMENTS

Dr. Chang and his colleagues report their experience over 15 years with the relatively unusual aneurysms involving the posterior cerebral arteries arising distal to the basilar bifurcation. Of note is that only half of these lesions were saccular, and that definitive clipping was possible in only two. The report emphasizes the controversial topic of trapping of large, giant, or fusiform posterior cerebral artery aneurysms. This technique was employed in four cases and a prophylactic revascularization procedure was performed in two. The two patients who were not so protected suffered significant ischemic complications.

Despite evidence previously reported in the literature of the relative safety of trapping the posterior cerebral artery, especially in children, to date no effective angiographic or neurophysiological criteria are available to assist the surgeon in preoperatively or intraoperatively predicting individual tolerance. Whereas youth and brisk retrograde bleeding after proximal clipping provide some degree of security, the seriousness of the potential deficits and the diminished autoregulatory capacity after subarachnoid hemorrhage make routine sacrifice of this vessel an unsettling practice. In our experience, although the distal posterior cerebral territory can be well supplied in many patients by the middle cerebral and the anterior cerebral watershed, the critical branches and perforators from the proximal P-1 and P-2 segments that may inadvertently be included in the trapped segment have essentially no collateral supply. The posterior thalamoperforates, thalamogeniculates, and peduncular perforating vessels must be clearly seen before decisions can be made about final clip placement. We wholeheartedly agree with the authors that the various possible revascularization techniques should be employed to protect the distal posterior cerebral territory when a trapping procedure is anticipated. We have been disappointed with the small volume of blood that can be furnished by the extremely distal superficial temporal when it is routed subtemporally into the ambient cistern. We prefer to use either a short saphenous vein graft from the proximal superficial temporal or a longer saphenous interposition graft from the cervical external carotid to guarantee adequate immediate perfusion.

Hunt Batjer, M.D.
Dallas, Texas

Chang and coworkers have reported on an unusually large series of posterior cerebral artery (PCA) aneurysms and given excellent recommendations on their treatment. I take issue with only two points. First, I do not believe they have demonstrated the value of performing a revascularization procedure when the aneurysm cannot be clipped. The performance of an end-to-end anastomosis seems to me to be a superior solution if it is technically feasible. Second, I take issue with their preference for the pterional approach to these lesions except for those involving the most proximal portion of the PCA. The PCA aneurysms that give the greatest difficulty are those on the more distal segment of the artery and these are best handled by the subtemporal approach. We have successfully clipped an aneurysm of the terminal trifurcation of the PCA at the posterior lateral margin of the brain stem by a subtemporal approach. Furthermore, only this approach can expose enough of the artery to permit an end-to-end anastomosis. Once again, I congratulate the authors on their wide experience with this unusual lesion.

Michael Salcman, M.D.
Baltimore, Maryland