

2. Heath PD, Nightingale S: Clusters of tonic spasms as an initial manifestation of multiple sclerosis. *Ann Neurol* 12: 494-495, 1982
3. Twomey JA, Espir MLE: Paroxysmal symptoms as the first manifestations of multiple sclerosis. *J Neurol Neurosurg Psychiatry* 43: 296-304, 1980
4. Matthews WB: Tonic seizures in disseminated sclerosis. *Brain* 81: 193-206, 1958
5. Joynt RJ, Green D: Tonic seizures as a manifestation of multiple sclerosis. *Arch Neurol* 6: 293-299, 1962
6. Matthews WB: Paroxysmal symptoms in multiple sclerosis. *J Neurol Neurosurg Psychiatry* 38: 617-623, 1975
7. Miley CE, Forster FM: Paroxysmal signs and symptoms in multiple sclerosis. *Neurology* 24: 458-461, 1974
8. Shibasaki H, Kuroiwa Y: Painful tonic seizure in multiple sclerosis. *Arch Neurol* 30: 47-51, 1974
9. Meyers R: Ballismus. In *Handbook of Clinical Neurology*, Vol. 6, Vinken PJ, Bruyn GW (eds). North-Holland Publishing Co., Amsterdam, 1968, pp. 476-490
10. Kase CS, Maalsby GO, DeJuan E, Mohr JP: Hemichorea-hemiballismus and lacunar infarction in the basal ganglia. *Neurology* 31: 452-455, 1981
11. Sandyk R: Hemichorea-hemiballismus caused by lacunar infarction in the basal ganglia. *S Afr Med J* 63: 739-740, 1983
12. Tabaton M, Mancardi G, Loeb C: Generalized chorea due to bilateral small, deep cerebral infarcts. *Neurology* 35: 588-589, 1985
13. Russo LS: Focal dystonia and lacunar infarction of the basal ganglia: a case report. *Arch Neurol* 40: 61-62, 1983
14. Watson CP, Chiu M: Painful tonic seizures in multiple sclerosis: localization of a lesion. *Can J Neurol Sci* 6: 359-361, 1979
15. Lance JW: Sporadic and familial varieties of tonic seizures. *J Neurol Neurosurg Psychiatry* 26: 51-59, 1963
16. Lance JW: Familial paroxysmal dystonic choreoathetosis and its differentiation from related syndromes. *Ann Neurol* 2: 285-293, 1977
17. Bresnihan B: CNS lupus. *Clin Rheum Dis* 8: 183-195, 1982
18. Johnson RT, Richardson EP: The neurological manifestations of systemic lupus erythematosus. *Medicine* 47: 337-369, 1968
19. Hart RG, Miller VT, Coull BM, Bril V: Cerebral infarction associated with lupus anticoagulants — preliminary report. *Stroke* 15: 114-118, 1984
20. Gonzalez-Scarano F, Lisak RP, Bilaniuk LT, Zimmerman RA, Atkins PC, Zweiman B: Cranial computed tomography in the diagnosis of systemic lupus erythematosus. *Ann Neurol* 5: 158-165, 1979
21. Hutchinson M, Bresnihan B: Neurological lupus erythematosus with tonic seizures simulating multiple sclerosis. *J Neurol Neurosurg Psychiatry* 46: 583-585, 1983

## Ophthalmoplegia with Contralateral Hemiplegia. Occlusion of the Internal Carotid Artery Due to Thrombosis of an Intracavernous Aneurysm

J.C. GAUTIER, M.D., A. AWADA, M.D., AND A. MAJDALANI, M.D.

**SUMMARY** A left ophthalmoplegia and right hemiplegia were due to thrombosis of an intracavernous aneurysm with occlusion of the left internal carotid artery. Ophthalmoplegia with contralateral hemiplegia is probably a rare syndrome. Thrombosis of and intracavernous aneurysm is probably a rare cause of occlusion of the internal carotid artery.

Stroke Vol 17, No 6, 1986

**OCCLUSIVE THROMBOSIS** of the internal carotid artery (ICA) secondary to thrombosis in an aneurysm of the intracavernous ICA (ICICA) is probably very rare. It is not mentioned in current textbooks.<sup>1-3</sup> We report one such case with a distinct clinical picture namely ipsilateral complete ophthalmoplegia with contralateral hemiplegia.

### Case Report

A 65 year-old right handed woman was found at home seated on a chair with a right-sided weakness and speech disorder. She was admitted 24 hours later, on June 30, 1985.

She was alert with a right hemiplegia and aphasia. There were no gross sensory or visual field defect. She had a left ptosis and complete extrinsic and intrinsic

paralysis of the left eye. There was no proptosis or chemosis. No bruit was heard over the neck and eyeballs. Cardiac examination was without significant abnormalities. BP:160/80.

Unenhanced CT scan 1 hour after admission showed a left prerolandic low density area and a high density area in the left cavernous sinus region. On the same day angiography showed occlusion of the left ICA approximately 3 cms after its origin (fig. 1). A second CT with contrast and slices 6 mms thick showed a rounded image highly suggestive of a thrombosed large (23 mms diameter) aneurysm of the left ICICA (fig. 2). There was in addition erosion of the anterior clinoid process and of the lateral wall of the ethmoidal sinus (fig. 1 and 2). On July 4, a right carotid angiography showed 2 small berry aneurysms, at the bifurcation respectively of the right ICA and right middle cerebral artery.

The hemiparesis partially improved. The ophthalmoplegia was still complete when the patient was discharged to a Rehabilitation Unit on August 5, 1985.

From the Department of Service d'Urgences Cerebrovasculaires, La Salpetriere, 75013 Paris, France.

Address correspondence to: Professor J.C. Gautier, Service d'Urgences Cerebrovasculaires, La Salpetriere, 75013 Paris, France.

Received April 3, 1986, accepted May 12, 1986.

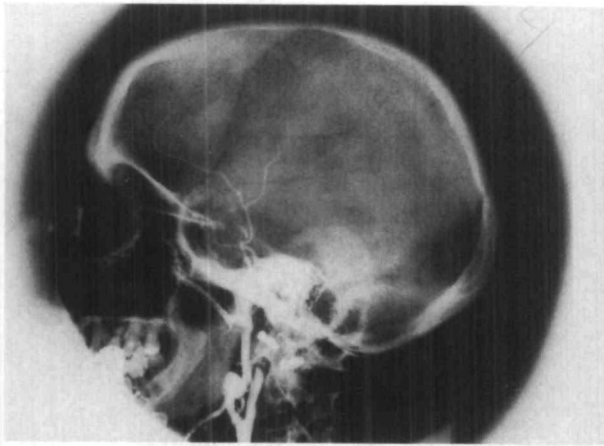


FIGURE 1. Occlusion of the left ICA 3 cms beyond its origin.

### Discussion

The aneurysm in this patient had a diameter of 2, 3 cms thus falling short of the definition of giant aneurysms (diameter higher than 2.5 cms).<sup>4</sup> To our knowledge only 1 similar case of occlusion of the ICA has been reported (Whittle et al.<sup>5</sup>) As in our patient the proximal edge of the thrombus occluding the ICA was well beyond the ICA origin, suggesting retrograde thrombosis. Whittle et al in the same year reported a series of 12 patients with thrombosis of giant intracranial aneurysms (2 mentioned as 'carotid cavernous').<sup>6</sup> It is not clear whether their case 4 is the same as that mentioned above. Nevertheless, in the reported cases, thrombosis of giant ICICA aneurysms resulted in ophthalmoplegia with proptosis and in one patient, facial dysesthesiae. In none of them was ipsilateral ophthalmoplegia with contralateral hemiplegia seen as in the patient reported here.

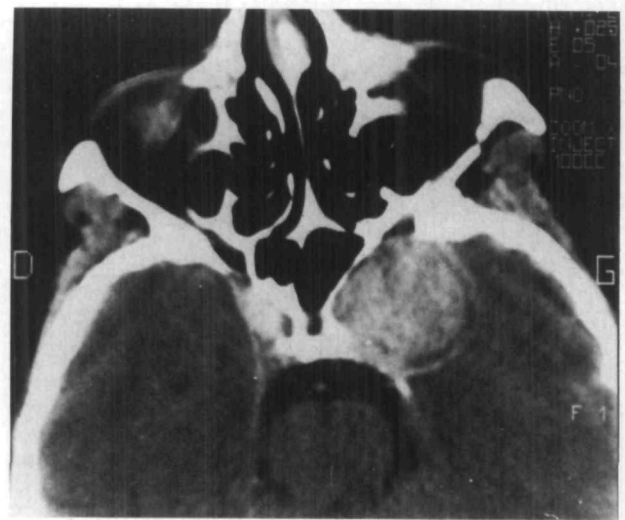

FIGURE 2. CT with contrast medium. Large thrombosed intracavernous aneurysm. Target image. Erosion of the anterior clinoid process and lateral wall of the ethmoidal sinus. G: left.

### References

1. Adams RD, Victor M: Cerebrovascular diseases. *In: Principles of Neurology*, New York: McGraw Hill Co, 1985
2. Ross Russell RW: Less common varieties of cerebral arterial disease. *In: Vascular Disease of the Central Nervous System*, RW Ross Russell ed. Edinburgh: Churchill Livingstone, 1983
3. Gautier JC, Mohr JP: Intracranial internal carotid artery disease. *In: Stroke: Pathophysiology, Diagnosis and Management*, Vol 1, HJM Barnett, JP Mohr, BM Stein, FM Yatsu eds. New York: Churchill Livingstone, 1986
4. Morley TP, Barr HWK: Giant intracranial aneurysms. Diagnosis, Course and Management. *Clin Neurosurg* 16: 73-94, 1969
5. Whittle IR, Williams DB, Halmagyi GM, Besser M: Spontaneous thrombosis of a giant intracranial aneurysm and ipsilateral carotid artery. *J Neurosurg* 56: 287-289, 1982
6. Whittle IR, Dorsh NW, Besser M: Spontaneous thrombosis in giant intracranial aneurysms. *J Neurol Neurosurg Psychiatr* 45: 1040-1047, 1982