

# Teaching NeuroImage: Unilateral Primary Angiitis of the CNS

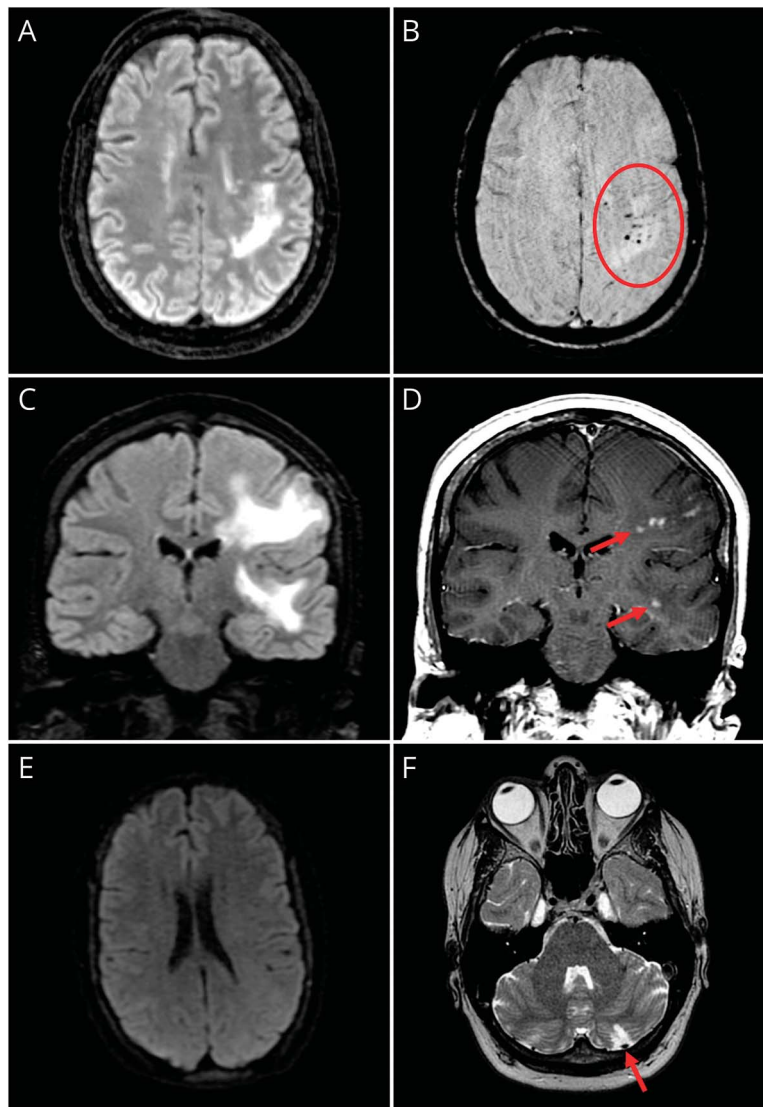
Samir Alkabie, MD, Madison T. Gray, MD, Jonathan C. Lau, MD, Lillian Barra, MD, Jennifer Mandzia, MD, Qi Zhang, MBBS, and Adrian Budhram, MD

*Neurology*® 2024;102:e208018. doi:10.1212/WNL.0000000000208018

## Correspondence

Dr. Budhram  
adrian.budhram@lhsc.on.ca

**Figure 1** Imaging Findings in Unilateral PACNS



Prebiopsy brain MRI shows left hemispheric T2-FLAIR hyperintensity (A) with microhemorrhage (B, circle). Brain MRI 7 years prior also shows left hemispheric T2-FLAIR hyperintensity (C), reflecting long-standing disease. Patchy enhancement is seen (D, arrows). No diffusion restriction is seen (E), but a left cerebellar infarct is identified (F, arrow). FLAIR = fluid-attenuated inversion recovery; PACNS = primary angiitis of the CNS.

## MORE ONLINE

For multiple-choice questions relevant to Teaching NeuroImages and Teaching Video NeuroImages, find @greenjournal on Twitter using the hashtag #NeurologyRF

From the Departments of Clinical Neurological Sciences (S.A., J.C.L., J.M., Q.Z., A.B.) and Pathology and Laboratory Medicine (M.T.G., Q.Z., A.B.), Western University, London Health Sciences Centre; and Division of Rheumatology, Department of Medicine (L.B.), Western University, St. Joseph's Health Care, London, Ontario, Canada.

Go to [Neurology.org/N](https://www.neurology.org/N) for full disclosures. Funding information and disclosures deemed relevant by the authors, if any, are provided at the end of the article.

Copyright © 2023 American Academy of Neurology

Copyright © 2023 American Academy of Neurology. Unauthorized reproduction of this article is prohibited.

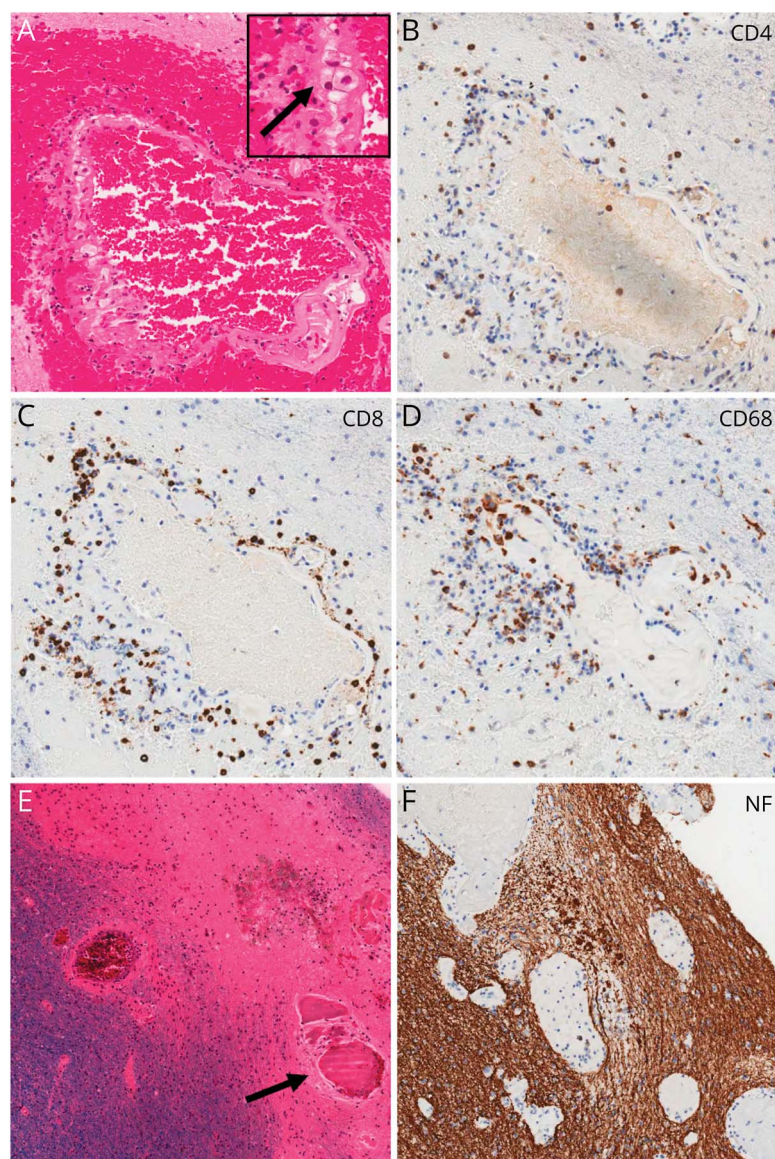
A 48-year-old woman was referred with an 18-year history of focal-onset seizures. She also reported years-long slowly progressive right-sided weakness that was corroborated on examination. Repeated brain MRIs over 15 years showed multifocal left hemispheric T2 fluid-attenuated inversion recovery-hyperintense lesions with patchy enhancement and microhemorrhages, no diffusion restriction, and a left cerebellar infarct (Figure 1, A–F). Only 2 nonspecific white matter lesions were seen contralaterally, indicating largely unihemispheric disease. Differential diagnosis included unilateral primary angiitis of the CNS (PACNS), Rasmussen encephalitis, and myelin oligodendrocyte glycoprotein antibody-associated disease.<sup>1</sup> Serum and CSF testing for autoimmune, infectious, and malignant etiologies and whole-body fluorodeoxyglucose-PET, whole-exome genetic sequencing, and MR vessel-wall imaging were nondiagnostic. Brain biopsy revealed vasculitis (Figure 2, A–F), and the patient was diagnosed

with unilateral PACNS. Treatment with mycophenolate mofetil has been initiated. Unilateral PACNS is a rare unihemispheric disease characterized by an indolent course and seizures, recognition of which is critical to accurate diagnosis.<sup>1,2</sup>

### Contributions

S. Alkabe: drafting/revision of the manuscript for content, including medical writing for content; major role in the acquisition of data; study concept or design; analysis or interpretation of data. M.T. Gray: drafting/revision of the manuscript for content, including medical writing for content; major role in the acquisition of data; study concept or design; analysis or interpretation of data. J.C. Lau: drafting/revision of the manuscript for content, including medical writing for content; major role in the acquisition of data; analysis or interpretation of data. L. Barra: drafting/revision of the

**Figure 2** Pathologic Findings in Unilateral PACNS



Micrograph of a single white matter vessel (A) demonstrates intramural fibrinoid necrosis with perivascular haemorrhage and transmural inflammation mediated by CD4 (B) and CD8 (C) T-lymphocytes and CD68-positive histiocytes (D and inset A, arrow). Luxol fast blue/H&E (E) and neurofilament (F) staining show loss of myelinated axons and vascular thrombosis (E, arrow). Image magnifications: 10× (A–D) and 20× (E and F). PACNS = primary angiitis of the CNS.

manuscript for content, including medical writing for content; analysis or interpretation of data. J. Mandzia: drafting/revision of the manuscript for content, including medical writing for content; analysis or interpretation of data. Q. Zhang: drafting/revision of the manuscript for content, including medical writing for content; major role in the acquisition of data; analysis or interpretation of data. A. Budhram: drafting/revision of the manuscript for content, including medical writing for content; major role in the acquisition of data; study concept or design; analysis or interpretation of data.

### Study Funding

The authors report no targeted funding.

### Disclosure

S. Alkabie, M. Gray, J. Lau, L. Barra, J. Mandzia, and Q. Zhang report no disclosures relevant to the manuscript; A. Budhram

holds the London Health Sciences Centre and London Health Sciences Foundation Chair in Neural Antibody Testing for Neuro-Inflammatory Diseases, and receives support from the Opportunities Fund of the Academic Health Sciences Centre Alternative Funding Plan of the Academic Medical Organization of Southwestern Ontario (AMOSO).

### Publication History

Received by *Neurology* July 26, 2023. Accepted in final form September 27, 2023. Submitted and externally peer reviewed. The handling editor was Resident & Fellow Section Editor Whitley Aamodt, MD, MPH.

### References

1. AbdelRazek MA, Hillis JM, Guo Y, et al. Unilateral relapsing primary angitis of the CNS: an entity suggesting differences in the immune response between the cerebral hemispheres. *Neurol Neuroimmunol Neuroinflamm*. 2021;8(2):e936.
2. Santyr B, Pejhan S, Zhang Q, Budhram A. Unilateral primary angitis of the central nervous system. *Ann Neurol*. 2021;90:999-1000.

---

## Infographics Available on Select Articles

Infographics are an exciting feature available across the *Neurology*<sup>®</sup> journals, providing an engaging and convenient way to understand the information presented in select articles. All infographics are created by a team of scientific writers and illustrators and undergo a rigorous review process involving input and feedback from the author and *Neurology* editors. View a selection of infographics at: [Neurology.org/Infographics](https://www.neurology.org/Infographics)

---

---


## Visit the *Neurology*<sup>®</sup> Resident & Fellow Website

Click on Residents & Fellows tab at [Neurology.org](https://www.neurology.org).

Now offering:

- *Neurology* Resident & Fellow Editorial team information
- “Search by subcategory” option
- E-Pearl of the Week
- Direct links to Career Planning and AAN Resident & Fellow Pages
- Recently published Resident & Fellow articles
- Commentaries by Editors and Resident & Fellow team members

 Find *Neurology* Residents & Fellows Section on Facebook: [facebook.com/AANResidentsAndFellows](https://facebook.com/AANResidentsAndFellows)

 Follow *Neurology* on X: @GreenJournal #NeurologyRF

 Find *Neurology* Residents & Fellows Section on Instagram: @aanbrain #NeurologyRF

---