

Posterior Cerebral Artery Stenosis

Michael S. Pessin, MD,* Eddie S. Kwan, MD,† L. Dana DeWitt, MD,* Thomas R. Hedges III, MD,‡
Daniel Gale, MD,† and Louis R. Caplan, MD*

We analyzed the clinical features of symptomatic posterior cerebral artery (PCA) stenosis in 6 patients selected from 15 patients with angiographically documented PCA atherosclerosis occurring during a 7-year period. Transient ischemic attacks (TIAs) were the major presentation in 5 patients. A homonymous visual field defect was present in 2 patients. TIA symptoms were predominantly visual or sensory, or both. The most common visual symptom was difficulty seeing to one side. One patient saw flashing lights. Sensory spells were always paresthetic, usually involving the arm and hand and occasionally the face and leg. Three patients had visual and sensory spells together. Two patients with a visual field defect had calcarine infarcts found by computed tomography. All patients were treated with warfarin. During follow-up (4 months to 4 years), no patient had a new stroke in the PCA territory, and only one continued to have TIAs. PCA atherosclerosis is rarer than PCA embolic occlusion. In contrast to those with PCA embolism, our patients with PCA atherosclerosis had more TIAs and fewer infarcts. The clinical features of PCA stenosis—preponderance of visual and sensory TIAs—distinguish this vascular lesion from stenosis of the middle cerebral artery.

Pessin MS, Kwan ES, DeWitt LD, Hedges TR III, Gale D, Caplan LR:
Posterior cerebral artery stenosis. *Ann Neurol* 21:85–89, 1987

Infarction in the posterior cerebral artery (PCA) territory is commonly caused by embolism, either cardio-genic or from a more proximal vertebrobasilar intra-arterial or unknown source [1, 4, 7, 9]. In contrast, PCA atherosclerosis is an uncommon lesion [1, 9] whose clinical course and angiographic features have not been reported. To clarify the clinical features of PCA stenosis, we retrospectively analyzed 6 symptomatic patients with PCA atherosclerosis and compared them to our previous series [9] of patients with PCA embolism.

Methods

Patients were selected by reviewing the angiographic log book for the 7-year period, 1978 through 1985. Fifteen patients with atheromatous PCA stenosis were identified, but review of the medical records showed that only 6 had related symptoms. We report the clinical and angiographic features in these 6 patients. Patients with a recognized cardiac embolic source were excluded.

All angiograms were performed through the transfemoral route and were reviewed in detail by a neuroradiologist (E. S. K.). Information noted included the degree of PCA stenosis as measured directly from the angiogram and compared to an adjacent section of normal artery; the location and extent of the stenosis; associated stenosis in the vertebrobasilar circulation; and any hemodynamic effects evidenced by slow flow through the stenotic region or shifts in the collateral vessels of the adjacent border zone. Computed tomographic (CT) scans were reviewed in all patients

for areas of infarct in the PCA territory as well as in the brainstem and cerebellum.

All patients were examined by one of the authors, and the medical records were reviewed in detail for all pertinent information. Neuroophthalmological examination was carried out in 4 of the patients.

Results

Angiographic and CT Findings

The angiographic and CT data are presented in Table 1. Five patients had unilateral symptomatic PCA stenosis and 1 patient had bilateral disease. Based on anatomical segments of the PCA described by Margolis and co-workers [8], the stenosis affected the more proximal (perimesencephalic) portion of the PCA in all patients. In the 5 patients with unilateral PCA disease, the site of stenosis was the peduncular segment in 2, ambient segment in 2, and quadrigeminal segment in 1. The patient with bilateral symptomatic PCA stenoses had involvement of the peduncular and ambient segments. There were single areas of stenosis in 4 patients and multiple areas in 2. The length of stenotic areas varied from 2 to 5 mm. The degree of stenosis ranged from 50 to 80%. Antegrade flow through stenoses was present in all patients and there was no angiographic evidence of slowing or other hemodynamic effects. Intraluminal thrombus or distal embolization was not present. In 4 patients, both PCAs arose from the basilar artery, and in the 2 other

From the Departments of *Neurology, †Radiology, and ‡Ophthalmology, Tufts–New England Medical Center, Boston, MA.

Received May 12, 1986. Accepted for publication June 18, 1986.

Address reprint requests to Dr Pessin, Department of Neurology, Tufts–New England Medical Center, 171 Harrison Ave, Boston, MA 02111.

Table 1. Angiographic and Computed Tomographic Findings in 6 Patients with Posterior Cerebral Artery Stenosis

Patient No.	Site of Stenosis	Percent Stenosis	CT Findings ^a	Other Lesions
1	Peduncular segment	80	Negative	...
2	Quadrigeminal segment	63	Calcarine infarct	...
3	Peduncular segment	50	Negative	Left ICA occlusion
4	Ambient segment	75	Calcarine infarct	Left MCA stenosis, right calcarine branch stenosis
5	Ambient segment	80	Negative	Diffuse VB atheroma, asymptomatic right PCA stenosis
6 ^b	Left ambient segment	72	Negative	...
	Right peduncular segment	50

^aCT findings in symptomatic PCA territory only.

^bBilateral symptomatic PCA stenoses.

CT = computed tomography; VB = vertebrobasilar; ICA = internal carotid artery; MCA = middle cerebral artery; PCA = posterior cerebral artery.

patients one PCA arose from the internal carotid artery and one from the basilar artery. Associated lesions included diffuse atheromatous changes in the vertebrobasilar system in 1 patient, including severe asymptomatic PCA stenosis; stenosis of the middle cerebral artery (MCA) and calcarine artery branch in 1, and occlusion of the internal carotid artery in 1.

CT scans showed calcarine infarcts corresponding to the symptomatic PCA in 2 patients, and a calcarine infarct in the territory of an asymptomatic PCA stenosis in 1 other patient. One patient had a small cerebel-

lar infarct, one had a thalamic lacuna, and one had bilateral capsular lacunae.

Clinical Features

Table 2 presents the clinical findings. There were 5 men and 1 woman, ranging in age from 63 to 79 years. Hypertension was present in 2 patients and one also had diabetes mellitus. One patient had mitral valve prolapse and another had coronary artery disease. The left PCA was symptomatic in 3 patients, the right in 2,

Table 2. Clinical Features in 6 Patients with Posterior Cerebral Artery Stenosis

Patient No.	Sex, Age (yr)	Number and Nature of TIAs	Stroke Features	Treatment and Follow-up
1	M, 68	Two over 2 mo; in one, black loss of vision to right, clumsy involuntary movements in right arm, and garbled speech, 2-3 hrs; right hand weakness	None	Asymptomatic on warfarin for 4 mo; then death from intracranial hematoma after head injury
2	M, 79	None	Left hemianopia	Asymptomatic on warfarin for 14 mo
3	M, 64	Many over 6 wk; loss of vision to right, pins-needles in right fingers moving up arm with occasional speech difficulty, 2 min	None	TIAs continued on warfarin for 4 mo
4	M, 69	Three over 4 mo; loss of vision to left, once tingling left hand-face; a few min to 45 min	Left superior quadrantanopia	Asymptomatic on warfarin for 4 yr, then death due to left hemisphere infarction
5	M, 63	Many over 2 mo; tingling, pins-needles in right cheek, arm-hand, occasionally leg, 5 min	None (old left hemiparesis)	Asymptomatic on warfarin for 5 mo
6	F, 78	Four over 9 mo; bilateral visual loss or flashing lights-gray vision, gray loss of vision to right, bright red-white lights, sometimes leg numbness and lightheadedness, 10 min	None	One episode left visual blurring on warfarin, died at 9 mo

TIA = transient ischemic attack; M = male; F = female.

and one had bilateral symptoms localized to both PCA territories.

The presenting problem in 5 patients were PCA territory transient ischemic attacks; the 1 remaining patient had an established homonymous hemianopia without warning TIAs. One of the patients with TIAs (no. 4) had a left superior quadrantanopia on Goldmann perimetry. The 2 patients with homonymous visual field deficits both had appropriate calcarine infarcts shown by CT.

The TIAs were brief and multiple. Three patients had two, three, and four TIAs, respectively, and 2 patients had "many" over 6 weeks to 9 months. TIAs lasted 2 to 10 minutes, the longest 2 to 3 hours. Four of the 5 patients with TIAs had visual symptoms as part of their attacks. The features included visual loss to one side, sometimes described as black or gray. One patient with bilateral PCA stenoses experienced unilateral or bilateral visual symptoms of flashing lights, red-white lights, or gray vision. All patients with visual spells also had other simultaneous symptoms, including clumsiness and involuntary movements of an arm, migrating pins and needles sensations in the arm and hand with speech difficulty, tingling of the face and hand, and lightheadedness with leg numbness. One patient had only sensory TIAs consisting of tingling and pins and needles sensation of the cheek, arm, hand, and occasionally the leg.

Treatment and Follow-up

All patients were treated with warfarin and followed from 4 months to 4 years (Table 2). While taking warfarin, 4 patients remained asymptomatic, one (no. 3) continued to have TIAs, and one (no. 6) had only one TIA during a 9-month follow-up period. No patient had a new infarction in the PCA territory. Three patients died while being treated with warfarin with prothrombin times that showed therapeutic levels; one had an intracranial hematoma after head injury, one died of a new infarction in the left hemisphere (MCA territory), and one was found dead with no cause determined.

Patient Histories

The following patient histories illustrate the typical clinical course.

Patient 1

A 68-year-old man had two TIAs over a 2-month period. While giving a sermon, he felt weak and lost vision to the right side as if something had blackened it out. His right arm became clumsy, with involuntary movements, and his speech was garbled. The attack lasted 2 to 3 hours. On another occasion he had weakness of his right hand. Neurological findings were normal. Bilateral carotid and left vertebral artery angiography demonstrated severe stenosis of the proxi-

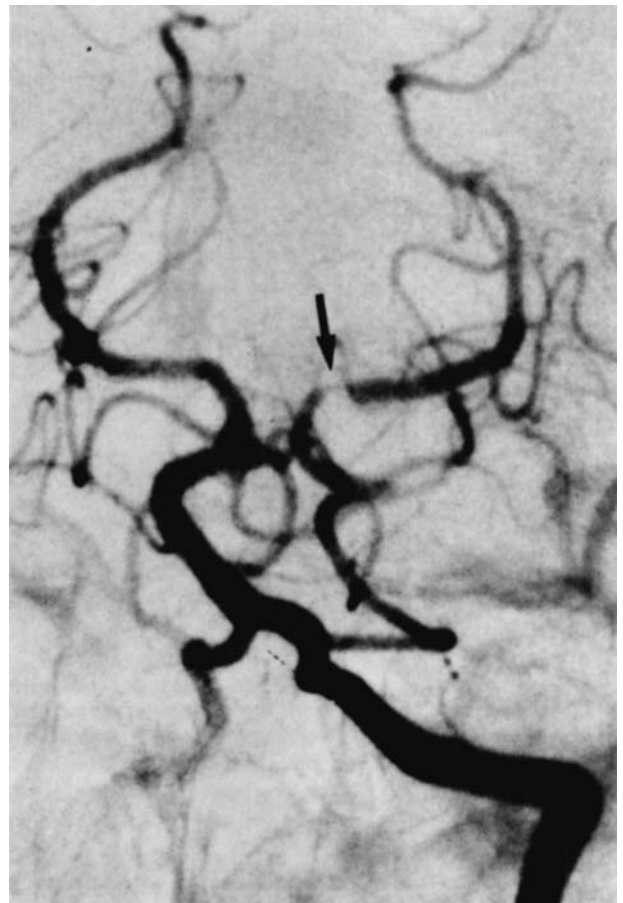

Fig 1. Anteroposterior view of a selective left vertebral angiogram with simultaneous compression of the left carotid artery. There is a high-grade stenosis (arrow) in the proximal left posterior cerebral artery just distal to its junction with the left posterior communicating artery. Compression of left carotid artery eliminated the possibility of flow artifact created by non-opacified blood from the anterior circulation.

mal portion of the left PCA, just distal to the posterior communicating artery (Fig 1). Both carotid bifurcations had only mild atheroma.

Neuroophthalmological findings were normal. Routine laboratory studies yielded normal results, including complete blood count, platelet count, electrocardiogram, and echocardiogram. The patient remained symptom free for 4 months while taking warfarin. One night he fell in the bathroom, striking his head on the bathtub. On the way to the hospital he lost consciousness and died in 6 hours. Postmortem examination showed a parenchymatous hemorrhage in the right hemisphere.

Patient 3

A 64-year-old man had many TIAs over a 6-week period. The attacks usually consisted of a 2-minute episode of loss of vision to the right side, pins and needles sensation of the right fingers that moved up the arm, occasionally accompanied by speaking difficulty and weakness of the right arm.

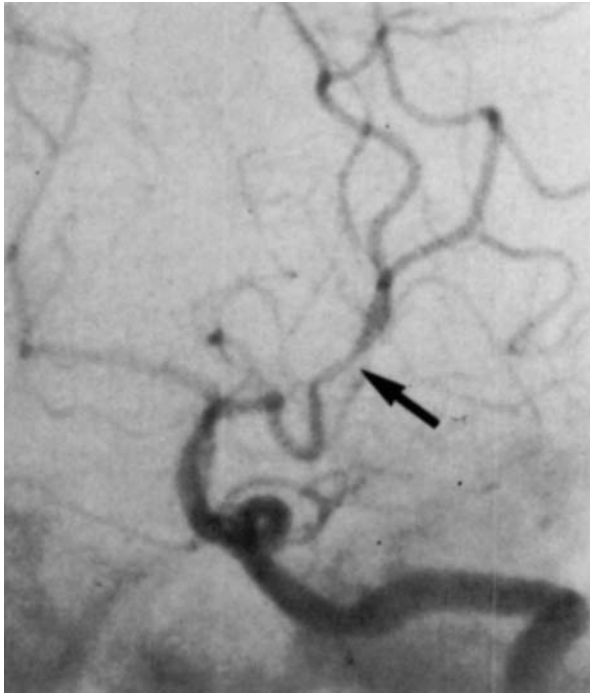

Fig 2. Anteroposterior view of a left subclavian angiogram. Moderate stenosis is identified at the junction of the peduncular and ambient segments of the posterior cerebral artery (arrow).

He had a history of hypertension, mild renal insufficiency, and peripheral vascular disease.

Neurological findings were normal. Bilateral carotid and left vertebral artery angiography demonstrated occlusion of the left internal carotid artery at its origin, with a normal right carotid system. Stenosis was present at the proximal left PCA (Fig 2). Routine laboratory findings were normal except for a blood urea nitrogen level of 53 mg/dl and a creatinine concentration of 1.6 mg/dl. The patient was started on warfarin therapy but his TIAs continued during a 4-month follow-up.

Patient 4

A 69-year-old man had three TIAs during a 4-month period. His attacks were stereotyped and consisted of visual loss to the left side, lasting a few minutes to 45 minutes. During one of these episodes he also noted tingling of the left hand and face. His past history was noteworthy for peripheral vascular disease. Neurological examination revealed only a left superior quadrantanopia on Goldmann perimetry. Bilateral carotid and a left brachial angiogram demonstrated that the right PCA filled from the carotid injection and showed several areas of irregular stenosis (Fig 3). Minor atheroma of the carotid bifurcation was present. CT showed a right occipital enhancing infarct. Routine laboratory studies including an electrocardiogram were normal. Warfarin therapy was begun and the patient remained asymptomatic during a 4-year follow-up. He then died of a new infarction in the left hemisphere while he was still taking warfarin.

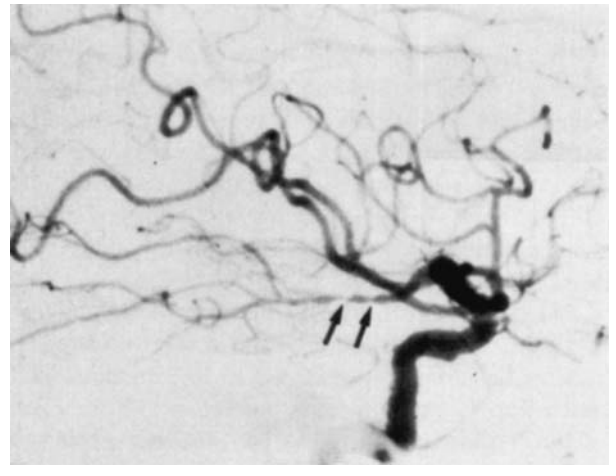


Fig 3. Lateral view of a right common carotid angiogram demonstrates a long irregular beaded appearance in the ambient segment of the right posterior cerebral artery (double arrows).

Discussion

PCA atheromatous stenosis, like MCA stenosis, is an uncommon vascular lesion, given that we identified only 15 patients in a 7-year angiographic review. During the same approximate time, we identified 80 patients and reported on 35 with presumed embolism of the PCA territory [9]. Among 22 patients with necropsy-proved disease of the PCA main stem or branch, only 2 had atherothrombotic occlusion [1]. Other studies [1, 4, 7] have corroborated that embolism, either cardiac or local, is the major mechanism in ischemia and infarction of the PCA territory. We could not find other reports that systematically analyzed angiographically proved PCA stenosis. The small number of patients in the present study may reflect in part our predominantly white patient population; intracranial vertebrobasilar atheroocclusive disease may be more common in blacks [5].

The proximal portion (perimesencephalic segments) of the PCA was the major site of stenosis, as shown by angiography—a finding similar to the stenosis found in MCA disease affecting the main stem. Hemodynamic changes and the distal effects of embolism are the presumed mechanisms for production of symptoms, although we were unable to document their presence on angiography.

TIAs were the major presentation in 5 of our patients. TIA features were distinctive, with visual symptoms predominant, often associated with sensory complaints. These features help distinguish PCA territory TIAs from those associated with MCA stenosis, in which motor and speech disturbances are common and visual symptoms absent [6]. The TIAs were often multiple and stereotyped, features consistent with an

atherothrombotic–hemodynamic mechanism. The simultaneous occurrence of 2 or more TIA symptoms was the rule. In contrast, only 3 of 35 previously reported patients with presumed embolism of the PCA territory had warning TIAs [9], and all had infarcts of the PCA territory, most of sudden onset.

At first glance, the visual and sensory TIA features in our patients with PCA stenosis resemble migrainous accompaniments. However, absence of headache, lack of a build-up in the visual disturbance, and absence of gradual progression or transition from one symptom to another help distinguish TIAs originating in the PCA territory from migrainous events [2, 3].

All of our patients were treated with warfarin, but the small numbers and lack of controls preclude endorsement of any specific therapy. During follow-up, no patient had further infarction in the territory of the PCA stenosis, yet 3 patients fared poorly, dying of other causes. Recognition of the clinical features of PCA stenosis may help identify more patients with this condition and lead to appropriate study of various medical treatments.

References

1. Castaigne P, L'Hermitte F, Gautier JC, et al: Arterial occlusions in the vertebro-basilar system. A study of 44 patients with post-mortem data. *Brain* 96:113–154, 1973
2. Fisher CM: Migraine accompaniments versus arteriosclerotic ischemia. *Trans Am Neurol Assoc* 93:211–213, 1968
3. Fisher CM: Late-life migraine accompaniments as a cause of unexplained transient ischemic attacks. *Can J Neurol Sci* 7:9–17, 1980
4. Fisher CM, Karnes WE: Local embolism. *J Neuropathol Exp Neurol* 24:174, 1965
5. Gorelick PB, Caplan LR, Hier DB, et al: Racial differences in the distribution of posterior circulation occlusive disease. *Stroke* 16:785–790, 1985
6. Hinton RC, Mohr JP, Ackerman RH, et al: Symptomatic middle cerebral artery stenosis. *Ann Neurol* 5:152–157, 1979
7. Koroshetz WJ, Ropper AH: Local embolism as a cause of stroke in the posterior circulation. *Neurology* 35(suppl 1):214, 1985
8. Margolis MT, Newton TH, Hoyt WF: The posterior cerebral artery: Part II. Gross and roentgenologic anatomy. In Smith JL (ed): *Neuro-Ophthalmology Symposium of University of Miami and the Bascom Palmer Eye Institute*. Hollandale, FL, Huffman, 1970, pp 161–192
9. Pessin MS, Lathi ES, Cohen MB, et al: Clinical features and mechanism of occipital infarction in the posterior cerebral artery territory. *Ann Neurol* 18:123, 1985