

Global Aphasia Without Hemiparesis

Daniel Tranel, PhD; José Biller, MD; Hanna Damasio, MD;
Harold P. Adams, Jr, MD; Steven H. Cornell, MD

● Three patients acutely developed global aphasia, but did not manifest the typical accompanying right hemiparesis. Computed tomography and magnetic resonance imaging studies demonstrated that the patients had two discrete left hemisphere lesions, one in the anterior language cortices or language-related subcortical areas, and one in the posterior language cortices. Cerebral angiography showed that two patients had complete occlusion of the left internal carotid artery, and the third had an intraluminal "clot" in the supraclinoid portion of the left internal carotid, findings suggestive of an embolic etiology. Our cases indicate that global aphasia without hemiparesis predicts two discrete lesions and a particularly good recovery of speech and language.

(*Arch Neurol* 1987;44:304-308)

Global aphasia is characterized by severe impairment of speech production, auditory comprehension, and repetition. Hemiplegia is considered to be an almost constant component of the clinical presentation.¹ The presence of global aphasia is indicative of a large lesion in the left perisylvian and basal ganglia regions, an assumption supported by most studies for which anatomical data are available. Furthermore, the severity of global aphasia and the size of lesion in these

locations are strongly associated.^{2,5} Recently, however, it has been noted that global aphasia can be associated with large lesions confined to prero-landic language areas.^{6,8} Finally, global aphasia may even result from two discrete lesions, one affecting the anterior and the other involving the posterior left language areas.^{9,10} Van Horn and Hawes¹⁰ described three patients who developed global aphasia without hemiparesis, and suggested that this presentation was indicative of "embolic encephalopathy." We recently studied three patients who acutely developed global aphasia without hemiparesis as a result of cerebral infarctions. These patients were examined in both acute and chronic stages. Our findings support the conclusions that global aphasia without hemiparesis predicts two discrete left hemisphere lesions; predicts an unusually good recovery of speech and language; and may be an indicator of an embolic etiology.

PATIENTS AND METHODS

We evaluated three patients who, as a result of cerebral infarctions, developed global aphasia without hemiparesis. Two patients had computed tomography (CT) and neuropsychologic evaluation both in the acute phase (within 14 days of onset), and in the chronic phase (between three and ten months after onset), and the third patient received these studies acutely and again five weeks after onset. Magnetic resonance imaging (MRI) was also obtained for all patients. Cerebral angiography was performed during the acute phase of the illness.

Computed tomography was obtained with a fourth generation scanner (Picker 1200 Sinerview). Transverse slices of 8 mm thickness were obtained. Magnetic resonance imaging was obtained using a scanner (Picker 0.5 Tesla Superconducting Magnetic Resonance Scanner). Anatomical

localization was obtained by analysis of CT and MRI according to the standard procedures of the Division of Behavioral Neurology's Neuroimaging Laboratory, University of Iowa, Iowa City. Patient identification in the films was masked. Investigators blind to the patients' behavioral status selected the appropriate template system for plotting the abnormal images and charted the position of those images on a standard template protocol.¹¹ A transparency containing the boundaries of neural units of interest, in both gray- and white-matter structures, was then superimposed on the chart. Damage was assigned to the units that contained the abnormal images.

A complete neuropsychologic evaluation included assessment of intellectual functioning (Wechsler Adult Intelligence Scale—Revised), verbal and visual memory, perception, and orientation. Testing was conducted over several short sessions, commensurate with the patients' ability to cooperate and attend. Some tests were omitted or truncated, as necessitated by the patients' condition. Speech and language were assessed with the Multilingual Aphasia Examination¹² and the Boston Diagnostic Aphasia Examination.¹³ Emphasis was placed on the most salient parameters of speech and language, including fluency, articulation, naming, repetition, comprehension, and reading and writing.

REPORT OF CASES

CASE 1.—After an evening of heavy alcohol consumption and subsequent vomiting, a 37-year-old right-handed man suddenly became unable to speak, except for saying "yes" and "goddamn." He complained of "numbness" of the right side of the face. Neurologic examination showed a discrete right facial weakness and a minimal right pronator drift (both of which resolved completely by the third day after onset). Strength was otherwise normal. Tendon reflexes were slightly brisker in the right upper extremity. Plantar responses were normal. Computed tomography showed

Accepted for publication Oct 20, 1986.

From the Departments of Neurology, Divisions of Behavioral Neurology (Drs Tranel and Damasio) and Cerebrovascular Diseases (Drs Biller and Adams), and Radiology, Section of Neuroradiology (Dr Cornell), University of Iowa, Iowa City.

Reprint requests to Department of Neurology, University of Iowa Hospitals and Clinics, Iowa City, Iowa 52242 (Dr Tranel).

asymmetry of the lateral ventricles, but no focal area of abnormal attenuation was seen. Angiography demonstrated an intraluminal filling defect in the supraclinoid portion of the left internal carotid artery.

During the next three days, the patient was noted to utter only a few poorly articulated words. Comprehension of conversational speech was restricted to very simple commands. He could not name, repeat, read, or write. Six days after onset, CT with contrast enhancement showed two well-defined areas of infarction in the left hemisphere, one anterior (frontal lobe) and one posterior (parietal lobe). The anterior lesion involved the most superior part of the frontal operculum (area 44), and extended into the premotor region immediately above (area 6). The posterior lesion involved part of the supramarginal gyrus (area 40), as well as the inferior part of the superior parietal lobule (areas 7 and 5). It extended inferiorly to involve the most posterior portion of the superior temporal gyrus (posterior area 22).

Comprehensive neuropsychologic evaluation was completed within two weeks of the ictus. The patient continued to have severely nonfluent speech. He had virtually no spontaneous speech production. In response to questions, he attempted to communicate. However, utterances were restricted to a few grunts and to one or two unintelligible phonemes. He was unable to name in either the visual, auditory, or tactile modalities. Repetition was not possible. He could follow simple commands and showed some preservation of aural and reading comprehension of simple words and short phrases; however, aural and reading comprehension of more complex material was severely defective. He was severely agraphic, and had gestural apraxia. Nonverbal abilities, such as visual perception and two- and three-dimensional constructional praxis, were normal.

Magnetic resonance imaging obtained five months after onset showed two discrete lesions in the left hemisphere, in the same locations as described before (Fig 1). At this time, follow-up neuropsychologic evaluation revealed remarkable recovery of speech and language (Table). His speech remained slightly effortful, but he produced sentences of normal length, and there were no paraphasias. As shown in Table, nearly all formal linguistic functions had improved to the normal range.

CASE 2.—A 52-year-old right-handed man suddenly developed right-sided focal seizures and an inability to speak. On admission to the hospital, he was alert and oriented. He did not produce any intelligible speech, but answered questions by nodding. He was able to follow a few very simple commands. He had mild right central facial paresis, and slight pronator drift on the right. There were no other signs of motor weakness. Tendon reflexes were slightly brisker in the right upper extremity and right knee. Plantar responses were normal. He had frequent episodes of right facial twitching. By the seventh day after onset, the facial weakness and pronator drift had disappeared.

Computed tomographic scans obtained

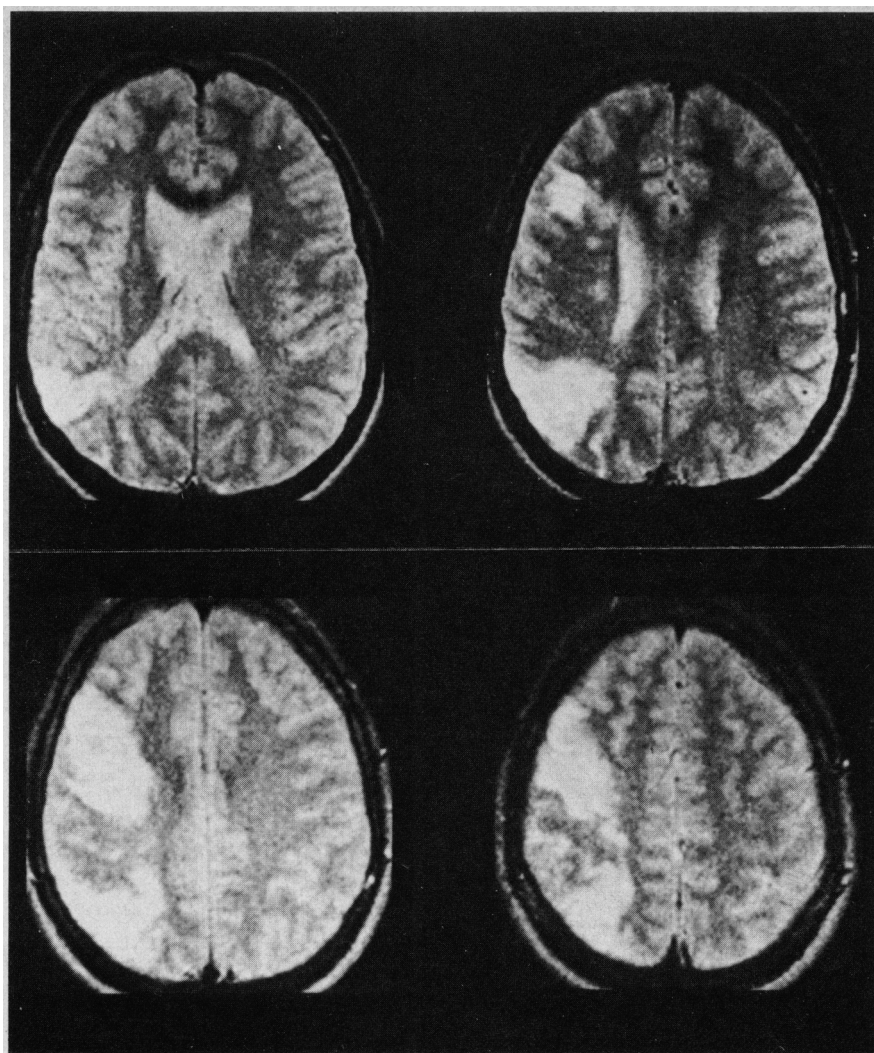


Fig 1.—Magnetic resonance imaging scan of patient 1 obtained five months after onset with T2-weighted image. Note two distinct areas of increased signal in left hemisphere.

Speech and Language Characteristics of Patients 1 and 2				
Characteristic	Patient 1		Patient 2	
	Acute	Chronic	Acute	Chronic
Speech	Severely nonfluent; reduced to "yes" and a profanity	Fluent, nonparaphasic	Severely nonfluent; two profanities	Essentially fluent with occasional paraphasias
Language Naming*	2/30	30/30	0/30	18/30
Sentence repetition*	1/14	12/14	0/14	8/14
Aural comprehension*	8/18	18/18	1/18	14/18
Token test*	5/44	33/44
Reading†	4/10	9/10
Writing*	Severely defective	Normal	Severely defective	Normal
Gestural praxis	Severely defective	Normal	Moderately defective	Normal
Controlled oral word association*	0%	22%	Severely defective	Moderately defective

* Multilingual Aphasia Examination.

† Boston Diagnostic Aphasia Examination.

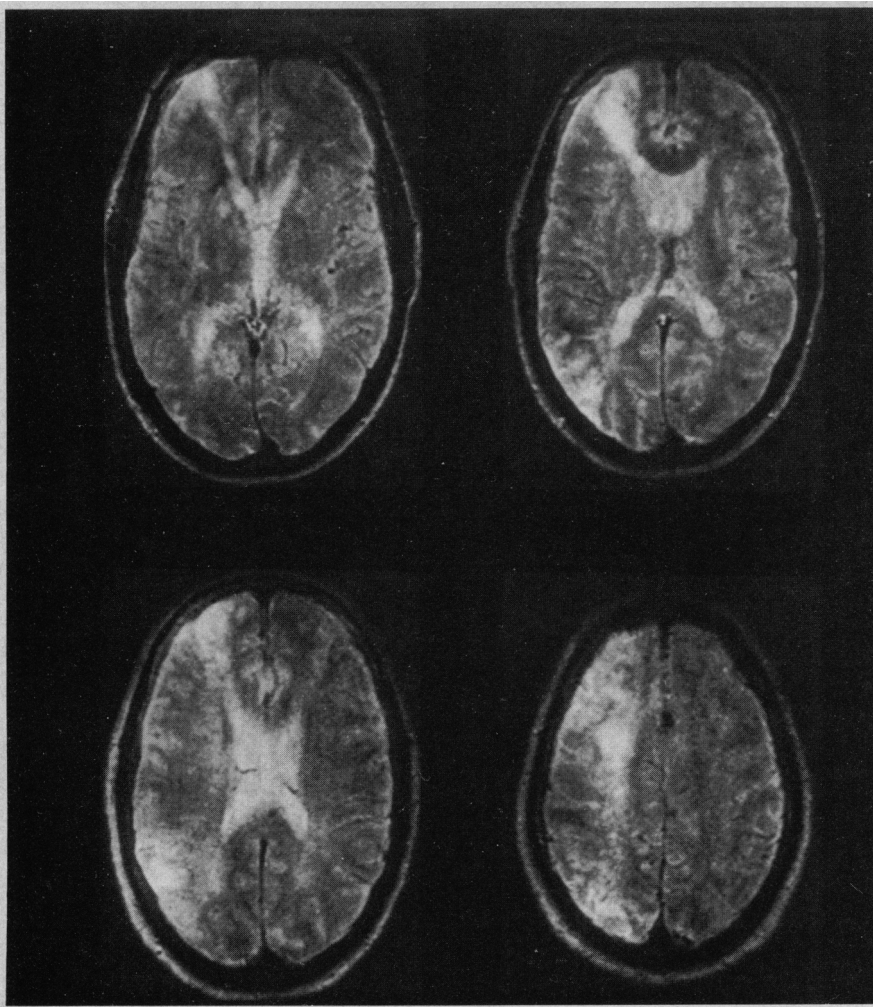


Fig 2.—Magnetic resonance imaging scan of patient 2 obtained two days after onset with T2-weighted image. Note two distinct areas of increased signal in left hemisphere.

the day of onset showed a lesion in the parietal region, and an ill-defined area of possible infarct in the left frontal lobe. Electroencephalography demonstrated rare, left frontal high amplitude and rhythmic delta paroxysms. Cerebral angiography showed complete occlusion at the origin of the left internal carotid and a small residual stump. The left middle cerebral artery filled through retrograde flow from the ophthalmic artery. It did not receive collateral flow from the right internal carotid or from the posterior circulation.

Magnetic resonance imaging performed at this time showed two discrete lesions in the left hemisphere (Fig 2). A frontal-lobe lesion involved the most anterior and superior portion of the frontal operculum (area 45 and white matter undercutting area 44), and extended into prefrontal areas 46 and 9. The other lesion was in the parietal lobe, and involved the inferior and posterior portions of the inferior parietal lobule (areas 40 and 39).

Laboratory evaluation of speech and language was started the day after the event, and continued for several days. It revealed severe impairments in nearly all aspects of speech and language. Spontaneous speech was limited to only two words, both pro-

fancies. Even these were uttered with extreme effort and frequent initial stuttering. The patient could not name or repeat. He had severe alexia and agraphia, and gestural apraxia of the right arm. Comprehension was limited to very simple, one-step commands (eg, "make a fist"). He also showed constructional apraxia and impaired right-left discrimination. Visual perception was relatively intact. He improved slightly during the first week in the hospital, the most notable recovery taking place in the domain of comprehension of conversational speech.

Follow-up neuropsychologic evaluation ten months after the stroke showed excellent recovery of speech and language (Table). He had occasional pauses and word-finding difficulties in spontaneous speech, but formal linguistic assessment demonstrated normal or near-normal levels of performance in most areas tested. Computed tomography performed at this time showed a well-defined frontal lobe lesion in the same area as described before, but extending higher into prefrontal regions in the dorsolateral sector (areas 9 and 8). The parietal lobe lesion was visible as an area of atrophy in the inferior parietal lobule (areas 40 and 39).

CASE 3.—A 51-year-old right-handed

man had a long history of poorly controlled arterial hypertension and severe cerebral vascular disease. According to relatives, he began to evidence changes in behavior and mental status three years previously, with a gradual diminution of activities and mental acuity, and eventual retirement from work. In retrospect, these changes probably reflect the cumulative effect of multiple ischemic events; however, at no time did he show evidence of focal motor or sensory deficits. He then developed an acute onset of difficulty speaking, which prompted admission to our service.

On admission, he showed severe global aphasia. The remainder of the neurologic examination was normal. Computed tomography performed three days after onset showed multiple infarcts located in the left posterior temporoparietal region, left basal ganglia, left prefrontal region, right corona radiata, and right posterior infracalcarine area. These lesions were also seen on MRI obtained the same day.

Cerebral angiography performed five days after the onset of symptoms showed complete occlusion of the left internal carotid artery. The left middle cerebral artery filled through the ophthalmic collaterals. Branch occlusions of the angular and posterior parietal branches of the left middle cerebral artery were also noted.

Neuropsychologic testing was conducted ten days after admission. His speech was severely nonfluent, and he showed profound deficits in most aspects of linguistic functioning. He did produce some short utterances of two or three words. These contained paraphasic errors, but no significant articulatory disturbance. Naming and repetition were not possible. He showed marked impairment of aural and reading comprehension, even for simple material such as single words and short phrases. He was agraphic, with frequent paraphagic errors especially when copying written text.

Five weeks later, he showed slightly improved speech fluency. He produced longer utterances with frequent paraphasic errors, but continued to have little success in naming, repetition of short sentences, or comprehension of verbal material. Also, he showed moderate compromises in areas of nonverbal, visuospatial cognitive functioning. These deficits, less severe than those in the verbal sphere, were interpreted as due to the right hemisphere lesions.

Computed tomography performed at this time showed three distinct areas of infarct in the left hemisphere (Fig 3). One was in the dorsolateral prefrontal cortex (areas 46, 9, 8). Another was in the basal ganglia, and involved the head of the caudate nucleus, part of the anterior limb of the internal capsule, and the paraventricular white matter. The third was in the posterior portion of the superior temporal gyrus (posterior area 22 and 37) and the inferior parietal lobule (areas 40 and 39).

A neuropsychologic follow-up examination was performed four months after the initial event. His speech at this time was essentially fluent, although there were frequent pauses and hesitations. Paraphasias

were common, especially in spontaneous speech and naming tasks. He remained unable to name (nearly all paraphasic responses) or repeat, but aural and reading comprehension were significantly improved. There were also very significant improvements in gestural and constructional praxis. Although nearly all of his scores continued to fall in the "impaired" range, he generally showed a very good profile of recovery of verbal communication abilities, relative to the severe global aphasia he manifested acutely.

COMMENT

Our patients acutely developed a syndrome of global aphasia without the expected hemiparesis, caused by cerebral infarction. The lesions associated with global aphasia can vary in both extent and location. There is, however, a strong association between the typical clinical picture of global aphasia and involvement of the entire left perisylvian region. These lesions result from a large infarction in the territory of the left middle cerebral artery. Damage involves all or most of the areas known to be related to speech and language: the frontal operculum (areas 44 and 45), the posterior half of the superior temporal gyrus (areas 41, 42, and posterior area 22), the posterior region of the middle and inferior temporal gyri (area 37), the supramarginal and angular gyri (areas 40 and 39), and deep structures, including the basal ganglia and insula. Commonly, damage involves part of the motor cortices, or the subcortical white matter where corticobulbar fibers cross, or both. Thus, global aphasia and right-sided motor deficits typically occur together, although the latter may be relatively transient in a few cases.¹⁴

Our cases, however, had two discrete lesions. One of these was in anterior language cortices or in the subcortical gray-matter areas known to be related to language dysfunction,^{15,16} and one was in the posterior language cortices. The primary motor cortices were intact. A similar localization of lesions in a case of global aphasia was noted previously in a description from this laboratory.⁹

The pathological events that lead to such double and discrete areas of damage are of special interest. Van Horn and Hawes¹⁰ described three patients who developed global aphasia without hemiparesis, all of whom had two separate lesions in the left hemisphere. The authors concluded that this clinical picture was indicative of an "embolic encephalopathy." Our cases are also consistent with the notion of an embolic pathophysiology.

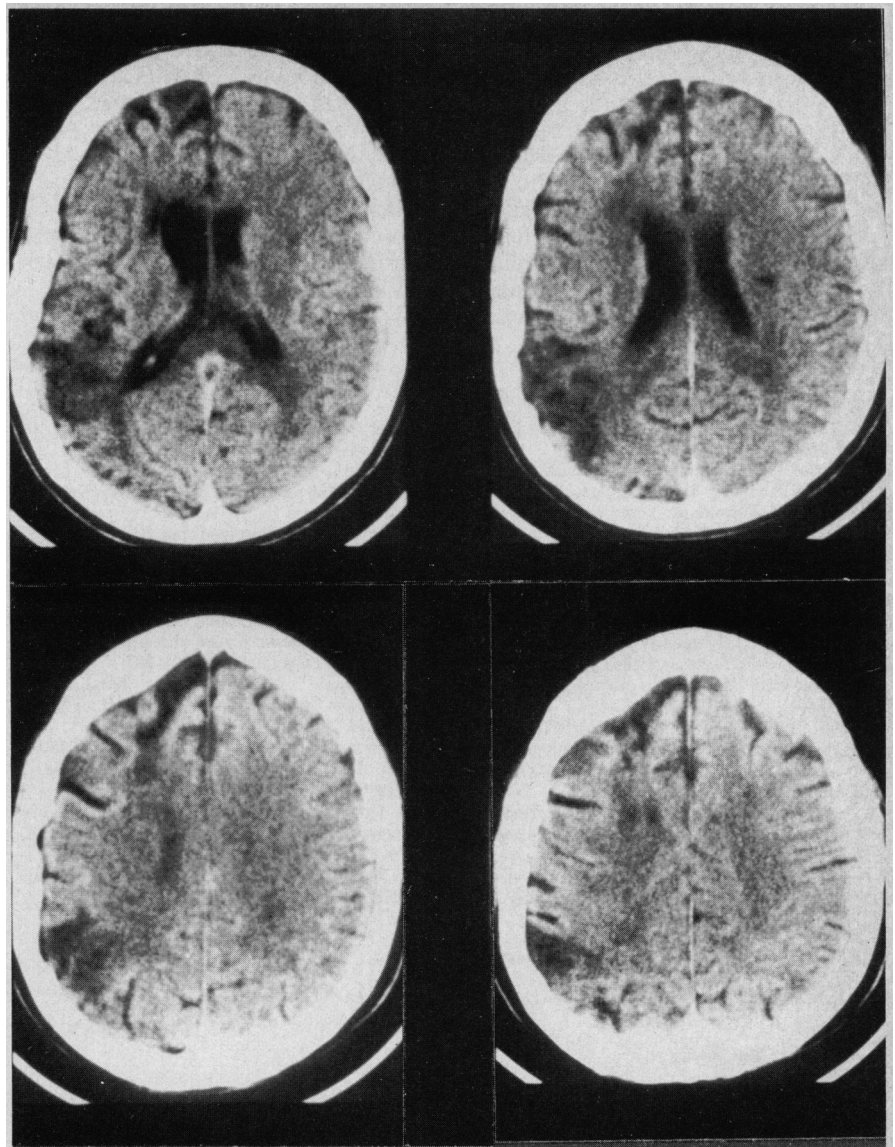


Fig 3.—Magnetic resonance imaging scan of patient 3 obtained five weeks after onset without contrast. Note three distinct areas of low density in left hemisphere.

Two patients had complete occlusion of the left internal carotid artery, and the third had an intraluminal "clot" in the supraclinoid portion of the left internal carotid artery.

A final point of importance is the issue of recovery. Poor recovery from global aphasia is a ubiquitous finding in extant research.^{5,17-21} A comparison between recoveries from different types of aphasia shows that patients with global aphasia invariably fare the poorest.^{18,20,21} Sarno and Levita¹⁹ noted that the greatest changes in the evolution of global aphasia may occur between the sixth and 12th months after onset. Nevertheless, these patients remained severely defective in communication skills 12 months after onset, and were still classified as global aphasics. Intensive speech

therapy does not appear to significantly improve this poor recovery.^{18,19}

In sharp contrast, the three cases described here showed very good recovery of speech and language. This was particularly evident in patients 1 and 2, in whom speech became fluent, repetition became normal, and aural comprehension only showed deficits with complex material. Agraphia and gestural apraxia also resolved. Patient 3 also improved substantially, although not as completely. By ten months after onset, none of the three patients continued to meet diagnostic criteria for global aphasia. Patients 1 and 2 showed only minimal signs of residual aphasia, not sufficient to qualify for formal classification; patient 3 could be classified as having a residual Broca's aphasia.

It is interesting to speculate as to the possible reasons for this uncharacteristic recovery. A major difference between our patients and the traditional patient with global aphasia is the extent of involvement of language-related areas. Typically, as elaborated above, there is extensive destruction of most of the perisylvian and basal ganglia regions, including the frontal operculum, posterior superior temporal gyrus, inferior parietal

lobule, insula, and motor cortices. However, our patients had only circumscribed involvement of some of these areas. Thus, although the initial insults rendered these areas sufficiently dysfunctional to produce a picture of global aphasia, the amount of undamaged language-related territory probably allowed for this otherwise unusually complete recovery of speech and language.

In short, the presentation of global

aphasia without hemiparesis predicts two discrete lesions in the anterior and posterior left hemisphere language areas, possibly of an embolic etiology. This syndrome also seems to indicate the possibility of an unusually good recovery of verbal communicative abilities.

This study was supported in part by National Institute of Neurological and Communicative Diseases and Stroke (Bethesda, Md) grant PO1 NS 19632.

References

1. Geschwind N: Current concepts: Aphasia. *N Engl J Med* 1971;284:654-656.
2. Benson DF, Geschwind N: The aphasias and related disturbances, in Baker AB, Baker LH (eds): *Clinical Neurology*. New York, Harper & Row Publishers Inc, vol 1, 1971.
3. Naeser MA, Hayward RW: Lesion localization in aphasia with cranial computed tomography and the Boston Diagnostic Aphasia Examination. *Neurology* 1978;28:545-551.
4. Naeser MA, Hayward RW, Laughlin SA, et al: Quantitative CT scan studies in aphasia: I. Infarct size and CT numbers. *Brain Lang* 1981;12:140-164.
5. Kertesz A, Harlock W, Coates R: Computer tomographic localization, lesion size, and prognosis in aphasia and nonverbal impairment. *Brain Lang* 1979;8:34-50.
6. Mazzocchi F, Vignolo LA: Localization of lesions in aphasia: Clinical-CT scan correlation in stroke patients. *Cortex* 1979;15:627-653.
7. Basso A, Lecours AR, Moraschini S, et al: Anatomical correlations of the aphasias as defined through computerized tomography: Exceptions. *Brain Lang* 1985;26:201-229.
8. Vignolo LA, Boccardi E, Caverni L: Unexpected CT-scan findings in global aphasia. *Cortex* 1986;22:55-69.
9. Damasio H: Cerebral localization of the aphasias, in Sarno MT (ed): *Acquired Aphasia*. Orlando, Fla, Academic Press Inc, 1981, pp 27-50.
10. Van Horn G, Hawes A: Global aphasia without hemiparesis: A sign of embolic encephalopathy. *Neurology* 1982;32:403-406.
11. Damasio H: A computed tomographic guide to the identification of cerebral vascular territories. *Arch Neurol* 1983;40:133-142.
12. Benton AL: *Multilingual Aphasia Examination*. Iowa City, Department of Neurology, University of Iowa, 1976.
13. Goodglass H, Kaplan E: *The Assessment of Aphasia and Related Disorders*. Philadelphia, Lea & Febiger, 1972.
14. Ferro JM: Global aphasia without hemiparesis. *Neurology* 1983;33:1106.
15. Damasio AR, Damasio H, Rizzo M, et al: Aphasia with nonhemorrhagic lesions in the basal ganglia and internal capsule. *Arch Neurol* 1982;39:15-20.
16. Naeser M, Alexander MP, Helm-Estabrooks N, et al: Aphasia with predominantly subcortical lesion sites. *Neurology* 1982;39:2-14.
17. Yarnell P, Monroe P, Sobel L: Aphasia outcome in stroke: A clinical neuroradiological correlation. *Stroke* 1976;7:516-522.
18. Sarno MT, Levita E: Recovery in treated aphasia in the first year post-stroke. *Stroke* 1979;10:663-670.
19. Sarno MT, Levita E: Some observations on the nature of recovery in global aphasia after stroke. *Brain Lang* 1981;13:1-12.
20. Kertesz A, McCabe P: Recovery patterns and prognosis in aphasia. *Brain* 1977;100:1-18.
21. Demeurisse G, Demol O, Derouck M, et al: Quantitative study of the rate of recovery from aphasia due to ischemic stroke. *Stroke* 1980;11:455-458.