

such as computed tomography and magnetic resonance imaging do not lead to the correct diagnosis, strong diagnostic consideration should be given to a vascular dissection, which must be demonstrated by arteriography.

We believe that facial numbness and dysesthesia represent previously unemphasized features of internal carotid artery dissection. Spontaneous vascular dissections should be considered in the differential diagnosis of patients presenting with unilateral head and neck pain, oculosympa-

thetic paresis, dysgeusia, and facial numbness.

References

1. Fisher CM: The headache and pain of spontaneous carotid dissection. *Headache* 1982;22:60-65.
2. Mokri B, Sundt TM, Houser OW: Spontaneous internal carotid dissection, hemicrania, and Horner's syndrome. *Arch Neurol* 1979;36:677-680.
3. West TET, Davies RJ, Kelly RE: Horner's syndrome and headache due to carotid artery disease. *Br Med J* 1976;3:818-820.
4. Davis RH, Daroff RB, Hoyt WF: Hemicrania, oculosympathetic paresis and subcranial

carotid aneurysm: Raeder's paratrigeminal syndrome (group 2) case report. *J Neurosurg* 1968;29:94-96.

5. Mokri B, Sundt TM, Houser OW, et al: Spontaneous dissection of the cervical internal carotid artery. *Ann Neurol* 1986;19:126-138.
6. Thompson HS, Mensher JH: Adrenergic mydriasis in Horner's syndrome: Hydroxyamphetamine test for diagnosis of postganglionic defects. *Am J Ophthalmol* 1971;72:472-480.
7. Carpenter MB: *Human Neuroanatomy*. Baltimore, Williams & Wilkins, 1976.
8. Anderson CA, Collins GJ, Rich NM, et al: Spontaneous dissection of the internal carotid artery associated with fibromuscular dysplasia. *Am Surg* 1980;46:263-266.

Loss of Deep Dyslexic Reading Ability From a Second Left-Hemispheric Lesion

David P. Roeltgen, MD

• It has been hypothesized that the residual reading ability in people with deep dyslexia (an acquired dyslexia in which the subjects make semantic paralexias, eg, child read as boy) utilizes right hemispheric structures. A patient who was deep dyslexic following an initial left hemispheric stroke was studied. Following a new left hemispheric stroke, he lost his residual reading ability. In this patient, deep dyslexic reading abilities were dependent on left hemispheric structures.

(*Arch Neurol* 1987;44:346-348)

Subjects with deep dyslexia produce semantic paralexias when reading aloud. Other characteristics, including visual errors, function word substitutions, derivational errors, demonstration of an inability to derive phonology from print and reading high imagery words better than low imagery words, nouns better than adjectives, adjectives better than verbs, and nouns better than function words, also occur as part of the syndrome.¹ Although there is agreement

on the general clinical presentation of patients with deep dyslexia, there is considerable controversy regarding potential anatomic substrates underlying their residual reading ability. We addressed this issue by assessing the residual reading ability in a patient with deep dyslexia after he had a second cerebral lesion. Consequently, we were able to draw some conclusions regarding the anatomic substrate for his reading abilities following his first stroke.

REPORT OF A CASE

A 54-year-old right-handed man had a left cerebral infarction in 1981. He had a transient right-sided paresis and mild stable aphasia. He was studied 2½ years following his stroke and except for a mild aphasia, results of an examination were normal. His spontaneous speech was mildly nonfluent with good articulation. His comprehension for conversation and commands was good, but deteriorated with increased complexity of syntax. Naming to confrontation was good. Based on history and results of the Western Aphasia Battery (WAB)² (Table 1), he could best be described as a recovered Broca's aphasic. He was considered deep dyslexic because he made semantic errors when reading aloud, especially when reading paragraphs.

When reading single words (n = 420) he made 58 errors: 3% semantic ("clothing" for "fabric"), 14% derivational ("confidence" for "confidence"), 43% visual ("melt" for "man"), and 4% function word substitutions ("should" for "such"). When reading words in paragraphs (n = 387) he made 55 errors: 11% semantic, 9% deriva-

tional, 20% visual, and 35% function word substitutions. Analysis of his ability to read single words is presented in Table 2.

The patient had adequate comprehension of single words and moderately good comprehension of paragraphs, with a raw score of 65 on the paragraph comprehension subtest of the Peabody Individual Achievement Test.³ On phonological reading tasks, he had difficulty reading nonwords (14 [23%] of 60 correct) but repeated them well (20 of 20) (Battery of Linguistic Analysis of Writing and Reading)⁴; (Battery of Adult Reading Function [L. J. Rothi, H. B. Coslett, K. M. Heilman, unpublished data, 1983]). He also made errors on a visually presented rhyming task when asked to say whether two words rhymed (16 of 20 correct; chance equals ten of 20) and on a picture-pointing task for nonwords that were homophonic for real words (pseudohomophones) (Battery of Adult Reading Function; 36 of 40 correct; chance equals 13 of 40) (Table 3).

In September 1984, the patient sustained a new stroke, with a new right hemiparesis and marked worsening of his language performance. The results of the rest of the examination were unchanged. On examination, his fluency and comprehension were more impaired than previously, and his repetition was limited to approximately two word phrases. Naming ability declined such that he was able to name only rare objects with phonemic cues. Clinical evaluation and results from the WAB² (Table 1) suggested that he could be best classified as having a mixed aphasia.

His language performance was studied at two, four, and six weeks following his second stroke, and results from clinical and formal examinations were constant. He had fairly consistent scores on the WAB² (Table 1).

Accepted for publication Oct 13, 1986.

From the Department of Neurology, University of Missouri-Columbia and the Harry S Truman Memorial Veterans Hospital, Columbia, Mo.

Presented at the Eighth European Conference of the International Neuropsychological Society, Copenhagen, June 1985.

Reprint requests to Department of Neurology, M741 Health Science Center, University of Missouri-Columbia, Columbia, MO 65212 (Dr Roeltgen).

He had little residual reading ability after the second stroke. Whereas previously he had read 100% of a list of highly imageable nouns and 90% of function words, he now read only 5% and 0%, respectively, despite correctly repeating 95% of the nouns and 75% of the function words. He correctly read only rare single letters. Error analysis revealed that there were no semantic paralexias and perhaps one function word substitution. Some errors had slight visual similarity to the stimulus word ("dog" for "egg") but most errors were unrelated real words ("stamp" for "fruit") or neologisms ("staems" for "whatever"). He could not read any nonsense words, but repeated 50%. He had no phonological reading ability; he could not perform the previously presented visual rhyming task or the pseudohomophone pointing task. He comprehended some single words, including occasional words that he could not read aloud. Single word comprehension on the Reading Comprehension Battery for Aphasia¹ was slightly greater than chance.

Computed tomography (CT) performed within 48 hours after the new stroke demonstrated well-defined areas of low density, one small one in the right frontal region and one large one in the left posterior temporoparietal region. The right frontal lesion involved part of the inferior frontal gyrus, the lower half of the precentral gyrus, and part of the mid and anterior insula cortex. The left-sided lesion involved the cortex surrounding the posterior half of the superior temporal sulcus as well as the angular gyrus, and extended subcortically to the lateral ventricle. In addition, a less well-defined low-density region was present in the left frontoparietal region. Two weeks later, a repeated CT scan demonstrated enhancement of the left frontal lesion. This lesion involved the lower portions of the precentral and postcentral gyri, the insula cortex, the posterior half of the superior temporal gyrus, and part of the body of the caudate nucleus. Independent neurologists and a radiologist interpreted the clinical and radiologic evidence as indicating two previous old ischemic infarctions and a recent left frontoparietal ischemic infarction (Figure).

COMMENT

There is considerable controversy regarding possible anatomic substrates subserving the residual reading ability in patients with deep dyslexia, and much of this controversy centers on the production of semantic paralexias.⁶⁻¹²

Some authors suggest that the compensatory reading strategies used by deep dyslexic patients, especially those strategies responsible for the production of semantic paralexias, utilize, at least in part, reading mechanisms located in the right hemisphere (right hemisphere hypothesis).^{7,8,11,12} Major support for this conclusion is the qualitative similarity between the reading ability of

Table 1.—Results of the Western Aphasia Battery*					
	Information	Fluency	Comprehension	Repetition	Naming
Initial assessment	9.0	6.0	8.2	7.6	9.1
Second assessment					
Second week	0.0	5.0	6.25	4.5	1.5
Sixth week	0.0	5.0	...†	4.7	...

* Adapted from Kertesz.²

† Similar result on one subtest (Auditory Word Comprehension).

Table 2.—Analysis of Single-Word Reading Ability: A Battery of Linguistic Analysis for Writing and Reading*							
	Imageable Nouns†	Function Words†	High- Imagery Nouns†	Low-Imagery		Orthographic	
				Nouns‡	Adjectives‡	Verbs‡	Regular§ Irregular§
Correct, %	100	90	97	80	83	75	82 71

* Adapted from Roeltgen et al.⁴

† Matched for length, frequency, and regularity (n = 40 nouns and function words).

‡ Matched for length and frequency (n = 30).

§ Matched for length, frequency, and word class (n = 45).

patients with deep dyslexia and the responses of some subjects, normal and commissurotomy, to orthographic input presented only to the left visual field.^{12,13} These groups all have been shown to produce semantic paralexias.

Alternatively, other authors suggest that the right hemisphere has little or no reading ability, and that the oral reading ability of deep dyslexic patients depends on residual left hemispheric mechanisms.^{9,14}

Following his initial symptomatic stroke (presumably the stroke that caused the left parietal lesion), this patient had a mild stable aphasia. He also had a dyslexia characterized by semantic, derivational, and visual paralexias, as well as function word substitutions. He also read nouns of high imagery better than matched nouns of low imagery, and read nouns better than matched function words and nouns better than matched adjectives, which he read better than matched verbs (Table 2). In addition, he showed difficulty in deriving phonology from print. He read only 14 of 60 nonwords and had difficulty on two phonology recognition tasks, rhyming and pseudohomophone picture-pointing. These findings are consistent with the diagnosis of deep dyslexia.

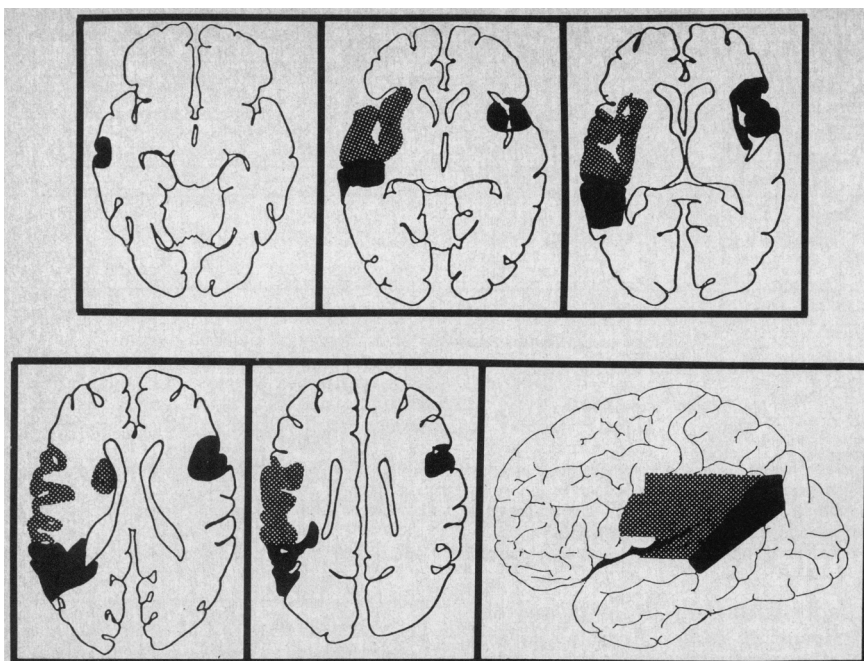
Following his most recent stroke, the patient lost much of his speech ability and almost all of his reading ability, including reading of real words, deriving phonology from print and comprehension.

Computed tomography following the last stroke indicated that he had most likely sustained a recent left frontal cerebral infarction. Although no old CT scans were available for comparison, the clinical and radiologic

Table 3.—Phonetic Reading	
Test	Score Correct/ Given
Nonword oral reading from Battery of Linguistic Analysis of Writing and Reading (one and two syllables) ⁴	8/20
Nonword oral reading from Battery of Adult Reading Function (one, two, and three syllables with com- plex phonemes, eg, blends) ⁵	6/40
Rhyming task (real words)	16/20 (chance, 10/20)
Picture-pointing task (three pictures) when stimulus was a nonword homo- phonic for a real word	36/40 (chance, 13/40)

ic evidence indicate that the left frontal lesion was recent and the other lesions were old. The size and location of the right frontal lesion, close to or involving the motor area, make it unlikely that an acute ischemic stroke in that location would be undetectable clinically. Similarly, the new right hemiparesis is consistent with a new left hemispheric lesion. The non-changing, well-defined lesions, posteriorly on the left and on the right, as found on the initial CT scan, are inconsistent with the diagnosis of acute ischemic infarction. In contrast, the left frontal lesion that was initially ill-defined and later enhanced is typical for an acute ischemic infarction.

These clinical and radiologic data are consistent with the conclusion that in this patient, the residual reading ability following the first stroke was dependent on left frontal mechanisms.



Second computed tomographic study after latest stroke. Stippled area is enhancing lesion, consistent with recent ischemic infarction. Shaded areas are well-defined lucencies, consistent with old ischemic infarctions. Brain slices were plotted using technique of Damasio and Damasio.¹⁷ The lateral view was extrapolated from transverse sections and plotted on lateral view of left hemisphere (modified after Gado et al¹⁸).

The right hemisphere hypothesis for reading includes at least two components, analysis and response.¹⁰ Analysis is thought to include those mechanisms necessary for perception and description of the stimulus word so as to generate a semantic code. This information is then thought to be transferred to the left hemisphere for response. The response may include oral reading and/or lexical decision.

Prior to his last stroke, our patient was able to perform analysis (comprehension of written words and slightly better than chance ability to point to pictures when pseudohomophones were presented) and production (oral reading). Following the last stroke, despite retaining some speech ability (comprehension, single-word repetition, and one-to-three-word spontaneous utterances), he lost ability to perform both analysis and production for reading. Such findings are most consistent with the conclusion that, in this patient, reading analysis and production, including lexical access for comprehension and production of semantic paralexias, were dependent on left hemispheric mechanisms that were present after his earliest aphasic stroke.

There are at least two ways that this patient's residual reading abilities may have been dependent on left hemispheric mechanisms. First, those mechanisms may have been present in

the left hemisphere and subsequently disrupted by the second left hemispheric stroke. Alternatively, the second left hemispheric stroke may have disrupted access to language mechanisms that remained intact in the right hemisphere. The second explanation is unlikely because the occipital lobes, the temporo-occipital region, and the splenium of the corpus callosum, structures usually thought to be necessary for the perception of and interhemispheric transfer of visually perceived written language,¹⁵ were intact after the second left hemispheric stroke. Consequently, perception and interhemispheric transfer of visual information, including reading, should have remained intact after the second left hemispheric stroke.

Although these data are consistent with the conclusion that this patient's deep dyslexic reading abilities, both analysis and production, depended on intact left hemispheric functions, such a conclusion may not be true for all patients with deep dyslexia. Heilman et al¹⁶ described a patient with a global aphasia following a left hemispheric stroke. Their patient had preserved reading comprehension that was lost after a new right hemispheric stroke. Their results indicate that, unlike the present patient, some patients may have mechanisms present in the right hemisphere capable of analysis of reading. The results

from the present patient, as well as those from the patient described by Heilman et al suggest that residual mechanisms necessary to analyze reading may be present in the left or right hemisphere, but that in some patients both mechanisms are disrupted by new left hemispheric lesions.

This study was supported by Teacher Investigator Development award K07 NS00807 to the University of Missouri-Columbia.

The author thanks Lisa Carr for helping test the subject, and Evelyn Hampton for manuscript preparation.

References

1. Coltheart M: Deep dyslexia: A review of the syndrome, in Coltheart M, Patterson KE, Marshall JC (eds): *Deep Dyslexia*. London, Routledge & Kegan Paul, 1980, pp 22-47.
2. Kertesz A: *Western Aphasia Battery*. London, University of Western Ontario, 1980.
3. Dunn LN, Markwardt FC: *Peabody Individual Achievement Test*. Circle Pines, Minn, American Guidance Service, 1970.
4. Roeltgen DP, Cordell C, Sevush S: A battery of linguistic analysis for writing and reading. *Int Neuropsychol Soc Bull*, October 1983, p 31.
5. La Pointe LL, Horner J: *Reading Comprehension Battery for Aphasia*. Tigard, Ore, CC Publications, 1979.
6. Saffran EM, Bogoy LD, Schwartz MF, et al: Does deep dyslexia reflect right-hemisphere reading? in Coltheart M, Patterson K, Marshall JC (eds): *Deep Dyslexia*. London, Routledge & Kegan Paul, 1980, pp 381-406.
7. Coltheart M: Deep dyslexia: A right hemisphere hypothesis, in Coltheart M, Patterson KE, Marshall JC (eds): *Deep Dyslexia*. London, Routledge & Kegan Paul, 1980, pp 22-47.
8. Landis T, Regard M, Graves R, et al: Semantic paralexia: A release of right hemispheric function from left hemispheric control? *Neuropsychologia* 1983;21:359-364.
9. Marshall JC, Patterson KE: Semantic paralexia and the wrong hemisphere: A note on Landis, Regard, Graves, and Goodglass. *Neuropsychologia* 1983;21:425-427.
10. Patterson K, Besner D: Is the right hemisphere literate? *Cog Neuropsychol* 1984;1:315-341.
11. Rabinowicz B, Moscovitch M: Right hemisphere literacy: A critique of some recent approaches. *Cog Neuropsychol* 1984;1:343-350.
12. Zaidel E, Schweiger A: On wrong hypotheses about the right hemisphere: Commentary on Patterson K, Besner D, "Is the right hemisphere literate?" *Cog Neuropsychol* 1984;1:351-364.
13. Regard M, Landis T: Experimentally induced semantic paralexias in normals: A property of the right hemisphere. *Cortex* 1984;20:263-270.
14. Besner D: Deep dyslexia and the right-hemisphere hypothesis: Evidence from the USA and the USSR. *Can J Psychol* 1983;37:565-571.
15. Friedman RB, Albert ML: Alexia, in Heilman KM, Valenstein E (eds): *Clinical Neuropsychology*. New York, Oxford University Press Inc, 1985, 49-73.
16. Heilman KM, Rothi L, Campanella D, et al: Wernicke's and global aphasia without alexia. *Arch Neurol* 1979;36:129-133.
17. Damasio H, Damasio A: 'Paradoxical' ear extinction in dichotic listening: Possible anatomical significance. *Neurology* 1979;29:644-653.
18. Gado M, Hanaway J, Frank R: Functional anatomy of the cerebral cortex by computed tomography. *J Comput Assist Tomogr* 1979;3:1-19.