

Luxury Perfusion Syndrome in Cerebral Vascular Disease Evaluated with Technetium-99m HM-PAO

GIANLUIGI SPREAFICO, M.D., FABIO CAMELLI, M.D., GENZIANA GADOLA, M.D.,
ROBERTO FRESCHI, M.D.,* AND FRANCO ZANCANER, M.D.†

A recently developed Tc-99m radiocompound, hexamethylpropyleneamine oxime (Tc-99m HM-PAO), exhibits favorable properties for regional cerebral blood flow study in man. The authors present a case of luxury perfusion syndrome observed in a 72-year-old patient with acute stroke and a right-sided hemiplegia, documented by planar scintigraphy and SPECT study in correlation with CT scan. The metabolic basis of this phenomenon is discussed and the usefulness of assessing regional brain perfusion by Tc-99m HM-PAO with conventional nuclear medicine equipment is underlined.

*From the Department of Nuclear Medicine,
Department of Neurology,* and the
Department of Neurosurgery,†
Legnano Hospital,
Legnano, Italy*

THE ASSESSMENT OF REGIONAL cerebral blood flow (rCBF) can help in the differentiation of cerebral vascular diseases and monitor the immediate and late effects of the vascular events (1,2,3). The regions affected by various types of cerebral vascular accidents are generally associated with reduced perfusion. Nevertheless, in some patients regional perfusion increases paradoxically soon after cerebral vascular lesions (luxury perfusion syndrome (LPS)). A case in which luxury perfusion was detected by planar scintigraphic image and brain SPECT is reported and discussed.

Case Report

A 72-year-old man was admitted to the hospital with acute stroke and a right-sided hemiplegia. Five days after the onset of symptoms a study with Tc-99m HM-PAO was performed. The injected dose was 20 mCi (740 MBq), and imaging started 15 minutes after the injection.

Planar image in the left lateral projection showed a decreased uptake of radiotracer in the upper part of parietal lobe with an increased uptake in the temporal lobe and lower part of parietal lobe (Fig. 1).

Tomographic images confirmed the finding of the

planar scintigraphy and also showed a marked increase of regional blood flow in deep regions of the left temporal lobe compared to normal areas on the right side (Fig. 2). A CT scan obtained one day later showed a large area of low density in the left parietal and temporal lobes (Fig. 3).

Discussion

Regional cerebral perfusion is regulated in part by the local metabolic needs of the brain. In acute stroke, due to the loss of the normal autoregulatory mechanisms, an inappropriate vascular dilatation occurs, inducing an over-abundant cerebral blood flow relative

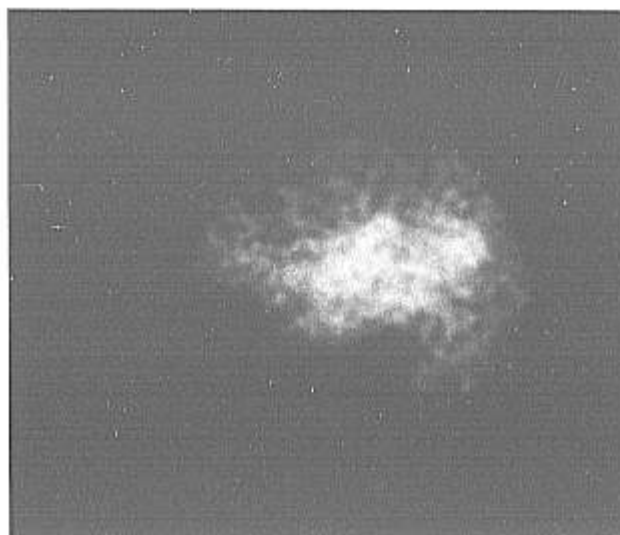


Fig. 1. Tc-99m HM-PAO planar image. Left lateral projection. Increased uptake of radiotracer in temporal lobe and lower part of parietal lobe.

Received for publication March 19, 1986; accepted June 3, 1986.
Reprint requests: Gianluigi Spreafico, U.O. di Medicina Nucleare, Ospedale di Legnano, Via Candiani 2, 20025 Legnano, Italia.

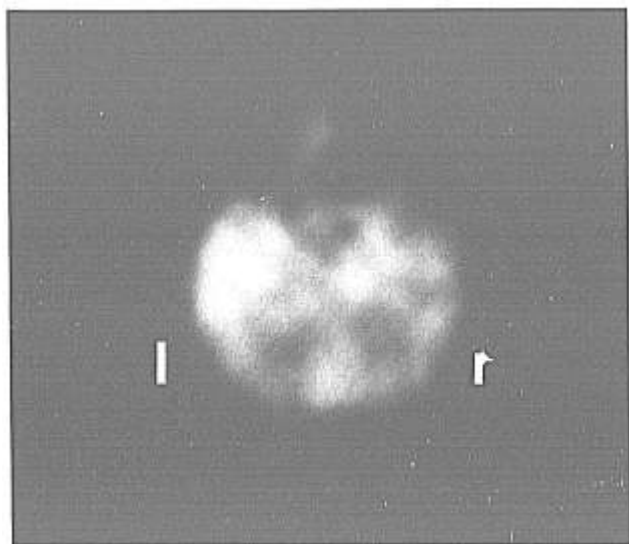


Fig. 2. Tc-99m HM-PAO tomography. Increased uptake in the left temporal lobe.

to metabolic need of the brain tissue.

The LPS observed during the first days of vascular accident is considered a transitory phenomenon, and is thought to be considerably important in relation to the pathophysiology of many acute brain diseases, notably apoplexy and acute neurosurgical conditions (4).

The sequential scintigraphic images following intravenous injection of the tracer (cerebral angioscintigraphy) enhance the information provided by nuclear medicine techniques, and in some cases help in the diagnosis of vascular brain lesions with hyperperfusion (5,6). Nevertheless, this method does not provide a correct localization of the hyperperfused cere-

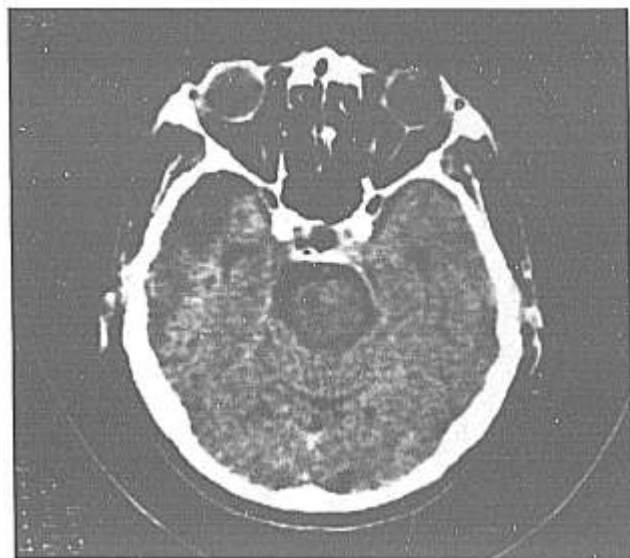

Fig. 3. X-ray CT scan. Area of low density in left temporal lobe.

bral lesions and in some cases the angioscintigraphic finding of LPS must be differentiated from arterio-venous malformations, hypervascular tumors, and hypervascular patterns associated with idiopathic focal epilepsy.

In ischemic cerebral vascular accidents, the CT scan evaluates the mass effect during the early stage and can differentiate ischemic infarcts and intracerebral hemorrhage although some hemodynamic alterations are not detectable by this technique.

The use of radiocompounds that cross the normal as well as the damaged blood-brain barrier and are taken up by the brain tissue has improved knowledge of the rCBF in many brain diseases.

Most of the existing radiocompounds, such as I-123 labeled amine and diamine derivatives, are still particularly expensive and limited by logistical problems. A Tc-99m labeled oxim, a hexamethyl-propyl-eneamine derivative (Tc-99m HM-PAO) has been developed recently. This lipophilic radiopharmaceutical is taken up by the brain in a way similar to I-123 labeled amines. In comparison with these compounds, Tc-99m HM-PAO presents some advantages. It shows little redistribution in the human brain up to 4-5 hours after IV injection (7); moreover the wide diffusion of Mo-99/Tc-99m generators and the physical characteristics of this radionuclide allow SPECT execution in every instance with conventional equipment.

Planar and tomographic images performed with this radiocompound are able to detect the site and extension of anomalous hyperperfused areas, providing useful data for a more correct diagnostic and therapeutic procedure. Moreover, although the planar image can detect the superficial aspect of vascular lesions, the SPECT technique provides more detail, also showing brain perfusion changes in the deep regions.

References

1. Alavi A, Reivich M, Jones SC, et al: Functional imaging of the brain with positron emission tomography. In Freeman L, Weissman H (eds): *Nuclear Medicine Annual*. New York, Raven Press, 1982, pp 319-372.
2. Lassen NA: Cerebral blood flow tomography with Xenon-133. *Semin Nucl Med* 15: 347, 1985.
3. Royal HD, Hill TC, Holman L: Clinical brain imaging with Isopropyl-Iodoamphetamine and SPECT. *Semin Nucl Med* 15: 357, 1985.
4. Lassen NA: The luxury perfusion syndrome and its possible relation to acute metabolic acidosis localized within the brain. *Lancet* II: 1113, 1966.
5. Soin JS, Burdine JA: Acute cerebral vascular accident associated with hyperperfusion. *Radiology* 118: 109, 1976.
6. Banzo J, Morales F, Abòs MD, et al: 'Luxury perfusion syndrome' in a patient with reversible ischemic neurological deficits. *Eur J Nucl Med* 8: 135, 1983.
7. Ell PJ, Hocknell JML, Jarrit PH, et al: A 99mTc-labeled radiotracer for the investigation of cerebral vascular disease. *Nucl Med Commun* 6: 437, 1985.