

Case report

Delayed hydrocephalus and visual field defect due to perianeurysmal inflammation after treating a large unruptured aneurysm with flow diverter and coil: A case report

Satoru Takahashi¹, Mariko Ishikawa, Hirotaka Sagawa², Hikaru Wakabayashi, Shoko Fujii³, Kyohei Fujita⁴, Jiro Aoyama, Sakyo Hirai⁵, Kazutaka Sumita^{*,6}

Department of Endovascular Surgery, Tokyo Medical and Dental University, Tokyo, Japan



A B S T R A C T

Flow diverter (FD) placement is increasingly used to treat large supraclinoid aneurysms. Here, we report a case of hydrocephalus following FD placement. One patient in her 60s underwent FD placement combined with coil embolization. Within 1 month, the patient started to show visual field defects and symptoms of hydrocephalus, which worsened within another month. We report that hydrocephalus developed acutely, without high protein levels in the cerebrospinal fluid, and as a complication using a Surpass Streamline. Although the precise mechanisms are unclear, our report suggests a different mechanism for the development of hydrocephalus after FD placement combined with coil embolization.

1. Introduction

Flow diverter (FD) placement for treating large supraclinoid aneurysms has increased recently. Based on the SCENT trial, Surpass Streamline (Stryker Neurovascular, Fremont, CA) can be used for unruptured-supraclinoid aneurysms with wide neck (≥ 4 mm) and large or giant size (≥ 10 mm) [1]. The combination of FD placement and coil embolization is suggested to prevent rupture after surgery; however, several reports have described the development of hydrocephalus as a complication after treatment with a pipeline embolization device (Medtronic, Minneapolis, MN, USA) combined with coil embolization [2]. Here, we report the case of an unruptured supraclinoid aneurysm treated with a Surpass Streamline in combination with coil embolization in a patient who developed hydrocephalus without septic or aseptic meningitis.

2. Case report

A patient in her 60s was referred to our hospital with a right internal

carotid artery (ICA) aneurysm, coincidentally diagnosed using magnetic resonance imaging (MRI). The patient showed no neurological deficits. Pretreatment angiographic images showed a large aneurysm ($16 \times 15 \times 15$ mm with a neck of 7.5 mm) arising from the right ICA C2 segment (Fig. 1A, B). The patient underwent placement of a FD, Surpass Streamline (4×25 mm), combined with coil embolization using 7 detachable coils (Target 360, Stryker Neurovascular, Fremont, CA, USA) (Fig. 1C, D, E). One week after surgery, the patient was discharged without any neurological deficits and was maintained on dual antiplatelet therapy with 100 mg aspirin and 3.75 mg prasugrel.

The patient presented with a slight defect in the right visual field, gait disturbances, and memory loss one month later. Since the symptoms were mild, we followed up on her symptoms on an outpatient basis. However, the symptoms gradually worsened within a month of the last visit, and urinary incontinence was observed. Angiographic images showed a coil composition with a loop at the tip of the aneurysm (Fig. 1F, G). The Goldmann visual field test revealed defects in both visual fields, which were more severe on the right side (Fig. 1J). Fluid-attenuated inversion recovery (FLAIR) MRI detected edema around the

* Correspondence to: Department of Endovascular Surgery, Tokyo Medical and Dental University, 1-5-45 Yushima, Bunkyo-ku, Tokyo 113-8519, Japan.

E-mail address: sumita.nsrq@tmd.ac.jp (K. Sumita).

¹ <https://orcid.org/0000-0001-6969-8046>

² <https://orcid.org/0000-0002-8476-7721>

³ <https://orcid.org/0000-0002-0695-4716>

⁴ <https://orcid.org/0000-0002-5240-6884>

⁵ <https://orcid.org/0000-0002-3077-1821>

⁶ <https://orcid.org/0000-0002-1348-1099>

treated aneurysm along the optic tract, lateral geniculate body, inferior horn of the lateral ventricles, and even the contralateral posterior horn of the lateral ventricles, which was not observed immediately after surgery (Fig. 2A, C). In addition, the ventricles were enlarged with an Evans index (EI) of 0.37 compared with a preoperative FLAIR EI of 0.3 (Fig. 2B, D). No mechanical obstruction of the cerebrospinal fluid (CSF) pathway was detected on cisternography (Fig. 2G). The CSF examination showed a normal level of protein (23 mg/dL), glucose (86 mg/dL), and no increased cells (1 lymphocyte/ μ L). Although the patient was

treated with steroids, the disturbance of consciousness worsened, and the patient underwent ventriculoperitoneal shunt placement three months after the FD placement (Fig. 2H, I). Because both aspirin and prasugrel were in therapeutic range confirmed by point-of-care platelet function tests, we stopped prasugrel before shunt placement for safety.

Angiographic images 1 year after endovascular surgery showed coil compaction with the disappearance of the loop in the space on the tip of the aneurysm, suspected to be due to change in the composition of thrombus inside the aneurysm (Fig. 1H, I). In the FLAIR MR images, the

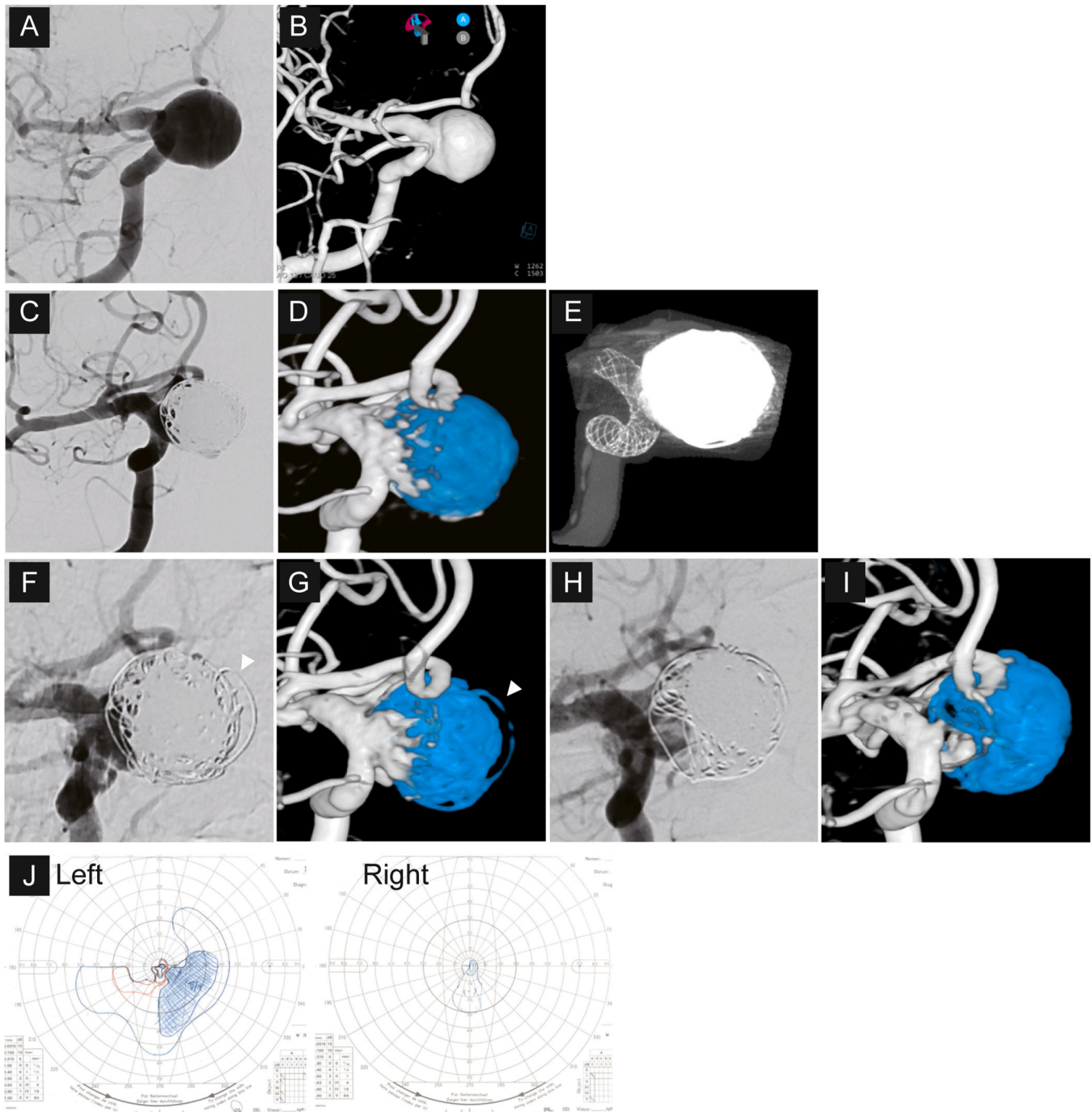


Fig. 1. Images before and after coil embolization and flow diverter placement. A. An angiographic image of the aneurysm before endovascular surgery. B. A 3D-reconstructed image of the aneurysm. C. An angiographic image of the aneurysm after coil embolization. D. A cone-beam computed tomographic image after coil embolization and flow diverter placement. E. A 3D-reconstructed image. Blue indicates the embolized coil. Time course for the change in the shape of treated aneurysm. F-I. Angiographic (F and H) and 3D reconstructed (G and I) images of the aneurysm after endovascular surgery. Blue indicates the embolized coil. F and G: 3 months after endovascular surgery when the symptoms from hydrocephalus were the most severe. The arrowheads indicate a coil loop in the tip of the aneurysm, H and I: 1 year after endovascular surgery. J. The results of the Goldmann visual field test. The test was performed 2 months after endovascular surgery.

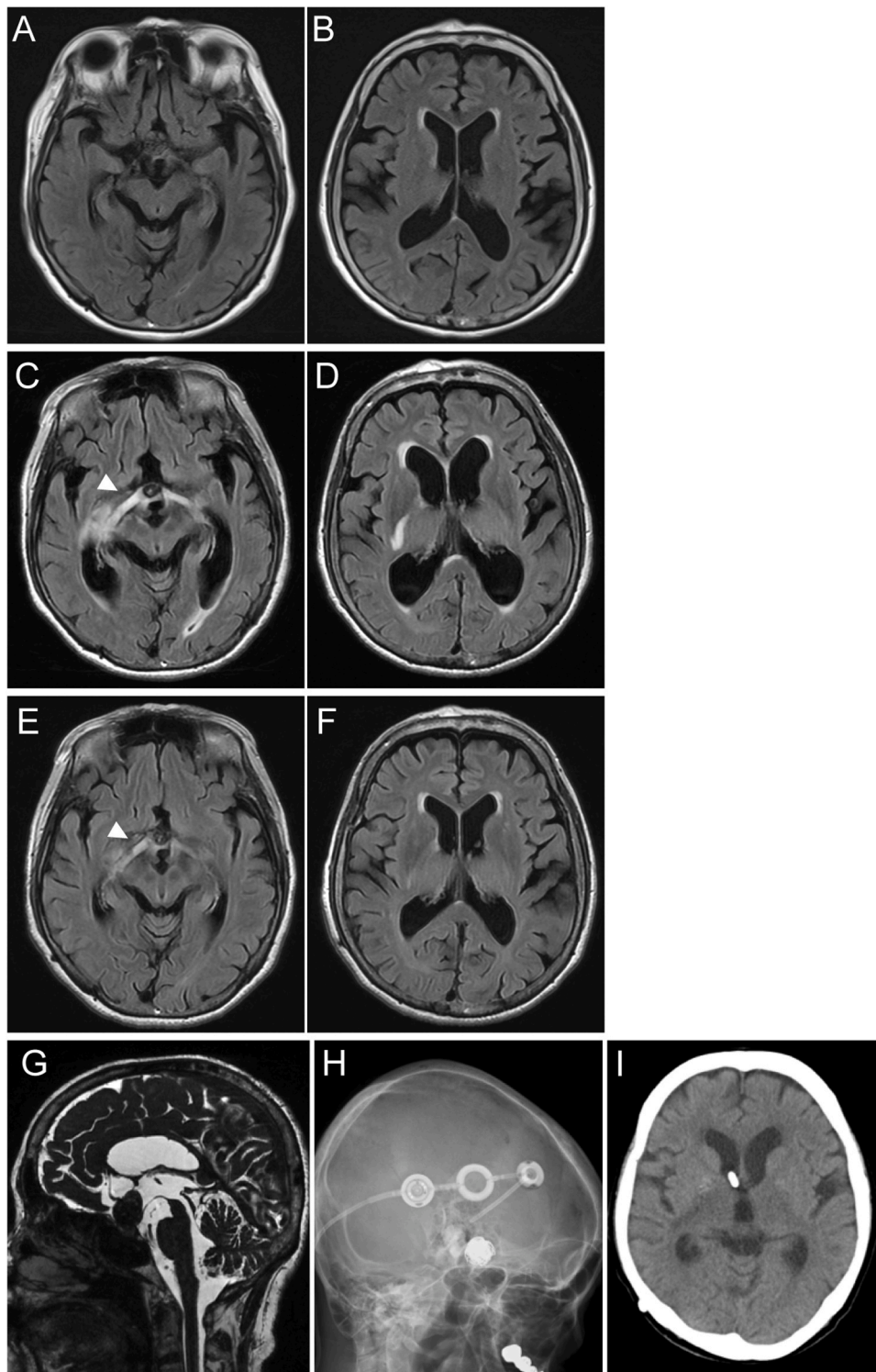


Fig. 2. Time course for edema change around ventricles. A-F. MRI FLAIR images just after flow diverter placement and coil embolization (A, B), just before ventriculoperitoneal shunt (C, D), and 6 months after endovascular surgery or 3 months after shunt placement (E, F). Arrowheads indicate the edema along the optic tract. G. A cisternographic image before shunt placement. H, I. An X-ray image (H) and a CT scan image (I) after shunt placement.

edema clearly decreased, and the ventricles were no longer enlarged (Fig. 2E, F; edema along the optic tract is indicated by arrowheads). The patient almost completely recovered from the hydrocephalus symptoms, and the visual field defect improved slightly.

3. Discussion

Hydrocephalus is a complication of FD placement for large aneurysms. To the best of our knowledge, this is the first report of hydrocephalus as a complication of Surpass Streamline. Five patients from four reports, including ours, had progressive gait disturbances, dementia, or urinary incontinence due to hydrocephalus [2–4]. In all patients,

shunt placement improved symptoms. An increasing number of reports have revealed the possibility of developing hydrocephalus after FD placement; however, the etiology of hydrocephalus development remains unclear.

Fanning et al. reported that aseptic meningitis is associated with the development of hydrocephalus [5]. Indeed, all other cases that developed hydrocephalus after FD placement showed high protein levels without increased cells or decreased glucose in the CSF, indicating aseptic meningitis. Previous reports on hydrocephalus after coil embolization for unruptured aneurysm suggested aseptic meningitis due to inflammatory response from thrombus formation was the cause of hydrocephalus (Table 1) [6–11]. However, in our case, the CSF protein levels were normal, indicating the absence of aseptic meningitis. Several reports have indicated hydrocephalus after coil embolization of unruptured aneurysms without elevated CSF protein levels [12]. They predicted that the use of a hydrogel-coated coil or an inflammatory response due to incomplete occlusion of the aneurysms was the cause of hydrocephalus. Since we did not use a hydrogel-coated coil for embolization, we suspected that the inflammatory response around the treated aneurysm was the cause of the hydrocephalus. In our case, the edema detected on FLAIR images spread from the optic tract, lateral geniculate body, the inferior horn of the lateral ventricles, and even the

contralateral-posterior horn of the lateral ventricles, which was broader than previous report [2]. The severe inflammatory response around the treated aneurysm may have been the cause of hydrocephalus without aseptic meningitis.

All aneurysms in the anterior circulation that developed hydrocephalus after endovascular surgery arose superiorly from the ICA and were physically closer to the ventricles. In addition, all patients underwent FD placement in combination with coil embolization. In one case that followed the aneurysmal size, the diameter temporarily increased, resulting in perianeurysmal edema, and the patient developed a defect in the visual field. The aneurysm was also temporarily enlarged, showing a change in coil composition. Changes in the aneurysm size and coil composition reflect thrombosis in the treated aneurysm. Thrombosis leads to perianeurysmal inflammation, which increases mediators and cytokines in the subarachnoid space, causing edema [13]. When hydrocephalus developed, the coil deformed, and although it appeared to deviate slightly from the original aneurysm, edema may have occurred due to the direct contact of the coil-embolized aneurysm with the optic tract from the thrombosed part. Although the number of cases was small, there may be a correlation between the severity of perianeurysmal inflammation, location of aneurysms, and treatment strategy, leading to the development of hydrocephalus.

Table 1

Literature review of hydrocephalus as late complications in unruptured aneurysms after coil embolization.

author	age/ sex	aneurysm location	aneurysm size	coils	flow diverter	time to postoperative hydrocephalus	shunt placement	predicted cause of hydrocephalus
Meyers et al. (2004)	52/F	paraophthalmic	> 20 mm	BC/ HC/ MC		NA	yes	chemical meningitis
Berenstein et al. (2006)	75/F 46/M 79/M	paraophthalmic ICA PCoA	10-25 mm < 10 mm 10-25 mm	BC/ HC BC/ HC BC/ HC		2.3 months 1.5 months 1 week	yes yes yes	aseptic meningitis due to inflammatory response from HC in two of the three patients
Im et al. (2007)	56/F	ICA	8.2 mm	BC/ HC		6 months	yes	aseptic meningitis due to inflammatory response from HC
Kang et al. (2007)	67/F 64/F 67/F 41/M 51/F	ICA ICA ICA ICA BA	11.4 mm 9.6 mm 3.7 mm 12.4 mm 9.3 mm	BC/ HC BC/ HC BC/ HC BC/ HC		NA NA NA NA NA	no yes yes no yes	aseptic meningitis due to inflammatory response from HC
Mitha et al. (2008)	57/F 56/F	PCoA BA	26 mm 12 mm	BC/ HC BC/ HC		3 weeks 2.5 months	yes yes	impaired CSF absorption due to elusion of the hydrogel polymer or an associated breakdown product into CSF
Fanning et al. (2008)	56/M 67/F 45/F	BA paraophthalmic BA	6 mm 13.2 mm 13.9 mm	BC/ HC BC/ HC BC/ HC		30.6 months 11.8 months 7.8 months	yes no no	inflammatory response from HC
Misaki et al. (2010)	69/F	ICA	18.8 mm	BC		7 months	no	inflammatory response from aneurysm recurrence
Ozaki et al. (2011)	69/F 66/F	PCoA ICA	15 mm 22 mm	BC BC		18 months 18 months	yes yes	aseptic meningitis due to chronic inflammatory response from HC
Zanaty et al. (2014)	75/F	PCoA	12 mm		PED	2.5 months	yes	chronic inflammatory response from HC
Teranishi et al. (2017)	64/M 68/F	ICA ophthalmic	27 mm 16.5 mm		PED PED	11 months 5 months	yes yes	aseptic meningitis due to exaggerated inflammation
Ichinose et al. (2022)	75/F	ICA	21 mm	BC	PED	10 months	yes	aseptic meningitis due to chronic inflammatory response
Present case	69/F	ICA	16 mm	BC	Surpass Streamline	1 month	yes	acute inflammatory response

ICA:internal carotid artery, BA:basilar artery, PCoA:posterior communicating artery, BC:bare platinum coils, HC:HydroCoils, MC:Matrix coils, NA:not available, PED:pipeline embolization device

In our case, the patient started to show gait disturbance and dementia only 1 month after endovascular surgery. Previous cases showed symptoms of hydrocephalus within 2.5–14 months. The short time course until the appearance of symptoms also supports our hypothesis that the cause of hydrocephalus was not a chronic inflammatory response leading to aseptic meningitis, but rather an acute response. The precise mechanisms are unclear; however, our report suggests a potentially different mechanism for the development of hydrocephalus after FD placement combined with coil embolization compared with previous reports.

4. Conclusion

Herein, we present the case of a patient who developed hydrocephalus as a complication of FD placement combined with coil embolization. Although the mechanism is unclear, we suggest that severe perianeurysmal inflammation alone, without aseptic meningitis, could lead to the acute onset of hydrocephalus. Further research and accumulation of case reports are necessary to clarify the pathophysiological mechanisms underlying the development of hydrocephalus after FD placement in combination with coil embolization.

Author contributors

Dr. Takahashi and Ishikawa contributed to the conception and design of the study, data acquisition, drafting of the manuscript. Dr. Sumita contributed to the design of the study, data acquisition, and drafting of the manuscript. Drs. Sagawa, Wakabayashi, Fujii, Fujita, Aoyama and Hirai contributed to data interpretation and critical revision of the manuscript for important intellectual content.

Funding

This research received no specific grant from any funding agency in the public, commercial or not-for-profit sectors.

CRediT authorship contribution statement

Sumita Kazutaka: Conceptualization, Supervision, Writing – original draft, Data curation. **Wakabayashi Hikaru:** Data curation, Writing – review & editing. **Sagawa Hirotaka:** Data curation, Writing – review & editing. **Ishikawa Mariko:** Conceptualization, Data curation, Writing – original draft. **Takahashi Satoru:** Conceptualization, Data curation, Writing – original draft. **Hirai Sakyo:** Writing – review & editing. **Aoyama Jiro:** Writing – review & editing. **Fujita Kyohei:** Writing – review & editing. **Fujii Shoko:** Writing – review & editing.

Acknowledgments

None.

Patient consent

We obtained written consent from the patient. This is available on

request.

Disclosure statement

K.S received lecture fees from Stryker. The other authors have no potential conflict of interest.

References

- [1] P.M. Meyers, A.L. Coon, P.T. Kan, A.K. Wakhloo, R.A. Hanel, SCENT trial: one-year outcomes, *Stroke* 50 (2019) 1473–1479, <https://doi.org/10.1161/STROKEAHA.118.024135>.
- [2] T. Ichinose, K. Misaki, N. Uchiyama, T. Kamide, I. Nambu, A. Yoshikawa, S. Tsuchiya, M. Nakada, Late complications of visual impairment and hydrocephalus after flow diverter-assisted coil embolisation for intracranial large aneurysm: a case report and literature review, *Br. J. Neurosurg.* 0 (2022) 1–5, <https://doi.org/10.1080/02688697.2021.2024502>.
- [3] M. Zanaty, M.B. Khan, N. Chalouhi, S.I. Tjoumakaris, R.H. Rosenwasser, P. Jabbour, Development of normal pressure hydrocephalus after the placement of a pipeline embolization device for the treatment of a large aneurysm: Case report, *Clin. Neurol. Neurosurg.* 122 (2014) 116–119, <https://doi.org/10.1016/j.clineuro.2014.04.006>.
- [4] K. Teranishi, K. Yatomi, Y. Mitome-Mishima, N. Sugiyama, M. Yamamoto, H. Oishi, Delayed hydrocephalus after combined treatment with pipeline embolization device and platinum coil for large unruptured intracranial aneurysm: a report of two cases, *J. Neuroendovascular Ther.* 12 (2018) 148–152, <https://doi.org/10.5797/jnet.cr.2017-0076>.
- [5] N.F. Fanning, R.A. Willinsky, K.G. TerBrugge, Wall enhancement, edema, and hydrocephalus after endovascular coil occlusion of intradural cerebral aneurysms, *J. Neurosurg.* 108 (2008) 1074–1086, <https://doi.org/10.3171/JNS/2008/108/6/1074>.
- [6] P.M. Meyers, S.D. Lavine, B.-F. Fitzsimmons, C. Commichau, A. Parra, S.A. Mayer, R.A. Solomon, C.E. Sander Jr, Chemical meningitis after cerebral aneurysm treatment using two second-generation aneurysm coils: report of two cases, *Neurosurgery* 55 (2004) 1222, <https://doi.org/10.1227/01.neu.0000140987.71791.df>.
- [7] A. Berenstein, J.K. Song, Y. Niimi, K. Namba, N.S. Heran, J.L. Brisman, M. C. Nahoum, M. Niimi, D.J. Langer, M.J. Kupersmith, Treatment of cerebral aneurysms with hydrogel-coated platinum coils (HydroCoil): early single-center experience, *Am J Neuroradiol.* (2006) 1834–1840. (<http://www.ajnr.org/content/27/9/1834>).
- [8] S.-H. Im, M.H. Han, B.J. Kwon, C. Jung, J.E. Kim, D.H. Han, Aseptic meningitis after embolization of cerebral aneurysms using hydrogel-coated coils: eeport of three cases, *Am. J. Neuroradiol.* 28 (2007) 511–512. (<http://www.ajnr.org/content/28/3/511>).
- [9] H.-S. Kang, M.H. Han, T.H. Lee, Y.S. Shin, H.G. Roh, O.-Ki Kwon, B.J. Kwon, S. Y. Kim, S.H. Kim, H.S. Byun, Embolization of intracranial aneurysms with hydrogel-coated coils, *Result a Korean Multicent.* Trial 61 (2008) 51–59, <https://doi.org/10.1227/01.neu.0000279723.67779.f0>.
- [10] K. Misaki, N. Uchiyama, M. Mohri, Y. Hirota, Y. Hayashi, J.I. Hamada, Unusual delayed hydrocephalus after bare platinum coil embolization of an unruptured aneurysm, *Neurol. Med. Chir. (Tokyo).* 50 (2010) 581–585, <https://doi.org/10.2176/nmc.50.581>.
- [11] M. Ozaki, Y. Murayama, M. Ebara, H. Takao, T. Abe, Delayed hydrocephalus after embolization of unruptured aneurysms using bare platinum coils: report of 2 cases, *Am. J. Neuroradiol.* 32 (2011) 188–190, <https://doi.org/10.3174/ajnr.A2317>.
- [12] A.P. Mitha, J.H. Wong, J.Q. Lu, W.F. Morrish, M.E. Hudon, W.Y. Hu, Communicating hydrocephalus after endovascular coiling of unruptured aneurysms: report of 2 cases, *J. Neurosurg.* 108 (2008) 1241–1244, <https://doi.org/10.3171/JNS/2008/108/6/1241>.
- [13] R.D. Turner, L.D.B. Da Costa, K.G. TerBrugge, A multicenter registry of hydrocephalus following coil embolization of unruptured aneurysms: which patients are at risk and why it occurs, *J. Neurointerv. Surg.* 5 (2013) 207–211, <https://doi.org/10.1136/neurintsurg-2011-010194>.