

Received: 2023.10.18

Accepted: 2024.01.01

Available online: 2024.01.05

Published: 2024.02.15

# Anesthetic Considerations for Patients with Locked-In Syndrome Undergoing Endoscopic Procedures

## Authors' Contribution:

Study Design A  
Data Collection B  
Statistical Analysis C  
Data Interpretation D  
Manuscript Preparation E  
Literature Search F  
Funds Collection GAEF 1 **Monique T. Barakat**AE 1 **Subhas Banerjee**AEF 2 **Timothy Angelotti**

1 Department of Internal Medicine, Division of Gastroenterology and Hepatology, Stanford University, Stanford, CA, USA

2 Department of Anesthesiology, Perioperative and Pain Medicine, Stanford University, Stanford, CA, USA

**Corresponding Author:** Timothy Angelotti, e-mail: [timangel@stanford.edu](mailto:timangel@stanford.edu)**Financial support:** None declared**Conflict of interest:** None declared**Patient:** Female, 38-year-old  
**Final Diagnosis:** Locked-in syndrome  
**Symptoms:** Locked-in syndrome  
**Clinical Procedure:** Colonoscopy  
**Specialty:** Anesthesiology**Objective:** Rare disease**Background:** Delivering safe anesthetic care to a patient unable to communicate easily and effectively with the anesthesia team presents many unique challenges. Communication may be limited by language, which can be resolved with translation services, or neurological conditions, such as stroke or traumatic brain injury, which are not easily remedied. In such patients, the inability to communicate effectively can lead to anxiety and negatively impact the patient-anesthesiologist relationship, especially when higher cognitive functions are preserved.**Case Report:** We present a case of a patient with locked-in syndrome (LIS), who presented to our endoscopy unit for a routine colonoscopy. The patient could only communicate with eye movements and blinking, thus limiting our ability to assess their pain or other needs in the perioperative period; however, she was otherwise cognitively intact. By utilizing the patient's home healthcare team and quickly adapting their unique communication methods during the perioperative period, we were able to provide an appropriate, safe anesthetic for this patient with LIS.**Conclusions:** Many patients requiring an anesthetic are unable to effectively communicate due to language issues, hearing loss/mutism, neurological injury/stroke (aphasia), or developmental disabilities. The unique communication needs of this patient with LIS went beyond utilizing a translator and required the healthcare team to quickly learn a new communication method. We also discuss forms of intraoperative monitoring that can be used to differentiate consciousness from the anesthetized state in LIS patients, as well as making recommendations for future care of such patients.**Keywords:** Anesthesiology • Colonoscopy • Communication Aids for Disabled • Communication Barriers • Endoscopy, Gastrointestinal • Locked-In SyndromeFull-text PDF: <https://www.amjcaserep.com/abstract/index/idArt/942906>


2984



—



3



21



Publisher's note: All claims expressed in this article are solely those of the authors and do not necessarily represent those of their affiliated organizations, or those of the publisher, the editors and the reviewers. Any product that may be evaluated in this article, or claim that may be made by its manufacturer, is not guaranteed or endorsed by the publisher

## Background

Effective communication with patients during the perioperative period is critical for obtaining informed consent for the anesthetic plan, answering questions of the patient/family, and, most importantly, for developing a trustful patient–anesthesiologist connection. Communication between patient and anesthesiologist can be limited by language, inability to hear or speak, and other neurological conditions (eg, stroke or traumatic brain injury). Inability of a patient to communicate effectively can be anxiety-inducing for them and their family and can negatively impact the patient–anesthesiologist relationship. In such situations, general endotracheal anesthesia (GEA) may appear to be the appropriate anesthetic choice over monitored anesthesia care (MAC) due to the inability to easily communicate with a sedated patient during the procedure. However, GEA may be excessive for certain surgeries or procedures, exposing the patient to unnecessary risks.

Locked-in syndrome (LIS) is a neurological condition of quadriplegia with preserved consciousness, in which the ability to communicate is commonly limited to vertical eye movements and eyelid blinking. LIS occurs in patients as a rare outcome of brain injury due to a brainstem or pontine lesion, most commonly a basilar artery occlusion or pontine hemorrhage, but LIS can also occur in the setting of neurodegenerative conditions, including amyotrophic lateral sclerosis [1-3]. Though first described in 1844 by Alexandre Dumas in his novel *“The Count of Monte Cristo,”* where a character, Monsieur Noirtier de Villefort, is depicted as “a corpse with living eyes,” the medical condition, now known as LIS, was not described in the medical literature until 1941 [4]. However, the term LIS was not introduced into the clinical literature until 1966 [5] and subsequently, various subtypes of LIS have been proposed [6]. LIS has been noted to have 5 characteristics: sustained eye opening, preserved basic cognitive abilities, aphonia or severe hypophonia, quadriplegia/quadruparesis, and vertical or lateral eye movements as a means of communication [7].

Initially, long-term survival of patients with LIS due to a brain lesion was estimated to be 60%, but introduction of early rehabilitation and effective nursing care have reduced mortality to 14% at 5 years [2,8]. Many patients with LIS live at home but require continuous homecare from family members and/or healthcare professionals. Communication is paramount for proper care of LIS patients. The use of a simple code based upon groupings of vowel/consonants (ie, the AEIOU alphabet board) can be utilized by LIS patients with their caregivers to spell words, using a combination of eyelid blinking and vertical eye movements (Figure 1) [2,9]. Amazingly, this system can become a fast method of communication for those trained in it. The development of advanced communication methods has become a focus for effective LIS patient care, ranging from patient–computer interfaces

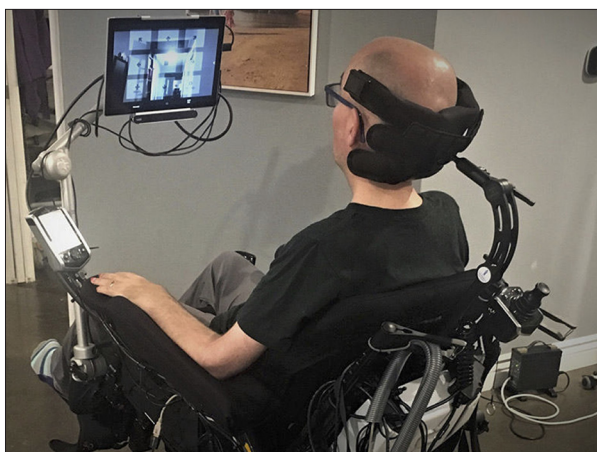A	B	C	D	End of word	
E	F	G	H	End of sentence	
I	J	K	L	M	N
O	P	Q	R	S	T
U	V	W	X	Y	Z

**Figure 1.** An AEIOU alphabet board. To use the board, an assistant calls out the colors and the patient signals the required color by a pre-selected eye movement (usually upward). The assistant then calls out the letters sequentially on that line, allowing the patient to select the letter by their eye movement. Chosen letters are written down to formulate a sentence, question, or answer. With experience, the board may not be required. Different combinations of letters have been used by others, often arranged in order of their frequency.

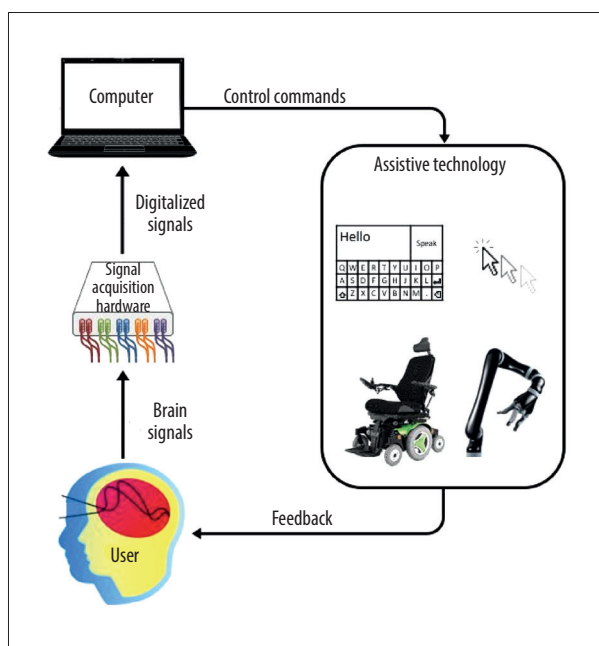
that track eye movement with infrared sensors to brain-computer interface (BCI) technology that utilizes brain waves, to control a keyboard and computer voice prosthetics (Figures 2, 3) [10-12]. However, these systems may not be easily adapted to patient care within a hospital setting, especially in pre-procedure, procedural, and post-procedural areas.

Given the overall increased survival of patients with LIS, more of them will need surgeries or procedures that require administration of an anesthetic. However, the ability to communicate with an LIS patient or assess their pain or other needs in the perioperative period is limited, unless providers are skilled in the alternative communication methods mentioned above. Challenges encountered in both the pre-operative and post-operative phase using available computer-based communications systems include the fact that health care workers are not typically trained in using these systems, calibration features may be restricted to use by family members who may not be present in the pre-operative area, and the systems are not easily portable, limiting their usefulness in the peri-operative setting. Challenges specific to the perioperative and post-operative period include the fact that BCI technology may be negatively impacted by anesthetic or sedative drugs. Descriptions of LIS patients in the anesthesiology literature have been limited to case reports of transient LIS induced by local anesthetic toxicity [13-15]. For surgeries that require GEA, many of the issues of communication and pain assessment are mitigated by the anesthetic. However, LIS patients may require procedures in which MAC would be an appropriate choice, but possibly difficult given the communication gap between the patient and untrained healthcare providers.

In this case report, we present a patient with LIS who underwent a colonoscopy with a MAC anesthetic. There was concern



**Figure 2.** An example of advanced eye tracking technology for patient communication and mobility. The keyboard is controlled by eye movement, which is usually preserved in patients with LIS, and can be used for communication or control of other devices such as a wheelchair. (Photo courtesy of THHS (The Homecare Industry Information Service) trade magazine).



**Figure 3.** A schematic of a Brain Computer Interface for patient communication or control of assistive devices. The user produces brain signals that are processed by computer to infer a control command to speak or to control an object. (Figure modified from OHSU REKNEW).

expressed by the patient, her family, and other healthcare providers that a MAC anesthetic may not be appropriate given her overall neurological condition, but a GEA for a colonoscopy seemed to be unnecessary. Upon further discussion with all involved, a plan was developed that specifically focused on

perioperative aspects of their care and the patient's communication needs, allowing for a MAC anesthetic to be safely administered. Written Health Insurance Portability and Accountability Act authorization and patient consent were obtained for publication of this case report, with the patient confirming her consent via the AEIOU alphabet board and her husband signed the paper consent form on her behalf.

## Case Report

A 50-year-old, 65-kg woman presented to the Endoscopy Unit for an outpatient colonoscopy to further evaluate a positive fecal immunochemical test (FIT). The patient had sustained bilateral pontine, left cerebellar, right thalamic, and bilateral posterior occipital infarcts due to a left vertebral artery dissection and basilar artery thrombosis in 2010. These injuries resulted in LIS with spasticity and complete paralysis of all voluntary muscles, except for eye movement. She was wheelchair-bound and required continuous care and supervision at home, provided by family and home healthcare nurses. She received nutrition through a gastrostomy tube due to difficulty swallowing. Her other medical history was notable for hypertension (controlled on medication), hyperlipidemia, history of deep venous thromboses (now off anti-coagulation), and bilateral sensory hearing loss (separate from LIS). Though she was non-verbal, she was conscious and could briskly communicate via eye movements with her family and caregivers using an AEIOU alphabet board to confirm her understanding of the procedure and its associated risks [2]. No formal assessment of her cognitive abilities was made, but she asked detailed questions about the procedure and anesthetic and had been previously deemed competent to make her own medical decisions for her prior and upcoming surgeries. Her airway exam revealed a Mallampati score of II, a thyromental distance of >3 fingerbreadths, with normal oropharyngeal and neck anatomy, and submandibular compliance.

Two anesthetic plans were presented to the patient, GEA and MAC, and the pros and cons of each were discussed with the assistance of her home healthcare providers and spouse. Since the planned procedure was a colonoscopy and not an upper endoscopy, GEA was deemed to not be required for the procedure. However, the patient had concerns about undergoing the procedure with a MAC anesthetic. The ability to communicate with a patient while initiating sedation was a concern, given that none of her hospital-based medical providers were proficient in use of the AEIOU alphabet board that she used for communication. After further discussion, it was agreed that the home healthcare nurse would be allowed into the endoscopy suite to facilitate communication with the patient and make her less anxious, without the need for anxiolytic drugs. The home healthcare nurse would leave the room once the

patient was appropriately sedated and thus non-communicative, similar to what is done for many pediatric patients when accompanied by their parents for anesthetic administration.

Prior to administration of any anesthetic agents, we established certain key questions that we would ask during the procedure to assess her state of pain control, anxiolysis, and consciousness as sedation was initiated (eg, are you feeling pain, anxiety, or require more sedation?). She would respond with eye blinking, once for 'yes' and twice for 'no'. The anesthetic goal was deep sedation, but not comparable to general endotracheal anesthesia, with good analgesic coverage to limit the occurrence of pain or discomfort. Given the duration of the procedure, we chose not to use a sedation scale (eg, Modified Ramsay Sedation Score). Additionally, sedation scales may not be appropriate in this patient population, since many of them depend upon patient movement, beyond eye movement, to properly utilize the scale [16]. The patient was transported to the procedure room and after application of standard ASA monitors, she was turned onto her left side in a head-elevated position, and an oxygen mask was placed on her face (10 l/m). She was then administered 60 mg of IV lidocaine prior to receiving a continuous infusion (90 mcg/kg/min) and boluses (40 mg) of propofol. Additionally, she received fentanyl (50 mcg), ondansetron (4 mg), and dexamethasone (4 mg).

Propofol was titrated until the patient would open her eyes to a strong stimulus, but not to voice. When her eye opening became sluggish in response to a glabellar tap, the colonoscope was inserted and if she did not respond, then the procedure was allowed to proceed. If she opened her eyes spontaneously during the procedure, she was then asked if she was experiencing pain or wanted more sedation, as described above, and was then treated accordingly. Though traditional MAC implies vital sign and patient monitoring, patient monitoring was limited due to LIS. Given the duration of the case and experience of the endoscopist and anesthesiologist with patients with other neurological conditions (eg, quadriplegia), we were comfortable assessing the patient despite our limited assessment methodology.

At the end of the procedure, the patient was minimally arousable, but was stable with respect to hemodynamics and ventilation. She tolerated the procedure well without any apparent respiratory or cardiovascular complications or issues. Following the procedure, she was brought to the PACU, where we had arranged for her home healthcare nurse to be already present to assist in communication with the PACU nurse. The patient recovered from her MAC anesthetic approximately 15 minutes following discontinuation of propofol and was able to quickly communicate with her caregiver. Of note, the patient returned to our facility 1 year later to undergo a tympanoplasty to address her sensorineural hearing loss, a surgery for which she received a GEA without complication.

## Discussion

Many patients who present for a procedure that requires an anesthetic are unable to effectively communicate with their healthcare teams, either due to a language issue, hearing loss/mutism, neurological injury/stroke (aphasia), or developmental disabilities. However, many alternative communication methods are available for these patients, from foreign language translators for non-English speakers, to sign language/written communication for mute or deaf patients. Despite potential communication concerns with such patients, a MAC anesthetic is commonly administered unless a GEA is required due to the surgical procedure.

The ability to assess whether a patient is feeling pain during a procedure is a concern for anesthesiologists, especially for a patient unable to communicate. In a case report of an LIS patient undergoing sacral ulcer debridement, the MAC anesthetic plan included use of a bispectral (BIS) monitor to assess the anesthetic state of the patient in the operating room (OR) and post-anesthesia care unit (PACU) [17]. In that report, the authors describe how targeting a BIS value of 40-60 during anesthesia allowed them to differentiate between an anesthetized vs an awake state, despite the patient's eyes being closed. The BIS range was chosen following a 2-hour observation period of the patient to assess bispectral index (BIS) values for awake/asleep with eyes open and awake/asleep with eyes closed. The BIS observation protocol was implemented in part since the patient was expected to undergo multiple debridements and would require multiple anesthetics.

Our patient was not undergoing a potentially painful surgical procedure (such as debridement), but a routine colonoscopy, which can be done with an MAC anesthetic or even minimal or no conscious sedation. We did not deem this procedure to be painful on the same scale as traditional surgery. Therefore, we decided not to utilize BIS or other similar neurophysiological monitoring for this procedure. Sedation scales were not completely applicable since many of them depend upon patient movement beyond eye movement, as mentioned above. Instead, we developed our own monitoring methodology using a stimulus (eg, glabellar tap) combined with a simple set of "yes/no" questions surrounding pain, anxiety, or sedation. Most importantly, we spent time with the patient prior to administering any medications to devise our impromptu protocol. By developing a trusting rapport with the patient, we were able to quickly develop our own monitoring methodology. However, if neurophysiological monitoring was to be used, then an observational period as described above would be necessary to determine if this monitor can differentiate between the different states of consciousness or the anesthetized state. The need for such an observational period would further complicate planning for a short 30-minute procedure such as a colonoscopy.

A patient with LIS presents with not only a communication deficit but also quadriplegia/paresis and other neurological issues described above, in the setting of maintained consciousness. Despite the constellation of medical and communication issues, patients with LIS should be suitable candidates for MAC anesthesia. Given the limited ability of LIS patients to communicate, we planned to administer a short-acting MAC anesthetic, avoiding anxiolytics such as benzodiazepines. By doing so, the patient was able to clearly communicate 15 minutes after stopping the propofol infusion.

There are few published case reports in the anesthesia literature concerning anesthetic care for patients with communication deficits (eg, deaf or mute), and the communication issues that can arise with such patients [18]. One case report was met with controversy over its negative comments about the utility of American Sign Language (ASL) in such clinical situations [19]. Many federal laws (eg, the US Civil Rights Act of 1964 Title VI and Executive Order 13166) require hospitals to have translation services available in person or by phone for most situations, including American Sign Language, but communication with LIS patients requires specialized training beyond standard translation services [20].

Unfortunately, most of the BCI devices being developed require either a camera to monitor head or eye movements, combined with a computer screen and interface, or specialized brainwave monitoring with either external or implanted electrodes [11,12,21]. Such communication set-ups are usually utilized by the patient while either seated in a chair, bed, or motorized wheelchair, and are not amenable for use within an operating or procedure room due to their size and the need for the patient to be placed on an operating room table. Despite its simplicity, an AEIOU alphabet board can be imposing to utilize if untrained in their use. However, we found it to be easy to learn for basic communication needs, as described in **Figure 1**. Once the anesthesiologist has established the eye movements that the patient will use to communicate, simple questions can be answered even for those unfamiliar with their use. Additionally, simple cue cards with words such as “pain” or “nausea” can be produced readily to deal with such concerns, using yes/no answers. Due to the high patient turnover and dense scheduling of our endoscopy unit, we opted to ask the patient’s home healthcare team to assist with communication during the perioperative period. Despite our limited training, we felt comfortable enough to use the AEIOU alphabet board if needed.

## Conclusions

Overall, patient-centered concerns for LIS include ensuring that healthcare providers unfamiliar with the patient do not make assumptions about the ability of a patient to feel pain

or discomfort and that proper control of pain or discomfort occurs during and after any procedure. However, the healthcare team needs to ensure that such communication extends from the pre-operative holding area to the PACU. We accomplished this goal by arranging for the patient’s home healthcare nurse to be involved in the pre- and post-anesthesia care of the patient to assuage any fears or concerns of the patient. However, an AEIOU alphabet board was available, and we were quickly trained in its basic use. However, the most difficult portion of administering an MAC anesthetic to a patient with LIS is the determination of pain or discomfort. Based on our experience and case reports in the literature, we recommend the following:

1. The healthcare team and procedural area staff caring for an LIS patient should be made aware by the scheduling office of the planned anesthetic prior to the day of surgery. If a pre-anesthesia clinic is involved with patient care, then they should inform the procedural area of the scheduled LIS patient, so that appropriate staffing and room plans can be arranged ahead of time to prevent same-day delays.
2. Inquire about communication assistance from members of the patient’s home care team and/or family for the perioperative period, possibly assisting in the operating or procedure room until induction and in the PACU following the anesthetization. This plan can be implemented for either a GEA or MAC anesthetic. If comfortable, the healthcare team can use an AEIOU alphabet board.
3. Prior to initiating the anesthetic, establish simple questions about pain, sedation, and anxiety that can be answered by the patient eye-blinking ‘yes’ or ‘no.’ The questions will be important for intraoperative and post-operative care assessment. Use of an AEIOU alphabet board may be limited until the patient reaches a state of more complete wakefulness.
4. Consider using a BIS monitor or other neurophysiological monitoring device for more painful procedures performed under an MAC anesthetic. This plan may require pre-procedure testing to determine the range of values that represent awake or asleep, regardless of eye opening [17]. If such methods are not readily available or if the situation requires an urgent surgery or procedure, then general endotracheal anesthesia may be a better choice over MAC to ensure control of pain or discomfort.
5. Limit anesthetic drug choices to those drugs with the shortest duration of action to ensure that the patient awakens quickly and with minimal residual sedative effect to enable early communication.

## Declaration of Figures’ Authenticity

Figure 1 submitted have been created by the authors who confirm that the images are original with no duplication and have not been previously published in whole or in part. Figures 2 and 3 published under permission.

## References:

1. Laureys S, Pellas F, Van Eeckhout P, et al. The locked-in syndrome: What is it like to be conscious but paralyzed and voiceless? *Prog Brain Res.* 2005;150:495-511
2. Smith E, Delargy M. Locked-in syndrome. *BMJ.* 2005;330(7488):406-9
3. Khalili-Ardali M, Wu S, Tonin A, et al. Neurophysiological aspects of the completely locked-in syndrome in patients with advanced amyotrophic lateral sclerosis. *Clin Neurophysiol.* 2021;132(5):1064-76
4. Cairns H, Olfield R, Pennybacker JB. Akinetic mutism with an epidermoid cyst of the 3<sup>rd</sup> ventricle. *Brain.* 1941;64:273-80
5. Plum FF, Posner JD. The diagnosis of stupor and coma. Philadelphia: FA Davis Co.; 1966
6. Bauer G, Gerstenband F, Rimpl E. Varieties of locked-in syndrome. *J Neurol.* 1979;221:77-91
7. Recommendations for use of uniform nomenclature pertinent to patients with severe alterations in consciousness. American Congress of Rehabilitation Medicine. *Arch Phys Med Rehabil.* 1995;76:205-9
8. Casanova E, Lazzari RE, Lotta S, Mazzucchi A. Locked-in syndrome: improvement in the prognosis after an early intensive multidisciplinary rehabilitation. *Arch Phys Med Rehabil.* 2003;84(6):862-67
9. Leon-Carrion J, van Eeckhout P, Dominguez-Morales Mdel R. The locked-in syndrome: A syndrome looking for a therapy. *Brain Inj.* 2002;16(7):555-69
10. Doble JE, Haig AJ, Anderson C, Katz R. Impairment, activity, participation, life satisfaction, and survival in persons with locked-in syndrome for over a decade: Follow-up on a previously reported cohort. *J Head Trauma Rehabil.* 2003;18(5):435-44
11. Koch Fager S, Fried-Oken M, Jakobs T, Beukelman DR. New and emerging access technologies for adults with complex communication needs and severe motor impairments: State of the science. *Augment Altern Commun.* 2019;35(1):13-25
12. Chaudhary U, Vlachos I, Zimmermann JB, et al. Spelling interface using intracortical signals in a completely locked-in patient enabled via auditory neurofeedback training. *Nat Commun.* 2022;13(1):1236
13. Durrani Z, Winnie AP. Brainstem toxicity with reversible locked-in syndrome after intrascapular brachial plexus block. *Anesth Analg.* 1991;72(2):249-52
14. Dukes RR, Alexander LA. Transient locked-in syndrome after vascular injection during stellate ganglion block. *Reg Anesth.* 1993;18(6):378-80
15. Tuz M, Erodlu F, Dodru H, et al. Transient locked-in syndrome resulting from stellate ganglion block in the treatment of patients with sudden hearing loss. *Acta Anaesthesiol Scand.* 2003;47(4):485-87
16. De Jonghe B, Cook D, Appere-De-Vecchi C, et al. Using and understanding sedation scoring systems: A systematic review. *Intensive Care Med.* 2000;26(3):275-85
17. Yoo C, Ayello EA, Robins B, et al. Perioperative use of bispectral (BIS) monitor for a pressure ulcer patient with locked-in syndrome (LIS). *Int Wound J.* 2014;11(5):540-45
18. Shulman SM, Polepalle S. Spinal anesthesia for a deaf-mute patient undergoing prostatic surgery. *Anesthesiology.* 1993;78(3):590-91
19. Snyder FL, Dwersteg JF. Anesthetic care and management of patients who are deaf and mute. *Anesthesiology.* 1993;79(2):408-9
20. Ramirez N, Shi K, Yabroff KR, et al. Access to care among adults with limited English proficiency. *J Gen Intern Med.* 2023;38(3):592-99
21. Branco MP, Pels EGM, Sars RH, et al. Brain-computer interfaces for communication: preferences of individuals with locked-in syndrome. *Neurorehabil Neural Repair.* 2021;35(3):267-79