

Serpent Strikes, Sapien Sways: A Rare Case of Bilateral Cerebellar Infarct following Viper Bite

K. M. Srinath, Mahim Sethi, B. Madhu¹, M. C. Prasad, Sunila B. Sangappa²

Departments of General Medicine, ¹Community Medicine and ²Prosthodontics, JSS Medical College and Hospital, JSSAHER, Mysore, Karnataka, India

Abstract

Ischemic stroke following snake bite is rare. We report a posterior circulation infarct involving bilateral cerebellum and occipital lobe following Russell's viper bite in a previously healthy individual. A 50 years old healthy individual, soon after being bitten by the Russel viper on the left foot he developed pain and swelling followed by drooping of eyelids, slurring of speech and giddiness with multiple episodes of vomiting. The patient was administered ASV as well as neostigmine and atropine injections. Following this, the neurological manifestations resolved except dysarthria. CT brain study done was normal. On day 2 of hospitalization, he developed left cerebellar signs (positive finger nose finger test, rebound phenomenon, dysdiadochokinesia, a positive heel shin test). Subsequently, an MRI with MR angiogram was done which showed acute infarcts in bilateral cerebellar hemispheres, with the left superior cerebellar peduncle showing restricted diffusion and low ADC values. Ischemic infarction following viper envenomation has been described by only few authors. In majority of the cases reported, ischemic infarction involved the anterior circulation. The possible mechanisms of infarction in this scenario are discussed. Patient was treated with anti-snake venom and showed a good recovery. Early imaging and early treatment with anti-snake venom is important for a favourable outcome.

Keywords: Cerebellar infarct, magnetic resonance imaging brain study, viper bite

Résumé

L'AVC ischémique consécutif à une morsure de serpent est rare. Nous rapportons un infarctus de la circulation postérieure impliquant le cervelet et le lobe occipital bilatéraux suite à une morsure de vipère de Russell chez un individu auparavant en bonne santé. Un individu en bonne santé de 50 ans, peu de temps après avoir été mordu par la vipère Russel au pied gauche, il a développé une douleur et un gonflement suivis d'un affaissement des paupières, d'un trouble de l'élocution et de vertiges avec de multiples épisodes de vomissements. Le patient a reçu de l'ASV ainsi que des injections de néostigmine et d'atropine. Suite à cela, les manifestations neurologiques ont disparu sauf la dysarthrie. L'étude cérébrale réalisée par TDM était normale. Au 2ème jour d'hospitalisation, il a développé des signes cérébelleux gauches (test doigt nez doigt positif, phénomène de rebond, dysdiadochokinésie, test talon tibia positif). Par la suite, une IRM avec angiographie IRM a été réalisée qui a montré des infarctus aigus dans les hémisphères cérébelleux bilatéraux, le pédoncule cérébelleux supérieur gauche montrant une diffusion restreinte et de faibles valeurs d'ADC. L'infarctus ischémique consécutif à une envenimation par vipère n'a été décrit que par quelques auteurs. Dans la majorité des cas rapportés, l'infarctus ischémique impliquait la circulation antérieure. Les mécanismes possibles de l'infarctus dans ce scénario sont discutés. Le patient a été traité avec du venin anti-serpent et a montré une bonne récupération. Une imagerie précoce et un traitement précoce avec du venin anti-serpent sont importants pour un résultat favorable.

Mots-clés: Infarctus cérébelleux, étude cérébrale par imagerie par résonance magnétique, morsure de vipère

INTRODUCTION

Snakebite is an acute, life-threatening, and time-limited medical emergency. Viperidae species consisting of Russell's viper and saw-scaled viper are the leading cause of fatal snakebite in India.^[1] Snake venoms consist of highly complex mixtures of enzymes, polypeptides, glycoproteins, and other constituents.

Address for correspondence: Dr. M. C. Prasad,

Department of General Medicine, JSS Medical College and Hospital,
JSSAHER, Mysore, Karnataka, India.
E-mail: drprasadmc@gmail.com

This is an open access journal, and articles are distributed under the terms of the Creative Commons Attribution-NonCommercial-ShareAlike 4.0 License, which allows others to remix, tweak, and build upon the work non-commercially, as long as appropriate credit is given and the new creations are licensed under the identical terms.

For reprints contact: WKHLRPMedknow_reprints@wolterskluwer.com

How to cite this article: Srinath KM, Sethi M, Madhu B, Prasad MC, Sangappa SB. Serpent strikes, sapien sways: A rare case of bilateral cerebellar infarct following viper bite. Ann Afr Med 2024;23:104-6.

Submitted: 26-Mar-2023

Revised: 02-Jun-2023

Accepted: 12-Jun-2023

Published: 12-Feb-2024

Access this article online

Quick Response Code:



Website:
www.annalsafmed.org

DOI:
10.4103/aam.aam_44_23

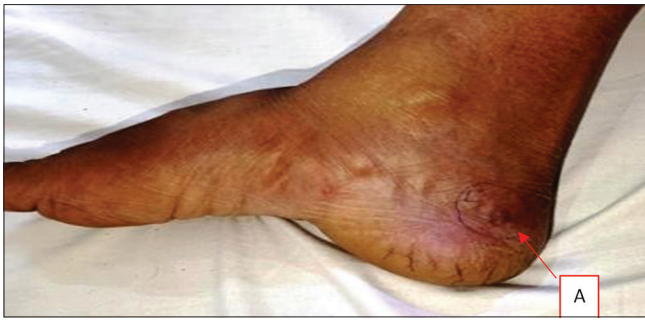

Figure 1: Viper bite mark at medial surface of foot

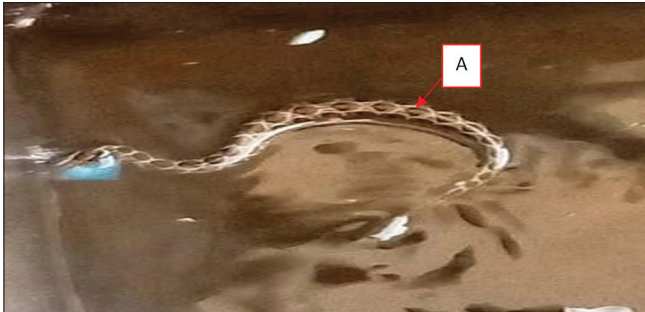


Figure 2: Viper snake found in water

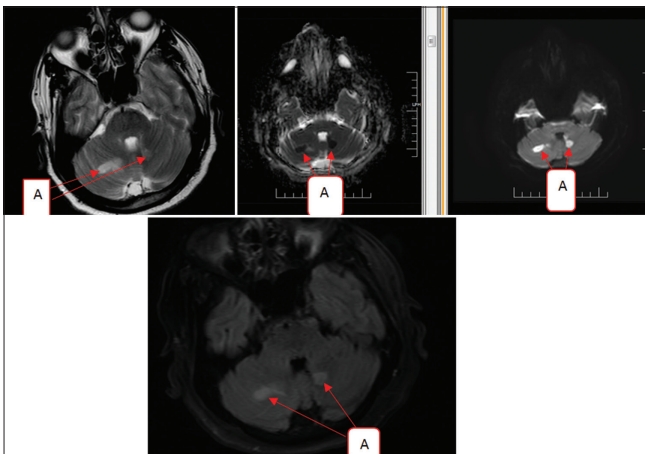


Figure 3: Magnetic resonance imaging brain study shows bilateral cerebellar infarct with the left superior cerebellar peduncle showing restricted diffusion and low apparent diffusion coefficient values

The common clinical characteristics of viper bite include local cellulitis, renal failure, and systemic hemorrhagic manifestation. Neurological deficit following viper bite is common and is usually due to intracerebral or subarachnoid bleed. Ischemic infarction following viper envenomation has been described by only a few authors.^[2] In majority of the cases reported, ischemic infarction involved the anterior circulation.^[3] We report a posterior circulation infarct involving bilateral cerebellum and occipital lobe following Russell's viper bite.

HISTORY

A 50-year-old male, known hypertensive, presented to the emergency department with an alleged history of Russell's

viper bite on his right foot [Figure 1]. The incident occurred an hour back while he was cleaning his water tank [Figure 2]. He had pain and swelling at the bite site initially. Later over 4 h, he developed drooping eyelids, slurring of speech, and giddiness with multiple episodes of vomiting. There was no LOC, seizure, and COVID infection.

Assessment

Upon arrival at the emergency department of the hospital, his pulse rate was 84 bpm and blood pressure was 200/100 mmHg. A local examination revealed two deep fang marks with surrounding redness and edema, as well as minimal bleeding over the right medial malleolus. The patient was drowsy, with a Glasgow Coma Scale of 13/15. His pupils were 3 mm bilaterally with a normal light reflex. He had drooping eyelids, dysarthria, and a flexor plantar response with normal fundus.

In view of neurological manifestations, the patient was administered ten vials of antivenom (ASV) as well as neostigmine and atropine injections. Following this, the neurological manifestations resolved except dysarthria. Computed tomography brain was normal. A complete hemogram revealed mild thrombocytopenia (1.4 lakh platelets) and neutrophilic leukocytosis (15,030/mm³, 94% neutrophils). His coagulation profile was found to be abnormal with an international normalized ratio of 2.26 and a prothrombin time of 26.9 s. The whole-blood clotting time was 20 min. Urine examination showed microscopic hematuria and hemoglobinuria. Liver function tests and renal functions were within normal limits. He received 10 more vials of ASV as well as 4 units of fresh frozen plasma for correction of deranged coagulation parameters.

Course

On day 2 of hospitalization, a detailed neurological examination revealed persistence of dysarthria with new onset of dysphonia and left upper- and lower-limb incoordination (positive finger–nose–finger test, rebound phenomenon, dysidiadochokinesia, and a positive heel shin test) along with swaying to the left while walking.

Subsequently, a magnetic resonance imaging (MRI) with magnetic resonance angiogram was done which showed acute infarcts in bilateral cerebellar hemispheres, with the left superior cerebellar peduncle showing restricted diffusion and low apparent diffusion coefficient values [Figure 3]. Electrocardiogram, lipid profile, carotid Doppler, echocardiogram, and magnetic resonance angiogram were normal, which negated the possibility of an ischemic or embolic stroke. Thrombophilic profile was sent for analysis.

Management

After normalization of the thrombocytopenia, microscopic hematuria, and coagulation profile, the patient was started on dual antiplatelet therapy, neuroprotective medications, high-dose statins with speech, and limb physiotherapy. The patient's further hospital stay remained uneventful. Postdischarge, tests

for lupus anticoagulant and anticardiolipin antibodies were found negative. Protein C, protein S, and antithrombin III levels were normal. Over a period of 3 weeks, the patient showed an improvement in upper-limb incoordination but mild gait ataxia which improved after 6 weeks.

DISCUSSION

Russell's viper venom contains C-type lectin-like proteins, snake venom serine proteases, esterases, hydrolases, and hemorrhagic agents.^[4] These proteins create a procoagulant state by activating thrombocytes and the complement system, which leads to widespread endothelial damage, vasospasm, and ultimately thrombosis of the cerebral blood vessels.

In a literature search study carried out from 1995 to 2018 by Mohammed Al-Sadawi *et al.*, there were only 18 case studies all over the world that reported a posterior circulation stroke following a viper bite.^[5] Murthy *et al.* have reported a case of cerebral infarction and diffuse encephalopathy following a viper bite.^[5] In a study of 309 patients with snakebite, Mosquera *et al.* reported cerebrovascular complications in 8 patients (2.6%), 7 hemorrhagic strokes and 1 ischemic stroke.^[6] Bashir and Jenkins reported a patient in whom envenomation with Russell's viper resulted in hemiplegia and aphasia, consistent with a middle cerebral artery infarction.^[7]

Better outcomes have been reported with immediate ASV treatment. In the study by Thomas *et al.*, of the 33 patients with envenomation who had not received ASV or received ASV after 8 h of envenomation, 14% developed thrombotic complications and 4 of the 14 patients who had not received ASV died. Of the 70 patients who received ASV within 6 h of envenomation, none had thrombotic complications.^[8] Our patient, despite treatment with ASV within 1 h of envenomation, developed delayed cerebral infarction on the 2nd day.

Ischemic stroke after viper bite has been reported less commonly in the literature; furthermore, the onset of ischemic stroke and reversibility is rare. We present a case of snakebite with ischemic stroke which has a clinically reversible outcome.

CONCLUSION

Cerebral infarction can be one of the differential diagnoses of neurological deterioration following Russell's viper bite. Learning point from these cases is that snakebite should be

one of the differential diagnoses for any young patient with stroke. We call the attention of physicians working in rural areas, to look for such less recognized etiologies of stroke in tropical countries and importance of timely radio imaging, especially MRI brain in recognizing the condition and to initiate appropriate therapy.

Acknowledgment

We acknowledge the Patient and the Department of Medicine, JSS Medical College and Hospital, for providing the opportunity to treat this patient.

Declaration of patient consent

The authors certify that they have obtained all appropriate patient consent forms. In the form the patient(s) has/have given his/her/their consent for his/her/their images and other clinical information to be reported in the journal. The patients understand that their names and initials will not be published and due efforts will be made to conceal their identity, but anonymity cannot be guaranteed.

Financial support and sponsorship

Nil.

Conflicts of interest

There are no conflicts of interest.

REFERENCES

- David AW. Guidelines for the Clinical Management of Snake-Bites in South-East Asia Region. New Delhi: World Health Organisation, Regional Office for South-East Asia Region; 2005. p. 1-77.
- Panicker JN, Madhusudanan S. Cerebral infarction in a young male following viper envenomation. *J Assoc Physicians India* 2000;48:744-5.
- Lee BC, Hwang SH, Bae JC, Kwon SB. Brainstem infarction following Korean viper bite. *Neurology* 2001;56:1244-5.
- Thomas L, Tyburn B, Bucher B, Pecout F, Ketterle J, Rieux D, *et al.* Prevention of thromboses in human patients with *Bothrops lanceolatus* envenoming in Martinique: Failure of anticoagulants and efficacy of a monospecific antivenom. Research group on snake bites in Martinique. *Am J Trop Med Hyg* 1995;52:419-26.
- Mohammed Al Sadawi *et al.*, *International Journal of Clinical Research & Trials* 2019;4: 07. ArticleID4: IJCRT 133.
- Mosquera A, Idrovo LA, Tafur A, Del Brutto OH. Stroke following *Bothrops* spp. snakebite. *Neurology* 2003;60:1577-80.
- Bashir R, Jenkins J. Cerebral infarction in a young female following snake bite. *Stroke* 1985;16:328-30.
- Thomas L, Tyburn B, Ketterle J, Biao T, Mehdaoui H, Moravie V, *et al.* Prognostic significance of clinical grading of patients envenomed by *Bothrops lanceolatus* in Martinique. Members of the research group on snake bite in Martinique. *Trans R Soc Trop Med Hyg* 1998;92:542-5.