

# Regional cerebral blood flow and metabolism in reversible ischemia due to vasospasm

## Determination by positron emission tomography

WILLIAM J. POWERS, M.D., ROBERT L. GRUBB, JR., M.D., ROY P. BAKER, M.D.,  
MARK A. MINTUN, M.D., AND MARCUS E. RAICHLE, M.D.

*Department of Neurology and Neurological Surgery, and Division of Radiation Sciences, The Edward Mallinckrodt Institute of Radiology, and The McDonnell Center for Studies of Higher Brain Function, Washington University School of Medicine, St. Louis, Missouri*

✓ Regional cerebral blood flow (rCBF) and regional cerebral metabolic rate of oxygen (rCMRO<sub>2</sub>) were measured by positron emission tomography (PET) in four patients with subarachnoid hemorrhage and hemiparesis due to cerebral vasospasm. With resolution of the vasospasm, two patients recovered and two remained hemiparetic. Contralateral to the hemiparesis, rCBF was slightly higher in the two patients who eventually recovered (15.0 and 16.2 ml/100 gm/min) than in the two who remained hemiparetic (12.0 and 11.7 ml/100 gm/min). The rCMRO<sub>2</sub> measurements showed similar differences, with values of 1.34 and 2.60 ml/100 gm/min in the patients who recovered, and 0.72 and 1.66 ml/100 gm/min in those who did not. These preliminary findings indicate that with PET studies it may be possible to prospectively differentiate patients with neurological deficits due to reversible ischemia from patients with irreversible infarction.

**KEY WORDS** • cerebral blood flow • metabolism • vasospasm •  
positron emission tomography • subarachnoid hemorrhage

CEREBRAL ischemia due to vasospasm accounts for a major portion of the morbidity and mortality that follows intracranial aneurysm rupture. The neurological deficits produced by vasospastic ischemia are potentially reversible if adequate blood flow can be restored before permanent infarction has occurred. Intravascular volume expansion with induced arterial hypertension has proven to be the most successful treatment in this regard, reversing neurological deterioration in over 75% of patients.<sup>22</sup> Since this therapeutic approach carries risks, especially in patients with unclipped aneurysms, the ability to differentiate patients with reversible ischemia from those with irreversible infarction would be of great clinical value.

Measurements of cerebral blood flow (CBF) during cerebral ischemia have demonstrated that brain electrical activity diminishes at flows below approximately 20 ml/100 gm/min, whereas membrane failure and cell death do not occur until CBF falls below approximately 10 ml/100 gm/min.<sup>2,5,16,21,25,36,38</sup> Values of CBF within this range of 10 to 20 ml/100 gm/min have been

correlated with reversible neurological deficits in an experimental study of cerebral ischemia in primates.<sup>21</sup> Extension of these findings to clinical practice requires a method for accurate quantitative measurement of regional CBF (rCBF) in man. The development of positron emission tomography (PET) has provided such a method and, furthermore, allows measurement of the regional cerebral metabolic rate of oxygen (rCMRO<sub>2</sub>).<sup>34</sup> Given the normal dependence of the brain on oxidative metabolism, rCMRO<sub>2</sub> is likely to be a sensitive indicator of the development of irreversible infarction. Although PET has been widely used to study cerebral hemodynamics and metabolism in human subjects with cerebrovascular disease,<sup>1,4,12,26,31,32,40</sup> no quantitative studies of patients with transient reversible neurological deficits have been reported.

As part of an ongoing study of rCBF and rCMRO<sub>2</sub> in patients with subarachnoid hemorrhage (SAH) caused by ruptured aneurysms,<sup>3,14,27</sup> we have used PET to serially study four patients who developed focal neurological deficits in association with arteriographic

vasospasm. Our findings are reported here. With resolution of the vasospasm, two patients recovered and two remained hemiparetic. The PET measurements of rCBF and rCMRO<sub>2</sub>, obtained early in the course of vasospasm, prior to computerized tomography (CT) demonstration of infarction, showed higher values in those patients who eventually recovered. These preliminary data indicate that it may be possible to prospectively differentiate patients with reversible ischemic neurological deficits from those with irreversible infarction. Furthermore, these data indicate that patients with neurological deficits caused by cerebral vasospasm provide an excellent opportunity to study such phenomena in man.

### Summary of Cases

Four patients with SAH due to ruptured intracranial aneurysms were studied at a time when they had recently developed a focal neurological deficit in association with arteriographic evidence of vasospasm. All of these patients underwent repeat PET studies when vasospasm had resolved. In addition, three of the four had also undergone an initial PET study earlier in the course of their illness, prior to the development of vasospasm.

#### Case 1

This 34-year-old right-handed woman was admitted to Barnes Hospital 1 day after experiencing a severe headache, loss of consciousness, nausea, and vomiting. Examination on admission was normal except for meningismus. Computerized tomography scanning revealed blood in the suprasellar, interhemispheric, and Sylvian cisterns. The ventricles were larger than anticipated for the patient's age. Three-vessel arteriography performed on Day 2 revealed a right posterior communicating artery aneurysm with no evidence of vasospasm. An initial PET study was performed (Fig. 1 *left column*). At this time the patient was awake and alert with no focal neurological deficits. On Day 8 she developed a right hemiparesis and nonfluent dysphasia. Computerized tomography showed residual subarachnoid blood with no increase in ventricular size. The hemiparesis and dysphasia improved over the next 2 days but were still present on Day 10 when bilateral carotid arteriography demonstrated severe spasm of the internal carotid, middle cerebral, and anterior cerebral arteries bilaterally. Positron emission tomography studies (Fig. 1 *center column*) were performed immediately following arteriography. The hemiparesis and dysphasia continued to improve, and by Day 19 the patient was neurologically normal. Computerized tomography on Day 20 showed moderate hydrocephalus with no evidence of cerebral infarction. Right carotid arteriography on Day 23 showed marked relief of spasm with only slight residual narrowing of the A<sub>1</sub> segment. A third PET study (Fig. 1 *right column*) was performed immediately following arteriography. The aneurysm was successfully clipped on Day 24 and the postopera-

tive course was uneventful. The patient was neurologically normal at the time of discharge.

#### Case 2

This 53-year-old right-handed woman was admitted after the sudden onset of occipital headache accompanied by loss of consciousness. On admission, she was awake and oriented, with no focal neurological deficits. Computerized tomography on Day 1 demonstrated subarachnoid blood with an intracerebral hematoma in the right frontal operculum. Three-vessel arteriography performed on Day 2 showed an aneurysm at the bifurcation of the right middle cerebral artery, with no evidence of vasospasm. Initial PET studies were performed on Day 4 when the patient was lethargic but without focal neurological deficits. She remained somewhat sleepy. On Day 9 she became progressively more lethargic and developed a left hemiparesis. Computerized tomography showed some increase in edema around the right-sided hematoma. A second series of PET studies was performed at this time. A right brachial arteriogram obtained on Day 10 revealed marked spasm of the internal carotid, middle cerebral, and anterior cerebral arteries. Over the next week her left hemiparesis gradually resolved. On Day 18 she was alert and oriented, with no focal weakness. Right carotid arteriography performed at this time showed marked improvement of the vasospasm. A third set of PET studies was performed immediately following arteriography. On Day 19 the aneurysm was successfully clipped. Postoperatively, the patient developed a left hemiparesis in association with marked edema of the right frontal and temporal lobes. Over the next 2 weeks the edema resolved and the hemiparesis improved, leaving her with only minimal left-sided weakness at the time of discharge.

#### Case 3

This 66-year-old left-handed man was admitted to another hospital because of severe headache and vomiting. Computerized tomography showed blood in the basal cisterns, and arteriography demonstrated a right posterior communicating artery aneurysm. Examination on admission was normal except for meningismus. On Day 7 he became drowsy and confused, and was transferred to Barnes Hospital on Day 9. At that time, he was lethargic and disoriented with mild left facial weakness, a clumsy left hand, and inattention to the left visual field. Computerized tomography showed minimal SAH. Over the next few days his clinical condition worsened. He became sleepier and developed dense left facial weakness with mild weakness of the left arm. Three-vessel carotid arteriography performed on Day 13 showed spasm of the M<sub>1</sub> and A<sub>1</sub> segments bilaterally. Initial PET studies were performed immediately thereafter. At this time the patient had left facial weakness and mild left arm weakness, which persisted. Right carotid arteriography on Day 23 showed no evidence of spasm. Repeat PET studies were performed.

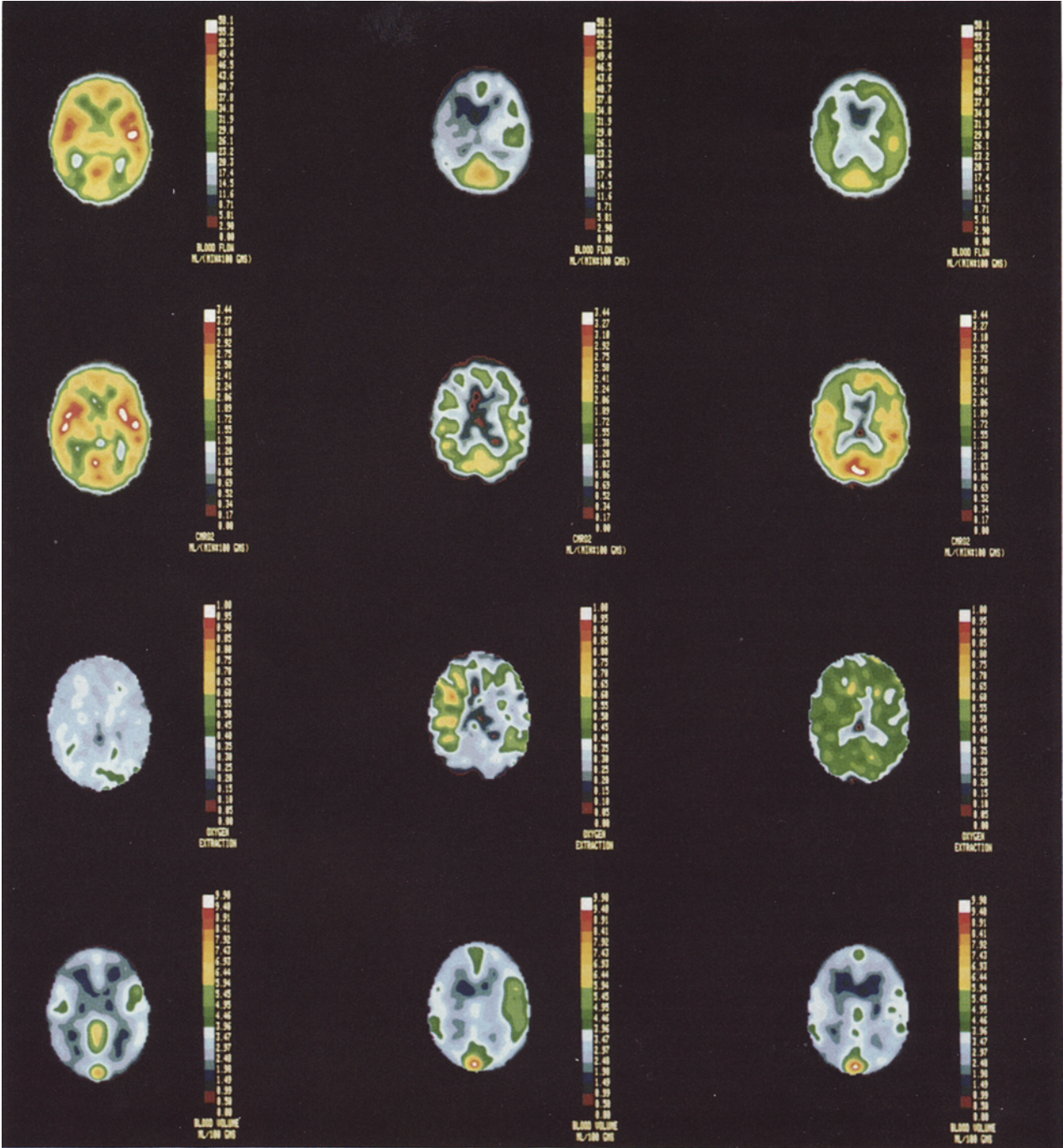


FIG. 1. Three sequential positron emission tomography studies performed in Case 1, a 34-year-old woman with a ruptured posterior communicating artery aneurysm. *Left Column:* The first study, performed on Day 2 after hemorrhage when the patient was neurologically normal, reveals no abnormalities in regional cerebral blood flow (rCBF, *top row*), regional cerebral metabolic rate of oxygen (rCMRO<sub>2</sub>, *second row*), regional oxygen extraction fraction (rOEF, *third row*), or regional blood volume (rCBV, *bottom row*). *Center Column:* The second study, performed on Day 10 when the patient was dysphasic with a right hemiparesis due to vasospasm, shows a widespread decrease in rCBF to both hemispheres, worse on the left. The rCMRO<sub>2</sub> is also decreased bilaterally, more so on the left. The rOEF is elevated on the left compared to the right, whereas rCBV is lower. *Right Column:* The third study, performed on Day 23 well after the dysphasia had cleared, reveals improved hemodynamics and metabolism bilaterally. Quantitative regional measurements derived from these scans are shown in Table 1.

The patient continued to have marked left facial weakness and mild left arm weakness. The aneurysm was successfully clipped on Day 24. The postoperative course was complicated by the development of communicating hydrocephalus, requiring placement of a shunt. Computerized tomography performed on Day 59 showed a well demarcated infarct in the right frontal lobe. He was discharged with left facial weakness.

#### Case 4

This 54-year-old right-handed woman was found in bed, lethargic and complaining of headache. On admission to Barnes Hospital, she was drowsy but arousable, with no focal neurological deficits. Computerized tomography showed diffuse subarachnoid and intraventricular blood, ventricular dilation, and an intracerebral hematoma in the right frontotemporal region. Right carotid arteriography demonstrated a right posterior communicating artery aneurysm and no vasospasm. A left frontal craniotomy was performed. Initial PET studies were performed on Day 4 when the patient was lethargic but had no focal neurological deficits. On Day 8 she developed left hemiparesis involving the face and arm. This deficit persisted. Right carotid arteriography performed on Day 10 revealed spasm of the internal carotid and middle cerebral arteries bilaterally. A second PET study was performed immediately following the angiogram. Computerized tomography on Day 10 showed partial resolution of the intracerebral hematoma with no evidence of infarction or hydrocephalus. On Day 17 the hemiparesis was still present. Right carotid arteriography showed no spasm of the middle cerebral artery and only slight residual spasm of the A<sub>1</sub> segment. A third series of PET studies was then performed. The aneurysm was successfully clipped on Day 19. Left hemiparesis persisted, and CT performed on Day 27 showed an infarct of the right internal capsule and temporoparietal white matter.

### Positron Emission Tomography Studies

#### Materials and Methods

Measurements of regional cerebral hemodynamics and metabolism were performed on a PETT VI machine in the low-resolution mode. This machine, which was developed at our institution, collects seven contiguous tomographic slices 14.4 mm apart, with a transverse resolution of 12.4 to 14.9 mm and an axial resolution of 9.7 to 20.5 mm.<sup>41</sup> Patients were positioned so that the lowest tomographic slice was at the canthomeatal line. Calibration of the PETT VI to achieve quantitative measurements of local tissue radioactivity was performed as described previously.<sup>35</sup> Venous and arterial catheters were placed to permit injection of radiotracer and collection of arterial blood samples.

A transmission scan with a germanium-68/gallium-68 ring source was obtained for each subject to provide the data on attenuation of photons that is necessary for quantitative reconstruction of subsequent scans. Three

separate physiological studies were then carried out. During each, sequential arterial blood samples were drawn to permit conversion of the quantitative regional radioactivity data obtained with the PETT VI machine to quantitative physiological measurement. All studies were carried out in a darkened room with a low ambient noise level. The patients' eyes and ears were not masked. The rCBF was measured using a bolus intravenous injection of oxygen-15 (<sup>15</sup>O)-labeled water.<sup>17,35</sup> Regional cerebral blood volume (rCBV) was measured following single-breath inhalation of air containing trace amounts of <sup>15</sup>O-labeled carbon monoxide.<sup>15,29</sup> The rCMRO<sub>2</sub> was measured using single-breath inhalation of <sup>15</sup>O-labeled oxygen in combination with data supplied from the previous rCBF and rCBV studies. This technique directly measures the regional oxygen extraction fraction (rOEF). The rCMRO<sub>2</sub> is then calculated as the product of rOEF, rCBF, and the arterial oxygen content.<sup>29</sup> The short half-life (123 seconds) of <sup>15</sup>O permitted all these studies to be performed in rapid succession. All radio-nuclides were produced in the Washington University Medical Cyclotron. Identical studies were performed in 10 normal subjects, aged between 20 and 74 years.

Informed written consent from the subject or next of kin was obtained prior to each PET study. All protocols were approved by the Human Studies Committee and the Radioactive Drug Research Committee of the Washington University School of Medicine.

#### Data Analysis

For each patient, two regions of interest were constructed using the rCBF scan obtained during vasospasm. First, a rectangular region measuring 4.7 to 7.3 sq cm was drawn around the area of decreased rCBF in the hemisphere contralateral to the neurological deficit. This region was superior to and clearly separate from the region of decreased rCBF caused by the intracerebral hematoma in Cases 2 and 4. A homologous region in the opposite hemisphere located symmetrically around the biparietal midline was then outlined. Values for rCBF, rCMRO<sub>2</sub>, rCBV, and rOEF for these two regions during vasospasm were then determined. Using a computer-based stereotaxic method for anatomical localization recently developed in this laboratory,<sup>8</sup> the same regions were then placed on the subject's other PET studies and the corresponding regional physiological values were obtained.

### Results

Values for rCBF, rCMRO<sub>2</sub>, rOEF, and rCBV obtained from the three studies performed prior to the development of vasospasm were all within the normal range (Table 1 and Fig. 2). With the development of cerebral vasospasm, rCBF and rCMRO<sub>2</sub> in both hemispheres decreased in all four patients; however, the values were always lower in the symptomatic hemisphere contralateral to the clinical neurological deficit (Table 1 and Fig. 2). The rCBF in the symptomatic

TABLE 1  
Regional measurements of cerebral hemodynamics and metabolism in Cases 1 to 4\*

Case No.	Days Post-SAH	Neurological Grade†	Focal Deficits	Vasospasm	rCBF (ml/100 gm/min)		rCMRO <sub>2</sub> (ml/100 gm/min)		rOEF		rCBV (ml/100 gm)	
					Right	Left	Right	Left	Right	Left	Right	Left
1	3	I	none	none	45.3	37.8	2.54	2.27	0.30	0.33	4.13	3.43
	10	III	rt HP	severe	24.4	15.0	1.49	1.34	0.35	0.49	5.03	3.53
	23	II	none	minimal	30.5	25.1	2.20	1.94	0.42	0.45	3.71	3.53
2	4	III	none	none	34.1	35.7	2.70	2.40	0.40	0.43	3.14	3.63
	9	III-IV	lt HP	severe	16.2	28.1	2.60	3.07	0.99	0.68	4.01	3.58
	18	III	none	minimal	36.4	37.2	1.16	1.42	0.23	0.28	3.92	4.54
3	13	III	lt HP	severe	12.0	16.4	0.72	1.49	0.33	0.50	3.70	2.91
	23	III	lt HP	none	14.9	19.6	0.77	1.34	0.33	0.43	2.39	2.79
4	4	II	none	none	35.1	42.6	2.29	3.11	0.37	0.41	2.70	3.33
	10	III	lt HP	severe	11.7	23.6	1.66	2.29	0.76	0.51	2.18	2.19
	17	III	lt HP	none	23.1	24.9	1.21	2.07	0.27	0.42	3.91	3.99
normal mean values					50.7		3.19		0.40		3.98	
normal range					31.1-83.7		2.34-4.22		0.23-0.60		2.61-6.50	

\* SAH = subarachnoid hemorrhage; rCBF = regional cerebral blood flow; rCMRO<sub>2</sub> = regional cerebral metabolic rate of oxygen; rOEF = regional oxygen extraction fraction; rCBV = regional cerebral blood volume; HP = hemiparesis.

† Neurological grading according to Hunt and Hess.<sup>18</sup>

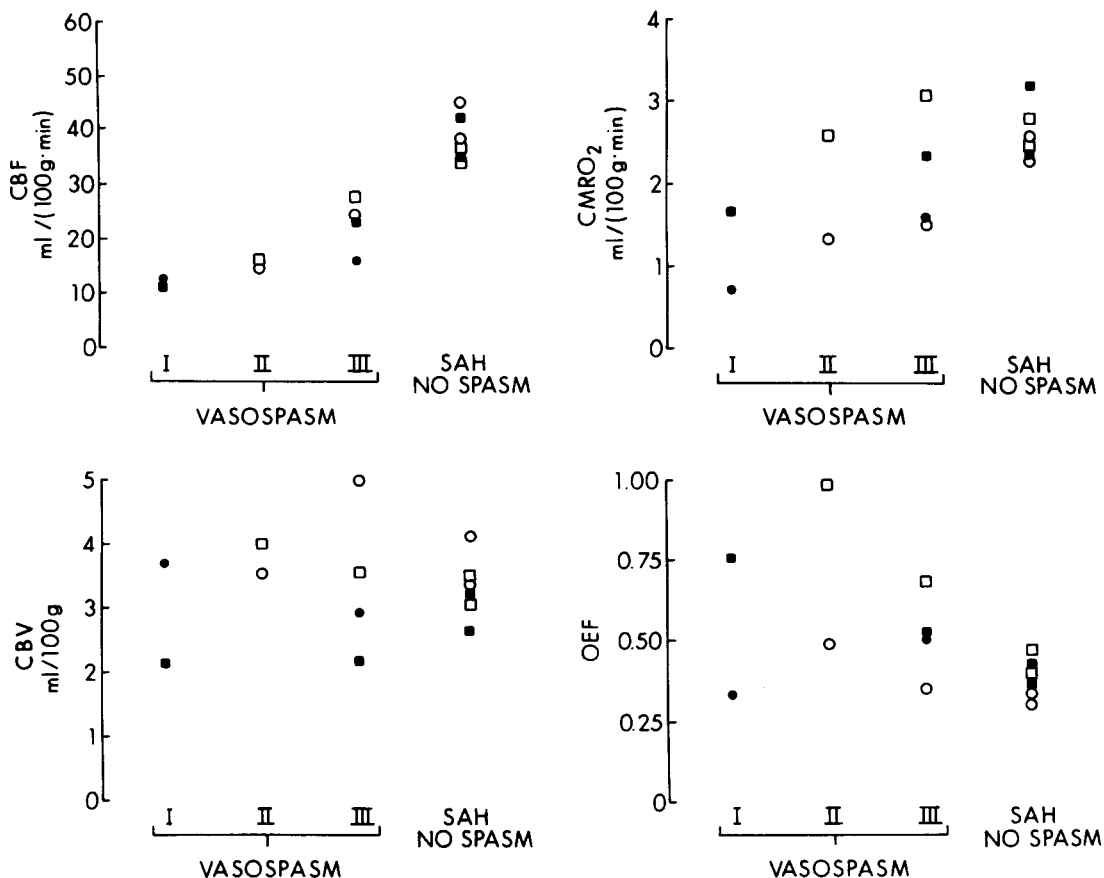


FIG. 2. Regional measurements of cerebral blood flow (CBF), cerebral metabolic rate of oxygen (CMRO<sub>2</sub>), cerebral blood volume (CBV), and oxygen extraction fraction (OEF) in four patients with neurological deficits due to cerebral vasospasm following subarachnoid hemorrhage (SAH). Values from the symptomatic hemisphere contralateral to the neurological deficit in the two patients with irreversible deficits (I) are compared with those from the two patients with reversible deficits (II). Values from the other hemisphere during vasospasm are given for all four patients (III). Three of these patients also underwent positron emission tomography studies early in the course of their disease prior to vasospasm and these values are shown for comparison. White circles = Case 1; white squares = Case 2; black circles = Case 3; and black squares = Case 4.



hemisphere was below 20 ml/100 gm/min in all four patients, but was slightly higher (15.0 and 16.2 ml/100 gm/min) in the patients who eventually recovered from their hemiparesis (Cases 1 and 2) than it was in those who did not (12.0 and 11.7 ml/100 gm/min in Cases 3 and 4). A similar but not as consistent pattern was also seen for rCMRO<sub>2</sub>. In Cases 1 and 2, rCMRO<sub>2</sub> in the hemisphere contralateral to the neurological deficit was 1.34 and 2.60 ml/100 gm/min, respectively, whereas in Cases 3 and 4 it was 0.72 and 1.66. With resolution of vasospasm, all four patients showed an increase in CBF bilaterally regardless of the clinical outcome. The rCBF rose above 20 ml/100 gm/min in both patients who recovered and in one who did not (Case 4). Changes in rCMRO<sub>2</sub> were more variable. Values of 2.20 and 1.16 ml/100 gm/min occurred in the contralateral hemisphere of those two patients who recovered from hemiparesis, and values of 0.77 and 1.21 ml/100 gm/min occurred in those who did not. Measurements of rCBV and rOEF exhibited no consistent pattern (Table 1 and Fig. 2).

### Discussion

Measurements of rCBF in these four cases have demonstrated thresholds for reversible ischemia and irreversible infarction similar to those described in experimental animals by other investigators.<sup>2,5,16,21</sup> Regional values for CBF below 20 but higher than 12 ml/100 gm/min were associated with clinical neurological deficits that were reversible. Regional values for CBF of 12 ml/100 gm/min or less were associated with clinical deficits that were not reversible when vasospasm resolved. Previous studies of ischemic thresholds in man have been primarily restricted to establishing the relationship between rCBF and electroencephalographic (EEG) changes in patients undergoing carotid endarterectomy while under general anesthesia.<sup>25,36,38</sup> These studies have demonstrated that slowing or flattening of the EEG occurs when rCBF is less than 17 or 18 ml/100 gm/min. Using drug-induced hypotension, Finnerty and colleagues<sup>7</sup> demonstrated that signs of global cerebral ischemia appear when CBF falls to approximately 30 ml/100 gm/min without any change in CMRO<sub>2</sub>. Our observations represent the first correlation between rCBF and rCMRO<sub>2</sub> and the reversibility of focal neurological deficits in man.

Experimental models of cerebral ischemia have demonstrated that the relationship between rCBF and the occurrence of cerebral infarction is more complex than a simple threshold phenomenon. The development of irreversible neuronal damage depends not only on the magnitude of blood flow reduction but also on its duration, as well as on a variety of other factors including antecedent cerebral glucose stores and the selective vulnerability of specific neuronal populations.<sup>2,9,16,21,33</sup> The complexity of these interactions, taken together with the well known phenomenon of luxury perfusion<sup>24,30</sup> (as seen in the third PET study in Case 4), makes it unlikely that measurements of rCBF alone

will be adequate for reliable identification of tissues in which ischemia is reversible. Given the normal dependence of the brain on oxidative metabolism, it seems probable that the level of regional oxygen consumption will also be critical in determining the survival of cerebral tissue. Measurements of rCMRO<sub>2</sub> in combination with rCBF determinations may therefore aid in the identification of reversible ischemia. Our data indicate that there is a threshold for irreversible infarction at rCMRO<sub>2</sub> levels of 1.0 to 1.5 ml/100 gm/min. The data are not as consistent as those for rCBF, however. These findings are in accord with our previous observation that patients with carotid occlusion and no neurological deficits have rCMRO<sub>2</sub> values of 1.43 ml/100 gm/min or greater.<sup>31</sup> They are also in agreement with a recent PET study of 25 patients with acute ischemic stroke<sup>4</sup> in which those areas of brain that later showed CT evidence of infarction had values for rCMRO<sub>2</sub> below 1.5 ml/100 gm/min.

While the present findings indicate that measurements of rCBF and rCMRO<sub>2</sub> early in the course of vasospastic ischemia may be useful in differentiating patients with reversible ischemia from those with irreversible infarction, there are several factors that must be taken into account when interpreting these results. The response of the brain to ischemia is a dynamic one, involving a complex cascade of biochemical reactions that may eventually culminate in cell death.<sup>33</sup> Threshold values for rCBF and rCMRO<sub>2</sub> may be different at different points during this cascade. Furthermore, cerebral vasospasm itself is not a static process. Reversible ischemia may become irreversible as vasospasm worsens and blood flow decreases further. Our failure to find absolutely consistent thresholds for reversible ischemia and irreversible infarction, especially for rCMRO<sub>2</sub>, may reflect the fact that we were studying a dynamic process with only a single set of measurements at one point in time during the period of ischemia.

The accuracy of PET in measuring rCBF and rCMRO<sub>2</sub> in small cerebral lesions is limited by the resolution of the PET scanner, which was 1 to 2 cm for the machine that we used. This means that rCBF or rCMRO<sub>2</sub> measured at any point in the brain represents a weighted average of the actual values at that point and of the values in the surrounding several centimeters of tissue. As a result, PET measurements of small regions tend to be higher or lower than they actually are, depending upon the values in the surrounding tissue. This partial volume effect may also account for some of the scatter in our data.

Previous studies of cerebral ischemia have also demonstrated increases in both rCBV and rOEF.<sup>1,7,12-14,20,27,31,32</sup> These increases are believed to reflect the compensatory mechanisms used by the brain to maintain oxidative metabolism in the face of decreased perfusion pressure.<sup>31</sup> Positron emission tomography measurements of rCBV and rOEF in human cerebrovascular disease have recently shown that focal increases of both rCBV and rOEF can occur in infarcted as well as in

ischemic tissue, demonstrating the nonspecific nature of these findings.<sup>4,23,26,40</sup> The underlying pathophysiological basis for the changes observed in rCBV and rOEF is still poorly understood and requires further study.<sup>31</sup> We did not find these two measurements useful in differentiating reversible ischemia from irreversible infarction in the present study.

Clinical deterioration following SAH can occur for a variety of reasons in addition to vasospasm. Changes in CBF and neurological status may also be caused by edema, hydrocephalus, or rebleeding.<sup>6,19,28,39</sup> Although none of these factors appeared to be of major importance in our four cases, some contribution cannot be entirely excluded. Since our primary purpose was to investigate the relationship between rCBF, rCMRO<sub>2</sub>, and neurological function, the precise cause of the changes in rCBF and rCMRO<sub>2</sub> is less important than the consequences that these changes produced.

Previous studies of CBF following aneurysm rupture have often shown a poor correlation between focal areas of decreased blood flow and the presence of neurological deficits.<sup>10,11,14,37</sup> Our findings suggest that these discrepancies can be explained by the variable degree of local CBF reduction. Unless flow is reduced below 20 ml/100 gm/min, no corresponding clinical findings would be expected.

The results of this study suggest that accurate quantitative measurements of rCBF and rCMRO<sub>2</sub> may be useful in differentiating patients with reversible ischemic neurological deficits from those with irreversible infarction. Although of great clinical importance, investigations of the reversibility of ischemic neurological deficits in man are difficult to perform. Patients who develop vasospasm present a unique opportunity to perform studies of cerebral hemodynamics and metabolism before, during, and after an ischemic insult that may produce no clinical symptoms, a transient neurological deficit, or permanent infarction. During the past 3 years we have been fortunate to study four such patients who developed neurological deficits, two of whom recovered completely. Even though our findings are consistent with other experimental and clinical observations, this small number of patients provides insufficient data to draw any firm conclusions. We would suggest, however, that this approach to the study of reversible ischemia is important as well as clinically feasible, and that further research along these lines should be pursued.

## Acknowledgments

The authors would like to thank the members of the Department of Neurology and Neurological Surgery for their cooperation in allowing us to study their patients, and the staff of the Division of Radiation Sciences, The Edward Mallinckrodt Institute of Radiology, for their assistance.

## References

1. Ackerman RH, Correia JA, Alpert NM, et al: Positron imaging in ischemic stroke disease using compounds la-

- beled with oxygen 15. Initial results of clinicophysiological correlations. *Arch Neurol* 38:537-543, 1982
2. Astrup J: Energy-requiring cell functions in the ischemic brain. Their critical supply and possible inhibition in protective therapy. *J Neurosurg* 56:482-497, 1982
3. Baker RP, Martin WRW, Herscovitch P, et al: Evaluation by positron emission tomography of cerebral hemodynamics and metabolism following subarachnoid hemorrhage. *J Nucl Med* 23:P5, 1982 (Abstract)
4. Baron JC, Rougemont D, Boussier MG, et al: Local CBF, oxygen extraction fraction (OEF), and CMRO<sub>2</sub>: prognostic value in recent supratentorial infarction in humans. *J Cereb Blood Flow Metab* 3 (Suppl 1):S1-S2, 1983
5. Branston NM, Ladds A, Symon A, et al: Comparison of the effects of ischaemia on early components of the somatosensory evoked potential in brainstem, thalamus, and cerebral cortex. *J Cereb Blood Flow Metab* 4:68-81, 1984
6. Ferguson GG, Harper AM, Fitch W, et al: Cerebral blood flow measurements after spontaneous subarachnoid haemorrhage. *Eur Neurol* 8:15-22, 1972
7. Finnerty FA Jr, Witkin L, Fazekas JF: Cerebral hemodynamics during cerebral ischemia induced by acute hypotension. *J Clin Invest* 33:1227-1232, 1954
8. Fox PT, Perlmutter JS, Raichle ME: A stereotactic method of anatomical localization for positron emission tomography. *J Comput Assist Tomogr* 9:141-153, 1985
9. Garcia JH, Mitchem HL, Briggs L, et al: Transient focal ischemia in subhuman primates. Neuronal injury as a function of local cerebral blood flow. *J Neuropathol Exp Neurol* 42:44-60, 1983
10. Gelmers HJ, Beks JWF, Journée HL: Regional cerebral blood flow in patients with subarachnoid haemorrhage. *Acta Neurochir* 47:245-251, 1979
11. Géraud G, Tremoulet M, Guell A, et al: The prognostic value of noninvasive CBF measurement in subarachnoid hemorrhage. *Stroke* 15:301-305, 1984
12. Gibbs JM, Wise RJS, Leenders KL, et al: Evaluation of cerebral perfusion reserve in patients with carotid-artery occlusion. *Lancet* 1:310-314, 1984
13. Grubb RL Jr, Phelps ME, Raichle ME: The effects of arterial blood pressure on the regional cerebral blood volume by x-ray fluorescence. *Stroke* 4:390-399, 1973
14. Grubb RL Jr, Raichle ME, Eichling JO, et al: Effects of subarachnoid hemorrhage on cerebral blood volume, blood flow, and oxygen utilization in humans. *J Neurosurg* 46:446-453, 1977
15. Grubb RL Jr, Raichle ME, Higgins CS, et al: Measurement of regional cerebral blood volume by emission tomography. *Ann Neurol* 4:322-328, 1978
16. Heiss WD, Rosner G: Functional recovery of cortical neurons as related to degree and duration of ischemia. *Ann Neurol* 14:294-301, 1983
17. Herscovitch P, Markham J, Raichle ME: Brain blood flow measured with intravenous H<sub>2</sub><sup>15</sup>O. I. Theory and error analysis. *J Nucl Med* 24:782-789, 1983
18. Hunt WE, Hess RM: Surgical risk as related to time of intervention in the repair of intracranial aneurysms. *J Neurosurg* 28:14-20, 1968
19. Ishii R: Regional cerebral blood flow in patients with ruptured intracranial aneurysms. *J Neurosurg* 50:587-594, 1979
20. Jawad K, Miller JD, Fitch W, et al: Measurement of jugular venous blood gases for prediction of brain ischaemia following carotid ligation. A comparison with direct measurements of cerebral blood flow. *Eur Neurol* 14:43-52, 1976
21. Jones TH, Morawetz RB, Crowell RM, et al: Thresholds

- of focal cerebral ischemia in awake monkeys. *J Neurosurg* 54:773-782, 1981
22. Kassell NF, Peerless SJ, Durward QJ, et al: Treatment of ischemic deficits from vasospasm with intravascular volume expansion and induced arterial hypertension. *Neurosurgery* 11:337-343, 1982
  23. Lammertsma AA, Wise RJ, Heather JD, et al: Correction for the presence of intravascular oxygen-15 in the steady-state technique for measuring regional oxygen extraction ratio in the brain: 2. Results in normal subjects and brain tumour and stroke patients. *J Cereb Blood Flow Metab* 3:425-431, 1983
  24. Lassen NA: The luxury-perfusion syndrome and its possible relation to acute metabolic acidosis localised within the brain. *Lancet* 2:1113-1115, 1966
  25. Leech PJ, Miller JD, Fitch W, et al: Cerebral blood flow, internal carotid artery pressure, and the EEG as a guide to the safety of carotid ligation. *J Neurol Neurosurg Psychiatry* 37:854-862, 1974
  26. Lenzi GL, Frackowiak RS, Jones T: Cerebral oxygen metabolism and blood flow in human cerebral ischemic infarction. *J Cereb Blood Flow Metab* 2:321-335, 1982
  27. Martin WRW, Baker RP, Grubb RL, et al: Cerebral blood volume, blood flow, oxygen metabolism in cerebral ischaemia and subarachnoid haemorrhage: an *in-vivo* study using positron emission tomography. *Acta Neurochir* 70:3-9, 1984
  28. Mathew NT, Meyer JS, Hartmann A: Diagnosis and treatment of factors complicating subarachnoid hemorrhage. *Neuroradiology* 6:237-245, 1974
  29. Mintun MA, Raichle ME, Martin WRW, et al: Brain oxygen utilization measured with O-15 radiotracers and positron emission tomography. *J Nucl Med* 25:177-187, 1984
  30. Olsen TS, Larsen B, Skriver EB, et al: Focal cerebral hyperemia in acute stroke. Incidence, pathophysiology and clinical significance. *Stroke* 12:598-607, 1981
  31. Powers WJ, Grubb RL Jr, Raichle ME: Physiologic responses to focal cerebral ischemia in humans. *Ann Neurol* 16:546-552, 1984
  32. Powers WJ, Martin WRW, Herscovitch P, et al: Extra-cranial-intracranial bypass surgery: hemodynamic and metabolic effects. *Neurology* 34:1168-1174, 1984
  33. Raichle ME: The pathophysiology of brain ischemia. *Ann Neurol* 13:2-10, 1983
  34. Raichle ME: Positron emission tomography. *Annu Rev Neurosci* 6:249-267, 1983
  35. Raichle ME, Martin WRW, Herscovitch P, et al: Brain blood flow measured with intravenous H<sub>2</sub><sup>15</sup>O. II. Implementation and validation. *J Nucl Med* 24:790-798, 1983
  36. Sundt TM Jr, Sharbrough FW, Anderson RE, et al: Cerebral blood flow measurements and electroencephalograms during carotid endarterectomy. *J Neurosurg* 41:310-320, 1974
  37. Symon L, Ackerman R, Bull JWD, et al: The use of the xenon clearance method in subarachnoid haemorrhage. Post-operative studies with clinical and angiographic correlation. *Eur Neurol* 8:8-14, 1972
  38. Trojaborg W, Boysen G: Relation between EEG, regional cerebral blood flow and internal carotid artery pressure during carotid endarterectomy. *Electroencephalogr Clin Neurophysiol* 34:61-69, 1973
  39. Weir B, Menon D, Overton T: Regional cerebral blood flow in patients with aneurysms: estimation by Xenon 133 inhalation. *Can J Neurol Sci* 5:301-305, 1978
  40. Wise RJS, Bernardi S, Frackowiak RSJ, et al: Serial observations on the pathophysiology of acute stroke. The transition from ischaemia to infarction as reflected in regional oxygen extraction. *Brain* 106:197-222, 1983
  41. Yamamoto M, Ficke DC, Ter-Pogossian MM: Performance study of PETT VI, a positron computed tomograph with 288 cesium fluoride detectors. *IEEE Trans Nucl Sci* 29:529-533, 1982

---

Manuscript received July 19, 1984.

This work was supported by National Institutes of Health Grants NS06833 and HL13851, and by Teacher Investigator Development Award NS00647 from the National Institute for Neurological and Communicative Disorders and Stroke to Dr. Powers.

Address reprint requests to: William J. Powers, M.D., Division of Radiation Sciences, Mallinckrodt Institute of Radiology, Washington University School of Medicine, 510 South Kingshighway, St. Louis, Missouri 63110.