

Spontaneous Cerebellar Hemorrhage after Coronary Artery Bypass Surgery

Douglas E. Anderson^a, José Biller^b, Ronald R. Schreiber^c

^aDivision of Neurosurgery (Department of Surgery), ^bDepartment of Neurology, ^cDivision of Cardiology (Department of Internal Medicine), Loyola University Medical Center, Maywood, Ill., USA

Key Words. Cerebellar hemorrhage · Coronary artery bypass surgery · Cranial computerized tomography

Abstract. A patient had a spontaneous intracerebellar hemorrhage following coronary artery bypass surgery. His clinical course, characterized by headaches, gait ataxia, and then signs of brain stem compression, is emphasized. Following diagnosis by cranial computerized tomography, successful surgical decompression by suboccipital craniotomy was performed. Reports of neurologic complications, especially intracranial hemorrhage, following coronary artery bypass surgery, are reviewed. Possible pathophysiologic mechanisms for these problems, and the diagnosis and treatment of this previously undescribed complication of coronary artery bypass surgery are discussed.

Introduction

Spontaneous parenchymatous brain hemorrhage accounts for approximately 10% of all strokes in the United States [10], and continues to be associated with a high morbidity and mortality rate [11]. Cerebellar hemorrhage itself represents about 10% of all spontaneous intracerebral hemorrhages, and may produce a life-threatening syndrome. The early clinical picture of a hemorrhage into the cerebellum is characterized by headaches,

dizziness, vertigo, nausea, vomiting, and inability to stand or walk [3]. In the vast majority of instances, operative intervention is necessary for survival and optimal outcome [4–8]. Cranial computerized tomography (CT) demonstrates accurately the localization and dimensions of the hemorrhage as well as the degree of ventriculomegaly and associated brain edema [9]. Cerebellar hemorrhage is most commonly secondary to arterial hypertension, but may occur with vascular malformation, neoplasms, trauma, bleeding dis-

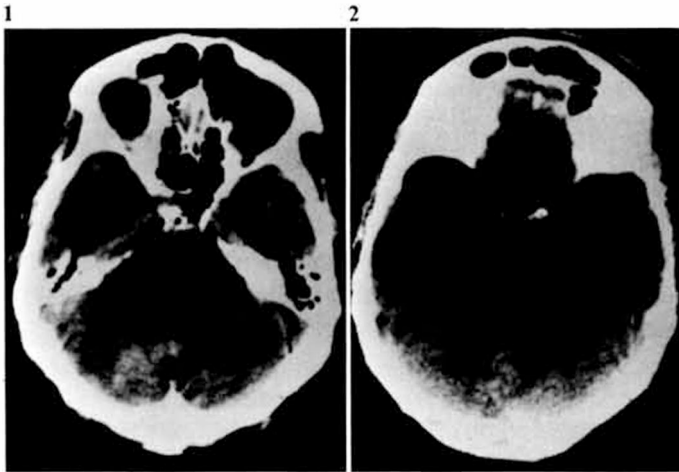


Fig. 1. CT of the posterior fossa demonstrating a high-density lesion in the posterior aspect of the right cerebellar hemisphere.

Fig. 2. A slightly higher CT scan showing the superior aspect of the lesion in figure 1, distortion and right to left displacement of brain stem structures, and evidence of ventricular (temporal horn) enlargement.

orders, vasculitis or extravasation into a hemorrhagic infarction. This report describes the unusual, and to our knowledge, previously unreported occurrence of a cerebellar hemorrhage in the immediate postoperative period following coronary artery bypass surgery.

Case Report

In February 1983, a 54-year-old normotensive, diabetic male underwent aortocoronary vein graft bypass to the diagonal branch of the left anterior descending, diagonal, obtuse marginal, ramus and right coronary arteries. Pump time was 1 h and 40 min and cross clamp time was 70 min. Patient's chest tubes, Swan Ganz catheter, arterial line and Foley catheter were all discontinued at appropriate intervals. 3 days postoperatively, he noticed a mild to moderate bifrontal and occipital headache. The headache progressed, and approximately 10 days postoperatively he developed nausea and vomiting. In addition, he noted a tendency to veer towards the right side on walking and had a single episode of binocular horizontal diplopia. A neurological consultation was then immediately requested. He had no prior history of headaches, trauma or focal neurological disturbances. Medication included digoxin, propranolol (Inderal), aspirin, dipyridamole (Persantin) and tolbutamide (Orinase).

During the examination, he was awake, oriented to place, person, time and situation, and had two 15-second episodes of 40 beats/min bradycardia. Otherwise his vital signs were normal. He responded to questions slowly with slight hoarseness but no dysarthria. He had bilateral horizontal nystagmus with the fast component in the direction of gaze. There was a minimal right pronator drift with slight right-sided terminal dysmetria and appendicular ataxia. Funduscopy was normal. The remainder of the neurological examination was unremarkable. Routine studies of blood yielded normal results. Emergency uninfused CT demonstrated a right cerebellar hemorrhage (fig. 1) with displacement of the fourth ventricle and mild to moderate temporal horn enlargement (fig. 2). Emergency neurosurgical consultation was requested. After pretreatment with mannitol (Osmitol 20%), steroids (Decadron), and hyperventilation, a suboccipital craniotomy in the sitting position was performed. A corticotomy was made in the right cerebellar hemisphere just lateral to the midline. This immediately revealed approximately 30 mm of acute and subacute blood clot which was resected. The clot was found to have shifted vermian structures significantly across the midline to the left. The wound was irrigated and closed in the usual fashion. Postoperative course was uncomplicated. Pathologic examination disclosed no evidence of tumor or arteriovenous malformation. Follow-up examination 12 months after surgery showed a completely normal neurological examination.

Discussion

Most instances of neurological dysfunction after open heart surgery result from a combination of predisposing and operative factors. Cerebral complications have been attributed to macroembolization of air or particulate matter, microembolization of air, fat, platelet-fibrin aggregates, foreign particles or antifoaming agents. Other causes of brain damage relate to inadequate cerebral perfusion in patients predisposed by prior cerebrovascular disease, prolonged cardiopulmonary bypass, or low perfusion pressures due to inadequate capillary bed perfusion [1–12]. The pathologic entities usually described include focal or multifocal infarcts, emboli lodged in small cerebral vessels, cerebral edema and intracranial hemorrhage [5–7], usually petechial, pervascular or focal in the subarachnoid space. Intracranial hemorrhage has been described by *Humphreys* et al. [5] to occur in children who had repair of congenital heart defects. *Hungxi* et al. [6] reported 20 cases of intracranial hemorrhage following open heart surgery. In their series, almost all patients were under the age of 15, and symptoms appeared within 24 h of surgery. Additionally, 85% of the hemorrhages occurred in the epidural or subdural space. In only 2 cases was the hemorrhage in the brain substance or the subarachnoid space. The author found at surgery, tearing of the superior sagittal sinus in 3 cases, bleeding from parasagittal veins in 1 case, and dural vessel oozing in 2 cases. Additionally, autopsies in 4 cases revealed subarachnoid hemorrhage in 2 cases, diffuse petechial hemorrhage in 1, and intracerebral hematoma with intraventricular extension in 1. Intraoperative anticoagulation, hypertonic perfusion, excessive diuresis, and venous and/or arterial hypertension during

or after perfusion were postulated as potential pathogenetic mechanisms by the authors. In our patient, no history of hypertension could be elicited prior to, during or after coronary vein graft bypass surgery, 'pump time' was not prolonged and no coagulation abnormalities were detected prior, during, or after surgery. Symptoms progressed somewhat slowly initially. Later, however, there was progression of neurologic signs compatible with brain stem compression, emphasizing the often unpredictable course of some cerebellar hemorrhages. The pathogenesis of cerebellar or other intracranial hemorrhages after open heart surgery is unclear, but undoubtedly is multifactorial and dependent on the combined effects of anticoagulation, venous or arterial hypertension and perioperative embolism.

References

- 1 Aguilar, M.J.; Gerbode, F.; Hill, J.D.: Neuro-pathological complications of cardiac surgery. *J. thorac. cardiovasc. Surg.* 61: 676–685 (1971).
- 2 Bricley, J.B.: Neuropathological findings in patients dying after open heart surgery. *Thorax* 18: 291–304 (1963).
- 3 Caplan, L.R.: Intracerebral hemorrhage; in Tyler, Dawson, *Current neurology*, vol. 2, chapter 12, pp. 185–205 (Houghton Mifflin, Boston 1979).
- 4 Fisher, C.M.; Picard, E.H.; Polak, A.; Dalal, P.; Ojemann, R.G.: Acute hypertensive cerebellar hemorrhage: diagnosis and surgical treatment. *J. nerv. ment. Dis.* 140: 38–57 (1965).
- 5 Humphreys, R.P.; Hoffman, H.J.; Mustard, W.T.; Trusler, G.A.: Cerebral hemorrhage following heart surgery. *J. Neurosurg.* 43: 671–675 (1975).
- 6 Hungxi, S.; Xiaogin, H.; Kongsoon, L.; Jiaquians, G.; Letien, X.: Intracranial hemorrhage and hematoma following open heart surgery; in Becker, *Psychopathological and neurological dysfunctions following open heart surgery*, pp. 293–299 (Springer, Berlin 1982).

- 7 Krous, H.F.; Tenckhoff, L.; Gould, N.S.; Stamm, S.J.: Subdural hematoma following open heart operations. *Ann. thor. Surg.* 19: 269–276 (1975).
- 8 LaBauge, R.; Boukobza, M.; Zinszher, J.; Blard, J.M.; Pages, M.; Salvanig, P.: Hématomes spontanés du cervelet. *Revue neurol.* 139: 193–204 (1983).
- 9 Little, J.R.; Tubman, D.E.; Ethier, R.: Cerebellar hemorrhage in adults. *J. Neurosurg.* 48: 575–579 (1978).
- 10 Mohr, J.P.; Caplan, L.R.; Melski, J.W.; Goldstein, R.J.; Duncan, G.W.; Kistler, J.P.; Pessin, M.S.; Bleich, H.L.: The Harvard Cooperative Stroke Registry: a prospective registry. *Neurology* 28: 754–762 (1978).
- 11 Ojemann, R.G.; Mohr, M.P.: Hypertensive brain hemorrhage; in Keener, *Clinical neurosurgery*, vol. 23, chapter 17, pp. 220–244 (1976).
- 12 Thomassen, R.W.; Howbert, J.P.; Winn, D.F., Jr.; Thompsen, S.W.: The occurrence and characterization of emboli associated with the use of a silicon antifoaming agent. *J. thorac. cardiovasc. Surg.* 41: 611–622 (1961).

Received: May 11, 1984

Accepted: July 11, 1984

Douglas E. Anderson, MD,
Division of Neurological Service,
Loyola University,
Stritch School of Medicine,
2160 S. First Avenue,
Maywood, IL 60153 (USA)