

## RECONSTRUCTION OF CAROTID ARTERY IN RADICAL NECK DISSECTION

Hiroshi OKAMURA, M.D., Koshiro NAKAMURA, M.D.,  
and Naoaki YANAGIHARA, M.D.

*Department of Otolaryngology, School of Medicine,  
Ehime University, Ehime, 791-02 Japan*

---

No permanent cure of head-and-neck cancer can be expected when the cancer infiltrates into the wall of the carotid artery. When the carotid artery was resected, the resultant hemiplegia poses very difficult postoperative rehabilitation problems, even though the cancer is eradicated. The recent development of vascular surgery has made reconstruction of the carotid artery feasible. In this paper, the authors reported the indications of reconstruction of the carotid artery in radical neck dissections and the surgical procedures. The indication of reconstruction of the carotid artery is determined by using of angiography, CT-scan and echography. Especially, echography is useful for determining the possibility of reconstructing the carotid artery. In the case of the infiltration type, we can start to remove tumor after preparing for the reconstruction of the carotid artery. The principle of surgical procedures consists of by-pass shunt with a vascular graft between the common and internal carotid arteries, excision of the artery with tumor and insertion of a vascular graft with end-to-end anastomoses. Concerning the selection of a vascular graft, an auto-vein graft is preferable to a synthetic graft in consideration of the postoperative patency of the vascular flow. Moreover, in the case of reconstructing the artery, preoperative irradiation has often been applied and a wide removal of the soft tissue is required, so it is recommended that the myocutaneous flap be used to cover the reconstructed area.

---

No permanent cure of head-and-neck cancer can be expected when the cancer cells infiltrate into the wall of the carotid artery. When the carotid artery was resected, the resultant hemiplegia poses very difficult

postoperative rehabilitation problems, even though the cancer is eradicated. The recent development of vascular surgery, however, has made reconstruction of the carotid artery feasible. In selected patients with a neck tumor infiltrating the carotid artery, a radical neck dissection with the use of reconstruction of the carotid artery can be carried out without risks of brain damage.

In this paper, the authors report the indications of the reconstruction of the carotid artery in radical neck dissections and the surgical procedures.

### *Indication*

At the authors' clinic, the indication of reconstruction of the carotid artery is determined by using of angiography, CT-scan and echography. Especially, echography, which is a non-invasive examination, has some advantages in investigating the relationship between the tumor and the carotid artery preoperatively. Echography makes it possible to display the pulsation of the wall of the carotid artery and the anatomical situation of the tumor and the artery in detail.

From our experience of echographic examinations, we could classify anatomical situations of the tumor and the carotid artery into the following two types; the compression type and the infiltration type, depending on whether or not the echo from the base of the tumor is recorded. Figure 1 shows an example of the compression type recorded from a case of papillary adenocarcinoma of the thyroid gland. The operation showed that the tumor did not infiltrate into the wall

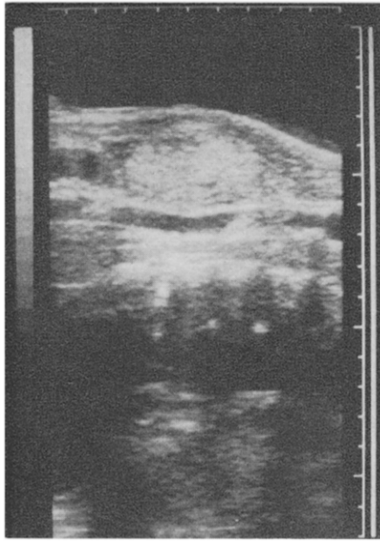


Fig. 1. An example of the compression type recorded by an echography. The wall of the carotid artery is well displayed.

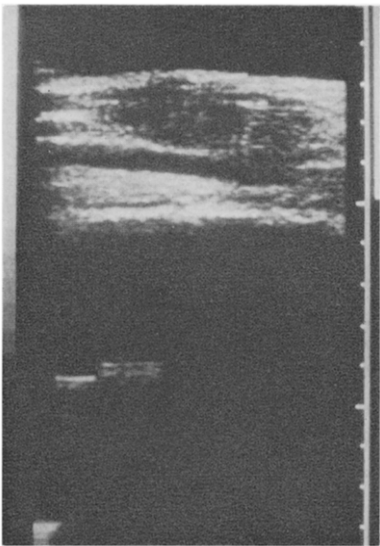


Fig. 2. An example of the infiltration type recorded by an echography. The wall of the carotid artery disappears.

of the carotid artery and, therefore, the artery was conserved. Figure 2 shows an example of the infiltration type recorded from a case of cervical lymphnode metastasis due to a tongue cancer, and the operation showed that the tumor infiltrated into the wall of the carotid artery. In the case of the

infiltration type, there is a possibility that the tumor infiltrates into the wall of the carotid artery, so we need to prepare for reconstructing the carotid artery.

#### *Surgical Procedures*

The principle of reconstruction of the carotid artery consists of by-pass shunt with a vascular graft between the common and internal carotid arteries, excision of the carotid artery with tumor and, then, insertion of a vascular graft with end-to-end anastomoses by using an atraumatic needle and 4-0 prolene threads. To prevent recurrence of the tumor, the site of the anastomosis should have a margin longer than 2 cm at least from the end of the tumor on the carotid artery.

An auto-vein graft is preferable to a synthetic vascular graft, and the reason will be discussed later. When we operate the oral or pharyngeal cavity with the reconstruction of the carotid artery simultaneously, the cavity should be closed watertight at the first step and, then, an auto-vein graft should be selected. We make it a rule to cover the operated area with a myocutaneous flap.

#### *Case Report*

*Case 1.* The patient, who was a 49-year-old male with tongue cancer  $T_2N_0M_0$ , was treated by using a synthetic vascular graft. The primary lesion was treated by radiation therapy and was well controlled, but a cervical lymph node metastasis was found one year and three months later. The CT-scan showed that the tumor surrounded the carotid artery. Since we did not need to operate the oral and pharyngeal cavities, a synthetic vascular graft (Dacron double velour) with the diameter of 6 mm was utilized. As the first step, a by-pass shunt inserted into the preclotted graft was made between the common and internal carotid arteries and, then, the tumor with the carotid artery was removed. Finally, end-to-end anastomoses of the graft were performed to the internal and common carotid arteries respectively (Fig. 3). The operated area was covered by the pectoral

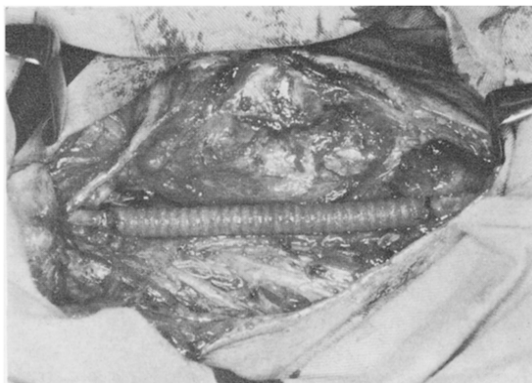


Fig. 3. The reconstruction of the carotid artery by using a synthetic vascular graft.

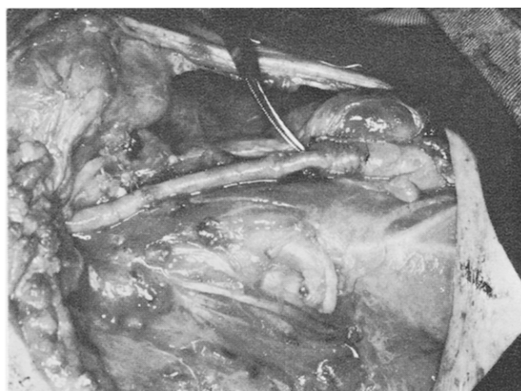

Fig. 4. The reconstruction of the carotid artery by using an auto-vein graft.

major myocutaneous flap. The ultrasonic Doppler method showed the patency of the reconstructed artery during the one month after the operation. However, that part was thereafter obliterated by a formation of thrombus, but no postoperative complications including hemiplegia occurred. Unfortunately, this patient died due to a metastasis of the tumor to the cervical vertebra 10 months later.

*Case 2.* The patient, who was a 63-year-old male with hypopharyngeal cancer  $T_2N_3M_0$ , was treated by using an auto-vein graft. The cervical metastatic tumor was diagnosed to have infiltrated into the wall of the carotid artery through CT-scan, angiography and echography. In this case, we planned to remove the hypopharyngeal tu-

mor and to reconstruct the carotid artery simultaneously. To avoid the contamination by saliva of the reconstructed area of the carotid artery, the hypopharyngeal cavity was closed watertight after the tumor was removed and, then, the carotid artery was reconstructed by using a reversed auto-vein graft obtained from the great saphenous vein (Fig. 4). The details of the method were the same as the first case. The operated area was covered by the latissimus dorsi myocutaneous flap. The operation was successful, and no postoperative complications occurred. The patient has been well controlled these two years under our following-up observation.

#### *Discussion and Conclusion*

In general, a radical neck dissection cannot be performed safely when the tumor has already infiltrated into the wall of the carotid artery. When the carotid artery was ligated or resected, the resultant hemiplegia poses very difficult postoperative rehabilitation problems (CONLEY, 1957; MOOR *et al.*, 1969; KONNO *et al.*, 1981). With the development of vascular surgery, a radical neck dissection with the use of reconstruction of the carotid artery can be carried out without risks of brain damage (CONLEY, 1957; LORE, 1965; INOKUCHI and YAGI, 1967; TOHYA *et al.*, 1981).

The recent advances of diagnostic methods, especially of the imaging diagnosis, have made it possible to clarify preoperatively the detailed relationship between the tumor and the carotid artery. However, it is not easy to determine the indications of reconstruction of the carotid artery preoperatively, even though angiography and CT-scan are applied. On this point, echography is useful for determining the possibility of reconstructing the carotid artery, as mentioned above. In the case of the infiltration type, we can start to remove tumor after preparing for the reconstruction of the carotid artery.

Concerning the selection of a vascular graft, an auto-vein graft is preferable to a synthetic graft for the following two reasons.

First, the diameter of a synthetic graft is required to be wider than 6 mm in consideration of the postoperative patency of the vascular flow. However, the diameter of the internal carotid artery is not wide enough for the above requirement in many cases. Hence the possibility of obliterating the reconstructed artery postoperatively due to a formation of thrombus, as shown in the first case. Next, when we operate the oral or pharyngeal cavity with a simultaneous reconstruction of the carotid artery, there is the possibility of contaminating the reconstructed area by saliva. In such a case, the choice of an auto-vein graft might be safer than that of a synthetic graft, and the use of the great saphenous vein in reversed fashion is suitable for the reconstruction.

Moreover, in the case of reconstructing the artery, preoperative irradiation has often been applied, and a wide removal of the soft tissue including the sternocleidomastoid muscle is required, so it is recommended that the myocutaneous flap be used to cover the reconstructed area.

The introduction of the reconstruction of the carotid artery might reduce the mortality

due to advanced head-and-neck cancer. But, as mentioned above, the reconstruction should be preceded by careful considerations of the anatomical situation of the tumor and the carotid artery by means of those imaging diagnostic methods that have recently advanced.

#### References

- CONLEY, J.J.: Carotid artery surgery in the treatment of tumors of the neck. *Arch. Otolaryngol.* **65**: 437-446, 1957.
- INOKUCHI, K., and YAGI, H.: Vascular reconstruction for radical neck dissection. *Otologia Fukuoka* **13**: 97-104, 1967.
- KONNO, A., TOGAWA, K., and IIZUKA, K.: Analysis of factors affecting complications of carotid ligation. *Ann. Otol.* **90**: 222-226, 1981.
- LORE, J.M.: Vascular surgery in operations of the head and neck. *Arch. Otolaryngol.* **74**: 646-651, 1965.
- MOOR, O.S., KARLAN, M., and SIGLER, L.: Factors influencing the safety of carotid ligation. *Am. J. Surg.* **118**: 666-668, 1969.
- TOHYA, M., OBUCHI, M., TANAKA, N., KITAO, Y., KURODA, T., and ISHIKAWA, T.: The vascular reconstruction of the carotid artery with radical neck dissection. *Otologia Fukuoka* **27**: 776-781, 1981.