

PROGRESSIVE NEURONAL DEGENERATION OF CHILDHOOD WITH LIVER DISEASE

A PATHOLOGICAL STUDY

by B. N. HARDING¹, J. EGGER¹, B. PORTMANN², and M. ERDOHAZI¹

(From ¹The Institute of Child Health and Hospital for Sick Children, Great Ormond Street, London WC1N 3JH and ²King's College Hospital and School of Medicine and Dentistry, Denmark Hill, London SE5 9RS)

SUMMARY

A clinicopathological study of 10 cases of progressive neuronal degeneration of childhood is reported. In the typical clinical course early developmental delay is followed by intractable epilepsy leading rapidly to death, in some cases in liver failure. Diagnostically useful investigations include characteristic EEG changes, evidence of progressive atrophy (particularly occipital) on CT scan, absent or reduced visual evoked responses, and biochemical evidence of abnormal liver function in many cases before commencement of anticonvulsant therapy. Siblings of 4 of the reported cases suffered a similar clinical disorder. Macroscopic appearances of the brain varied from virtual normality to severe atrophy. The cortical ribbon showed patchy lesions, but the calcarine cortex was characteristically involved, narrowed, granular and discoloured. Histological damage to the cerebral cortex was widespread but patchily accentuated. In milder lesions status spongiosus, astrocytosis and neuronal loss occurred only in the superficial cortex, in moderately affected areas deeper laminae were involved, and in the most severe lesions the entire cortex was reduced to a thin densely gliotic remnant. There was a pronounced tendency for the striate cortex to be the worst affected area. Of subcortical structures the thalamus, hippocampus and cerebellum were particularly severely involved. There was usually accompanying liver disease, particularly a subacute hepatitis comprising massive fatty degeneration, hepatocyte loss, bile duct proliferation and fibrous scarring, with or without cirrhosis. These pathological features are distinct from other combined degenerations of liver and brain and the cortical lesions differ significantly from the neuropathological sequelae of birth injury or severe epilepsy. Hepatic pathology is distinctive and does not appear to be related to drug therapy. It is concluded that these 10 cases of progressive neuronal degeneration of childhood with concomitant liver disease, together with a small number of previously reported cases, are a nosological entity which may result from an autosomal recessive inherited metabolic defect, the nature of which is at present obscure.

INTRODUCTION

In 1931 Alpers described diffuse cerebral cortical degeneration in a child who had suffered marked developmental delay and severe seizures. Subsequent cases have

Correspondence to: Dr B. N. Harding, Department of Neuropathology, Hospital for Sick Children, Great Ormond Street, London WC1N 3JH.

© Oxford University Press 1986

either been labelled eponymously or given descriptive titles such as poliodystrophia cerebri progressiva (Christensen and Krabbe, 1949), diffuse progressive cerebral cortical atrophy (Ford *et al.*, 1951), spongy glioneuronal dystrophy (Jellinger and Seitelberger, 1970), or diffuse cerebral degeneration in infancy (Blackwood *et al.*, 1963). Many heterogeneous cases have been placed in this category including examples of birth injury, postepileptic encephalopathy, and a miscellany of obscure grey matter degenerations in children, as well as a hard core of apparently idiopathic infantile cerebral degenerations, some with familial occurrence. In recent years, however, a number of cases of progressive neuronal degeneration of childhood (PNDC) with associated liver disease have been reported (Blackwood *et al.*, 1963; Wefring and Lamvik 1967; Cameron *et al.*, 1968; Jellinger and Seitelberger, 1970; Huttenlocher *et al.*, 1976). Over the past decade we have had the opportunity to examine post-mortem 10 cases of PNDC with concomitant liver degeneration. In the present paper we report the pathological findings which have been found to be consistent and characteristic of these cases, and which are correlated with the clinical observations.

MATERIAL AND METHODS

In 2 cases a complete post-mortem examination was performed in our laboratory. In the other 8 cases post-mortem was performed elsewhere, but the fixed brain and sections of liver were available for study, except in Case 3 (no liver sections were available) and Case 9 (neuropathological examination was limited to paraffin-embedded blocks of pons, cerebellar hemisphere, occipital lobe, and a coronal section of one hemisphere with frontal and temporal cortex, basal ganglia and midbrain).

In general, blocks surveying the major regions of the cerebral cortex, white matter, basal ganglia, brainstem and cerebellum were taken for paraffin histology, and sections stained with routine histological stains as well as Luxol fast blue-cresyl violet, phosphotungstic acid-haematoxylin, and Holmes and Glees-Marsland silver impregnations. Frozen sections stained for fat were also examined.

CASE HISTORIES AND PATHOLOGICAL FINDINGS

Case 1 (NP18.75)

Clinical history. Pregnancy and delivery were normal; this boy sat at 11 months, crawled at 12 months and walked at 18 months. He was always clumsy and speech development was slow. When 3 years old he started having seizures, and after an episode of status epilepticus, at the age of 6, partial seizures and status occurred frequently. Response to phenobarbital, carbamazepine and chlormethiazole was poor. He was hypotonic and later developed pyramidal signs. Liver function tests were abnormal at 6.5 years (SGOT 121 IU/l (normal < 17 IU/l), SGPT 19 IU/l (normal < 17 IU/l)). The EEG showed asymmetric slow activity of high amplitude and polyspikes, and visual evoked responses (VERs) were asymmetric. He died in liver failure aged 7.5 years. He had received sodium valproate for the last ten weeks, and it was thought that this had aggravated an already existing liver disorder. His brother also suffered from progressive neuronal degeneration with liver disease and died in liver failure aged 9.5 years.

Autopsy (Dr A. G. Ackerley). This showed bronchopneumonia. The liver weighed 550 g (normal 700 g) and was intensely yellow. The brain (fixed weight 1248 g) was macroscopically normal.

Histological findings. CNS. Throughout the cerebral cortex there was a general but variable increase in astrocyte numbers, least in temporal cortex and confined to superficial laminae, but more obvious in frontal and parietal areas where pairs and small groups of astrocytic nuclei, some with Alzheimer type II morphology, permeated laminae I–IV. There was an associated mild fibrous gliosis, particularly in subpial and periventricular zones. Neuronal loss appeared very slight but many nerve cells were shrunken. In both hemispheres the occipital cortex was more severely affected. On the right, patches of sponginess in laminae II and III, moderate neuronal loss and astrocytic proliferation occurred. The right striate cortex showed complete loss of lamination, only few granule cells and shrunken pyramidal cells remained, with replacement by large astrocytes, many Alzheimer type II, others gemistocytic, forming a dense feltwork of stout glial fibres. On the left, the parastriate cortex and focal areas on the superior and lateral surfaces were as severely affected as the right striate cortex. The left striate cortex was only slightly better preserved. Frozen sections revealed abundant sudanophil lipid within phagocytes in the cortex.

The white matter was gliotic, but myelin was normally stained. There was moderate neuronal loss and some gliosis in the Sommer sector of the hippocampus, in the putamen and claustrum and the lateral geniculate nucleus, but only astrocytosis in other thalamic nuclei and the caudate. In the cerebellum there was generalized severe loss of Purkinje cells and proliferation of Bergmann glia throughout the hemispheres. The vermis was less affected. Several minute old scars with Purkinje and granule cell loss and heavy fibrous gliosis were also present. The dentate nucleus showed nerve cell loss, sponginess and gliosis. The brainstem was rather gliotic, but the olives particularly showed neuronal loss and gliosis. There was also moderate loss of anterior horn cells from the cervical cord.

Liver. An on-going hepatic process was indicated by extensive hepatocyte degeneration, severe panlobular microvesicular fatty change, and both portal and lobular mixed inflammatory cell infiltration. Numerous ductule-like structures were present at the margins of the portal tracts. The process was of long-standing, for areas of previous liver cell loss were replaced by fibrous tissue.

Case 2 (NPI.78)

Clinical history. Pregnancy and delivery were normal. This boy had recurrent episodes of vomiting and was investigated for failure to thrive when 3 months old. At 5 months he was hypotonic and abnormal liver function (AST 51 IU/l (normal 6–17 IU/l), ALT 62 IU/l (normal 2–12 IU/l)) and raised CSF protein (3 g/l) were recorded. The EEG showed excess of slow waves and poor rhythmic activity. VERs were present but the initial components were ill-defined. A CT brain scan showed slight cortical and central atrophy. When 15 months old he started to have myoclonic attacks, which were treated with diazepam. He died aged 21 months.

Autopsy (Dr F. E. Scott). This revealed bronchopneumonia. The small liver weighed 128 g (normal 370 g) and was finely nodular.

Macroscopic neuropathological findings. The fixed brain weighed 736 g (normal for age 1060 g), the hindbrain 129 g. The cerebellum appeared relatively large. On coronal sections, the ventricular system was enlarged while the centrum semiovale and corpus callosum were reduced in bulk. In both hemispheres the cerebral cortex over the vertex and medial surface of the frontal and parietal lobes from the level of the anterior commissure to the parieto-occipital fissure was greatly shrunken and dark brown (fig. 1A). A similar almost symmetric lesion affected the calcarine cortex extending to the occipital poles (fig. 1B). Elsewhere the cortex appeared normal. Both thalamic and caudate nuclei were flattened, but the lentiform nuclei were normal. The hindbrain and cord also appeared normal.

Histological findings. CNS. A generalized neuronal loss affected all regions of the cerebral cortex, even macroscopically normal areas. In the least affected areas, such as temporal and insular cortex, there was moderate but patchy nerve cell loss from laminae II and III often with spongy degeneration in lamina II. Laminar architecture was retained; neurons in the deeper layers were preserved. There was also a considerable astrocytic proliferation and fibrillary gliosis in the molecular layer, and a large number of macrophages packed with sudanophilic lipid. Macroscopically abnormal areas, such as parietal and frontal cortex, showed more severe lesions (fig. 2A, B): spongy degeneration extended into

the deeper parts of lamina III, there was severe neuronal depletion but preservation of large pyramidal cells in lamina V, large numbers of microglial cells, prominent capillaries, and numerous swollen hypertrophic astrocytes producing a marked fibrous gliosis. Occipital regions were similar but the striate cortex was even more severely affected: thin and shrunken, it contained virtually no nerve cells,

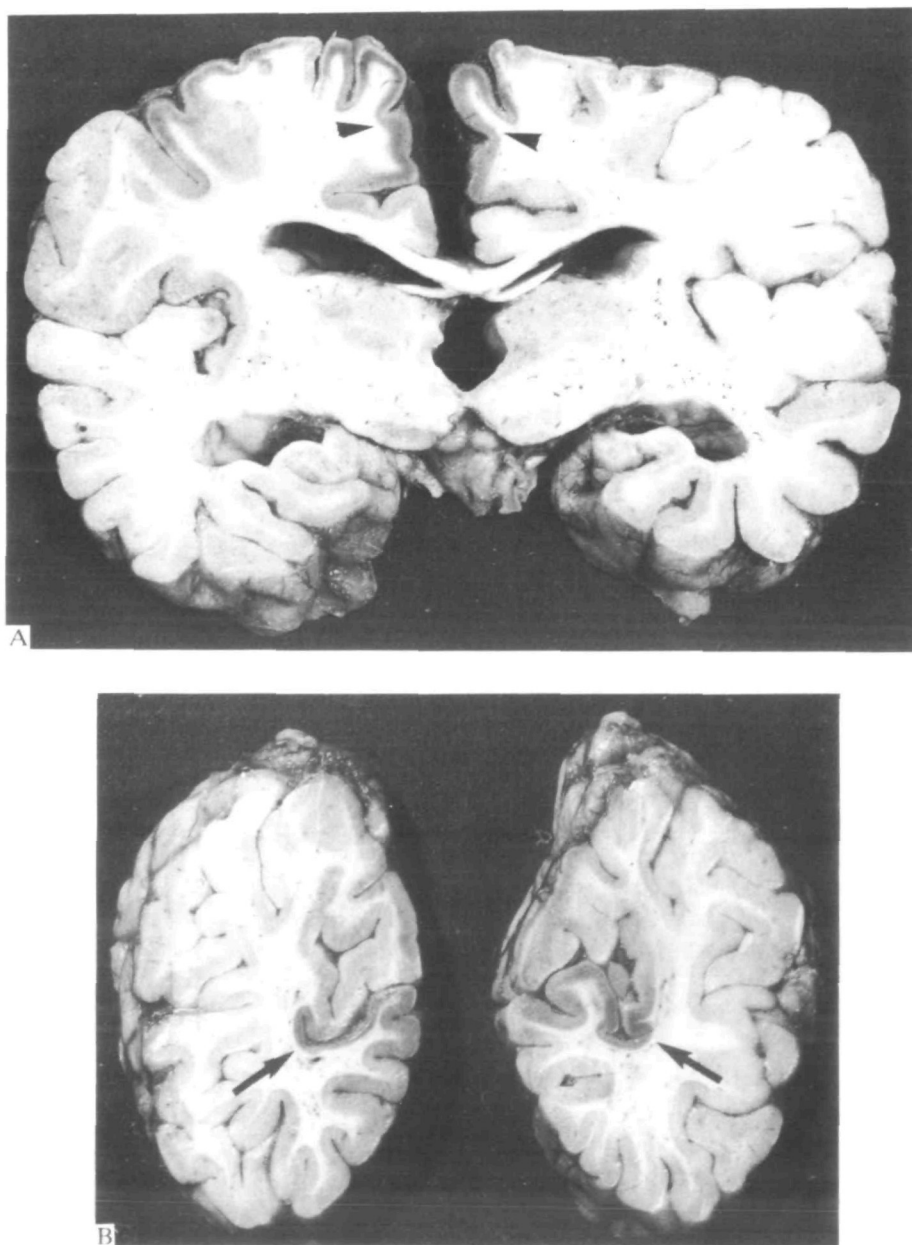


FIG. 1. *Case 2.* Coronal sections of the brain. A, midthalamic level; B, occipital lobes. There is bilateral and almost symmetric narrowing and discolouration of the posterior frontal cortex (arrowheads) and striate cortex (arrows).

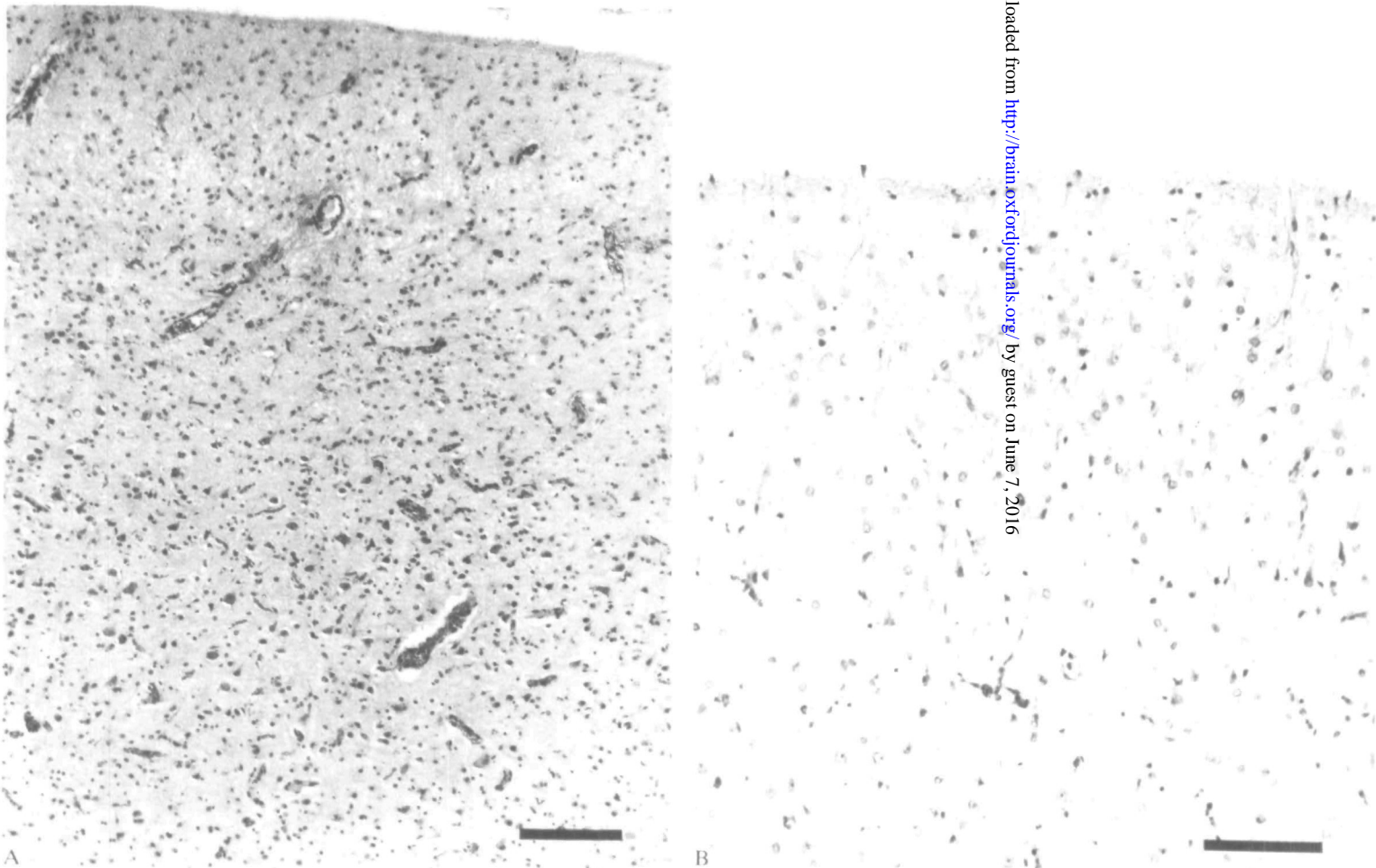


FIG. 2. Case 2. Histology of frontal cortex. Moderately severe lesion with gliosis, spongy change and loss of neurons in superficial layers but preservation of neurons in deeper laminae. Haematoxylin and eosin. A, bar = 0.2 mm; B, bar = 0.1 mm.

only many capillaries, plump astrocytes and lipid-laden macrophages, supported by a dense glial network.

The white matter was generally well preserved; slight pallor of myelin staining occurred beneath the grossly affected cortical areas and sudanophil material was present in perivascular macrophages in the centrum semiovale and internal capsule. The pyramidal layer of the hippocampus showed severe neuronal loss; h2 was the least affected sector. In the thalamus there was considerable nerve cell loss, especially in ventral and lateral nuclei where microglia formed neuronophagic nodules around shrunken degenerate neurons. Astrocytic proliferation and Alzheimer type II glia were also present. Gliosis and a more moderate neuronal loss were noted in the lateral geniculate nucleus, and also in the caudate. In the cerebellum patches of slight Purkinje cell loss and Bergmann gliosis occurred, the dentate nucleus being more noticeably depleted of neurons. The inferior olives also showed some nerve cell loss.

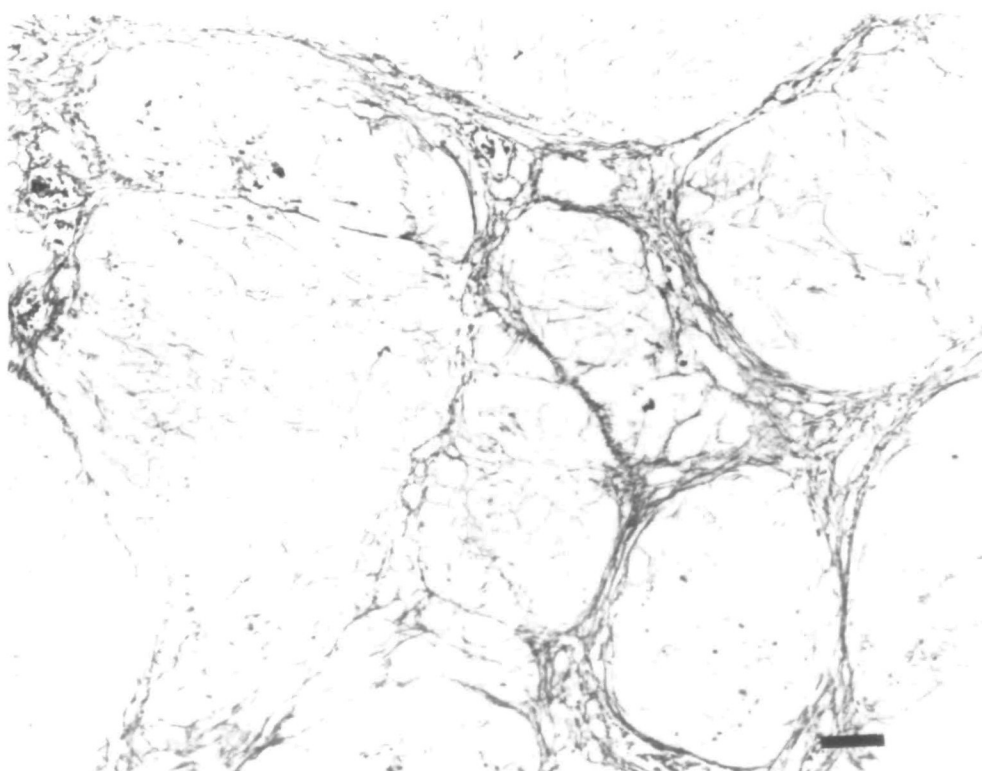


FIG. 3. Case 2. Liver, post-mortem specimen, showing annular postnecrotic fibrous septa and micronodular cirrhosis. Gordon and Sweet's silver impregnation for reticulin; bar = 0.1 mm.

Liver. The lobular hepatic architecture was distorted by thin 'postnecrotic' type bridging septa of collagen and reticulin producing a micronodular cirrhotic pattern (fig. 3). Considerable microvesicular fatty change with large ballooned hepatocytes was particularly prevalent in the periportal and periseptal areas, often associated with chronic inflammation. There were also foci of on-going parenchymal necrosis.

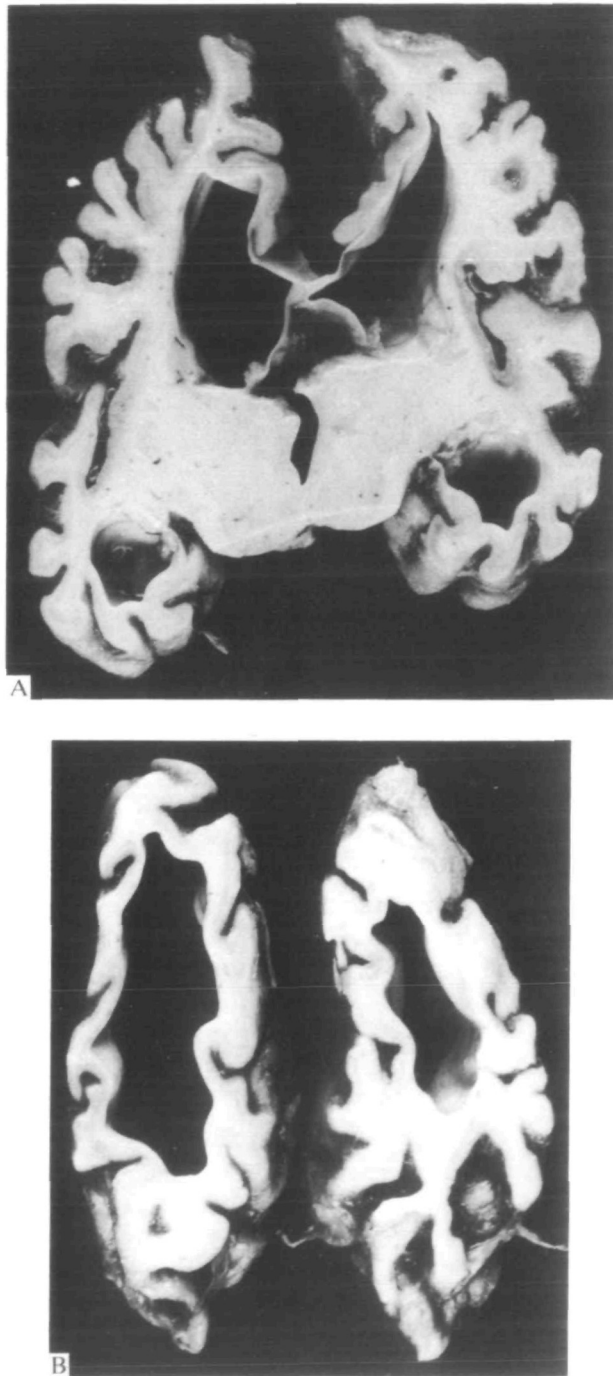


FIG. 4. *Case 3.* Coronal sections of the brain. *A*, midthalamic level; *B*, occipital lobes. All cortical regions show uniformly severe atrophy. There is ventricular dilatation and shrinkage of the white matter.

Case 3 (NP39.78)

Clinical history. Pregnancy and delivery were uneventful, and this girl developed normally until she was 4 weeks old when she began to suffer focal seizures and ceased making developmental progress. On examination she was hypotonic and thought to be blind. Routine investigations, including amino acids, serial viral titres, immunoglobulins and liver function tests were normal at the age of 6 weeks. Liver function tests were not repeated. The EEG showed slow waves of high amplitude and polyspikes of lower amplitude. VERs were absent. CT scans showed rapidly progressive cortical atrophy and low density areas in the left occipital white matter. She died when 12 months old. Her younger sister suffers from a progressive disorder with intractable seizures, mental retardation and liver disease.

Autopsy (Dr J. W. Nicholas). This showed bronchopneumonia.

Macroscopic neuropathological findings. The fixed brain weighed 340 g (normal for age 950 g), the brainstem and cerebellum 75 g. It was grossly shrunken with slender, hard convolutions and wide sulci. The hindbrain appeared better preserved. Coronal sections (fig. 4A, B) showed markedly dilated ventricles, greatly reduced white matter, and a thin severely gliotic cortical ribbon throughout the hemispheres, although the occipital cortex seemed the worst affected. The hippocampi were very small, the thalamus was shrunken, and the caudate nucleus flattened. Superior cerebellar folia appeared

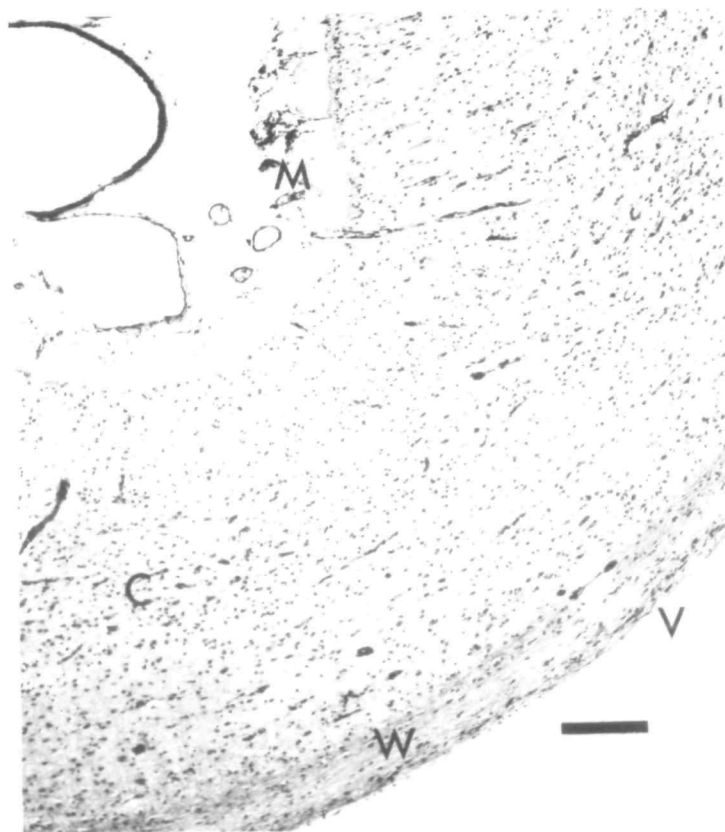


FIG. 5. *Case 3.* The calcarine cortex (C) and white matter (W) are reduced to a thin gliotic strip. V = ventricular cavity; M = leptomeninges. Haematoxylin and eosin; bar = 0.25 mm.

gliotic; the outline of the dentate nucleus was indistinct. The cerebral peduncles were narrow and the medullary pyramids grey.

Histological findings. CNS. All regions of the cerebral cortex showed severe neuronal loss. The orbital cortex was least affected, many nerve cells being preserved in laminae V and VI, some even in lamina III, and there was spongy change in lamina II. In most cortical areas only a minority of neurons in laminae V and VI remained; a heavy fibrillary gliosis, numerous capillaries and many lipid-laden macrophages were present. The occipital cortex, including the striate cortex, was worst affected: no neurons survived, only a residual thin gliomesodermal sheet (figs 5, 6).

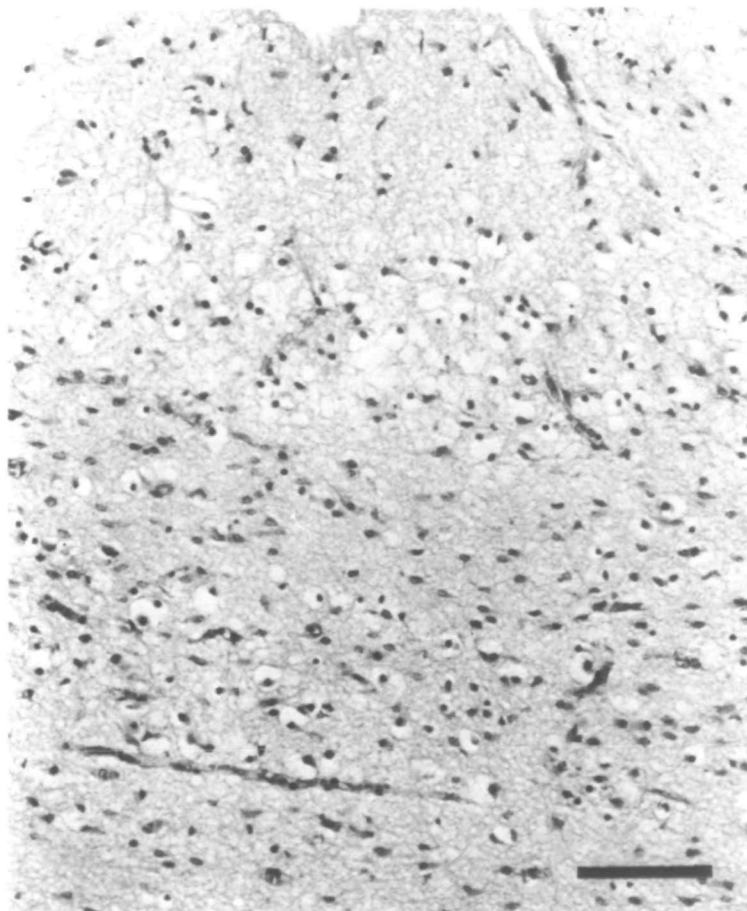

FIG. 6. Case 3. The calcarine cortex is shrunken, gliotic and devoid of neurons. Haematoxylin and eosin; bar = 0.1 mm.

The white matter of the centrum semiovale showed severe retardation of myelination, but no evidence of demyelination. However in the temporal and occipital lobes there was gross axon loss, dense fibrillary astrocytosis, and large numbers of lipid macrophages. In the hippocampus the pyramidal layer and dentate fascia showed severe neuronal loss, spongy degeneration and gliosis. In thalamic nuclei including the lateral geniculate only a few small islands of nerve cells remained and there was

spongy change, gliosis and prominent capillaries. Similar destruction occurred in the amygdala whereas other basal ganglia were only slightly gliotic. There was marked axonal loss in the internal capsule and long descending tracts of the brainstem and spinal cord. The substantia nigra showed neuronal loss, sponginess, astrocytic and microglial proliferation and prominent capillaries. Nerve cell loss and gliosis also occurred in the olives. In the cerebellum there was a moderate generalized Purkinje and granule cell loss; but focally, particularly at vascular boundary zones, it was severe with intense Bergmann gliosis. The dentate nucleus had sustained moderate neuronal loss.

Liver. No material was available.

Case 4 (NP60.78)

Clinical history. This girl was born to healthy nonconsanguineous parents. There had been a previous stillbirth. A normal pregnancy and forceps delivery was followed by a normal neonatal period and early milestones until 12 months of age when development ceased. From 13 months she had monthly episodes of lethargy and anorexia lasting about a week. At 16 months she was hypotonic and ataxic; plasma transaminases were elevated (AST 152 U/l (normal 15–45 U/l), ALT 138 U/l (normal 10–35 U/l)) and CSF protein was 1 g/l. She remained in status epilepticus from 17 months until her death six weeks later. Chlormethiazole, phenobarbital, carbamazepine, sodium valproate and dexamethazone were all used without success to control the seizures. Abnormal liver function persisted; a liver biopsy showed marked perlobular scarring and bridging between portal tracts, focal liver cell necrosis and inflammation of bridging septa. Assays of glucose-4-phosphatase, fructose-1-phosphatase, aldolase and fructose-1,6 diphosphatase were normal. The EEG was very abnormal with continuous generalized irregular slow activity of very large amplitude mixed with polyspikes.

Autopsy (Dr M Squier). Bronchopneumonia was present. The liver weighed 559 g (normal 345 g); the capsular surface was smooth, firmly nodular and yellow, and the cut surface yellow and greasy.

Macroscopic neuropathological findings. The fixed brain weighed 903 g (normal for age 1042 g), the hindbrain 127 g. On coronal sections the lateral and third ventricles were slightly dilated. The entire cortex was narrow and granular. This was more pronounced in orbital frontal, temporal and occipital cortex which were discoloured brown. The white matter appeared normal. The thalamus and caudate nucleus were rather shrunken, but the lentiform nucleus was normal.

Histological findings. CNS. All cortical areas were abnormal. The mildest change, gliosis in the molecular layer and status spongiosus in lamina II, occurred in the frontal lobes. Other areas, such as parietal, temporal and insular cortex showed spongy change and nerve cell loss extending into lamina III, and increased numbers of swollen astrocytes. In some parts of the parietal and insular cortex and most of the occipital lobe, gliosis and sponginess also affected lamina IV. But in the striate and parastriate areas the lesion involved all laminae. Very few nerve cells remained, there were many hypertrophic astrocytes, a dense fibrillary gliosis and numerous capillaries. Abundant sudanophil lipid was present in glial cells and macrophages. The underlying white matter showed slight myelin pallor, and a marked astrocytic fibrous gliosis.

In both hippocampi there was total loss of neurons of the fascia dentata; nerve cell loss was severe throughout the pyramidal layer, but h2 was least affected. The hippocampal neuropil was spongy and composed of microglia, numerous plump fibre-forming astrocytes and prominent capillaries. The thalamus was also spongy, depleted of nerve cells and gliotic, particularly in the anterior and dorsomedial nuclei where there was microglial proliferation. The lateral geniculate nucleus was affected to a lesser degree. The basal ganglia showed slight nerve cell loss with astrocytosis, including occasional Alzheimer type II glia. Neuronal loss, sponginess and gliosis were also found in the substantia nigra and there was nerve cell loss in the olives. In the cerebellum circumscribed old infarcts were largely confined to the sulcal depths, but neuronal loss and gliosis were more widespread in the vermis. The dentate showed slight neuronal loss.

Liver. Pathological changes, in particular microvesicular fatty infiltration, were similar to Case 2, although the degree and pattern of bridging fibrosis fell short of cirrhosis. Focal liver cell necrosis and more septal inflammation than in Case 2 were also present.

Case 5 (NP24.79)

Clinical history. After a normal pregnancy, this boy was born by caesarian section for cephalopelvic disproportion. There were no problems until he was 12 months old when developmental progress slowed; he did not start speaking or walking, and he was noted to be hypotonic and ataxic. At the age of 3 years, he had a generalized convulsion and subsequently frequent focal convulsions. At that time his blood count, renal function, immunoglobulins, viral titres and lysosomal enzymes were normal. Liver function tests were abnormal (AST 43 IU/l (normal 6–17 IU/l)), also blood pyruvate (220 μ mol/l (normal 45–91)), blood lactate (4.7 μ mol/l (normal 0.9–1.8)), and serum alanine. EEGs showed asymmetric slow activity and polyspikes. CT scans at 3 and 3.5 years showed progressive cerebral atrophy. He was treated with sodium valproate, carbamazepine, diazepam, phenobarbital, clonazepam and chlormethiazole, singly and in combination, but with poor control of seizures. He died in liver failure aged 3.5 years.

Autopsy (Dr M. Squier). There was bronchopneumonia and the stomach contained altered blood. The liver weighed 517 g (normal 420 g) and was finely nodular, firm and yellow.

Macroscopic neuropathological findings. The left hemisphere was frozen for biochemical study. The right hemisphere weighed 473 g (fixed), the cerebellum and brainstem 117 g. The gyral pattern was normal but the convolutions were slightly flattened, and there was uncal grooving. On coronal sections the lateral and third ventricles were enlarged. The white matter appeared normal. The cortical ribbon was slightly uneven, narrow and discoloured in parts of the posterior frontal, parietal and occipital regions. The thalamus was shrunken, but the basal ganglia and hippocampi appeared normal. The brainstem and cerebellum were unremarkable.

Histological findings. CNS. Changes were widespread in the cerebral cortex but mostly very mild: the least affected areas, the frontal and temporal poles, showed only a slight astrocytosis in superficial laminae. The insular cortex and much of the occipital lobe in addition showed sponginess in layers I and II. The motor cortex and striate cortex were severely involved: the laminar architecture was completely disrupted by massive nerve cell loss and proliferation of hypertrophic fibre-forming astrocytes and lipid-laden phagocytes. Sudanophil material was plentiful throughout the cortex, even where mildly affected.

The ventrolateral parts of the thalamus were severely depleted of neurons, spongy and gliotic, but the lateral geniculate was virtually normal. There was only slight neuronal loss and gliosis in the basal ganglia, and also the nuclei pontis and the olives. The cerebellar vermis showed two old focal infarcts, and there was moderate neuronal loss in the dentate. The white matter and hippocampi were normal.

Liver. There was widespread panlobular liver cell damage and loss with extensive ballooning and microvesicular fatty infiltration of the remaining hepatocytes. Complete disorganization of the hepatic architecture had occurred. Cords of surviving fatty liver cells and duct-like structures were embedded in thick interlacing bands of dense fibrous tissue. A heavy inflammatory infiltrate and some cholestasis were present.

Case 6 (NP61.79)

Clinical history. Pregnancy was normal; delivery was assisted by forceps. There were no neonatal problems, but this boy suffered frequent upper respiratory tract infections and episodes of vomiting. On examination at the age of 3 months he was retarded, floppy and blind. Liver function tests at 6 months were abnormal (ALT 28 IU/l (normal 2–12 IU/l), AST 44 IU/l (normal 6–17 IU/l)). Because of his weakness a muscle biopsy was performed but this was normal. CSF protein was raised at 1.5 g/l. The EEG showed an excess of irregular slow components and multifocal discharges. Flash VEPs were present, but the early components were ill-defined. CT scans showed progressive cortical atrophy. At the age of 8 months he was admitted in status epilepticus and, during the last year of his life, he had frequent partial and generalized seizures which were only poorly controlled with a variety of anticonvulsants (diazepam, carbamazepine, sulthiame, sodium valproate). He died at the age of

2 years. His younger sister suffers from a similar progressive neurological disorder with hypotonia, mental retardation and seizures.

Autopsy (Dr O. G. Williams). This showed bronchopneumonia.

Macroscopic neuropathological findings. The fixed brain weighed 957 g (normal for age 1064 g), the cerebellum and brainstem 110 g. The brain was externally unremarkable. Coronal sections revealed dilated ventricles, reduction in bulk of the centrum semiovale and shrinkage of the striatum and thalamus. The cortical ribbon appeared thinned in the left insula and the occipital lobe. Cerebellar folia on the lateral and inferior surfaces of the hemispheres were shrunken, but the brainstem appeared normal.

Histological findings. CNS. Throughout the cortex there was moderate neuronal loss, gliosis including many Alzheimer II type glia, and widespread sponginess in laminae II and III. Patchy accentuation occurred in frontal, temporal and insular cortex, with more nerve cell loss and cystic degeneration extending into lamina IV. The occipital lobe was still more severely involved; in the worst foci which included the striate cortex, spongy degeneration and considerable fibrous astrocytosis involved the whole depth of the cortex. Sudanophil material was sparse and only perivascular.

The white matter of the centrum semiovale showed some myelin loss and many lipid macrophages. There was widespread severe neuronal loss in both hippocampi, including the dentate fascia, although slightly accentuated in h1 and h3; fibrous gliosis was particularly dense in the endplate. Basal ganglia and thalamus showed moderate neuronal loss, especially the rostral striatum, external segment of the pallidum and medial thalamus. The lateral geniculate nucleus was spared. Nerve cell loss was apparent in the inferior colliculi, and there was gliosis in the pontine tegmentum. In the cerebellum there were boundary zone ischaemic lesions, and the dentate showed some neuronal loss and gliosis.

Liver. No architectural changes, significant fatty change or inflammatory infiltrates were present, but there were irregular foci of acute coagulation necrosis, midzonal in distribution.

Case 7 (NP2.81)

Clinical history. Pregnancy, delivery and early psychomotor development were normal. He presented at the age of 4 months with failure to thrive, and again at 16 months with a right-sided convulsion. He was hypotonic and was found to have abnormal liver function (SGPT 124 U/l (normal 15–45 U/l)). Other investigations were normal except for repetitive discharges in a multifocal distribution in the EEG, and cortical atrophy with low density in occipital cortex and white matter on CT scan. After the first seizure at 16 months there was a fluctuating downhill course with recurrent attacks not influenced by carbamazepine, sodium valproate and paraldehyde, singly or in combination. He died at 21 months.

Autopsy (Dr G. S. Graham). There was jaundice, and the liver was slightly enlarged, tawny yellow and finely nodular.

Macroscopic neuropathological findings. The fixed brain was macroscopically normal, and weighed 843 g (normal for age 1050 g), cerebellum and brainstem 122 g. Coronal sections revealed slightly large lateral ventricles, intact white matter, and narrowing of the cortical ribbon in the occipital lobes. The lesion was symmetric and involved the striate cortex and inferior surface. The left hippocampus was shrunken. There were no other macroscopic abnormalities.

Histological findings. CNS. Throughout most of the cerebral cortex there was mild nerve cell loss, gliosis and microcystic degeneration in lamina II. The occipital lobes were severely affected, especially in the striate cortex and in medial and inferior parts where the laminar architecture was replaced by spongy degeneration, proliferation of hypertrophic astrocytes and intense fibrillary gliosis. Abundant sudanophil material was present in the cortex.

The white matter showed no significant abnormality. The right hippocampus was normal. The left showed moderate neuronal loss and gliosis in h1 and h2; the endplate showed severe neuronal depletion and the fascia dentata subtotal loss and an intense fibrous gliosis. Basal ganglia and thalamus were unaffected, except for the lateral geniculate nucleus which showed mild cell loss and gliosis. In the cerebellum there was focal Purkinje and granule cell loss, more extensive in the vermis than the

hemispheres, and severe sponginess with neuronal loss and gliosis in the dentate nuclei. Nerve cell loss in the brainstem was slight and confined to the pontine tegmentum and the tenth nerve nuclei.

Liver. Hepatocytes showed a considerable degree of microvesicular fatty degeneration. Due to extensive liver cell loss the plates formed pseudoacini or pseudoductules set in a dense network of collagen. There were well-defined micronodules.

Case 8 (NP40.83)

Clinical history. He was born by caesarian section for cephalopelvic disproportion after an uneventful pregnancy. Early development was normal but at 15 months he stopped walking, speech failed to progress, and he became hypotonic and ataxic. At 30 months he had a generalized convulsion lasting for an hour following which there were frequent seizures unrelieved by phenobarbital and phenytoin. At 31 months he suffered a prolonged generalized convulsion with intermittent right-sided predominance which lasted over 24 h. Most routine laboratory investigations were normal, but plasma transaminases were raised (AST 98 U/l (normal 15–45 U/l), ALT 70 U/l (normal 10–35 U/l)) as was the CSF protein (1.34 g/l). The EEG was very abnormal, showing bilateral continuous irregular slow activity and frequent polyspikes on the left. Flash VERs were asymmetric, better formed on the left than the right. Until his death, from pneumococcal septicaemia at 33 months, he continued to have rhythmic right-sided and generalized seizures, remaining markedly hypotonic and developing bilateral pyramidal signs. Therapy included diazepam, paraldehyde, clonazepam and dexamethasone.

Autopsy (Dr R. Phillips). There was a lung abscess, and pleural and peritoneal haemorrhages. The liver weighed 548 g (normal 400 g) and was yellow.

Macroscopic neuropathological findings. The fixed brain which was macroscopically normal weighed 1057 g (normal for age 1140 g), the hindbrain 146 g. Coronal sections revealed slightly dilated ventricles, normal white matter, basal ganglia and thalamus. The cortical ribbon was normal everywhere except the calcarine cortex, which was narrowed and discoloured brown bilaterally (fig. 7 A, B).

Histological findings. CNS. All regions of the cerebral cortex showed mild loss of neurons, with shrunken and degenerate forms, and moderate astrocytic proliferation with many Alzheimer type II cells scattered through laminae I–III. The occipital cortex in addition showed widespread sponginess in lamina II, and a greater degree of neuronal loss and astrocytosis. The striate cortex on both sides was even more severely involved: the left showed sponginess, neuronal depletion and gliosis in laminae I–IV; on the right there was subtotal nerve cell loss, the cortical structure being replaced by sheets of swollen astrocytes (fig. 8A, B), microglia and capillaries. In frozen sections occasional vessels were cuffed by lipid-laden phagocytes.

There was some pallor of myelin staining in the internal capsule, as well as irregularities of myelin structure. The hippocampi were severely affected, especially h1 and h3, and Alzheimer type II glia were numerous. Basal ganglia and thalamus showed slight gliosis and also neuron depletion in the lateral geniculate body. In the brainstem there was destruction of the seventh nerve nuclei, gliosis and microglial proliferation, with similar but milder changes in the olives. Patchy Purkinje and granule cell loss from sulcal depths in the vermis, and focal cortical loss in the cerebellar hemispheres were accompanied by spongy degeneration, increased cellularity and slight neuron depletion in the dentate nuclei.

Liver. There was massive fatty change and extensive centrilobular liver cell loss, with collapse of plates and condensation of reticulin. Additional features were moderate chronic inflammation and marked proliferation of bile ducts. Some portoportal bridging was present, but no nodular regeneration. (Fig. 9).

Case 9 (NP12.84)

Clinical history. He was born by breech delivery, but no special resuscitative measures were required. There was failure to thrive and developmental delay from birth. Seizures began at 4 months and were treated with sodium valproate and chlormethiazole. He was hypotonic and later developed pyramidal

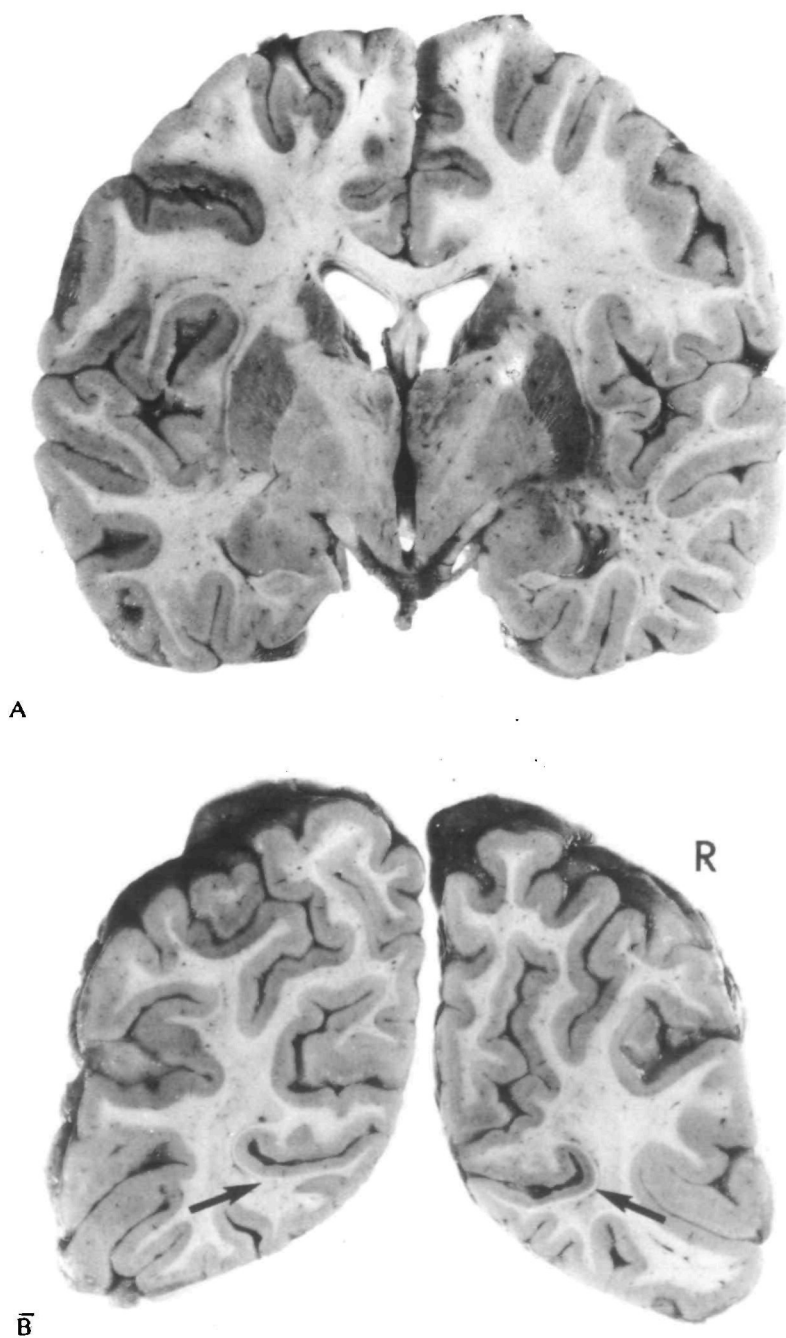


FIG. 7. *Case 8.* Coronal sections of the brain. A, at the level of the amygdaloid nuclei the cortex is macroscopically normal. B, in the occipital lobes the striate cortex (arrows) on both sides is narrow and slightly discoloured, the right being more severely affected than the left.

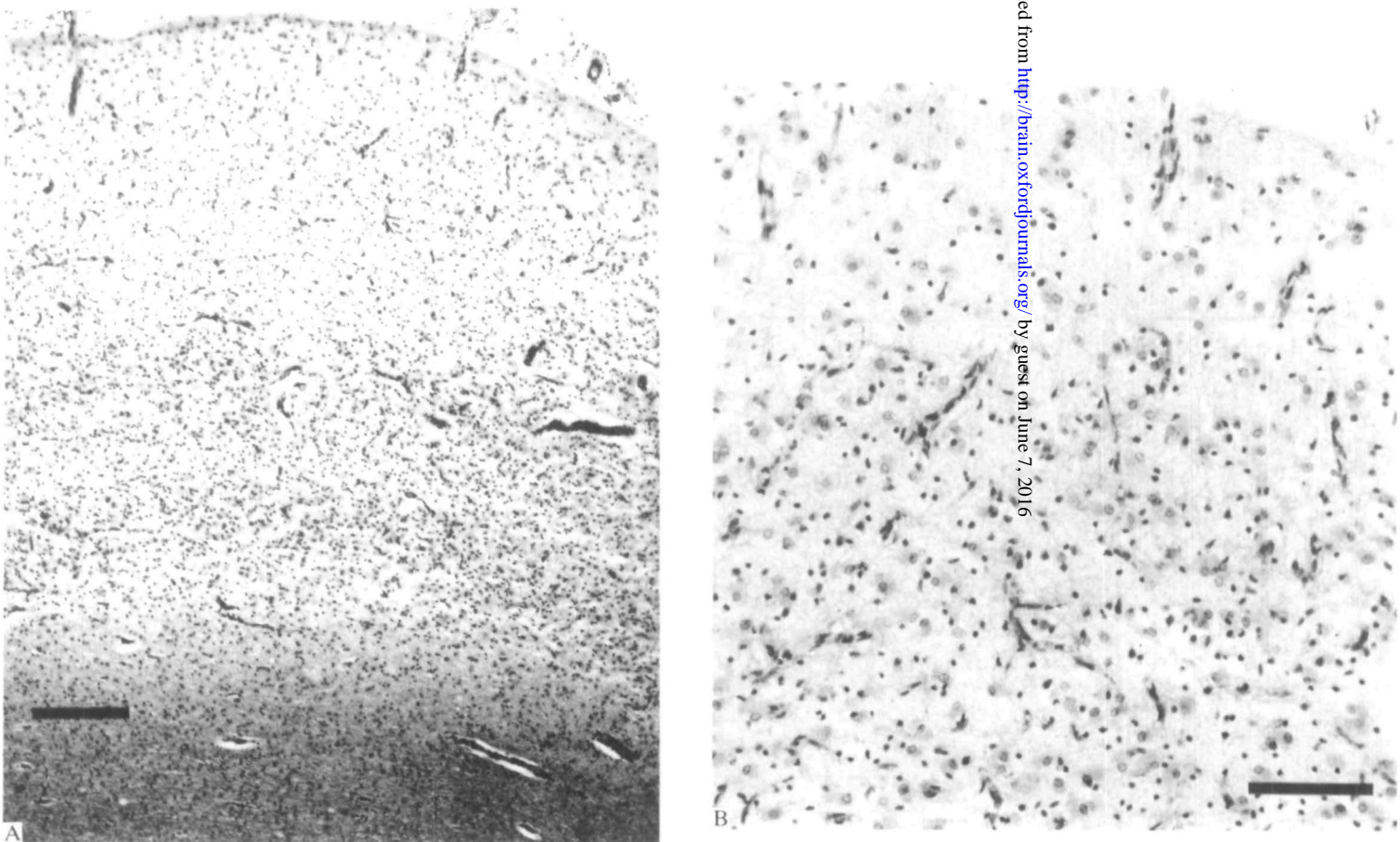


FIG. 8. *Case 8.* Histology of the striate cortex. The full thickness of the cortex is replaced by hypertrophic astrocytes, microglia and capillaries. Haematoxylin and eosin. A, bar = 0.3 mm; B, bar = 0.1 mm.

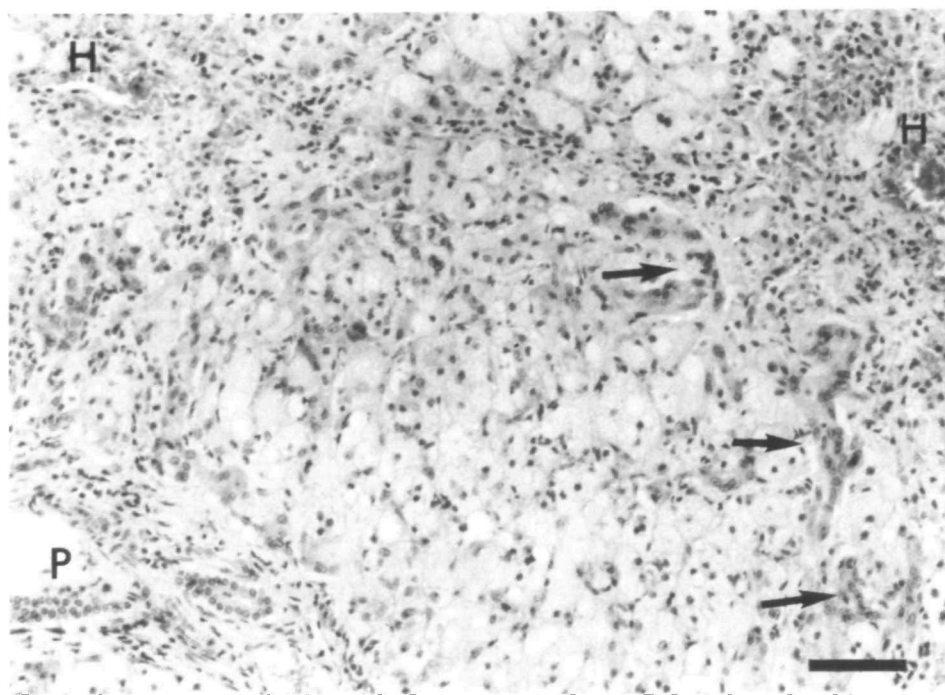


FIG. 9. Case 8. Liver, post-mortem specimen, showing centrilobular cell loss with bridging collapse towards a portal tract. Note the presence of duct-like structures (arrow) surrounding the postnecrotic areas, and the microvesicular fatty infiltration of the hepatocytes. H = hepatic venule; P = portal tract. Haematoxylin and eosin; bar = 0.1 mm.

signs. There was cortical atrophy on CT scan and abnormal slow waves and polyspikes on EEG. He died at 10 months after aspirating food when in status epilepticus. His younger brother also has a progressive neurological disease with seizures, hypotonia, developmental delay, blindness and abnormal liver function.

Autopsy (Dr W. Scarratt). The liver weighed 250 g (normal 270 g) and was pale. The brain weighed 525 g (normal for age 809 g).

Histological findings. CNS. Consistently throughout all areas of the cerebral cortex there was sponginess in lamina II and superficially in lamina III, moderate neuronal loss in the upper half of the cortical ribbon, and astrocytic proliferation in the molecular layer and lamina II with accompanying fibrillary gliosis. Patchy accentuation with more severe changes in layer III occurred in the cingulate gyrus, insular cortex and medial occipital cortex including the striate cortex.

The white matter of the cerebral hemispheres appeared well myelinated. The hippocampi showed severe nerve cell loss in the Sommer sector and the endplate, with marked fibrillary gliosis particularly in the latter (fig. 10); the h2 sector and fascia dentata were less involved. Moderate gliosis and nerve cell loss occurred in the thalamus, but to a lesser degree in the lateral geniculate than other nuclei. The basal ganglia were unaffected. The nuclei pontis were slightly depleted as was the dentate ribbon, but the cerebellar cortex was normal.

Liver. The only pathological feature was extensive panlobular microvesicular fatty change.

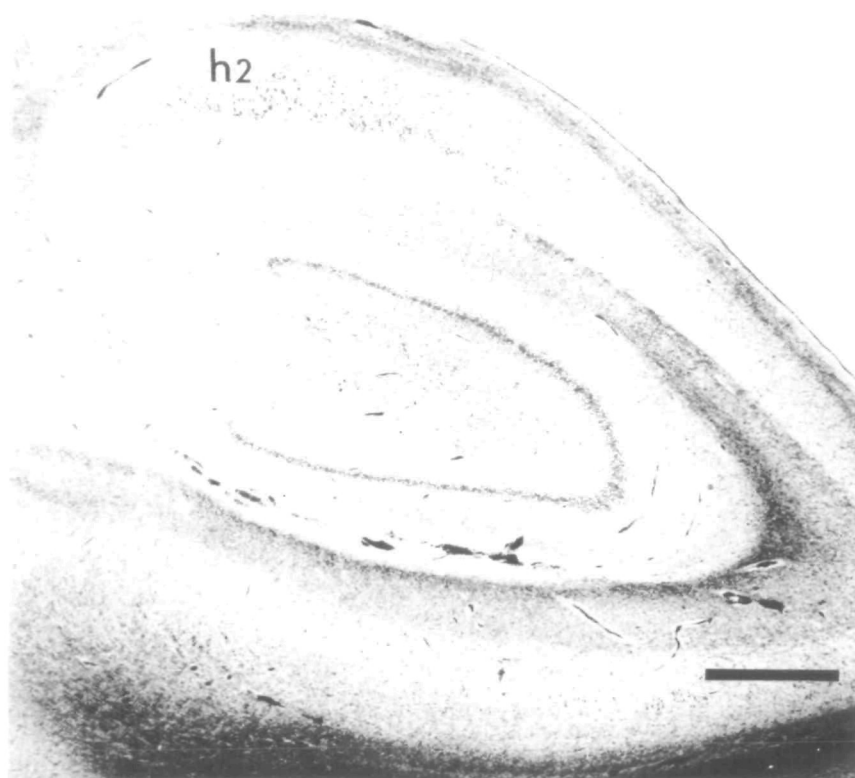


FIG. 10. *Case 9.* Section through hippocampus showing loss of pyramidal cells from the Sommer sector and endplate but preservation of h2. Luxol fast blue-cresyl violet; bar = 1 mm.

Case 10 (NP15.84)

Clinical history. Pregnancy and delivery were normal and motor development was normal until the age of 11 months when his progress slowed. There were recurrent episodes of vomiting from 16 to 24 months and at 28 months he had a prolonged left-sided convulsion, and similar seizures at 36 and 37 months. Subsequently he had recurrent short-lived seizures, mainly left-sided, and drop attacks. Anticonvulsant therapy included phenobarbital, clonazepam, carbamazepine, ethosuximide, phenytoin, diazepam, chlormethiazole, paraldehyde, sodium valproate and a ketogenic diet with no effect, and at 39 months old he required ventilation for status epilepticus. When examined at 3 years of age he was hypotonic, ataxic and his liver was enlarged, but liver function tests and CT scan were normal. The EEG showed a gross excess of high amplitude slow activity mixed with polyspikes and multifocal discharges, maximal in the anterior half of the right hemisphere. Flash VEPs were abnormal with a simple waveform and absent early components. By the age of 39 months liver function tests had become abnormal (AST 47 U/l (normal 15–45 U/l), ALT 39 U/l (normal 10–35 U/l)) and CT scan showed generalized atrophy with excessive low density in the right occipital region. He died in liver failure aged 41 months.

Autopsy (Dr J. Finch). There was jaundice and massive ascites. The liver (498 g) was shrunken and wrinkled.

Macroscopic neuropathological findings. The fixed brain weighed 1176 g. Large areas of the frontal,

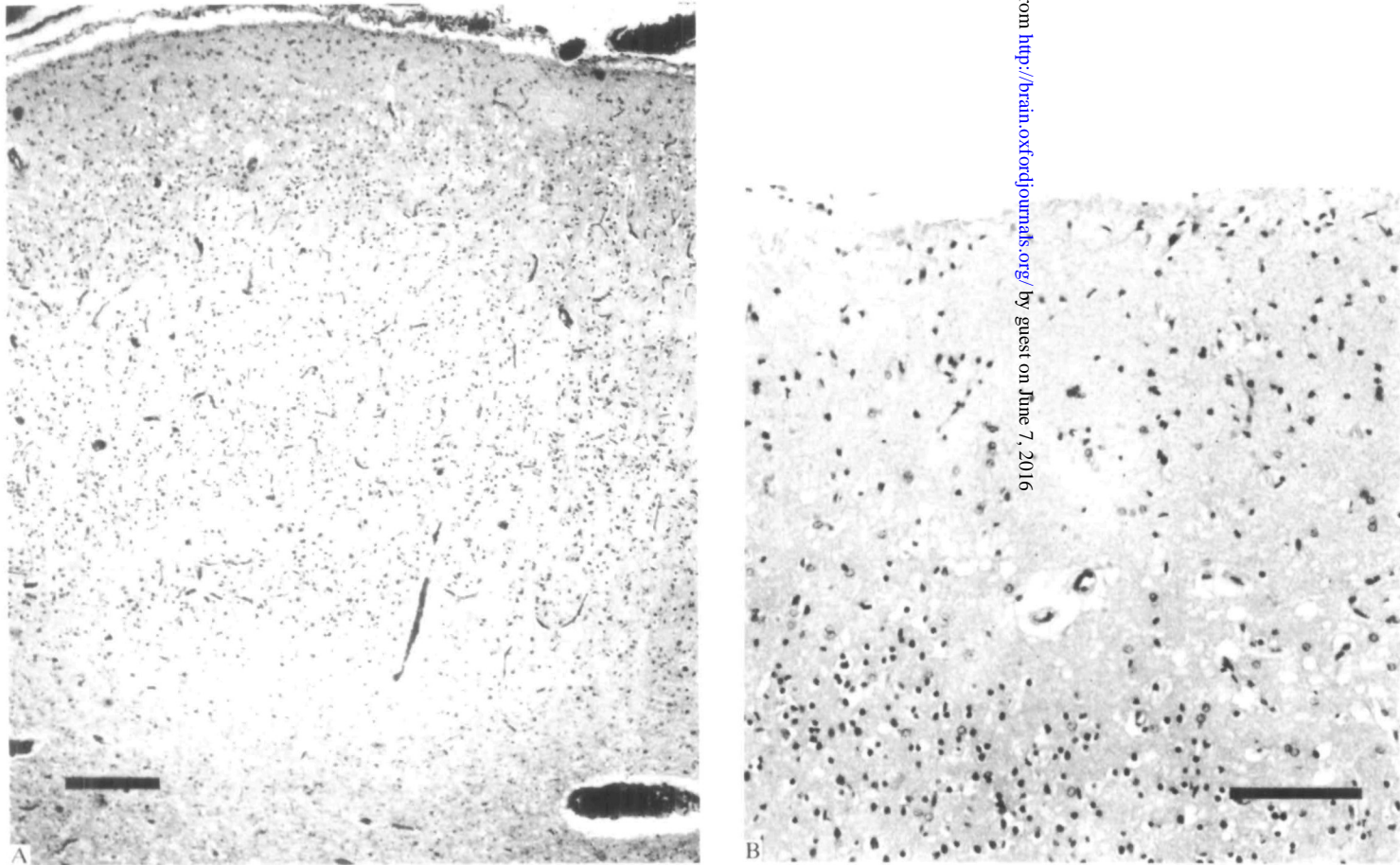


FIG. 11. *Case 10*. Histology of occipital cortex. Mild lesion with superficial gliosis and spongy change in lamina II but preservation of neurons. Haematoxylin and eosin. A, bar = 0.3 mm; B, bar = 0.1 mm.

parietal and medial occipital cortex were abnormal, with laminar dehiscence in places. There was dilatation of the temporal horns of the lateral ventricles. In the cerebellum many folia were shrunken.

Histological findings. CNS. Widespread although variable changes were present in the cerebral cortex. The mildest lesion, astrocytic proliferation in the molecular layer, was in the temporal lobe. Parietal and insular cortex showed marked sponginess in lamina II, and astrocytosis and nerve cell loss in the upper half of the cortical ribbon. Alzheimer type II glia were prominent, particularly in the insula. Similar changes were present in the left occipital lobe (fig. 11A, B) including striate cortex, but the right side showed only astrocytosis. More pronounced changes were present in the frontal cortex: sponginess in laminae II and III, considerable nerve cell loss, proliferation of plump astrocytes and gliosis. Patchy but considerable accumulations of sudanophil lipid were present in superficial cortex.

The white matter was moderately gliotic, but myelination was normal. The hippocampus showed severe nerve cell loss from h1 and h3, with moderate depletion of h2 and the dentate fascia. Plump astrocytes abounded in the Sommer sector and an intense fibrous gliosis involved the endplate and dentate fascia. There was astrocytic proliferation throughout the basal ganglia with Alzheimer type II glia particularly numerous in the caudate and amygdala, and more obvious nerve cell loss from the claustrum. The thalamus was more severely involved, with widespread spongy degeneration and considerable neuronal loss. Microglia and neuronophagia were noted in places, as well as astrocytosis. The lateral geniculate nucleus was normal. Large areas of the cerebellar cortex showed total loss of Purkinje cells and granule cells with proliferation of Bergmann glia and isomorphous gliosis. The dentate nucleus was slightly depleted of neurons and gliotic. Moderate nerve cell loss, gliosis and microglial proliferation occurred in the olives.

Liver. As well as massive fatty change, marked cholestasis and liver cell depletion, there was extensive bridging fibrosis with micronodular cirrhotic transformation.

SUMMARY OF CLINICAL FINDINGS

Clinical data of the 10 cases presented in this paper are summarized in Table 1. There were no significant perinatal problems. Presentation was between early infancy and 15 months with developmental delay and failure to thrive. Recurrent vomiting and hypotonia were also common. After a further variable period, usually several months, there was an explosive onset of epilepsy, often recurrent status epilepticus, intractable despite combination anticonvulsant therapy. Additional neurological findings included ataxia, pyramidal and extrapyramidal signs, deafness and blindness. Although the last was only detected in 3 cases, VERs were abnormal in 5 cases out of 7 investigated. The EEG showed unusual and characteristic changes (Boyd *et al.*, 1986), and CT scans indicated rapidly progressive atrophy particularly in occipital areas. Abnormal liver function was detected in 5 cases before commencement of anticonvulsant therapy. After the onset of epilepsy progression of the illness was usually rapid and relentless.

SUMMARY OF PATHOLOGICAL FINDINGS

Brain

Macroscopic. These comprised irregularity, narrowing, granularity and dark brown discolouration of the cortical ribbon, restricted to both calcarine fissures in Case 8, largely confined to the occipital lobes and particularly striate cortex in Cases

TABLE 1. SUMMARY OF CLINICAL FEATURES

Case	Sex	Affected sibling	Age* and manner of presentation	Other features	Age at onset of epilepsy*	Abnormal liver function tests detected*	Age at death*	Valproate
1	M	M (†9½yr)	12, mental retardation	VPA	36	80	89	+
2	M		3, failure to thrive	VHB	15	4	21	—
3	F	F	1, retarded, seizures	VH	1		12	+
4	F		< 12, mental retardation, failure to thrive	VHEA	17	16	19	+
5	M		12, mental retardation	A	37	37	41	+
6	M	F	2, mental retardation	VHBDE	8	6	24	+
7	M		4, failure to thrive	VHBA	16	16	21	+
8	M		15, mental retardation	VHPA	30	31	33	—
9	M	M	Retarded from infancy	HP	4		10	—
10	M		11, mental retardation	VHA	28	39	41	+

* In months. V = vomiting; H = hypotonia; P = pyramidal signs; E = extrapyramidal signs; B = blindness; D = deafness; A = ataxia.

6 and 7, more extensively involving frontal, parietal and occipital lobes in Cases 2, 5 and 10, and widespread throughout the cortical ribbon with some accentuation in the occipital lobes in Cases 3 and 4. Shrinkage of the thalamus, caudate nuclei, hippocampi and cerebellum were also features.

Microscopic. There was extensive neocortical pathology with wide variations between and within cortical regions, unrelated to vascular territories or gyral topography. The mildest change was astrocytic proliferation in the molecular layer, the next spongy change in lamina II, and then more obvious neuronal loss and astrocytosis in lamina III. Severely affected areas showed marked nerve cell loss, astrocytic hyperplasia and hypertrophy, and sometimes a 'collapsed' critical ribbon, the remnant comprising large astrocytes, a dense glial fibrillary meshwork and numerous capillaries. Topographical analysis (Table 2) revealed a pronounced tendency for the striate cortex to be the most severely affected cortical region. Case 9 differed slightly in being only mildly affected. Case 10 was the exception: frontal rather than striate cortex was worst affected. The white matter was usually only mildly affected. Subcortical lesions (Table 3) most consistently involved the hippocampi, thalamus and cerebellum.

Liver

The pathology can be summarized in three groups.

Group 1. Cases 1, 5, 7, 8 and 10 showed widespread severe microvesicular fatty change, on-going liver cell necrosis, and diffuse bile duct proliferation, together with heavy liver cell loss, collapse of plates and bridging fibrosis. Case 5 showed end-stage

TABLE 2. TOPOGRAPHICAL ANALYSIS OF CORTICAL DESTRUCTION

Case	Frontal	Parietal	Insula	Temporal	Occipital	Striate
1	+	+	+	+	R +++ L +++++	+++++
2	++++	++++	++	++	++++	++++
3	++++ (Orbital +++)	++++	++++	++++	++++	++++
4	+++	+++	+++	+++	+++	+++++
5	+	+	++	+	++	+++++
	(Motor +++++)					
6	+++	++	+++	+++	++++	++++
7	++	++	++	++	+++++	+++++
8	+	+	+	+	++	R +++++ L +++++
9	-	++	++	++	+++	+++
10	++++	++	+	+	+++	+++

+ = superficial astrocytosis; ++ = spongiosis layer II; +++ = spongiosis including layer III, obvious neuron loss; ++++ = severe neuron loss including layers IV, V; +++++ = subtotal neuron loss; - = not available.

TABLE 3. SUMMARY OF SUBCORTICAL PATHOLOGY

Case	Hippocampus	Thalamus	LGN*	Basal ganglia	Cerebellum	Brainstem
1	+	+	+	+	+	+
2	+	+	+	+	+	+
3	+	+	+	+	+	+
4	+	+	+	+	+	+
5	0	+	0	+	+	+
6	+	+	0	+	+	+
7	+	0	+	0	+	+
8	+	+	+	+	+	+
9	+	+	+	0	+	+
10	+	+	0	+	+	+

* Lateral geniculate nucleus. + = affected. 0 = normal.

destruction and fibrosis, and Cases 7 and 10 nodular regeneration and cirrhosis; Cases 1 and 8 were intermediate, neither strictly cirrhotic nor completely disorganized.

Group 2. Cases 2 and 4 showed less acute damage than Group 1 but more scarring and repair with fatty change and focal necrosis. Cirrhosis was predominant in Case 2, perilobular scarring and periportal bridging in Case 4.

Others. In Case 9 there was panlobular fatty degeneration and in Case 6, midzonal necrosis.

DISCUSSION

Our present clinical and neuropathological findings are indicative of a distinct clinicopathological entity. The familial incidence (Blackwood *et al.*, 1963; Wefring

and Lamvik, 1967; Jellinger and Seitelberger, 1970; Huttenlocher *et al.*, 1976) suggests autosomal recessive inheritance. Important diagnostic indicators are early visual impairment highlighted by VER abnormalities, characteristic waveforms on EEG, cortical atrophy with occipital predominance on CT scan, and hepatic dysfunction detectable biochemically.

The neuropathological findings are in keeping with previous descriptions (Blackwood *et al.*, 1963; Jellinger and Seitelberger, 1970; Huttenlocher *et al.*, 1976) in that all regions of the cerebral cortex are usually involved, not necessarily symmetrically, and there is variable severity between and within cortical areas. Progression of the lesions has previously been demonstrated (Blackwood *et al.*, 1963) by comparing consecutive biopsies and autopsies. And in our material there is a graded spectrum of pathological change in the cortex from superficial astrocytosis and spongy change in the mildest lesions, to gradual loss of neurons and gliosis spreading through the depth of the cortex, and to complete disorganization in the severest lesions. One observation which has not been described previously is the bias towards the visual cortex, which in our cases is generally the worst affected area (Table 2). This feature is most striking in Cases 1, 5, 7 and 8, where the abnormal striate cortex was easily picked out on naked eye examination; more widespread mild cortical damage was discernible only microscopically. The cause for the severe involvement of the visual cortex is obscure, one possibility being an increased metabolic requirement in view of the higher number of neurons in primate visual cortex (Rockel *et al.*, 1980). Its importance lies in its diagnostic usefulness, for it is the structural correlate of the notable abnormalities of visual function. Arguments favouring the view that PNDC is a nosological entity have failed in the past for lack of specific pathological indicators. There are no characteristic histological changes in neurons, and large numbers of lipid-laden macrophages mostly confined to the cortex represent nonspecific breakdown products (Blackwood *et al.*, 1963). The pathological process itself is not specific, but we would suggest that the topography of the cortical lesions (Table 2) is characteristic.

Astrocytic overgrowth is an important feature of PNDC, but it remains unclear whether it is a secondary reaction or an intrinsic part of the pathological process, a 'glioneuronal dystrophy' similar to Creutzfeldt-Jacob disease (Klein and Dichgans, 1969; Jellinger and Seitelberger, 1970). Crompton (1968) and Janota (1974) have noted morphological similarities between PNDC and Creutzfeldt-Jacob disease. Ultrastructural studies are as yet unhelpful, for while vacuolated astrocytic and neuronal processes are well known in Creutzfeldt-Jacob disease, electron microscopy of brain biopsies in a few cases of PNDC have disclosed only swelling of postsynaptic dendrites (Kolkmann, 1969), or giant neuronal mitochondria (Suzuki and Rapin, 1969; Sandbank and Lerman, 1972), a nonspecific finding. Successful transmission experiments have so far not been reported.

In severely affected cortex thin-walled capillaries are very numerous. Capillary proliferation may occur as a response to any cortical necrosis, but the increased density of capillaries is more likely to result from collapse of tissue (Blackwood

et al., 1963). These histological appearances differ from Leigh's disease (Egger *et al.*, 1984) in topography, nerve cell destruction and lack of endothelial hypertrophy.

In children with seizure disorders as severe and longstanding as in PNDC, the possible contribution of epileptic-hypoxic damage to the cerebral cortical destruction should be considered. Hypoxia complicating birth, and particularly following severe and serial convulsions has been canvassed (Wolf and Cowen, 1954; Greenhouse and Neuburger, 1964) as the prime pathogenetic mechanism for the diffuse cerebral cortical damage, although one early case (Christensen and Krabbe, 1949) had no generalized seizures. This view of PNDC as resulting from repetitive seizures is based on the apparent histological similarity between PNDC and postepileptic encephalopathy. In our cases of PNDC there is no clinical or pathological evidence for birth injury. After a normal start neurological deficit clearly preceded the onset of seizures. Also there is no correlation between the duration of the convulsive disorder and the degree of histological abnormality: the more mildly affected brains were those from patients who presented later and survived longer. The severity of the pathological lesions reflects the velocity of the whole clinical process rather than the epileptic component. From a histopathological standpoint too, the cerebral cortical degeneration differs significantly from descriptions of postictal damage in children surviving for short periods following prolonged status epilepticus (Scholz, 1951; Norman 1964; Ounsted *et al.*, 1966). In postictal damage there is widespread ischaemic cell change of cortical neurons, the process showing laminar intensification. In our cases there is no ischaemic cell change, and the lesion has a different pattern, spreading gradually deeper from superficial laminae to involve the whole cortical ribbon. Nor is there an accentuation of lesions in the depths of sulci or in vascular boundary zones, as occurs in hypoxic lesions. An early change in PNDC is sponginess of the superficial laminae, whereas spongy change occurs late in hypoxic lesions. A further difference between PNDC and postepileptic lesions concerns the calcarine cortex. Scholz (1951) and Norman (1964) emphasized that in postepileptic encephalopathy where the occipital lobe is diffusely involved, the calcarine cortex is often remarkably spared. In our cases the calcarine cortex is certainly never spared; as a rule it is the worst affected area. PNDC thus appears to be quite distinct, both clinically and pathologically, from complications of birth injury or postepileptic encephalopathy.

In subcortical structures it is more difficult to distinguish primary disease processes from possible effects of epilepsy, hypoxia or secondary retrograde degeneration. Cerebellar cortical pathology most probably results from hypoxia due to epilepsy. Hippocampal lesions in general also follow the expected pattern for postepileptic damage, Ammon's horn sclerosis or endplate sclerosis (Margerison and Corsellis, 1966). Nonetheless, the severity of the destruction and spongy degeneration in Cases 3 and 4 argue for some contribution from the primary degenerative process, as do the spongy lesions in the amygdala, substantia nigra and thalamus in Cases 3, 4, 5, 8 and 10. The lateral geniculate nucleus is of particular interest with regard to retrograde thalamic degeneration in view of the preferential

involvement of the striate cortex. In Cases 1, 7 and 8 where the clinical course was more protracted, neuronal loss, shrinkage and gliosis in the lateral geniculate were out of proportion to the rest of the thalamus; but in other cases the lateral geniculate was affected to a similar or lesser degree than other thalamic nuclei.

Liver disease is an integral part of the pathology in PNDC. Five of our cases (Group 1) showed similar rather unusual hepatic involvement with severe fatty degeneration of hepatocytes, accompanied by extensive cell loss, profuse bile duct proliferation, heavy fibrosis, and nodular regeneration. Two further cases (Group 2) showed fatty change and focal necrosis, but rather more scarring and repair and less acute liver damage. Similar lesions were found on reexamination of two siblings from the series of Blackwood *et al.* (1963)—one reminiscent of our Group 1, and the other more like Group 2—making it highly likely that they are different stages of the same process. Our Case 9 may represent an earlier or milder version of the process; this is consistent with the particularly mild cerebral lesions in that patient. Hepatic lesions have also been noted by Huttenlocher *et al.* (1976), Wefring and Lamvik (1967), Cameron *et al.* (1968) and Jellinger and Seitelberger (1970).

In view of the multiple drug therapy needed for the intractable epilepsy of these patients, one possibility to be considered is a toxic reaction producing liver failure. Although liver disease in previous cases is reported as manifesting late in the clinical course (if at all), in our patients there was biochemical evidence of significant liver involvement before or at the onset of seizures, and therefore before the institution of anticonvulsant therapy. Sodium valproate has been reported to produce toxic liver damage (Suchy *et al.*, 1979). Seven of our patients were given this drug (Cases 1, 3, 4, 5, 6, 7, 10); similar hepatic lesions occurred whether or not it was used, while the previously reported cases of PNDC with liver lesions were not exposed to valproate. Thus it seems highly unlikely that valproate had an initiating role in the liver disease, but the possibility that it may exacerbate established hepatic damage cannot be excluded. The only patient (Case 6) to show acute midzonal necrosis, which has an association with drug toxicity, had not received sodium valproate. This particular hepatic lesion remains unexplained, particularly as significant abnormalities of liver function were detected at least eighteen months before death.

Some Alzheimer type II astrocytes were present in 6 cases and probably represent an acute response to terminal liver failure and attendant hyperammonaemia (Victor *et al.*, 1965; Cavanagh and Kyu, 1971). Gross hepatic dysfunction occurred too late to be a major causative factor in the cerebral disorder. There are also considerable morphological differences between PNDC and hepatic encephalopathy in which severe striatal damage occurs and cortical degeneration has a laminar distribution with microcavitation at the corticomedullary junction. Wilson's disease differs even more from PNDC; pathology is found mainly in the basal ganglia, with milder changes in the cortex (Smith, 1976), and the clinical course is quite dissimilar. Reye's syndrome also enters the differential diagnosis but the clinical course is more acute, the cerebral pathology is basically different, and there is no chronic hepatic degeneration (Reye *et al.*, 1963). The present evidence, therefore, strongly supports

the contention of Wefring and Lamvik (1967) and Huttenlocher *et al.* (1976) that this disorder is a combined degeneration of the liver and brain, probably due to an inherited metabolic defect, the nature of which is unknown.

Nomenclature and nosology in PNDC have been a problem since the time of the original report by Alpers (1931) which, in many respects, may not be typical of later cases. The rather nonspecific histological findings have meant that this designation, like birth injury and postepileptic encephalopathy, has become a repository for obscure grey matter degenerations in infants (Friede, 1975). Jellinger and Seitelberger (1970) tried to distinguish an idiopathic form from symptomatic and epileptic cases with the aim of isolating a common aetiological group. But while their own Case 1 and the cases of Blackwood *et al.* (1963) (with liver lesions) were placed in the idiopathic group, the cases of Wefring and Lamvik (1967) were excluded *because* of liver disease. The present and previously cited cases (Blackwood *et al.*, 1963; Wefring and Lamvik, 1967; Cameron *et al.*, 1968; Jellinger and Seitelberger, 1970; Huttenlocher *et al.*, 1976) now amount to 24 patients in 16 kindreds with PNDC and hepatic degeneration, and other past cases may also belong to this category. With a probable autosomal recessive inheritance, PNDC and hepatic degeneration has now emerged as a distinct nosological entity with important implications for both clinical diagnosis and genetic counselling.

ACKNOWLEDGEMENTS

We wish to thank the pathologists and neuropathologists who made material available to us, and particularly Professor W. Blackwood and Dr P. Buxton for allowing us to examine sections from their published cases. We are indebted to Dr James Leonard and Dr John Wilson for permission to publish clinical details of their patients. We gratefully acknowledge the skilled assistance of Mrs P. Kelman-McConnachie for the histological preparations, and Mr J. Mills for the macroscopic photography.

REFERENCES

- ALPERS B J (1931) Diffuse progressive degeneration of the gray matter of the cerebrum. *Archives of Neurology and Psychiatry, Chicago*, **25**, 469–505.
- BLACKWOOD W, BUXTON P H, CUMINGS J N, ROBERTSON D J, TUCKER S M (1963) Diffuse cerebral degeneration in infancy (Alpers' disease). *Archives of Disease in Childhood*, **38**, 193–204.
- BOYD S G, HARDEN A, EGGER J, PAMPIGLIONE G (1986) Progressive neuronal degeneration of childhood ('Alpers disease') characteristic neurophysiological findings. *Neuropediatrics*. In press.
- CAMERON A H, JONES E L, SMITH W T, WOOD B S B (1968) Combined hepatic and cerebral degeneration in infancy. *Journal of Pathology and Bacteriology*, **96**, 227–230.
- CAVANAGH J B, KYU M H (1971) Type II Alzheimer change experimentally produced in astrocytes in the rat. *Journal of the Neurological Sciences*, **12**, 63–75.
- CHRISTENSEN E, KRABBE K H (1949) Poliodystrophia cerebri progressiva (infantilis): report of a case. *Archives of Neurology and Psychiatry, Chicago*, **61**, 28–43.
- CROMPTON M R (1968) Alpers' disease—variant of Creutzfeldt-Jakob disease and subacute spongiform encephalopathy? *Acta Neuropathologica, Berlin*, **10**, 99–104.
- EGGER J, PINCOTT J R, WILSON J, ERDOHAZI M (1984) Cortical subacute necrotizing encephalomyelopathy: a study of two patients with mitochondrial dysfunction. *Neuropediatrics*, **15**, 150–158.
- FORD F R, LIVINGSTON S, PRYLES C V (1951) Familial degeneration of the cerebral gray matter in

- childhood, with convulsions, myoclonus, spasticity, cerebellar ataxia, choreoathetosis, dementia, and death in status epilepticus; differentiation of infantile and juvenile types. *Journal of Pediatrics*, **39**, 33–43.
- FRIEDE R L (1975) *Developmental Neuropathology*. New York: Springer.
- GREENHOUSE A H, NEUBUERGER K T (1964) The syndrome of progressive cerebral poliodystrophy. *Archives of Neurology, Chicago*, **10**, 47–57.
- HUTTENLOCHER P R, SOLITARE G B, ADAMS G (1976) Infantile diffuse cerebral degeneration with hepatic cirrhosis. *Archives of Neurology, Chicago*, **33**, 186–192.
- JANOTA I (1974) Spongy degeneration of grey matter in three children: neuropathological report. *Archives of Disease in Childhood*, **49**, 571–575.
- JELLINGER K, SEITELBERGER F (1970) Spongy glio-neuronal dystrophy in infancy and childhood. *Acta Neuropathologica, Berlin*, **16**, 125–140.
- KLEIN H, DICHGANS J (1969) Familiäre juvenile glio-neurale Dystrophie: akut beginnende progressive Encephalopathie mit rechtsseitigen occipito-parietalen Herdsymptomen und Status epilepticus. *Archiv für Psychiatrie und Nervenkrankheiten*, **212**, 400–422.
- KOLKMANN F W (1969) *Die spongiosen Dystrophien des ZNS im Kindes- und Erwachsenenalter*. Habilitation-Schrift, Heidelberg.
- MARGERISON J H, CORSELLIS J A N (1966) Epilepsy and the temporal lobes: a clinical, electroencephalographic and neuropathological study of the brain in epilepsy, with particular reference to the temporal lobes. *Brain*, **89**, 499–530.
- NORMAN R M (1964) The neuropathology of status epilepticus. *Medicine, Science and the Law*, **4**, 46–51.
- OUNSTED C, LINDSAY J, NORMAN R (1966) Biological factors in temporal lobe epilepsy. *Clinics in Developmental Medicine* **22**, 1–135.
- REYE R D K, MORGAN G, BARAL J (1963) Encephalopathy and fatty degeneration of the viscera: a disease entity in childhood. *Lancet*, **ii**, 749–752.
- ROCKEL A J, HIORNS R W, POWELL T P S (1980) The basic uniformity in structure of the neocortex. *Brain*, **103**, 221–244.
- SANDBANK U, LERMAN P (1972) Progressive cerebral poliodystrophy—Alpers' disease: disorganized giant neuronal mitochondria on electron microscopy. *Journal of Neurology, Neurosurgery and Psychiatry*, **35**, 749–755.
- SCHOLZ W (1951) *Die Krampfschädigungen des Gehirns*. Berlin: Springer.
- SMITH W T (1976) Intoxications, poisons and related metabolic disorders. In: *Greenfield's Neuropathology*. Third edition. Edited by W. Blackwood and J. A. N. Corsellis. London: Edward Arnold, pp. 148–193.
- SUCHY F J, BALISTRERI W F, BUCHINO J J, SONDHEIMER J M, BATES S R, KEARNS G L, STULL J D, BOVE K E (1979) Acute hepatic failure associated with the use of sodium valproate: report of two fatal cases. *New England Journal of Medicine*, **300**, 962–966.
- SUZUKI K, RAPIN I (1969) Giant neuronal mitochondria in an infant with microcephaly and seizure disorder. *Archives of Neurology, Chicago*, **20**, 62–72.
- VICTOR M, ADAMS R D, COLE M (1965) The acquired (non-Wilsonian) type of chronic hepatocerebral degeneration. *Medicine, Baltimore*, **44**, 345–396.
- WEFRING K W, LAMVIK J O (1967) Familial progressive poliodystrophy with cirrhosis of the liver. *Acta Paediatrica Scandinavica*, **56**, 295–300.
- WOLF A, COWEN D (1954) The cerebral atrophies and encephalomalacias of infancy and childhood. *Research Publications: Association for Research in Nervous and Mental Disease*, **34**, 199–330.

(Received January 10, 1985. Revised May 31, 1985. Accepted June 14, 1985)