

# INFARCTS OF BOTH INFERIOR PARIETAL LOBULES WITH IMPAIRMENT OF VISUALLY GUIDED EYE MOVEMENTS, PERIPHERAL VISUAL INATTENTION AND OPTIC ATAXIA

by CH. PIERROT-DESEILLIGNY, F. GRAY and P. BRUNET

(From the Clinique de Sémiologie Neurologique, Unité de Recherches INSERM U. 289 and Laboratoire de Neuropathologie Charles Foix, Hôpital de la Salpêtrière, Paris)

## SUMMARY

Clinicopathological correlations are reported in a case with bilateral isolated infarcts in the posterior part of the parietal lobes, due to nonbacterial thrombotic endocarditis accompanying pancreatic adenocarcinoma. The initial left-sided infarct induced right visual neglect, impairment of right-beating optokinetic nystagmus (OKN), optic ataxia, Gerstmann's syndrome and apraxia. After the right-sided infarct, which occurred six weeks later, bilateral visuo-oculomotor disturbances were observed, including peripheral visual inattention, disorder of visually guided saccades, severe impairment of foveal smooth pursuit and OKN slow phase. The lesion on the left involved the upper part of the angular gyrus and a part of the adjacent superior parietal lobule (SPL). That on the right involved the supramarginal gyrus and extended posteriorly into the superoanterior extremity of the angular gyrus, into both margins of the adjacent intraparietal sulcus and into a small part of the SPL. As the oculomotor deficits and the peripheral visual inattention were bilateral after the second infarct, they probably resulted from the lesion of homologous areas in both cerebral hemispheres. The zone damaged in common included a small part of the SPL, the superoanterior extremity of the angular gyrus, and the adjacent intraparietal sulcus and a small portion of the subcortical white matter. This restricted cerebral zone could therefore, in man, be implicated both in the control of all visually guided eye movements and in visual attention. It is further suggested that two corticofugal pathways are implicated in visually guided saccades, the first arising from the frontal eye fields and projecting directly onto the premotor structures in the brainstem, the second arising from the posterior parietal cortex (probably mainly the intraparietal sulcus adjacent to the angular gyrus) and including a relay in the superior colliculus before reaching the premotor structures. Lastly, the findings support the hypothesis that optic ataxia results from interruption of direct and/or crossed occipitofrontal pathways coursing in the deep white matter of the parietal lobe.

## INTRODUCTION

The dorsal part of the inferior parietal lobule (IPL) of the monkey (Brodmann's area 7) is involved both in visual attention and in the different visually guided eye movements (Lynch *et al.*, 1977). In man, it has long been suggested that the

Correspondence to: Dr Ch. Pierrot-Deseilligny, Hôpital de la Salpêtrière, 47 Bd de l'Hôpital, 75651 Paris Cedex 13, France.

© Oxford University Press 1986

posterior part of the parietal lobe is similarly involved (Mesulam, 1981; Sharpe, 1982), but so far clinicopathological cases have been rare and the lesions have not been limited to the IPL (the angular and supramarginal gyri, namely Brodmann's areas 39 and 40, respectively), in general largely damaging the parieto-occipital region. The main interest of the clinicopathological case reported here is to show that severe deficits in visually guided eye movements (smooth pursuit and saccades) and peripheral visual inattention can be observed after bilateral infarcts involving only a restricted part of the IPL on each side. As these two infarcts occurred with an interval of six weeks, the clinical features of the initial left-sided damage could be studied first. The case also included other neurological disturbances, such as optic ataxia which, together with the eye movement disorders and the visual inattention, formed a syndrome resembling that described by Balint (1909).

### CASE REPORT

A 64-year-old right-handed woman, having stayed at school until 18 years of age but never having been employed, widowed, with no noteworthy previous medical history, was admitted to hospital after an initial convulsive seizure. On examination, she was alert and cooperative. Her gait was normal and she had no motor deficit. The plantar responses were flexor and the tendon reflexes normal. Postural sense in the right hallux was slightly impaired but other sensory modalities were normal. There was no astereognosis, but there was tactile inattention over the whole of the right side of the body.

There was no hemianopia (tested by confrontation at the bedside using a small red sphere) but right visual extinction was noted. Moreover, the patient showed right visual neglect since, on exploring pictures visually, she looked only at their left halves and noticed none of the objects located on the right. Saccades to command, visually guided saccades (to a small visual target such as a pencil), foveal pursuit (stimulated by a smoothly moved pencil) and oculocephalic movement performed in the lateral and vertical planes appeared clinically normal. It is possible, in the absence of recordings, that a slight saccadic component of horizontal foveal pursuit was overlooked. Horizontal optokinetic nystagmus (OKN), elicited by a narrow band of pictures passed in front of the patient (namely stimulating only the foveal smooth pursuit system) was asymmetric, the amplitude and frequency of nystagmus being clearly lower when the stimulus was moved leftwards. When eye-hand coordination was examined (the patient was instructed to fixate straight ahead while attempting to point at objects located first peripherally and then centrally in her visual field), a striking optic ataxia was noted: with the right hand, it was seen in both peripheral visual hemifields as well as when the object was fixated; with the left hand, it was in the right peripheral visual hemifield only.

There was a complete Gerstmann's syndrome with (1) severe finger agnosia, the patient being able to name and to point to her index finger only (or that of the examiner), but having no difficulty in pointing to and naming the other parts of her body; (2) obvious left-right disorientation (with almost 50 per cent error); (3) marked oral and written dyscalculia, single figure additions being occasionally right but always wrong with double figures; and (4) clear agraphia with almost completely unintelligible spontaneous writing, only slightly improved when copying, whichever hand was used. In contrast, reading was normal (for words as well as for letters), as was spoken language. Spontaneous speech was fluent, without paraphasic errors or circumlocutions; she named objects, and repeated and comprehended oral language without difficulty. In spontaneous drawing, a cube was reduced to a simple triangle but included two faces when copied. The patient could not perform common gestures (e.g., a military salute, the sign of the cross, waving goodbye) either spontaneously or by imitation, regardless of which upper limb was used, although she could recognize and name them

perfectly when they were performed by the examiner. She was unable to light a candle and could only manipulate everyday objects clumsily (e.g., fork, knife, pen). Memory and judgement were normal. Further neurological examination revealed no other anomalies.

The patient had lost 5 kg in the previous three months and was anorexic. She had an irregular hepatomegaly and peritonoscopy confirmed multiple metastases in the liver. General examination revealed no further abnormalities and the site of origin of the carcinoma was not sought. Left carotid arteriography showed occlusion of the posterior parietal branch of the left middle cerebral artery near its origin, but no other abnormalities.

Six weeks after admission, when her apraxia had slightly improved, sudden neurological deterioration was noted. The patient remained alert and cooperative during all the clinical examinations performed throughout the day. Motility in the limbs was normal on command but motor neglect in the left upper limb was suspected. Plantar and tendon reflexes were normal. On sensory examination, left-sided astereognosis was suspected but could not be confirmed because of a dystonic attitude of the left hand which prevented the manipulation of objects. The fingers were almost always held in extension, particularly during motor activity of either of the upper limbs. There was no other sensory loss. When testing stereognosis the patient sat up in bed with her gaze fixated in front of her. She was allowed to keep her eyes open not only because she apparently did not see objects placed in either hand, but also because she showed no inclination to move her gaze towards them. She did not blink when menaced in her peripheral visual field. However, there was no hemianopia since, on both sides, she could see the fingers of the examiner moving, although this perception was apparently obtained with much difficulty. She seemed to see only a few dashes on a sheet of paper presented to her containing numerous scattered dashes. Saccades to command were normal in all directions, but the patient could not perform a correct saccade from one visual target to another (the results were the same for two pencils or the faces of two examiners): she fixated the first target for an abnormally long time (at times a few seconds) and, when she succeeded in releasing her gaze, it wandered in search of the second target regardless of side. Starting from the first target, the direction of saccade was often but not always wrong. When correct, however, the amplitude of saccades was inaccurate (hypometric or hypermetric). Reading was now disturbed, essentially because of these saccadic disorders: the patient could leave a line and return leftwards but not catch the following line and, within a line, she missed some words. Foveal pursuit (still stimulated by a smoothly moved pencil) was absent leftwards. Rightwards, a movement was observed only when the stimulus was moving very slowly. It is still possible that a saccadic component of the residual rightward foveal pursuit was overlooked here. OKN was abolished in both lateral directions, the eyes remaining stationary at the midline. During this stimulation the patient saw and could name the different pictures passed just in front of her eyes. Vertical foveal pursuit and vertical OKN were not tested. Lateral and vertical oculocephalic movements were normal. Optic ataxia still existed for the right hand, but could not be assessed for the left, because of its dystonic attitude. Gerstmann's syndrome and apraxia persisted. Spoken language, memory and judgement were still normal. There were no other noteworthy neurological anomalies.

On the following day the patient developed bronchopneumonia with a pyrexia of 41° C, preventing oculomotor recordings which had been planned. Her general condition quickly deteriorated and she died three weeks later, namely nine weeks after the first neurological disturbances.

*In summary*, the clinical features of this case comprised: (1) after the first lesion, slight impairment of joint position sense in the right hallux, right tactile inattention, right visual neglect, impairment of right-beating OKN, optic ataxia (for the right hand in the whole visual field and for the left hand in the right visual field), Gerstmann's syndrome and various apraxias; (2) after the second lesion, possible left motor neglect, a dystonic attitude of the left hand, marked disturbance of visual attention in the whole peripheral visual field, disordered visually guided saccades, severe impairment of foveal pursuit, abolition of OKN slow phase (in both lateral directions), and persistence of optic ataxia, apraxia and Gerstmann's syndrome.

## PATHOLOGICAL FINDINGS

Post-mortem examination was performed 9 h after death. It revealed a pancreatic adenocarcinoma with hepatic metastases, nonbacterial thrombotic endocarditis involving the mitral and aortic valves, recent splenic infarction, and multiple distal pulmonary emboli which were the probable cause of death. Neither stenosis nor occlusion were found in the cervical arteries.

The brain weighed 1250 g. On macroscopic examination, coronal sections of the cerebral hemispheres and sections of the brainstem perpendicular to its axis showed two old bilateral infarcts in the posterior part of the middle cerebral artery territory.

For microscopic examination, all slices of the cerebral hemispheres affected by the infarcts were embedded in celloidin, cut serially at 15  $\mu$ m and stained with haematoxylin and eosin and Loyez's method for myelin. Every 7.5 mm on the left and every 15 mm on the right, a section stained for myelin (fig. 1) was drawn with the aid of a camera lucida to define the precise topography of the lesion. Light

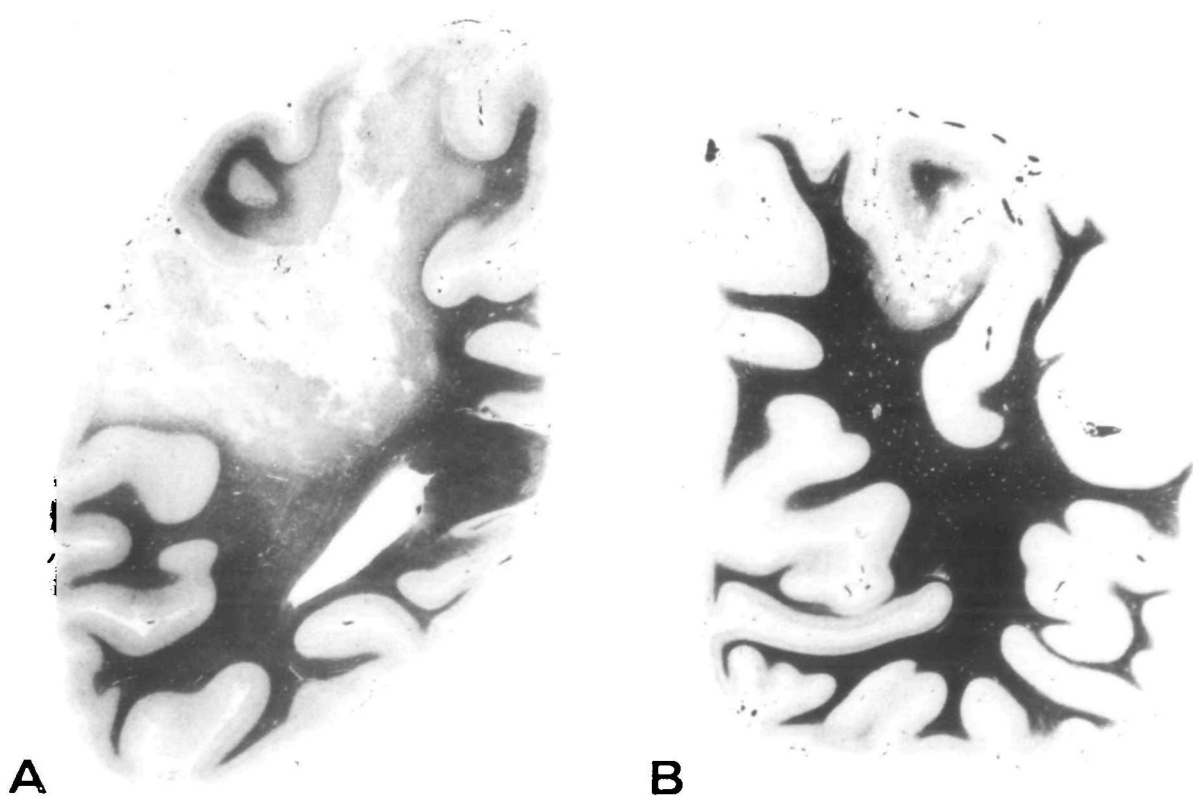


FIG. 1. Coronal sections of the cerebral hemispheres. Loyez  $\times$  1. A, left side, section 2 (see figs 2 and 4). B, right side, section 4 (see figs 3 and 4).

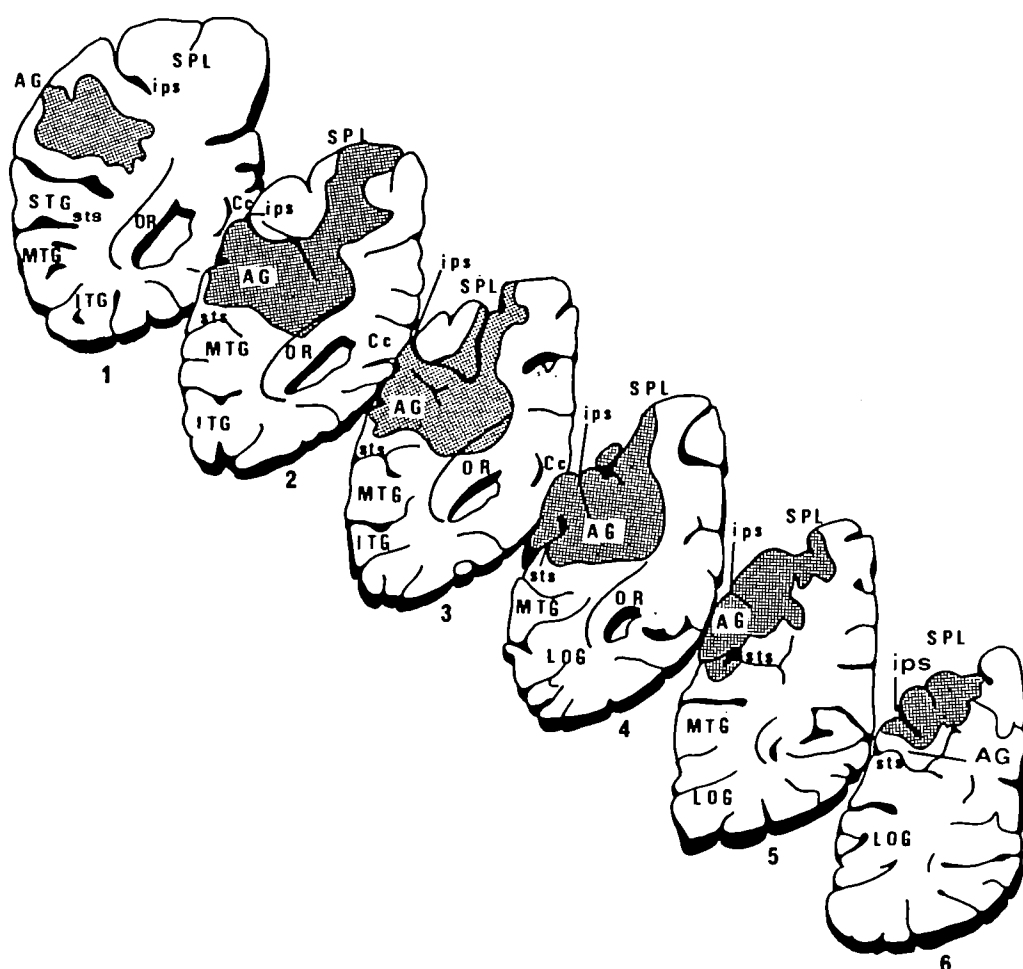


FIG. 2. Coronal sections of the left cerebral hemisphere. Drawn from sections stained by Loyez's method. AG = angular gyrus; Cc = corpus callosum; ips = intraparietal sulcus; ITG = inferior temporal gyrus; LOG = lateral occipital gyri; MTG = middle temporal gyrus; OR = optic radiations; PoCG = postcentral gyrus; pos = parieto-occipital sulcus; PrCG = precentral gyrus; SMG = supramarginal gyrus; SPL = superior parietal lobule; STG = superior temporal gyrus L; sts = superior temporal sulcus. Shaded area = lesion.

microscopy showed that the infarcts contained numerous gitter cells and rare siderophages. No arterial occlusion was found.

In the left cerebral hemisphere (fig. 2), the infarct had destroyed the upper part of the angular gyrus and the posterior and outer part of the superior parietal lobule (SPL), with an extension terminating in the superior and anterior part of this lobule. In the subcortical white matter, the lesion extended to the upper and outer part of the optic radiation, which was barely damaged. The supramarginal gyrus, the posterior part of the temporal gyri and the lateral occipital gyri were unaffected.

In the right cerebral hemisphere (fig. 3), the infarct had destroyed almost all the supramarginal gyrus. It extended posteriorly in the superoanterior extremity of the angular gyrus, in part of the intraparietal sulcus (both of whose margins were damaged) and into a small portion of the SPL. The subcortical white matter was slightly involved by the lesion which did not reach the optic radiation. The postcentral gyrus, the posterior part of the temporal gyri and the lateral occipital gyri were unaffected.

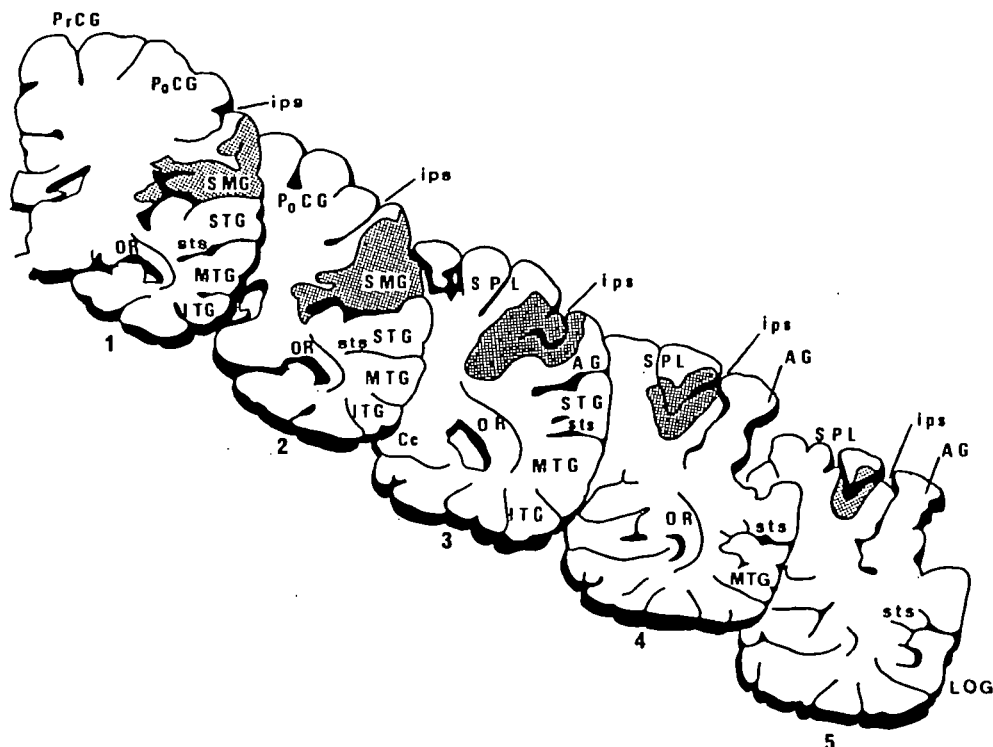


FIG. 3. Coronal sections of the right cerebral hemisphere. Drawn from sections stained by Loyez's method. For abbreviations, see fig. 2.

The brain was otherwise normal. No other ischaemic lesions or any metastases were found.

*In summary*, there had been two cerebral infarcts (fig. 4). The first damaged the upper part of the angular gyrus and a part of the SPL in the left cerebral hemisphere; the second damaged, in the right cerebral hemisphere, almost all the supramarginal gyrus and extended posteriorly into the superoanterior extremity of the angular gyrus, into the adjacent intraparietal sulcus and into a small part of the SPL.

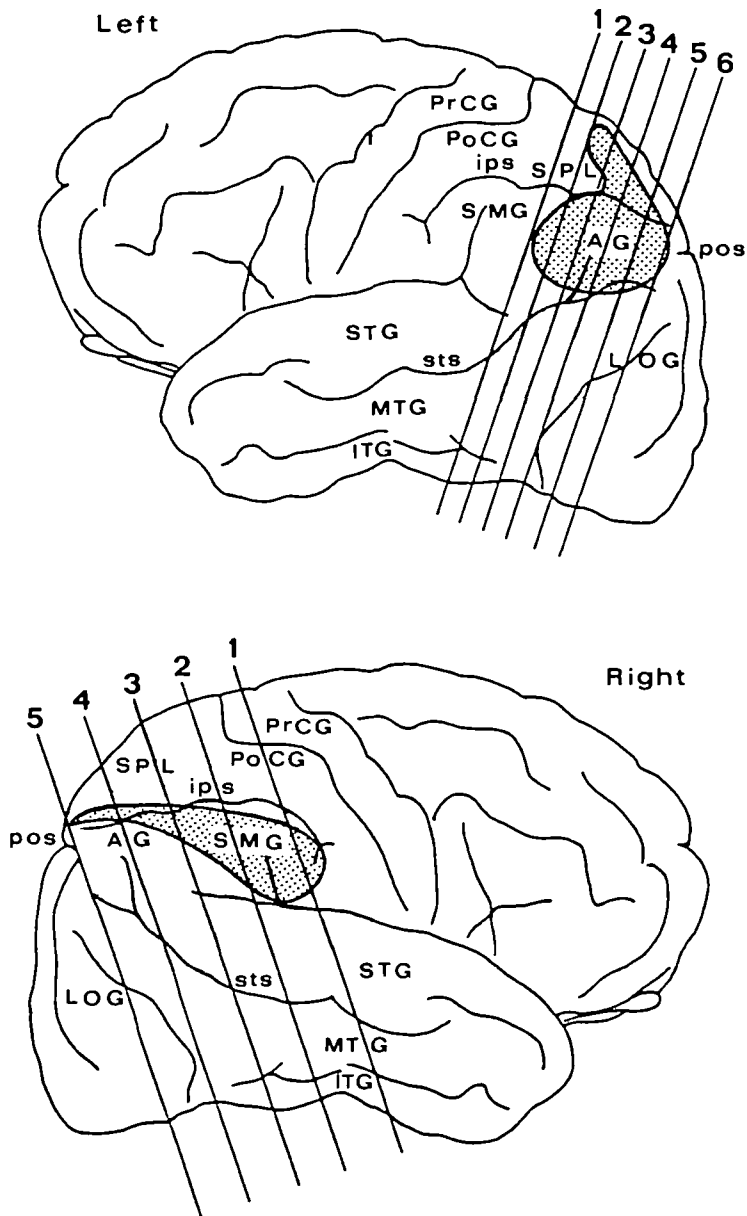


FIG. 4. Representation of the lesions on the cerebral cortex. The section planes are slightly inclined with respect to the coronal plane. Note that the cortical zone damaged in common in both hemispheres is clearly defined on the right side, including all the posterior extremity of the lesion between sections 3 and 5. For abbreviations, *see* fig. 2.

## DISCUSSION

After the first parietal infarct, this patient had multiple neuropsychological disturbances including various apraxias and Gerstmann's syndrome resulting from damage to the left angular gyrus (Gerstmann, 1940; Roeltgen *et al.*, 1983). These disturbances and some others observed after the second infarct, such as possible left motor neglect and a dystonic attitude of the left hand resembling an 'avoiding reaction' (Laplane *et al.*, 1979), were not studied in great detail and therefore will not be discussed. There were also certain oculomotor and visual disorders which, despite the absence of recordings, were sufficiently clear on bedside examination, especially after the second infarct, to allow some clinicopathological correlations.

*Smooth Pursuit Movements*

Each parietal lobe controls smooth pursuit movements in all directions and unilateral parietal lesions affect these movements only partially, with some predominance for those directed ipsilaterally to the lesion (Sharpe, 1982). Foveal smooth pursuit is then supplemented by catch-up saccades and the slow phase gain of OKN (velocity of eye movement on apparent velocity of stimulus) is reduced. In our case, after the left-sided infarct, OKN was impaired when stimulation was directed leftwards, as is usual with unilateral parietal damage (Carmichael *et al.*, 1954; Baloh *et al.*, 1980). After the second infarct, leftward foveal smooth pursuit and OKN slow phase in both lateral directions were abolished. As for the rightward foveal pursuit, it was elicited only by very slow stimulation and whether this residual movement was saccadic (without, therefore, persistence of any smooth movement) is not of critical importance here since the rightward OKN slow phase was abolished. Indeed, given that the OKN slow phase in our case—namely in the first seconds of stimulation (Baloh *et al.*, 1980) and with a stimulus essentially involving foveal vision (Leigh and Zee, 1983)—was probably performed by the same oculomotor system which produces the foveal smooth pursuit, it may be concluded that foveal smooth pursuit movements were at least severely impaired rightwards and abolished leftwards after the second infarct. As foveal smooth pursuit depends mainly on foveal vision, it may furthermore be considered that the visual inattention of our patient, essentially for peripheral stimuli, could not be the actual origin of the severe deficit of this eye movement.

Abolition or striking impairment of horizontal smooth pursuit movements due to bilateral hemisphere damage has been reported, to our knowledge, in only 6 previous clinicopathological cases (Holmes, 1918, Case 5; Hécaen *et al.*, 1950; Hécaen and de Ajiuraguerra, 1954, Cases 3 and 4; Michel *et al.*, 1965; Hausser *et al.*, 1980). Except in the first case (Holmes, 1918), in which the lesion was confined to the IPL on one side but for which the anatomical description was not very precise, the lesions of the other cases largely damaged both parieto-occipital regions, namely the IPL as well as the adjacent occipital cortex, and also, in 4 of



them, the frontal lobes bilaterally. For the clinicopathological case reported by Balint (1909), in which the lesions also damaged both parieto-occipital regions, the different eye movements were not specified in detail. In our case, the lesions lay essentially on both sides in the IPL. On the left, the lesion damaged all the upper part of the angular gyrus and extended upwards to the paramedian part of the SPL. On the right, the supramarginal gyrus was damaged and the lesion extended posteriorly in the superoanterior extremity of the angular gyrus and into the adjacent intraparietal sulcus and in a small part of the SPL. Given that the deficit of smooth pursuit movements was bilateral after the second infarct, it may be deduced that the damaged zone in common in both hemispheres included an area essential for these movements in man. This area appears very small since the damaged zone in common involved only the superoanterior extremity of the angular gyrus, both banks of the adjacent intraparietal sulcus, a small portion of the SPL and a slight portion of the subcortical white matter.

Such a finding correlates with experimental data since, in the monkey, foveal smooth pursuit was deranged after bilateral damage to the IPL sparing the adjacent occipital cortex (Lynch and McLaren, 1982), as in our case. On the other hand, for the OKN elicited by a full-field stimulation to be severely impaired in this animal, both structures would be involved by the lesion (Lynch and McLaren, 1983), but this would then involve mechanisms other than simple foveal stimulation. Visual tracking neurons have been found in the monkey in the dorsal part of the IPL (Mountcastle *et al.*, 1975; Lynch *et al.*, 1977; Sakata *et al.*, 1983)—in the area corresponding in man to the angular gyrus (Eidelberg and Galaburda, 1984)—and they seem to control smooth pursuit movements in both lateral directions, although mainly responding to ipsilateral stimuli (Kawano *et al.*, 1984). It must be pointed out that the precise location of these neurons in the dorsal part of the IPL is not yet well established since Lynch *et al.* (1977) found them near the intraparietal sulcus (the anterior border of the IPL), while Sakata *et al.* (1983) and Kawano *et al.* (1984) found them essentially in or near the dorsal extremity of the superior temporal sulcus (the posterior border of the IPL). The former location corresponds in man to the upper part of the angular gyrus, damaged on both sides in our case, but the latter location corresponds to the lower part of the angular gyrus which, in our case, was partly spared on the left side (*see* fig. 2) and undamaged on the right (*see* fig. 3, sections 3–5). If however, this latter location is confirmed in the monkey it should be noted that the subcortical extension of the lesions in our case could have interrupted the efferents from the lower part of the angular gyrus on both sides (*see* fig. 2, section 3, and fig. 3, section 3). Our anatomical data thus allow us merely to suggest that the cortical area controlling foveal smooth pursuit movements in man is probably inside the angular gyrus, between the dorsal end of the superior temporal sulcus and the adjoining intraparietal sulcus. As for damage to the small portion of the SPL involved by both lesions in our case, it was probably not at the origin of the different visuo-oculomotor disturbances since in the monkey the

SPL does not appear to contain neurons involved in such functions (Mountcastle *et al.*, 1975).

### *Visually Guided Saccades*

Visually guided saccades appeared clinically normal after the left unilateral damage. This is not surprising since, in such cases where recordings of eye movements have been made, only a slight increase in the latencies of contralateral visually guided saccades has been observed (Sundqvist, 1979). After the second lesion, saccades to command were normal, but visually guided saccades from one visual target to another were greatly disturbed bilaterally, the patient having difficulty in transferring gaze from the first target before wandering in search of the second. Furthermore in reading, the patient skipped lines or words. Therefore, visually guided saccades had a marked increase in latency and a lack of accuracy for direction as well as amplitude. It must be emphasized that associated peripheral visual inattention might play some role in these disturbances of visually guided saccades.

Analogous disorders of visually guided saccades have been observed previously in 2 clinicopathological cases having selective bilateral lesions of the parieto-occipital regions (Holmes, 1918, Case 5; Hécaen and de Ajiuraguerra, 1954, Case 3) but also in other clinical cases where the lesions most probably involved mainly the parieto-occipital regions (Godwin-Austen, 1965; Montero *et al.*, 1982). Since disorders of visually guided saccades were bilateral after the second infarct, our anatomical data allow us to suggest that in the parietal-occipital region it is also the superoanterior extremity of the angular gyrus and the adjacent intraparietal sulcus, damaged in common in both hemispheres, which are mainly involved in control of these movements. This appears probable since it has been reported in the monkey that the dorsal part of the IPL near the intraparietal sulcus contains saccade neurons which discharge just before and during visually guided saccades and are intermingled with the visual tracking neurons (Lynch *et al.*, 1977; Shibunati *et al.*, 1984).

It must be pointed out, however, that visually guided saccades, although greatly disorganized, still existed after bilateral lesions of the parieto-occipital region. On the other hand, in 2 cases where bilateral lesions in the region of the frontal eye fields (FEF) were combined with bilateral lesions of the parieto-occipital region (Hécaen and de Ajiuraguerra, 1954, Case 4; Hausser *et al.*, 1980), visually guided saccades were severely impaired or abolished. The FEF of the monkey (Brodman's area 8) contains neurons involved in visually guided saccades (Goldberg and Bushnell; Bruce and Goldberg, 1985). Thus, with destruction of both IPLs, visually guided saccades could still partly be controlled by the FEF: this structure could receive some visual information from the occipital lobes, but also from the superficial (visual) layers of the superior colliculus, either directly (Fries, 1984) or by a pathway passing through the thalamus, in which certain afferent tracts of the FEF (Barbas and Mesulam, 1981) are perhaps connected with certain efferent

tracts of the superior colliculus (Benevento and Fallon, 1975). The effect of lesions of both FEF on visually guided saccades has never to our knowledge been reported in man, but in the monkey it seems that such a destruction induces only subtle and transient oculomotor deficits (Schiller *et al.*, 1980). The deep (motor) layers of the superior colliculus constitute a subcortical area also involved in the control of visually guided saccades (Wurtz and Albano, 1980; Sparks and Mays, 1981) but bilateral damage to this structure is followed only by slight oculomotor deficits (Schiller *et al.*, 1980). On the other hand, bilateral damage to both the FEF and the superior colliculus leads in the monkey to a long-lasting and severe deficit paralysis of all saccades (Schiller *et al.*, 1980), as with bilateral lesions to both the FEF and the IPL in man. As there is in the monkey a direct projection from the IPL—according to Andersen *et al.* (1985), and Lynch *et al.* (1985) especially from the intraparietal sulcus—onto the deep layers of the superior colliculus (Fries, 1984; Weber and Yin, 1984), which could be involved in triggering saccades (Keating *et al.*, 1983), it may be concluded on both clinical and experimental grounds that two cortical areas control visually guided saccades (Pierrot-Deseilligny, 1985). These are (1) the FEF, by direct projections onto the immediate premotor structures of saccades, namely the paramedian pontine reticular formation (PPRF) for lateral movements (Leichnetz *et al.*, 1984a; Schnyder *et al.*, 1985) and the rostral interstitial nucleus of the medial longitudinal fasciculus (riMLF) for vertical movements (Leichnetz *et al.*, 1984b); and (2) the intraparietal sulcus adjacent to the angular gyrus, by indirect projections, including a relay in the superior colliculus, which also projects onto the PPRF (Graham, 1977; Harting, 1977; Raybourn and Keller, 1977) and onto the riMLF (Benevento and Fallon, 1975; Harting, 1977; Grantyn *et al.*, 1982). The IPL and the FEF are, moreover, reciprocally connected in the monkey by direct corticocortical tracts (Pandya *et al.*, 1971; Barbas and Mesulam, 1981; Petrides and Pandya, 1984). The different mechanisms produced in these two cortical areas during the triggering of visually guided saccades and the nature of their reciprocal functional influences remain to be determined precisely.

### *Visual Attention*

After the left-sided infarct, the patient clinically did not have a right hemianopia, but she showed right visual extinction and explored and seemed to see only the left half of pictures. Such signs are typically those of a marked right visual neglect (Chain *et al.*, 1979). After the right-sided infarct, the patient was not hemianopic and post-mortem study confirmed that the optic radiations were not involved by the lesions on the right side and only very slightly damaged on the left. However, although the fingers of the examiner were at times seen moving in the peripheral visual field, this perception was obtained with considerable difficulty. Moreover, the patient seemed to neglect some peripheral visual stimuli. Consequently, despite the absence of detailed investigation, it may be concluded that some bilateral peripheral visual inattention existed after the second infarct.

Contralateral visual neglect is now well known in unilateral parietal damage, usually more marked with lesions of the nondominant cerebral hemisphere but existing also with lesions of the dominant hemisphere (Brain, 1941; Allen, 1948; Critchley, 1953; Hécaen *et al.*, 1956; Heilman and Valenstein, 1972; Chain *et al.*, 1979). The comparative anatomical study of the earliest reported cases allowed Allen (1948) to emphasize that the angular gyrus plays an essential role in visual attention. In clinical cases, with proven or presumed bilateral parieto-occipital lesions, visual inattention involving the whole peripheral visual field has previously been observed, with on occasions a predominance of the disturbance on one side (Balint, 1909; Hécaen *et al.*, 1950; Hécaen and de Ajiuraguerra, 1954; Luria, 1959; Godwin-Austen, 1965; Michel *et al.*, 1965; Hausser *et al.*, 1980; Montero *et al.*, 1982; Guard *et al.*, 1984). Since in our case visual inattention was first unilateral before it affected the whole peripheral visual field after the second infarct, the zone damaged in common in both hemispheres included the area essential for peripheral visual attention in the parietal region, possibly the supero-anterior extremity of the angular gyrus and the adjacent intraparietal sulcus.

Such a finding appears particularly well correlated with the conclusion of a recent study in man. This suggested, on cytoarchitectonic criteria, that a very small zone located in and just below the dorsal portion of the intraparietal sulcus, overlapping slightly on the upper extremity of the angular gyrus and corresponding almost exactly to part of the damaged zone in common on both sides in our case, could be the area involved in visual attention in the parietal lobe (Eidelberg and Galaburda, 1984). Our finding is also correlated with experimental data, since in the monkey the dorsal part of the IPL near the intraparietal sulcus contains neurons involved in visual attention, intermingled with neurons controlling the different visually guided eye movements (Hyvärinen and Poranen, 1974; Mountcastle *et al.*, 1975; Lynch *et al.*, 1977; Bushnell *et al.*, 1981).

### *Optic Ataxia*

Optic ataxia with the right hand in the whole visual field and with the left hand in the right visual field was observed after the initial left-sided infarct. After the second infarct, this disturbance persisted with the right hand but could no longer be tested with the left because of its dystonic attitude. For this reason, only the disorder observed after the left infarct will be commented upon here and compared with previously reported cases in which lesions were certainly or presumably unilateral. Consequently, although the clinical triad observed in our case, namely disorders of visually guided eye movements, peripheral visual inattention and optic ataxia, was finally close to that in the clinicopathological case described by Balint (1909), the cases will not be compared because in Balint's case optic ataxia was associated not only with bilateral lesions of the parieto-occipital regions but also with another in the right precentral gyrus.

It has been suggested, both on experimental (Haaxma and Kuypers, 1975) and clinical grounds (Rondot *et al.*, 1977), that optic ataxia results from damage to

the visuomotor connections between the occipital and the frontal lobes. These connections would include (Rondot *et al.*, 1977) (1) a direct pathway, coursing in the upper half of the white matter of the parietal lobe, possibly through the superior longitudinal fasciculus according to the anatomical data of Dejerine and Dejerine-Klumpke (1895, 1901), and (2) a crossed pathway, probably passing through the splenium of the corpus callosum. Thus, each motor area controlling hand movement would receive visual information from both occipital lobes.

Such an organization is supported by functional and structural correlates in man. Surgical section at the parieto-occipital junction, just dorsal to the angular gyrus, has induced an optic ataxia for both hands but only in the visual hemifield contralateral to the lesion (Rondot *et al.*, 1977). The direct pathway between the ipsilateral occipital lobe and the ipsilateral frontal lobe and the crossed pathway between the ipsilateral occipital lobe and the contralateral frontal lobe (before its decussation through the splenium of the corpus callosum) were then probably damaged. A lesion of the splenium of the corpus callosum has induced a visuomotor disturbance resembling optic ataxia for both hands but, for each of them, only in the visual hemifield contralateral to the hand (Gazzaniga *et al.*, 1965). Both crossed pathways were then damaged. In a lesion involving, as in our case, the angular gyrus and adjacent superior parietal lobule, or in 2 other cases mainly involving the posterior part of the superior parietal lobule (Levine *et al.*, 1978; Auerbach and Alexander, 1981), optic ataxia affecting the contralateral hand in the whole visual field and the ipsilateral hand in the visual hemifield contralateral to the lesion was observed. Such a syndrome may be explained by the particular location, in our case, of the lesion which could have damaged (1) the direct pathway coursing in the deep white matter probably near the junction between the superior and inferior parietal lobules, (2) the crossed pathway between the ipsilateral occipital lobe and the contralateral frontal lobe, *before* its decussation since, in the posteroanterior direction, the lesion began just at the posterior limit of the angular gyrus and (3) the crossed pathway between the contralateral occipital lobe and the ipsilateral frontal lobe, *after* its decussation, since the lesion, in the superior and inferior parietal lobules, terminated at the anterior limit of the angular gyrus. To damage both crossed pathways, a unilateral hemisphere lesion must probably be, as in our case, first, close to the lateral portion of the splenium of the corpus callosum, namely in the white matter located deeply and medially with respect to the anterior half of the angular gyrus and, secondly, slightly extended in the posteroanterior direction in order to involve both types of fibre, before and after their decussation. Lastly, a lesion of the superior parietal lobule more anteriorly located (just above the supramarginal gyrus) might induce optic ataxia not only in the whole visual field but also in the contralateral hand, by damaging both the direct pathway and the crossed pathway, after its decussation. Such a clinicopathological correlation has not so far been reported to our knowledge, probably because there is usually a severe associated sensory deficit which prevents the detection of possible optic ataxia. However, in 2 clinical cases, without definite verification of the

location of the lesions but in which visual and sensori-motor function was preserved, optic ataxia of this last type has been described (Schott *et al.*, 1972).

### Conclusion

This clinicopathological case allows us to suggest that the parietal area mainly involved both in the control of visually guided eye movements and in visual attention is included in the angular gyrus and in the adjacent intraparietal sulcus. Furthermore, our data support the hypothesis that optic ataxia results from damage to direct and/or crossed occipitofrontal pathways coursing in the deep white matter of the parietal lobe.

### REFERENCES

- ALLEN I M (1948) Unilateral visual inattention. *The New Zealand Medical Journal*, **47**, 605-617.
- ANDERSEN R A, ASANUMA C, COWAN W M (1985) Callosal and prefrontal associational projecting cell populations in area 7A of the macaque monkey: a study using retrogradely transported fluorescent dyes. *Journal of Comparative Neurology*, **232**, 443-455.
- AUERBACH S H, ALEXANDER M P (1981) Pure agraphia and unilateral optic ataxia associated with a left superior parietal lobule lesion. *Journal of Neurology, Neurosurgery and Psychiatry*, **44**, 430-432.
- BALINT R (1909) Seelenlähmung des 'Schauens,' optische Ataxie, räumliche Störung der Aufmerksamkeit. *Monatschrift für Psychiatrie und Neurologie*, **25**, 51-81.
- BALOH R W, YEE R D, HONRUBIA V (1980) Optokinetic nystagmus and parietal lobe lesions. *Annals of Neurology*, **7**, 269-276.
- BARBAS H, MESULAM M-M (1981) Organization of afferent input to subdivisions of area 8 in the rhesus monkey. *Journal of Comparative Neurology*, **200**, 407-431.
- BENEVENTO L A, FALLON J H (1975) The ascending projections of the superior colliculus in the rhesus monkey (*Macaca mulatta*). *Journal of Comparative Neurology*, **160**, 339-361.
- BRAIN W R (1941) Visual disorientation with special reference to lesions of the right cerebral hemisphere. *Brain*, **64**, 244-272.
- BRUCE C J, GOLDBERG M E (1985) Primate frontal eye fields. I. Single neurons discharging before saccades. *Journal of Neurophysiology*, **53**, 603-635.
- BUSHNELL M C, GOLDBERG M E, ROBINSON D L (1981) Behavioral enhancement of visual responses in monkey cerebral cortex. I. Modulation in posterior parietal cortex related to selective visual attention. *Journal of Neurophysiology*, **46**, 755-772.
- CARMICHAEL E A, DIX M R, HALLPIKE C S (1954) Lesions of the cerebral hemispheres and their effects upon optokinetic and caloric nystagmus. *Brain*, **77**, 345-372.
- CHAIN F, LEBLANC M, CHEDRU F, LHERMITTE F (1979) Négligence visuelle dans les lésions postérieures de l'hémisphère gauche. *Revue Neurologique*, **135**, 105-126.
- CRITCHLEY M (1953) *The Parietal Lobes*. London: Edward Arnold.
- DEJERINE J, DEJERINE-KLUMPKE A (1895, 1901) *Anatomie des Centres Nerveux*. Paris: Masson.
- EIDELBERG D, GALABURDA A M (1984) Inferior parietal lobule. Divergent architectonic asymmetries in the human brain. *Archives of Neurology, Chicago*, **41**, 843-852.
- FRIES W (1984) Cortical projections to the superior colliculus in the macaque monkey: a retrograde study using horseradish peroxidase. *Journal of Comparative Neurology*, **230**, 55-76.
- GAZZANIGA M S, BOGEN J E, SPERRY R W (1965) Observations on visual perception after disconnection of the cerebral hemispheres in man. *Brain*, **88**, 221-236.

- GERSTMANN J (1940) Syndrome of finger agnosia, disorientation for right and left, agraphia and acalculia: local diagnostic value. *Archives of Neurology and Psychiatry, Chicago*, **44**, 398–408.
- GODWIN-AUSTEN R B (1965) A case of visual disorientation. *Journal of Neurology, Neurosurgery and Psychiatry*, **28**, 453–458.
- GOLDBERG M E, BUSHNELL M C (1981) Behavioral enhancement of visual responses in monkey cerebral cortex. II. Modulation in frontal eye fields specifically related to saccades. *Journal of Neurophysiology*, **46**, 773–787.
- GRAHAM J (1977) An autoradiographic study of the efferent connections of the superior colliculus in the cat. *Journal of Comparative Neurology*, **173**, 629–654.
- GRANTYN A, GRANTYN R, BERTHOZ A, RIBAS J (1982) Tectal control of vertical eye movements: a search for underlying neuronal circuits in the mesencephalon. In: *Physiological and Pathological Aspects of Eye Movements*. Edited by A. Roucoux and M. Crommelinck. The Hague and London: Junk, pp. 337–344.
- GUARD O, PERENIN M T, VIGHETTO A, GIROUD M, TOMMASI M, DUMAS R (1984) Syndrome pariétal bilatéral proche d'un syndrome de Balint. *Revue Neurologique*, **140**, 358–367.
- HAAXMA R, KUYPERS H G J M (1975) Intrahemispheric cortical connexions and visual guidance of hand and finger movements in the rhesus monkey. *Brain*, **98**, 239–260.
- HARTING J K (1977) Descending pathways from the superior colliculus: an autoradiographic analysis in the rhesus monkey (*Macaca mulatta*). *Journal of Comparative Neurology*, **173**, 583–612.
- HAUSSER C O, ROBERT F, GIARD N (1980) Balint's syndrome. *The Canadian Journal of Neurological Sciences*, **7**, 157–161.
- HÉCAEN M, AJIURAGUERRA J DE (1954) Balint's syndrome (psychic paralysis of visual fixation) and its minor forms. *Brain*, **77**, 373–400.
- HÉCAEN H, AJIURAGUERRA J DE, ROUQUÈS L, DAVID M, DELL M B (1950) Paralysie psychique du regard de Balint au cours de l'évolution d'une leucoencéphalite type Balo. *Revue Neurologique*, **81**–104.
- HÉCAEN H, PENFIELD W, BERTRAND C, MALMO R (1956) The syndrome of apractognosia due to lesions of the minor cerebral hemisphere. *Archives of Neurology and Psychiatry, Chicago*, **75**, 400–434.
- HEILMAN K M, VALENSTEIN E (1972) Auditory neglect in man. *Archives of Neurology, Chicago*, **26**, 32–35.
- HOLMES G (1918) Disturbances of visual orientation. *British Journal of Ophthalmology*, **2**, 449–468.
- HYVÄRINEN J, PORANEN A (1974) Function of the parietal associative area 7 as revealed from cellular discharges in alert monkeys. *Brain*, **97**, 673–692.
- KAWANO K, SASAKI M, YAMASHITA M (1984) Response properties of neurons in posterior parietal cortex of monkey during visual-vestibular stimulation. I. Visual tracking neurons. *Journal of Neurophysiology*, **51**, 340–351.
- KEATING E G, GOOLEY S G, PRATT S E, KELSEY J E (1983) Removing the superior colliculus silences eye movements normally evoked from stimulation of the parietal and occipital eye fields. *Brain Research, Amsterdam*, **269**, 145–148.
- LAPLANE D, MEININGER V, BANCAUD J, TALAIRACH J, BROGLIN D (1979) Contribution à l'étude anatomo-clinique des phénomènes d'évitement. *Revue Neurologique*, **135**, 775–787.
- LEICHNETZ G R, SMITH D J, SPENCER R F (1984a) Cortical projections to the paramedian tegmental and basilar pons in the monkey. *Journal of Comparative Neurology*, **228**, 388–408.
- LEICHNETZ G R, SPENCER R F, SMITH D J (1984b) Cortical projections to nuclei adjacent to the oculomotor complex in the medial dien-mesencephalic tegmentum in the monkey. *Journal of Comparative Neurology*, **228**, 359–387.
- LEIGH R J, ZEE D S (1983) *The Neurology of Eye Movements*. Philadelphia: Davis.
- LEVINE D N, KAUFMAN K J, MOHR J P (1978) Inaccurate reaching associated with a superior parietal lobe tumor. *Neurology, New York*, **28**, 556–561.

- LURIA A R (1959) Disorders of 'simultaneous perception' in a case of bilateral occipito-parietal brain injury. *Brain*, **82**, 437-449.
- LYNCH J C, GRAYBIEL A M, LOBECK L J (1985) The differential projection of two cytoarchitectonic subregions of the inferior parietal lobule of Macaque upon the deep layers of the superior colliculus. *Journal of Comparative Neurology*, **235**, 241-251.
- LYNCH J C, MOUNTCASTLE V B, TALBOT W H, YIN T C T (1977) Parietal lobe mechanisms for directed visual attention. *Journal of Neurophysiology*, **40**, 362-389.
- LYNCH J C, McLAREN J W (1982) The contribution of parieto-occipital association cortex to the control of slow eye movements. In: *Functional Basis of Ocular Motility Disorders*. Edited by G. Lennerstrand, D. S. Zee and E. L. Keller. Oxford: Pergamon Press, pp. 501-510.
- LYNCH J C, McLAREN J W (1983) Optokinetic nystagmus deficits following parieto-occipital cortex lesions in monkeys. *Experimental Brain Research*, **49**, 125-130.
- MESULAM M-M (1981) A cortical network for directed attention and unilateral neglect. *Annals of Neurology*, **10**, 309-325.
- MICHEL F, JEANNEROD M, DEVIC M (1965) Trouble de l'orientation visuelle dans les trois dimensions de l'espace. *Cortex*, **1**, 441-466.
- MONTERO J, PEÑA J, GENIS D, RUBIO F, PERES-SERRA J, BARRAQUER-BORDAS L (1982) Balint's syndrome. Report of four cases with watershed parieto-occipital lesions from vertebrobasilar ischemia or systemic hypotension. *Acta Neurologica Belgica*, **82**, 270-280.
- MOUNTCASTLE V B, LYNCH J C, GEORGOPOULOS A, SAKATA H, ACUNA C (1975) Posterior parietal association cortex of the monkey: command functions for operations within extrapersonal space. *Journal of Neurophysiology*, **38**, 871-908.
- PANDYA D N, DYE P, BUTTERS N (1971) Efferent cortico-cortical projections of the prefrontal cortex in the rhesus monkey. *Brain Research Amsterdam*, **31**, 35-46.
- PETRIDES M, PANDYA D N (1984) Projections to the frontal cortex from the posterior parietal region in the rhesus monkey. *Journal of Comparative Neurology*, **228**, 105-116.
- PIERROT-DESEILLIGNY C (1985) Circuits oculomoteurs centraux. *Revue Neurologique*, **141**, 349-370.
- RAYBOURN M S, KEELER E L (1977) Colliculoreticular organization in primate oculomotor system. *Journal of Neurophysiology*, **40**, 861-878.
- ROELTGEN D P, SEVUSH S, HEILMAN K M (1983) Pure Gerstmann's syndrome from a focal lesion. *Archives of Neurology, Chicago*, **40**, 46-47.
- RONDOT P, RECONDO J DE, DUMAS J L R (1977) Visuomotor ataxia. *Brain*, **100**, 355-376.
- SAKATA H, SHIBUTANI H, KAWANO K (1983) Functional properties of visual tracking neurons in posterior parietal association cortex of the monkey. *Journal of Neurophysiology*, **49**, 1364-1380.
- SCHILLER P H, TRUE S D, CONWAY J L (1980) Deficits in eye movements following frontal eye-field and superior colliculus ablations. *Journal of Neurophysiology*, **44**, 1175-1189.
- SCHNYDER H, REISINE H, HEPP K, HENN V (1985) Frontal eye field projection to the paramedian pontine reticular formation traced with wheat germ agglutinin in the monkey. *Brain Research, Amsterdam*, **329**, 151-160.
- SCHOTT B, MICHEL D, EYSETTE M (1972) Troubles de la structuration spatiale et enregistrement du regard. In: *Troubles du Regard et Mouvements Oculaires Anormaux dans les Atteintes du Système Nerveux Central*. Edited by B. Schott, M. Jeannerod and M. Boucher. Paris: Doin, pp. 165-175.
- SHARPE J A (1982) Cerebral ocular motor deficits. In: *Functional Basis of Ocular Motility Disorders*. Edited by G. Lennerstrand, D. S. Zee and E. L. Keller. Oxford: Pergamon Press, pp. 479-495.
- SHIBUNATI H, SAKATA H, HYVÄRINEN J (1984) Saccade and blinking evoked by microstimulation of the posterior parietal association cortex of the monkey. *Experimental Brain Research*, **55**, 1-8.
- SPARKS D L, MAYS L E (1981) The role of the monkey superior colliculus in the control of saccadic eye movements: a current perspective. In: *Progress in Oculomotor Research*. Edited by A. F. Fuchs and W. Becker. New York: Elsevier, pp. 137-144.



- SUNDQVIST A (1979) Saccadic reaction-time in parietal-lobe dysfunction. *Lancet*, *i*, 870.
- WEBER J T, YIN T C T (1984) Subcortical projections of the inferior parietal cortex (area 7) in the stump-tailed monkey. *Journal of Comparative Neurology*, **224**, 206-230.
- WURTZ R H, ALBANO J E (1980) Visual-motor function of the primate superior colliculus. *Annual Review of Neuroscience*, **3**, 189-226.

(Received January 29, 1985. Revised April 23, 1985. Accepted May 21, 1985)