

Pure Word Deafness: A Possible Explanation of Transient Deteriorations after Extracranial-Intracranial Bypass Grafting

Steven L. Kanter, M.D., Arthur L. Day, M.D., Kenneth M. Heilman, M.D. and Leslie J. Gonzalez-Rothi, Ph.D.

Departments of Neurosurgery (SLK, ALD) and Neurology (KMH, LJG-R), University of Florida, Gainesville, Florida

Pure word deafness is a rare behavioral disorder in which the comprehension of spoken language is grossly disturbed, but the abilities to speak, read, write, and process nonverbal auditory stimuli remain intact. This disorder is caused by superior temporal gyrus lesions in the dominant hemisphere that isolate Wernicke's area from incoming auditory information. This involved area is supplied by cortical middle and posterior temporal end-artery branches of the middle cerebral artery. Among approximately 100 extracranial-intracranial bypass procedures performed at our institution in the past 5 years, three patients developed the syndrome of pure word deafness. A cortical or posterior temporal branch of the middle cerebral artery was utilized as the recipient artery in each instance. In all cases, the deficit was transient, delayed (i.e. the patient did not awaken from anesthesia with the deficit), and unrelated to the preoperative deficit. The syndrome of pure word deafness may be more common after bypass than is currently recognized. Localized arterial spasm, dysautoregulation secondary to operative manipulation, or focal brain swelling may be operative mechanisms in the development of this and other delayed, reversible deficits related to bypass surgery. (*Neurosurgery* 18:186-189, 1986)

Key words: Auditory agnosia, Cerebral ischemia, Cerebral revascularization, Extracranial-intracranial bypass graft, Postoperative neurological deficit, Pure word deafness, Transient ischemic attack

INTRODUCTION

Pure word deafness (PWD), or auditory agnosia for speech, is a rare behavioral disorder characterized by an impaired ability to comprehend speech, while the abilities to speak, read, write, and process nonverbal auditory stimuli remain intact (2, 5, 6). Clinicopathological studies reveal that most cases of PWD are associated with bilateral temporal lobe lesions secondary to cerebrovascular disease (the two lesions usually occur at different times) (1, 10).

Unilateral left temporal lobe lesions may also induce PWD. In such cases, the lesion spares the posterior portion of the superior temporal gyrus (Wernicke's area), but destroys both the left auditory radiation from Heschl's gyrus and the callosal fibers originating in the right temporal lobe, thereby isolating Wernicke's area from auditory input (8). We are reporting three cases of transient PWD that occurred after left-sided extracranial-to-intracranial (EC-IC) bypass grafting. In each instance, a cortical artery supplying the superior temporal gyrus was utilized as the recipient vessel.

CASE REPORTS

Case 1

This 68-year-old hypertensive man presented with a 3-year history of intermittent left-sided exotropia. During otorhinolaryngological operation to repair a septal deviation, a "polyp" was discovered and biopsied, producing immediate severe hemorrhage that could only be controlled with rigorous nasal packing. Subsequent cerebral angiography revealed a giant left cavernous carotid aneurysm (Fig. 1). The patient was transferred to our hospital, where careful questioning revealed a 20-year history of slow, painless, progressive visual loss in the left eye and a 1-year history of left ptosis.

Physical examination at admission revealed extensive packing in the nasal cavity and nasopharynx, as well as a hemotympanum. Neurological examination disclosed a blind left

eye, with an oculomotor and abducens nerve palsy. Repeat cerebral angiography confirmed the presence of a giant intracavernous carotid artery aneurysm.

The patient subsequently underwent balloon trapping of the aneurysm combined with a left EC-IC bypass, using a cortical artery supplying the superior temporal gyrus. The patient's initial postoperative course was uneventful. However, on the 3rd postoperative day, he developed findings characteristic of PWD. He was unable to comprehend the simplest verbal command, whereas his reading, writing, and speaking were unimpaired. He was able to comprehend nonverbal environmental sounds and emotional prosody. There were no accompanying motor or sensory signs or seizure activity. Only minimal postoperative changes were noted on computed tomographic (CT) scan. The PWD rapidly improved over several days and completely resolved over a few weeks. Cerebral angiography performed 2 months postoperatively demonstrated a patent EC-IC anastomosis, with non-filling of the giant aneurysm (Fig. 2).

Case 2

This 53-year-old, right-handed man with severe arteriosclerotic heart disease experienced multiple episodes of right hemibody weakness associated with a nonfluent speech deficit. Cerebral CT scanning revealed a small infarct in the high left frontoparietal region. On cerebral angiography, the left internal carotid artery was completely occluded just distal to its origin. Arteriographic filling of the left middle cerebral artery (MCA) territory from collateral sources was poor. The contributions via the left external carotid artery through ophthalmic anastomoses and posterior communicating channels were minimal, and there was no crossfilling from the right carotid system directly into the left MCA.

The patient underwent successful coronary artery bypass grafting, but his cerebral episodes continued postoperatively in spite of oral anticoagulant therapy (warfarin). Three months later, he was referred for cerebral revascularization.

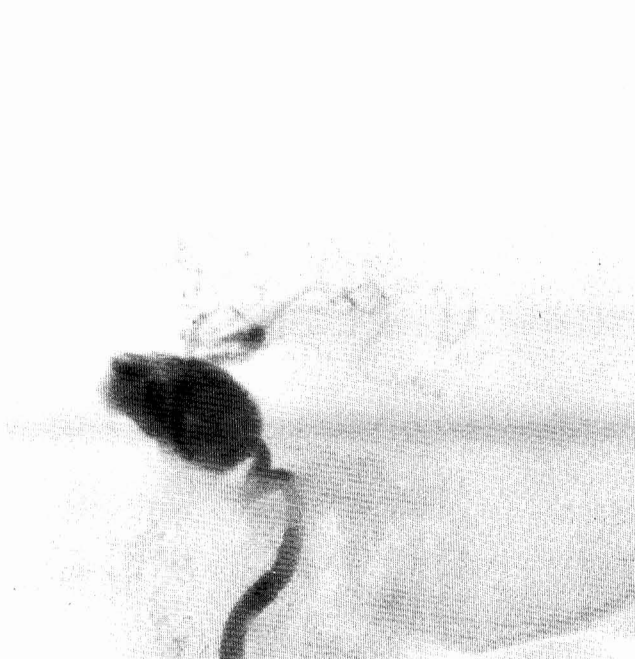

FIG. 1. Case 1. Preoperative cerebral angiogram (lateral view) reveals filling of a giant left cavernous carotid aneurysm.

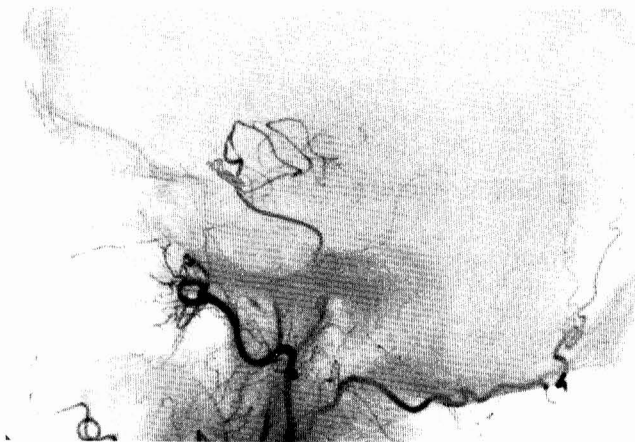


FIG. 2. Case 1. Postoperative cerebral angiogram (lateral view) reveals no evidence of filling of the giant aneurysm; the bypass is providing good flow to the superior temporal gyrus region, but is not contributing substantial arteriographic flow in a retrograde direction to other MCA branches. There was excellent crossover via the anterior communicating artery from the right carotid system.

Physical examination at admission revealed a mild right hemiparesis (leg worse than arm) and a trace right central facial palsy. Mentation appeared to be dulled, but no specific language deficits could be demonstrated. Using a superior temporal cortical branch of the MCA as the recipient vessel, a left EC-IC bypass was performed without complications. The initial postoperative course was uncomplicated, but on the 3rd postoperative day, the patient's wife reported that her husband had developed "decreased hearing." He subsequently experienced a right focal motor seizure. After apparent recovery from the seizure, a bedside higher cortical function evaluation revealed a deficit consistent with PWD. Although his speech was normal, he was unable to understand spoken words. Reading, writing, and fluency were normal. An emer-

gency CT scan revealed only minimal edema at the operative site.

Within several days, the PWD had completely resolved, and the patient had returned to his previous base line neurological status. A limited cerebral angiogram on the 7th postoperative day revealed good MCA filling in both retro- and orthograde directions via the anastomosis.

Case 3

This 64-year-old, hypertensive man with bilateral symptomatic internal carotid artery occlusions (transient ischemic attacks) subsequently underwent bilateral external carotid endarterectomies for severe external carotid stenoses. Six weeks after the second procedure, the patient experienced a 30-minute episode of confusion, expressive speech difficulty, and diffuse weakness. The findings of his neurological examination thereafter returned to normal. Cerebral angiography 2 weeks later revealed a patent external carotid operative site, but continued poor filling of the left hemisphere by collateral pathways.

The patient underwent an uncomplicated left EC-IC bypass grafting procedure using a superior temporal cortical recipient vessel. He awoke from anesthesia without neurological deficit, but the immediate postoperative period was complicated by several brief episodes of atrial fibrillation. On the 3rd postoperative day, his wife reported that he was intermittently "confused." On the 4th postoperative day, the patient was noted to be hypertensive to 270/98, and he subsequently experienced a grand mal seizure. As his postictal confusion cleared, the patient again became awake and alert. However, a language deficit with features characteristic of PWD was noted. The patient had normal fluent speech and was able to communicate with writing and reading, but was unable to understand spoken language.

An emergency CT scan revealed a questionable area of focal lucency in the left posterior superior temporal gyrus region. Cerebral angiography on the following day revealed good anastomosis patency and no evidence of branch occlusion. Electroencephalography revealed left hemispheric periodic lateralized epileptiform discharges. Over the next several days, the language deficit resolved, and no further seizure activity occurred.

DISCUSSION

PWD is one of a group of nonaphasic cortical auditory comprehension disorders that includes cortical deafness (unawareness of auditory stimuli, abnormal pure tone thresholds, absent peripheral or brain stem damage), auditory agnosia for nonspeech sounds (inability to recognize nonverbal sounds, preserved speech comprehension), and generalized auditory agnosia (intact auditory acuity, inability to comprehend verbal or nonverbal auditory stimuli). The term "pure word deafness" refers to impaired auditory comprehension of speech with relatively preserved reading, writing, spontaneous speech, and comprehension of nonverbal sounds (8). All three of our patients exhibited these findings and therefore conform with the diagnosis of PWD.

PWD patients are able to speak normally because Wernicke's area, Broca's area, and the connections between these areas are intact. They are able to read and write normally because, except for writing from dictation, auditory input is not critical to these functions. Recognition of environmental sounds and emotional prosody are preserved, as these functions are probably mediated by the right hemisphere temporal lobe (8). A schematic diagram of the functional dysconnection in PWD is presented in Figure 3.

Although PWD is usually associated with bilateral superior temporal gyrus lesions, it has also occurred with unilateral lesions of the left temporal lobe (8–10). As there was no evidence of right temporal lobe abnormalities in our patients, we believe that PWD was induced by dominant (left) temporal lobe dysfunction.

Most reported cases of PWD are caused by vascular disease, although some have been attributed to trauma, tumor, and infection (8). Production of this syndrome from unilateral disease apparently requires injury to those regions adjacent to the left Heschl's gyrus, a small insular cortical region located anterior and medial to Wernicke's area in the superior temporal gyrus. These two areas (Heschl's and Wernicke's) are supplied by cortical middle and posterior temporal end-artery branches of the MCA (Fig. 4) (3, 7).

The cortical branches supplying regions near and including

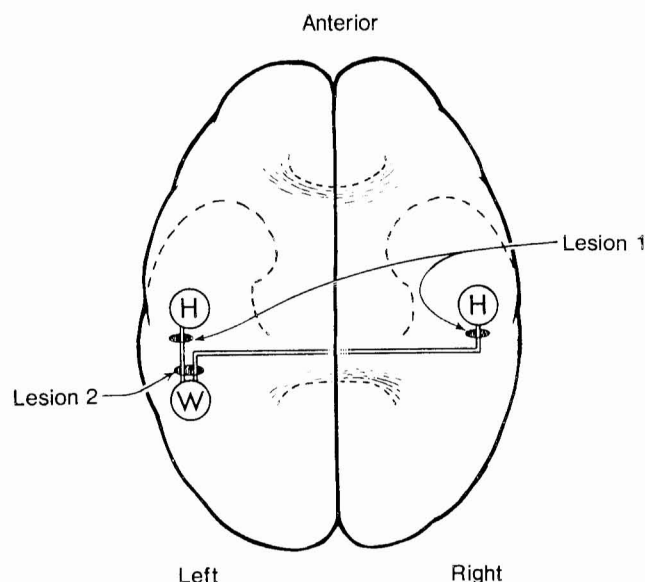


FIG. 3. Schematic diagram illustrates auditory radiations from Heschl's gyrus (*H*) to Wernicke's area (*W*). Disruption of these pathways, either from bilateral lesions (*Lesion 1*) or from a lesion on the left side after the radiations have united (*Lesion 2*), can isolate Wernicke's area from incoming auditory information, thereby producing the clinical syndrome of PWD.

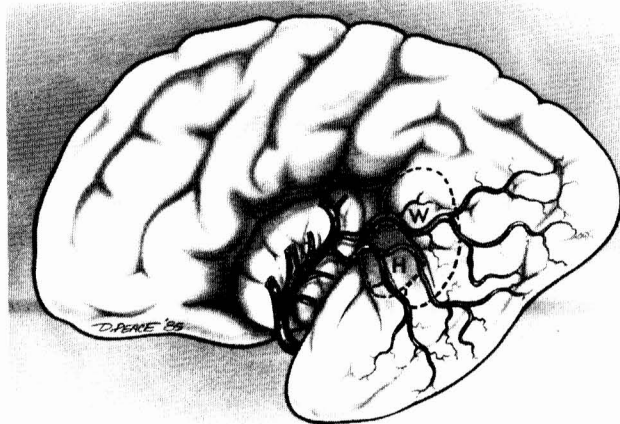


FIG. 4. Schematic representation of the blood supply to Heschl's gyrus (*H*) and Wernicke's area (*W*). Both regions are supplied by end-arterial segments of middle and posterior temporal MCA branches.

Heschl's gyrus may occasionally be used as recipient vessels during EC-IC bypass procedures (although the exact incidence of utilization in our series is not known). In the three patients presented, PWD followed an EC-IC bypass during which a middle or posterior temporal branch of the dominant hemisphere MCA was utilized as the recipient vessel. In each case, the deficit was transient, delayed, and different from any preoperative neurological dysfunction. Thus, the development of this syndrome under these circumstances lends further support for the anatomical substrate and localization of PWD. On a broader scale, this group of patients, each of whom developed a specific and focal neurological syndrome when a particular cortical vessel was surgically manipulated, may provide substantial insight into the cause of the transient deficits that occasionally follow EC-IC bypass.

Each of our three patients awoke from anesthesia able to understand spoken language, but subsequently experienced deterioration of this ability approximately 3 days postoperatively. Anesthesia or generalized systemic factors do not seem to be explanations because no significant episode of intra- or postoperative hypotension was recorded and no deficit was noted during the immediate postoperative period. Other obvious causes for deterioration, such as intracerebral or extracerebral hemorrhage, were eliminated by CT scanning.

One possible explanation for the development of this syndrome in this patient group is embolism. Each of these patients had an ipsilateral internal carotid occlusion, including one iatrogenic occlusion for a giant aneurysm (Case 1). Each, therefore, had an internal carotid artery stump that could have potentially embolized via the anastomosis to the recipient vessel. Alternatively, an embolic source could also have originated at the anastomosis site. Thrombosis of the cortical recipient vessel, however, was not an accompaniment, as each patient exhibited a patent bypass in both ortho- and retrograde directions. In our opinion, the lack of evidence of arterial branch occlusion by arteriography and the lack of symptom recurrence without specific intervening treatment make embolic mechanisms doubtful.

A more probable cause of these temporary deficits may be related to local vascular disturbances secondary to operative manipulation of the recipient vessel or leakage of small amounts of blood around the anastomosis. During the bypass, the small cortical artery is clamped for 30 to 40 minutes to suture the anastomosis, and this compression could lead to a temporary loss of neurogenic control of that vessel. Small amounts of blood seepage around this "denervated" vessel segment might also promote some element of local delayed vasospasm such as follows aneurysmal subarachnoid hemorrhage. Under such circumstances, autoregulation could be lost in the distal distribution of that vessel segment and could account for the "end-artery" clinical picture.

Damage done by coagulation of small perforators at the anastomotic site during preparation of the recipient vessel may also be a contributing factor, as this manipulation could produce focal swelling that might take several days to reach maximal (and clinically apparent) proportions. The wives of two of our patients had reported that their spouses were "hard of hearing" for 24 hours before recognition of the deficit, and this complaint probably represented early features of the syndrome. Furthermore, the deficit in each patient appeared during rapid postoperative tapering of steroid therapy, at a time when brain swelling would have been maximal (3 days after operation).

Both of these factors (the autoregulation disturbance and focal swelling) may also be contributory in the development of postoperative seizures. Although all of our bypass patients receive routine postoperative anticonvulsants, two patients

(Cases 2 and 3) experienced seizure activity that was temporally related to the onset of the language problem.

Recently, Heros et al. reported five patients who experienced temporary neurological deterioration after EC-IC bypass (4). These authors speculated that the bypass might induce a "hyperperfusion syndrome" of chronically hypoperfused regions of the brain. In our group of patients, only Cases 2 and 3 could have been considered to be chronically hypoperfused. Patient 1 underwent carotid occlusion at the time of bypass, and intraoperative blood flow measurement using intraarterial ^{133}Xe before carotid ligation was normal.

Heros et al. also postulated that the bypass might also alter local flow dynamics, leading to shifts in flow patterns that effectively change the "watershed" zone of the MCA, and that this alteration might be a possible contributing mechanism in the production of reversible deteriorations. In our three patients with PWD, however, the neurological deficit was located in the end-artery distribution of the recipient cortical artery rather than in a watershed zone.

In summary, we think that the syndrome of PWD is probably more common in the postbypass patient population than is currently recognized. Diagnosis is limited by a lack of familiarity with the specific neurological features and by the relative preservation of other speech and auditory modalities (patients can also lip-read, which will enable them to interpret speech input via visual cues). The development of this syndrome after utilization of a superior temporal cortical end-artery as a recipient vessel provides good confirmatory anatomical localization of the syndrome and implies that many of the transient deficits after EC-IC bypass may be related to transient phenomena in the specific vessel that receives the anastomosis.

Received for publication, June 4, 1985; accepted, October 13, 1985.

Reprint requests: Arthur L. Day, M.D., Department of Neurosurgery, Box J-265, University of Florida, Gainesville, Florida 32610.

REFERENCES

1. Albert ML, Goodglass H, Helm NA, Rubens AB, Alexander MP: Clinical aspects of dysphasia. New York, Springer-Verlag, 1981. pp 88-91.
2. Geschwind N: Disconnexion syndrome in animals and man. *Brain* 88:283-286, 1965.
3. Gibo H, Carver CC, Rhoton AL, Lenkey C, Mitchel RJ: Microsurgical anatomy of the middle cerebral artery. *J Neurosurg* 54:151-169, 1981.
4. Heros RC, Scott RM, Kistler JP, Ackerman RH, Conner ES: Temporary neurological deterioration after extracranial-intracranial bypass. *Neurosurgery* 15:178-185, 1984.
5. Kussmaul A: Disturbances of speech. *Cyclop Pract Med* 14:581-875, 1877.
6. Lichtheim ML: On aphasia. *Brain* 7:433-484, 1885.
7. Michotey P, Moscow NP, Salamon G: Anatomy of the cortical branches of the middle cerebral artery. in Newton TH, Potts DG (eds): *Radiology of the Skull and Brain*. St Louis, CV Mosby, 1974, vol 2, book 2, pp 1471-1478.
8. Rubens AB: Agnosia. in Heilman KM, Valenstein E (eds): *Clinical Neuropsychology*. New York, Oxford University Press, 1979, pp 251-262.
9. Ulrich G: Interhemispheric functional relationships in auditory agnosia: An analysis of the preconditions and a conceptual model. *Brain Lang* 5:286-300, 1978.
10. Vignolo L: Auditory agnosia: A review and report of recent evidence. in Benton A (ed): *Contributions to Clinical Neuropsychology*. Chicago, Aldine, 1969, pp 172-208.

COMMENTS

Pure word deafness is a very uncommon higher cortical language disturbance, but should be recognized by the neurosurgeon as not simply confusion or difficulty with hearing. Standard aphasia testing for fluency, comprehension, repetition, naming, reading, writing, and the ability to hear sounds, as pointed out by Kanter and his colleagues, provides the processing to probe and unearth the subtle distinctions representing focal deficits. Importantly, these apparently transient dysfunctions may provide pathophysiological clues for ischemic stroke therapy.

Frank M. Yatsu, M.D.
Houston, Texas

Kanter et al. describe a transient complication after EC-IC bypass grafting that may be easily unrecognized or misinterpreted. Pure word deafness may first be detected by family members, who think that the patient has a defect in hearing. With the current popularity of EC-IC bypass procedures and the finding of this syndrome in 3 of 100 consecutive patients, it seems that this short article is an important contribution to the neurosurgical literature.

David G. Sherman, M.D.
San Antonio, Texas