

## Vasospasm After Acoustic Neuroma Removal

Gilberto Machado de Almeida, M.D., Eduardo Bianco, M.D., and Alfredo S. Souza, M.D.

Department of Neurosurgery, Hospital Nove de Julho, São Paulo, Brazil.

de Almeida GM, Bianco E, Souza AS. Vasospasm after acoustic neuroma removal. *Surg Neurol* 1985;23:38-40.

A case of a acoustic neuroma with a two-stage removal due to severe bleeding is presented. The patient remained drowsy after the second operation and by the 8th day deteriorated quickly with progressive right hemiplegia and aphasia. The cerebrospinal fluid was bloody, vasospasm was shown in the angiograms, and an ischemic area was disclosed in the computed tomography scan. The outcome and the neuroradiologic examinations suggested that blood in the basal cisterns caused the vasospasm and the brain ischemia. A review of the literature disclosed only one similar case.

**KEY WORDS:** Subarachnoid hemorrhage; Cerebral vasospasm; Acoustic neuroma

In the last two decades many clinical and experimental studies have discussed the etiology, pathology, clinical significance, prevention, and treatment of vasospasm related to aneurysmal rupture and aneurysmal surgery [3,10,12,18,22,24,28,31]. Vasospasm due to other causes of subarachnoid hemorrhage such as bleeding from an angioma, head injury, or operations on tumors is less frequent. In a recent case report of vasospasm after a removal of a pituitary tumor, Hyde-Rowan et al [11] mentioned only eight similar cases. As far as we are aware, vasospasm after removal of an acoustic neuroma has been reported only once [13].

### Case Report

A 26-year-old man was admitted to the Hospital Nove de Julho (São Paulo) in July 1982, for treatment of a large cerebellopontine angle tumor. For 8 months before admission the patient had been suffering from pain in the distribution of the second branch of the right trigeminal nerve. He had noticed a hearing disturbance on the right side.

Neurologic examination disclosed decreased right corneal reflex, horizontal nistagmus, and right-sided de-

creased hearing. X-rays of the skull, vertebral angiogram, and computed tomography scan showed a right acoustic neuroma, measuring about 50 mm in its largest diameter.

### First Operation

On July 14, 1982 with the patient placed in left lateral decubitus, a right suboccipital craniectomy was carried out. The acoustic porus was enlarged with a diamond drill, and the facial nerve was identified at the porus. Only a partial removal was performed because the tumor was highly vascular and bled excessively. The postoperative course was uneventful, but a right facial paresis was noticed.

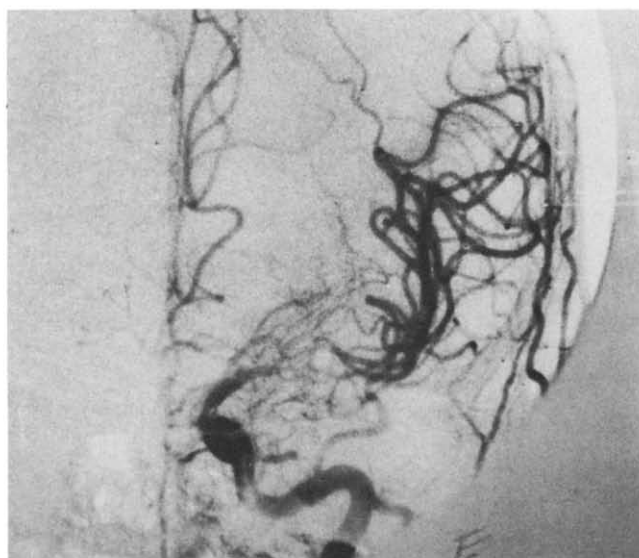
### Second Operation

On July 29, 1982 the craniectomy was reopened with the patient in the same "park bench" position and the remaining tumor was removed. At this time the bleeding was again remarkable. The facial nerve was sacrificed because the tumor was firmly attached to the nerve.

### Postoperative Course

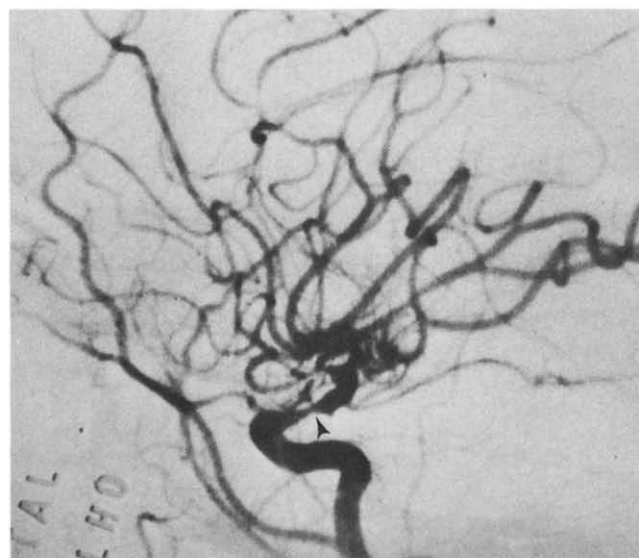After the operation the patient was drowsy, with stiffness of his neck. On August 6, 1982 the patient deteriorated progressively and after 8 hours was aphasic and had hemiplegia on the right side. On the same day a lumbar puncture disclosed hemorrhagic cerebrospinal fluid. The spinal fluid analysis showed 160,000 red blood cells per milliliter, 960 white blood cells per milliliter (16% polymorphonuclear leukocytes), 1,040 mg% of protein, and 31 mg% of glucose. The cerebrospinal fluid culture was negative. The computed tomography scan on the same day and again 2 days later disclosed only postoperative changes in the posterior fossa. On August 12, 6 days after the deterioration, an angiogram of the carotid artery showed vasospasm of the supraclavicular portion of the internal carotid artery and of the proximal segments of the anterior and middle cerebral arteries (Figure 1). On August 19, a small left parietal ischemic area was seen in the computed tomography scan (Figure 2). The neurologic deficits improved progressively. One year later the patient remained with a right

Address reprint requests to: Gilberto Machado de Almeida, Caixa Postal 11488, 05499 São Paulo, Brazil.



A

**Figure 1.** Angiogram of the left internal carotid artery, anteroposterior view (A), lateral view (B). Vasospasm of the supraclinoid portion of the internal carotid artery and of the proximal segments of the anterior and middle cerebral arteries is clearly shown.



B

facial palsy and with a light monoparesis on the right side in the lower limb. In April 1983 a facial-facial anastomosis was tried.

## Discussion

Vasospasm unrelated to aneurysm rupture or aneurysmal surgery is rare [1,17,27].

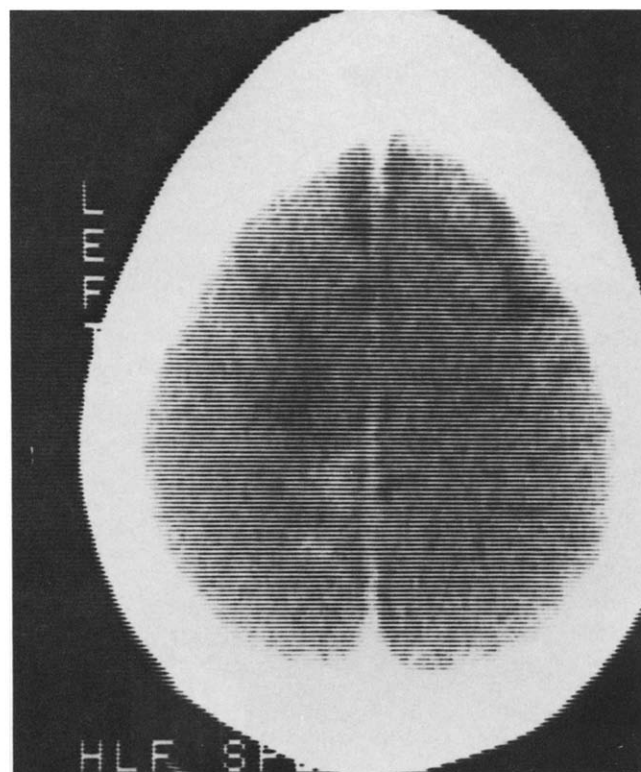
Posttraumatic intracranial artery spasm has been occasionally reported [2,26]. According to Arseni et al [2], the contusion of the arterial inner wall favors the development of spasm and thrombi. In most of the reported cases reopening of the vessels leads to the conclusion that the obstruction was caused by spasm. The persistence of incomplete filling of the arteries suggests an inner wall traumatic lesion [2]. We believe that the role played by the subarachnoid hemorrhage can not be ruled out when direct trauma to the arteries can not be proved.

Vasospasm after removal of a tumor is rare and usually is related to operation on pituitary tumors [4,11,15]. Trauma to the arterial walls can not be ruled out as its cause in those cases. Wilson and Field [29] and Wilkins [23,25] demonstrated a possible relation between hypothalamic dysfunction and vasospasm. Hypothalamic lesions could then also be the cause of vasospasm after removal of pituitary tumors.

Smith et al [21] reported a case of cerebral vasospasm after myelography, "It is uncertain whether the principal cause of this response was Pantopaque, subarachnoid blood, or the combination thereof."

Intracranial arterial spasm unrelated to intracranial bleeding has been reported in episodes of different types of vascular headaches [5,8,14]. This vasospasm can not be correlated with the one due to aneurysmal rupture. Fein [6] reporting on unruptured aneurysms concluded that subarachnoid hemorrhage is a necessary component for the development of clinically significant vasospasm.

**Figure 2.** Computed tomography scan showing an ischemic area with some contrast-medium enhancement.



Recently, vasospasm was detected in a patient with an unruptured and unoperated aneurysm [7].

Reports of major hemorrhage from acoustic neuromas are uncommon [9,16,19,30] and vasospasm was not reported in those cases.

Krayenbühl [13] discussing the dynamics of vasospasm reports briefly on a patient with internal carotid spasm after removal of an acoustic neuroma. The amount of bleeding and the patient's position were not mentioned. The deterioration occurred on the 13th day and the angiogram disclosed the vasospasm. About 20 days later, another angiogram was normal.

It is now widely accepted that subarachnoid blood after rupture of aneurysms plays a major role in the development of vasospasm [20]. However, the substances directly involved in the production of vasospasm [3,18,20,24,31] and the importance of other factors such as trauma to the arterial wall [2,11,26] or hypothalamic injury [23,25,29] are still controversial.

In our case the vasospasm was probably caused by a large amount of blood in the basal cisterns. Angiographically this tumor did not appear hypervascular but the intraoperative bleeding was remarkable. Once the patient was in a left lateral position, we suspect that a large amount of blood accumulated in the basal cisterns, mostly on the left side. In our patient there was no direct trauma to the arterial walls or direct hypothalamic lesion. So, the accumulation of blood around the involved arteries is probably the cause of the vasospasm. The characteristics of the deterioration on the eighth postoperative day correlate with the typical clinical picture of cerebral vasospasm [31]. The angiogram and the computed tomography scan confirmed the presence of spasm and infarction.

## References

- Adams CBT. Vasospasm: occurrence in conditions other than subarachnoid hemorrhage from a bleeding aneurysm. In: Wilkins RH, ed. Cerebral arterial spasm. Baltimore: Williams & Wilkins, 1980:471.
- Arseni C, Maretsis M, Horvath L. Posttraumatic intracranial arterial spasm: report of three cases. *Acta Neurochir (Wien)* 1971;24:25-35.
- Boullin DJ, Tagari P, Du Boulay G, Aitken V, Hughes JT. The role of hemoglobin in the etiology of cerebral vasospasm: an *in vivo* study of baboons. *J Neurosurg* 1983;59:231-6.
- Camp PE, Paxton HD, Buchan GC, Gahbauer H. Vasospasm after transsphenoidal hypophysectomy. *Neurosurgery* 1980;7:382-5.
- Dukes HT, Vieth RG. Cerebral arteriography during migraine prodrome and headache. *Neurology (Minneapolis)* 1964;14:636-9.
- Fein JM. Unruptured aneurysms and cerebral vasospasm. In: Wilkins RH, ed. Cerebral arterial spasm. Baltimore: Williams & Wilkins, 1980:499-504.
- Friedman P, Gass HH, Magidson M. Vasospasm with an unruptured and unoperated aneurysm. *Surg Neurol* 1983;19:21-5.
- Garnic JD, Schellinger D. Arterial spasm as a finding intimately associated with the onset as vascular headache. *Neuroradiology* 1983;24:273-6.
- Gleeson RK, Butzer JF, Grin OO. Acoustic neurinoma presenting as subarachnoid hemorrhage. Case report. *J Neurosurg* 1978;49:602-4.
- Graham DI, Macpherson P, Pitts LH. Correlation between angiographic vasospasm, hematoma and ischemic brain damage following SAH. *J Neurosurg* 1983;59:223-30.
- Hyde-Rowan MD, Roessmann V, Brodkey JS. Vasospasm following transsphenoidal tumor removal associated with the arterial changes of oral contraception. *Surg Neurol* 1983;20:120-4.
- Kapp JP, Neill CL, Hodges LR, Smith RR. The three phases of vasospasm. *Surg Neurol* 1982;18:40-5.
- Krayenbühl H. Beitrag zur Frage des cerebralen angioplastischen Insults. *Schweiz Med Wochenschr* 1960;90:961-5.
- Masuzawa T, Shinoda S, Furuse M, Nakahara N, Abe F, Sato F. Cerebral angiographic changes on serial examination of a patient with migraine. *Neuroradiology* 1983;24:277-81.
- Maw JR, Ausman JI, Erickson OL, Maxwell RE. Vasospasm following transcranial removal of large pituitary adenomas. *J Neurosurg* 1979;50:229-32.
- McCoy K, Barron KD, Cassidy RJ. Acoustic neurinoma presenting as subarachnoid hemorrhage: case report. *J Neurosurg* 1974;41:391-3.
- Peerless SJ. Postoperative cerebral vasospasm without subarachnoid hemorrhage. In: Wilkins RH, ed. Cerebral arterial spasm. Baltimore: Williams & Wilkins, 1980:496-8.
- Schumacker MA, Alksne JF. Mechanisms of whole blood-induced cerebral arterial contraction. *Neurosurgery* 1981;9:275-82.
- Shepherd RH, Cheeks RE. Subarachnoid hemorrhage and acoustic neuroma. *J Neurol Neurosurg Psychiatry* 1981;44:1057.
- Shigeno T. Norepinephrine in cerebrospinal fluid of patients with cerebral vasospasm. *J Neurosurg* 1982;56:344-9.
- Smith RA, Collier HF, Underwood FO. Cerebral vasospasm following myelography. *Surg Neurol* 1973;1:87-90.
- Suzuki J, Yoshimoto T, Onuma T. Early operations for ruptured intracranial aneurysms: study of 31 cases operated on within the first four days after ruptured aneurysm. *Neurol Med Chir (Tokyo)* 1978;18 (Pt 1):83-9.
- Wilkins RH. Hypothalamic dysfunction and intracranial arterial spasm. *Surg Neurol* 1975;4:472-80.
- Wilkins RH. Cerebral arterial spasm. Baltimore: Williams & Wilkins, 1980:699.
- Wilkins RH. The possible role of the hypothalamus in the development of intracranial arterial spasm. In: Wilkins RH, ed. Cerebral arterial spasm. Baltimore: Williams & Wilkins, 1980:266-9.
- Wilkins RH. Trauma-induced cerebral vasospasm. In: Wilkins RH, ed. Cerebral arterial spasm. Baltimore: Williams & Wilkins, 1980:472-5.
- Wilkins RH. Intracranial arterial spasm after procedures other than operations for intracranial aneurysm. In: Wilkins RH, ed. Cerebral arterial spasm. Baltimore: Williams & Wilkins, 1980:505-9.
- Wilkins RH. Attempted prevention or treatment of intracranial arterial spasm: a survey. *Neurosurgery* 1980;6:198-210.
- Wilson JL, Feild JR. The production of intracranial vascular spasm by hypothalamic extract. *J Neurosurg* 1974;40:473-9.
- Yonemitsu T, Niizuma H, Kodama N, Fujiwara S, Suzuki J. Acoustic neurinoma presenting as subarachnoid hemorrhage. *Surg Neurol* 1983;20:125-30.
- Zervas NT. Vasospasm: an update. *Clin Neurosurg* 1979;26:643-56.