

was seen if coma was due to structural damage within the brainstem. Our data do not refute the observation that in cases of acute metabolic coma, the coma itself may produce no short-term brainstem response abnormality. However, our data suggest that a high incidence of brainstem response abnormality may be seen in chronic metabolic imbalance, such as uremia.

Acknowledgments

The authors wish to thank Elizabeth Smith for technical assistance, Richard Clement for preparing the statistical data, and Margaret Geddes and N. Onur for secretarial assistance.

From the Clinical Neurophysiology Unit, University of Aston and Renal Unit, East Birmingham Hospital, Birmingham, UK.

Accepted for publication June 21, 1984.

Address correspondence and reprint requests to Dr. Komsuoğlu, Tıp Fakültesi, Camlik, Trabzon, Turkey.

References

1. Romano J, Engel GL. Delirium. I. Electroencephalographic data. *Arch Neurol Psychiat* 1944;51:356-77.
2. Kiley J, Hines O. Electroencephalographic evaluation of uremia. *Arch Intern Med* 1965;116:67-73.
3. Bourne JR, Ward JW, Teschan PE, Musso M, Johnston HB, Ginn HE. Quantitative assessment of the electroencephalogram in renal disease. *Electroencephalogr Clin Neurophysiol* 1975;39:305-448.
4. Hughes JR, Roxe DM, del Greco F, et al. Electrophysiological studies of uremic patients: comparison of peritoneal dialysis and hemodialysis. *Clin Electroencephalogr* 1980;11:72-82.
5. Lewis EG, Dustman RE, Beck EC. Visual and somatosensory evoked potential characteristics of patients undergoing hemodialysis and kidney transplantation. *Electroencephalogr Clin Neurophysiol* 1978;44:223-31.
6. Hamel B, Bourne JR, Ward JW, Teschan PE. Visually evoked cortical potentials in renal failure: transient potentials. *Electroencephalogr Clin Neurophysiol* 1978;44:606-16.
7. Picton T, Hillyard SA, Galambos R. The effects of attention on the auditory evoked potential. In: Keidel WD, Neff WD, eds. *Handbook of sensory physiology*, vol 3. New York: Springer 1976:343-90.
8. Davis H. Sedation of young children for electric response audiometry (ERA): summary of a symposium. *Audiology* 1973;12:55-7.
9. Knoll O, Harbort U, Schulte K, Zimpel F, Losse L. A neurophysiological bedside technique for monitoring uremic brain dysfunction. *Proc Eur Dial Transplant Assoc* 1980;17:714-8.
10. Amadeo M, Shagass C. Brief latency click evoked potentials during waking and sleeping in man. *Psychophysiology* 1973;10:244-50.
11. Jewett D. Volume-conducted potentials in response to auditory stimuli as detected by averaging in the cat. *Electroencephalogr Clin Neurophysiol* 1970;28:609-18.
12. Bolton CF. Electrophysiological changes in uremic neuropathy after successful renal transplantation. *Neurology (Minneapolis)* 1976;26:152-61.
13. Ibrahim MM, Barnes AD, Crosland JM, et al. Effect of renal transplantation on uremic neuropathy. *Lancet* 1974;2:739-42.
14. Olsen S. The brain in uremia. *Acta Psychiatr Neurol Scand [Suppl]* 1961;156:36.
15. Mendel MI, Goldstein R. Stability of the early components of the averaged encephalographic response. *J Speech Res* 1969;12:351-61.
16. Kiang N Y-S, Crist AH, French MA, Edwards AG. Postauricular electrical response to acoustic stimuli in humans. *Quarterly Progress Report, MIT* 1963;2:218-25.
17. Starr A, Achon JL. Auditory brainstem responses in neurological disease. *Arch Neurol* 1975;32:761-8.

"Apraxia" of eyelid opening: An involuntary levator inhibition

Article abstract—Apraxia of lid opening was described by Goldstein and Cogan as "a non paralytic motor abnormality characterized by the patient's difficulty in initiating the act of lid elevation."¹ We studied six such patients with this finding accompanied by vigorous frontalis contraction and no evidence of ongoing orbicularis oculi contraction, dysfunction of the oculomotor nerve, or loss of ocular sympathetic innervation. Four patients had Parkinson's disease or atypical parkinsonism, one had progressive supranuclear palsy, and one had Shy-Drager syndrome. At onset of ocular symptoms, mean age was 64 years, and the mean duration of extrapyramidal symptoms was 9.7 years. By definition, the motor system must be intact in any apraxia. Therefore, this disorder of lid opening in patients with extrapyramidal motor dysfunction is not an apraxia, but rather involuntary levator palpebrae inhibition of supranuclear origin.

NEUROLOGY 1985;35:423-427

Frederick E. Lepore and Roger C. Duvoisin

Disruption of supranuclear control of the levator palpebrae and orbicularis oculi can make it impossible for a person to open the eyes. The most common supranuclear disorder of eye opening is essential blepharospasm, seen alone or with contraction of other facial muscles in the Meige syndrome.¹ Bilateral "cerebral" ptosis, with no in-

volvement of sympathetic or oculomotor nerve pathways, can hamper eye opening after unilateral or bilateral hemisphere infarction.² Also, Cogan and Goldstein¹ drew attention to apraxia of lid opening: "a non paralytic motor abnormality characterized by the patient's difficulty in initiating the act of lid elevation." They found only three reported cases to

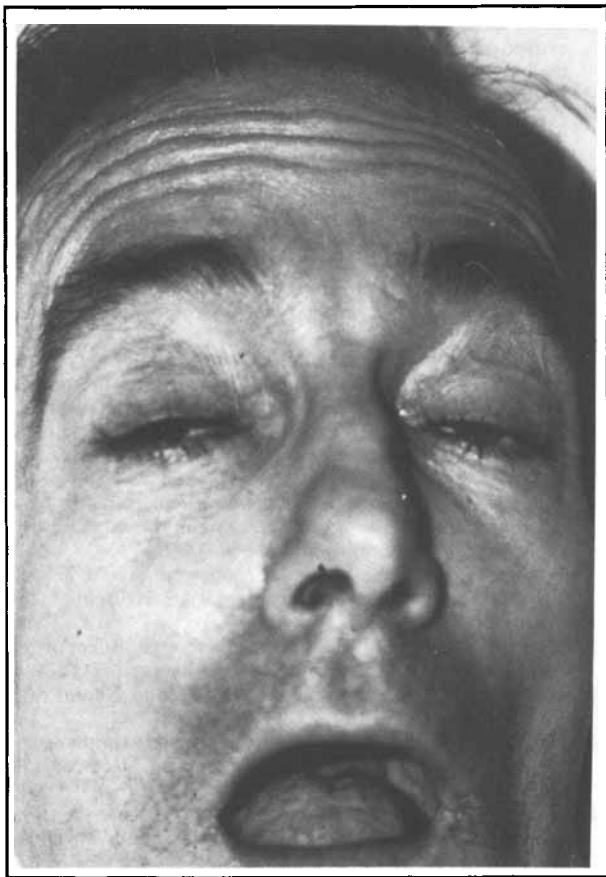


Figure 1. Patient is unable to fully open his eyes despite marked frontalis contraction. Note associated opening of mouth.

supplement four of their own.

We have studied six patients with the following combination: (1) transitory inability to initiate lid opening; (2) no evidence of ongoing orbicularis oculi contraction, such as lowering of the brows beneath the superior orbital margins (Charcot's eyebrow sign of blepharospasm)⁴; (3) vigorous frontalis contraction during periods of inability to raise eyelids; and (4) no oculomotor or ocular sympathetic nerve dysfunction and no ocular myopathy.

Case reports. Patient 1. For 10 years, a 59-year-old man had been treated for Parkinson's disease. He had taken carbidopa-levodopa with benefit for 6 years, followed by recurrence of bradykinesia. For the last 2 years, he had noted an increasingly frequent inability to open his eyes.

Examination revealed an alert and cooperative bedridden man with marked bradykinesia and resting tremor. Confrontation fields were full. Ocular ductions were full, and orthophoria was present. There were no abnormalities of fixation, saccades, pursuit movements, suppression of the vestibulo-ocular reflex, or optokinetic nystagmus. There was no spontaneous nystagmus. Pupils were 3.5 mm and reacted to light. Convergence was poor. After eye closure, he could not open his eyes for 20 to 30 seconds. Despite marked frontalis contraction with eyebrows well

above the superior orbital rim, the eyes would remain closed until the upper lids slowly elevated. At times, the patient opened his mouth to facilitate eye opening (figure 1).

Comment. When unable to open his eyes despite vigorous frontalis contraction, the patient would open his mouth. This strategy had been noted by Goldstein and Cogan,³ and it has been stated that "increased levator tonus may normally accompany wide opening of the mouth."⁵

Patient 2. This 51-year-old man had progressive slowness of bodily movement for 7 years with loss of finger dexterity, retropulsion, difficulty focusing his eyes, dysphagia, and dysarthria.

Examination disclosed a slow, broad-based gait. Rapid alternating movements were performed slowly, and intention tremor was present. Tendon jerks were active and symmetric. His head was flexed, and he spoke in a slow, soft monotone. Horizontal versions of the eyes were full, but there was limited vertical excursion that improved when the vestibulo-ocular reflex or Bell's phenomenon was elicited. Saccades were slow, pursuit movements were intact, and fixation was normal. End-point nystagmus was present symmetrically, and there was faulty suppression of the vestibulo-ocular reflex. Pupils were equal and reacted to light. The fundi were normal. Spontaneous blinking was decreased. After voluntary eye closure, his eyes remained closed for seconds despite vigorous frontalis movements and no apparent orbicularis oculi contraction.

Comment. The combination of progressive supranuclear palsy (PSP) and apraxia of eye opening in this patient was also reported in three of eight patients with PSP by Dehaene.⁶ Some of the sporadic eye-opening difficulty could be due to the constant loss of voluntary upward gaze, preventing the increased levator tone normally associated with contraction of the superior rectus muscle.³

Patient 3. A 64-year-old man was seen after 25 years of atypical parkinsonism and violent behavior. Although previously treated with haloperidol and thiothixene, his bradykinesia and gait disorder persisted despite treatment with carbidopa-levodopa exclusively.

He was dysarthric and had impassive facies. Bradykinesia and cogwheeling tone were present without resting tremor. Gait was narrow based, but there was retropulsion. Posture was erect. Intention tremor was present, and infrequent myoclonic movements of the arms were noted. Tendon jerks were diminished, and there were bilateral Babinski responses. Ocular movements were full with normal saccades and jerky pursuit movements. There was no spontaneous nystagmus, and fixation was normal. There was abnormal suppression of the vestibulo-ocular reflex. On voluntarily closing his eyes, the patient would sporadically be unable to open them despite vigorous frontalis contractions (figure 2). Prolonged upward gaze would induce a slow descent of the globes and upper lids, followed by a period of inability to open his eyes. Edrophonium did not alter the duration or frequency of these episodes.

Comment. Although this patient with atypical parkinsonism was intermittently unable to open his eyes after volitional eye closure, upward gaze was invariably followed by transient immobility of the levator. As in patient 2, a supranuclear vertical gaze disturbance was associated with levator dysfunction.

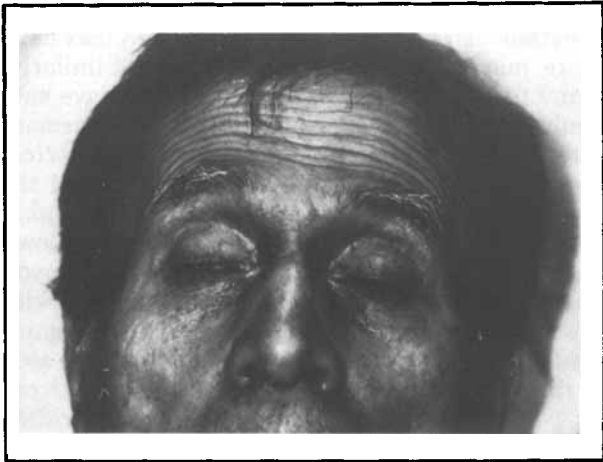

Figure 2. Intermittent inability to raise eyelids is induced in this patient after looking upward.

Patient 4. This man, at age 60, noted onset of gait difficulties and slowing of movements. A year later, he became impotent, and his blood pressure was low. Because of urinary incontinence, a suprapubic catheter was used. His gait gradually deteriorated, and he began having syncopal episodes; orthostatic hypotension was documented. At age 67, he was confined to bed and chair. Medications included carbidopa-levodopa and benzotropine mesylate.

Examination disclosed severe rigidity, bradykinesia, and low dysarthric speech. Reflexes were normal. There was no tremor. Ocular movements were full with normal saccades and no nystagmus. Pupils were 3.5 mm and sluggishly reactive. After eye closure, he could not voluntarily open his eyes. CT showed dilation of the third and fourth ventricles, enlargement of the prepontine and perimesencephalic cisterns, and prominent cerebellar folia and mild cerebral cortical atrophy.

Comment. This patient had apraxia of eyelid opening and Shy-Drager syndrome. Although atrophy on CT was not exclusively restricted to the rostral brainstem, this region was implicated in another supranuclear disorder of eye opening, blepharospasm.⁷

Patient 5. A 59-year-old man became mildly ataxic after a left lateral medullary infarct. He recovered with minimal residual deficits, but 3 years later began to fall frequently. At age 63, he had immobile facies, cogwheel rigidity, and shuffling gait. He has had sporadic difficulty opening his eyes after they have closed involuntarily in bright light. At times, he could open his eyes only by prying the lids apart with his fingers. No improvement of mobility or eye opening was noted with carbidopa-levodopa.

Examination revealed a severely impaired gait and retropulsion. Succession movements were slowed, and there was only minimal tremor of the hands. Tendon reflexes were normal. The optic disks were normal. Voluntary upward gaze was reduced, and upward excursion increased with oculocephalic testing. Fixation, pursuit movements, and saccades were normal. Mild blepharochalasis was present on the left. The patient was intermittently unable to raise his eyelids despite contraction of the frontalis (figure 3). Convergence was poor, and the glabellar reflex was persistent. There was abnormal suppression of the vestibulo-ocular reflex. CT showed mild

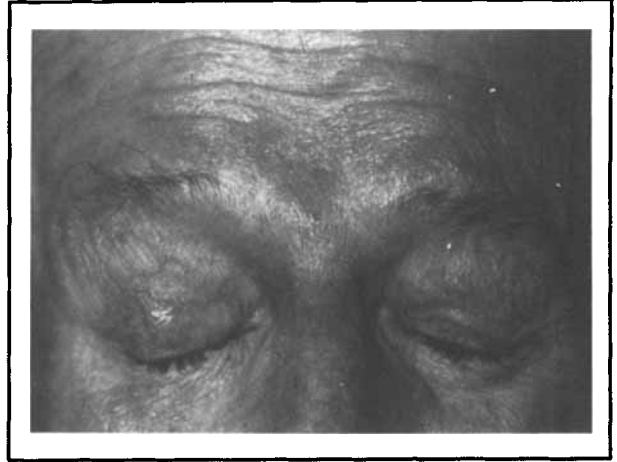

Figure 3. Prominent frontalis contraction will not open eyes of this patient with transient bilateral levator inhibition and blepharochalasis OS.

dilation of the third ventricle, prominence of the perimesencephalic cisterns, and calcification of the basal ganglia.

Comment. A supranuclear disorder of both upward gaze and eye opening was seen in this patient with atypical parkinsonism and lateral medullary infarction. CT revealed rostral brainstem atrophy, less severe than in patient 4.

Patient 6. For 5 years, this 80-year-old woman had impaired movement of the right arm. The movements became slower, and she had difficulty cooking and dressing, despite treatment with carbidopa-levodopa. For 2 years, she had sporadic inability to open her eyes.

Examination revealed a fixed smile and soft dysarthric speech. Her gait was broad based with short steps and decreased arm swing. There was no tremor, but marked rigidity of the neck was present. The tendon jerks were symmetric, and plantar responses were flexor. A glabellar sign was present. The optic fundi appeared normal. Ocular movements were full with normal saccades, but pursuit movements were jerky. Small-amplitude nystagmus was seen at the extremes of lateral gaze, and fixation could not be maintained for more than 10 seconds. Bell's phenomenon was absent. The pupils were 4.5 mm OD and 5.0 mm with an oval shape on the left. The pupils did not react to light but did constrict after instillation of 1% pilocarpine hydrochloride. Sporadic contractions of the orbicularis oculi were much greater on the right. When she attempted to open her eyes, the right orbicularis oculi showed sustained contraction while the left eye remained closed, despite relaxation of the orbicularis and ongoing contraction of the frontalis muscles (figure 4). CT was normal.

Comment. This patient with atypical parkinsonism demonstrated a striking transition from bilateral blepharospasm to right-sided blepharospasm and apraxia of eyelid opening on the left. Although this patient did not strictly meet our criteria for apraxia of eyelid opening because there was still blepharospasm, she demonstrated that these two signs may coexist.

Discussion. These six patients with a distinctive disorder of eyelid opening had extrapyramidal disease that required treatment with carbidopa-

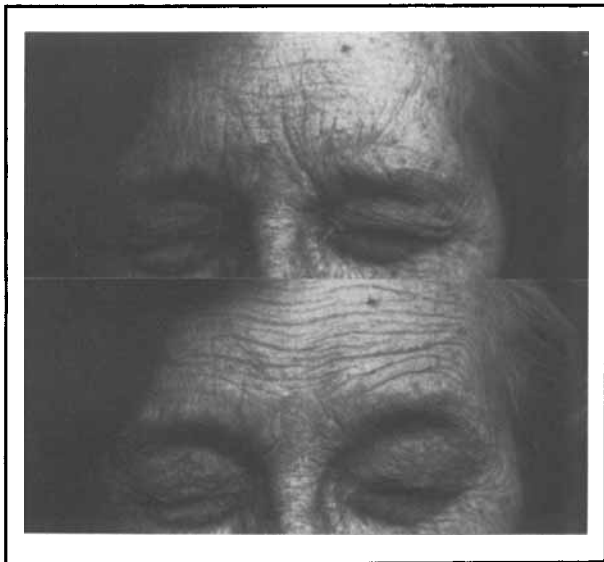

Figure 4. Top frame: bilateral involuntary orbicularis contraction is succeeded by (bottom frame) persistent orbicularis contraction OD and inability to open OS despite relaxation of orbicularis and frontalis contraction on the left.

levodopa or anticholinergic medication. One patient had Parkinson's disease; three had atypical parkinsonism (probably representing multiple system atrophy); one had progressive supranuclear palsy, and one had Shy-Drager syndrome. Goldstein and Cogan's four patients also had evidence of extrapyramidal disease.³ Although only one of their patients had supranuclear limitation of eye movements, three of our six patients had supranuclear vertical gaze palsies. At the onset of ocular symptoms, our patients' mean age was 64 years, and the mean duration of extrapyramidal symptoms was 9.7 years.

Although Goldstein and Cogan adhered to terminology of an older literature⁸ to designate "apraxia" of lid opening, "apraxia" may be an inaccurate term. Heilman and Valenstein⁹ stress that although "basal ganglia disease may interfere with the performance of skilled movements, the resulting abnormalities of movement are not considered to be apraxia." The extrapyramidal diseases in our patients disqualify their eye-opening disorders from consideration as an apraxia because the motor system was not intact. Additionally, none of our patients had evidence of buccolingual or facial apraxia, and patients with facial apraxia do not typically manifest disorders of eye opening.¹⁰ Wray regarded this disorder as an "akinesia of lid function,"¹⁰ but since these patients have a specific and transient inability to contract the levator palpebrae, it would be more accurate to consider the disorder an involuntary levator palpebrae inhibition of supranuclear origin.

How parkinsonism disrupts supranuclear control of eye opening requires elucidation. Although par-

kinsonian patients have mild supranuclear disorders of extraocular motility,¹¹ infrequently they may have more marked ocular motor deficits.¹² Similarly, many patients with Parkinson's disease have subclinical dysfunction of levator inhibition, as demonstrated by the prolonged period of electrical inactivity between the orbicularis twitch and the levator contraction at the end of a voluntary blink.¹³ This dysfunction may be augmented for unknown reasons until it becomes clinically apparent as involuntary levator inhibition. The association of Parkinson's disease and disorders of eye opening gains credence because apraxia of eyelid opening was seen in three of four patients with parkinsonism induced by 1-methyl-4 phenyl-1,2,5,6-tetrahydropyridine (MPTP)—a substance causing neuronal destruction and Lewy body production in the human substantia nigra.¹⁴

Are there any common elements in involuntary levator inhibition and the other supranuclear disorders of eye opening? Our patient 6 simultaneously exhibited blepharospasm and apraxia of eyelid opening. Although this simultaneous occurrence is uncommon, the sequence of these two clinical signs was described in essential blepharospasm by Boghen¹⁵: "There may be difficulty with lid opening even after active contraction of the orbicularis muscle has ceased." Additionally, facial nerve section for blepharospasm may be followed by complete paralysis of the orbicularis oculi, yet the eyelids remain closed.¹⁶ Although focal contraction of the pretarsal portion of the orbicularis oculi might mimic levator dysfunction, it appears more likely that there is frequently a component of involuntary levator inhibition in patients with essential blepharospasm. Although blepharospasm and involuntary levator inhibition are both marked by sporadic eyelid closure, the former can be distinguished by eyebrows lowered beneath superior orbital margins by contraction of the pretarsal, preseptal, and orbital fibers of the orbicularis oculi, whereas the latter consists of eyebrows elevated by frontalis action and no contraction of orbicularis. In contrast to the phasic episodes of involuntary levator inhibition in our patients, or in association with blepharospasm, continuous inhibition might account for persistent "cerebral ptosis" with difficulty initiating lid elevation seen with cortical disease.¹⁷

The neuroanatomic basis of apraxia of eyelid opening remains to be clarified. Nashold and Gills¹⁸ reported sporadic loss of volitional eye opening in a patient with a stereotactically placed thermal lesion of the prerubral fields of Forel H and red nucleus. It is uncertain whether this eyelid disorder was due to the lesion placed 3 months earlier or simply part of the progression of the involuntary movement disorder. Although rubral or prerubral involvement is not specifically demonstrable, two of our patients had rostral brainstem atrophy on CT. Since both corticobulbar and extrapyramidal systems control

tonus of the levator palpebrae,⁵ we presume that the extrapyramidal component was disrupted in our patients. Similarly, blepharospasm is often seen in parkinsonism (especially postencephalitic), and extrapyramidal dysfunction may be a factor in this possibly related supranuclear disorder of lid opening. However, supranuclear control of eyelid opening can be compromised by pyramidal motor-system disease, as demonstrated in cases of cerebral ptosis with no evidence of basal ganglia disease.^{2,17} Further study is needed to determine the circumstances in which a levator subnucleus deprived of corticobulbar or extrapyramidal input causes the signs of involuntary levator inhibition.

From the Department of Neurology, University of Medicine and Dentistry of New Jersey, Rutgers Medical School-Academic Health Science Center, New Brunswick, NJ.

Accepted for publication June 21, 1984.

Address correspondence and reprint requests to Dr. Lepore, University of Medicine and Dentistry of New Jersey, Rutgers Medical School-Academic Health Science Center, Department of Neurology, CN19, New Brunswick, NJ 08903.

References

1. Meige H. Les convulsions de la face, une forme clinique de convulsion faciale, bilaterale et médiane. *Rev Neurol (Paris)* 1910;10:437-43.
2. Caplan LR. Ptosis. *J Neurol Neurosurg Psychiatry* 1974;37:1-7.
3. Goldstein JE, Cogan DG. Apraxia of lid-opening. *Arch Ophthalmol* 1965;73:155-9.
4. Kestenbaum A. Clinical methods of neuro-ophthalmologic examination. New York: Grune and Stratton, 1947.
5. Walsh FB, Hoyt WF. Clinical neuro-ophthalmology, 3rd ed. Baltimore: William and Wilkins, 1969.
6. Dehaene I. Apraxia of eyelid-opening in progressive supranuclear palsy. *Ann Neurol* 1984;15:115-6.
7. Jankovic J, Havins WE, Wilkins RB. Blinking and blepharospasm: mechanisms, diagnosis and management. *JAMA* 1982;243:3160-4.
8. Riese W. Apraxie der lidöffnung (analyse einer bewegungsstörung). *J Psychol Neurol Lpz* 1930;40:347-55.
9. Heilman KM, Valenstein E, eds. Clinical neuropsychology. New York: Oxford University Press, 1979.
10. Case records of the Massachusetts General Hospital: case 32-1975. *N Engl J Med* 1975;293:346-52.
11. White OB, Saint-Cyr JA, Tomlinson RD, Sharpe JA. Ocular motor deficits in Parkinson's disease. II. Control of the saccadic and smooth pursuit systems. *Brain* 1983;106:571-88.
12. Guilloff RJ, George RJ, Marsden CD. Reversible supranuclear ophthalmoplegia with parkinsonism. *J Neurol Neurosurg Psychiatry* 1980;43:552-4.
13. Loeffler JD, Slatt B, Hoyt WF. Motor abnormalities of the eyelids in Parkinson's disease. *Arch Ophthalmol* 1966;76:178-85.
14. Langston JW, Ballard P, Tetrud JW, Irwin I. Chronic parkinsonism in humans due to a product of meperidine analog synthesis. *Science* 1983;249:979-80.
15. Boghen D. Involuntary movements of the face. American Academy of Neurology course, Toronto, April 1981.
16. Trobe JD. Blepharospasm. In: Ernest JT, ed. The year book of ophthalmology 1982. Chicago: Year Book Medical Publishers, 1982.
17. Nutt JG. Lid abnormalities secondary to cerebral hemisphere lesions. *Ann Neurol* 1977;1:149-51.
18. Nashold BS, Gills JP. Ocular signs from brain stimulation and lesions. *Arch Ophthalmol* 1967;77:609-18.

Accidental hypothermia in a healthy quadriplegic patient

Article abstract—An otherwise healthy 28-year-old quadriplegic patient was admitted to the hospital with a core temperature of 76 °F secondary to accidental hypothermia. Her neurologic disability was detrimental to thermoregulation by decreasing her ability to shiver actively and to vasoconstrict. The relationship between shivering and thermoregulation is discussed.

NEUROLOGY 1985;35:427-428

Philip Altus, MD; Jack W. Hickman, MD; and H. Juergen Nord, MD

In **accidental hypothermia**, body core temperature falls below 94 °F (34.4 °C) after exposure to environmental cold. Most are elderly victims, who are susceptible and vulnerable to the fatal effects of hypothermia because they cannot shiver actively. In usually warm climates, poorly insulated housing and unexpected cold weather may be hazardous. We recently cared for a young quadriplegic patient who suffered from accidental hypothermia.

In April 1983, this 28-year-old woman suffered a C-4 fracture in a motor vehicle accident and was left quadriplegic. She remained at home in Florida at-

tended by her grandmother. On the day before admission, her home heater malfunctioned when Tampa's low temperature was -7.2 °C. On the day of admission, a visiting health nurse found her confused, disoriented, hypotensive, and bradycardic. On admission, her rectal temperature was 24.4 °C, pulse was 30 beats per minute and regular, and blood pressure was 110/80 mm Hg. Examination showed clear lung fields, quadriplegia, and decubitus ulcers on her right calcaneus and left malleolus. She was disoriented but awake.

Laboratory values included a hemoglobin of 16.7

Neurology®

"Apraxia" of eyelid opening: An involuntary levator inhibition

Frederick E. Lepore and Roger C. Duvoisin

Neurology 1985;35:423

DOI 10.1212/WNL.35.3.423

This information is current as of March 1, 1985

Updated Information & Services

including high resolution figures, can be found at:
<http://www.neurology.org/content/35/3/423.full.html>

Citations

This article has been cited by 6 HighWire-hosted articles:
<http://www.neurology.org/content/35/3/423.full.html##otherarticles>

Permissions & Licensing

Information about reproducing this article in parts (figures, tables) or in its entirety can be found online at:
<http://www.neurology.org/misc/about.xhtml#permissions>

Reprints

Information about ordering reprints can be found online:
<http://www.neurology.org/misc/addir.xhtml#reprintsus>

Neurology® is the official journal of the American Academy of Neurology. Published continuously since 1951, it is now a weekly with 48 issues per year. Copyright © 1985 by Modern Medicine Publications, Inc.. All rights reserved. Print ISSN: 0028-3878. Online ISSN: 1526-632X.

