

Unusual features in a case of bilateral paramedian thalamic infarction

Sir: Bilateral paramedian thalamic infarction is a rare or at least rarely recognized cause of amnesia with abrupt onset. In a recent review of the literature 13 cases were reported.¹ The clinical picture consists of transient coma, amnesia, apathy and vertical gaze disturbance. A similar case, but with lack of impairment of consciousness and positive CSF findings as additional features, is presented.

A 59-year-old, right-handed, high-school educated clerk was admitted in what appeared to be a confusional state. On that morning he awoke normally but neglected to go to work, mistakingly regarding the day as Saturday. Later he left home with his daughter with the intention of going fishing but seemed not to know what to do. He wandered aimlessly for more than two hours and was, finally, brought to the hospital. On admission the patient's general condition was good. His blood pressure was 140/80 mmHg. He was alert but displayed apathy with expressionless facies and was unaware of any problem. Speech appeared to be normal but was usually limited to brief answers to questioning. The prominent feature was severe memory disturbance concerning current events and, to a lesser degree, recent events. Recollection of previous material was less affected. He could read and write and was able to perform calculations but gave the date and day of the week incorrectly and had difficulty in finding his bed in the ward. The rest of the neurological examination was normal, apart from a slight limitation of upward gaze.

The E.E.G. on the day of admission was normal, apart from mild slow waves with left temporal prevalence during hyperventilation. A second E.E.G. ten days later was normal. The CSF examination showed normal pressure and sugar, O cells and 166 mg% protein. A CT scan, two days after his admission, showed round hypodense areas in both medial thalami. The hypodense area in right thalamus was more extensive and showed luxury perfusion enhancement (fig (a)). Psychological testing 1 week after admission, on the Wechsler Adult Intelligence Scale (WAIS) showed that his verbal IQ was 97 and his performance IQ 85. He had low scores in subtests that primarily assess immediate verbal memory, visual-motor coordination and ability for synthesis and analysis in

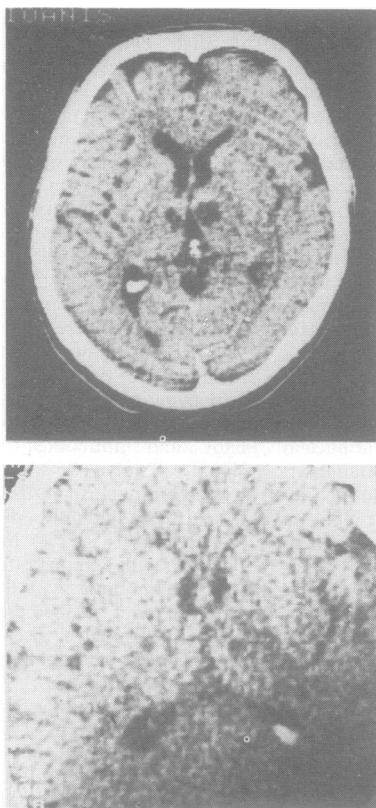


Fig (a) Brain CT scan showing hypodense areas in both thalamic areas. (b) CT scan 3 months later showing smaller hypodense areas.

space, namely digit span, digit symbol and block design. Furthermore his performance in Benton visual retention test was poor. The CT scan was repeated, 3 months later. The hypodense areas were now smaller, with no alteration after enhancement (fig (b)). The patient's condition remained unaltered during the following year.

Memory disturbance can be the result of a focal brain damage.² Isolated lesions of the medial thalami can be responsible, the lesion being unilateral³⁻⁵ or bilateral.¹ The question of whether unilateral, non-dominant thalamic lesions can produce amnesia remains open.⁵ Vascular lesions of both paramedian thalamic areas are possible owing to the fact that, occasionally, both paramedian thalamic areas are supplied by a solitary anterior thalamosubthalamic paramedian artery, the latter being a branch of the posterior cerebral

artery on one side.⁶ Typical features of bilateral paramedian thalamic infarction are amnesia with, transient coma and vertical gaze disturbance.¹ The disturbance of consciousness is attributed to bilateral lesions in the intralaminar nuclei that are part of the rostral extension of the mid-brain reticular activating system.¹ In cases of unilateral thalamic lesions no such disturbance has been reported.⁴⁻⁵ Our case seems to be unique in that a bilateral thalamic lesion was not followed by consciousness disturbance. The elevated protein in the CSF of our patient is an additional distinctive feature. This elevation could be explained as the result of an extension of the infarct to the system of perforating branches of the posterior cerebral artery. This system often supplies in part the choroid plexuses of the 3d ventricle and the thalamosubthalamic paramedian artery is one of its branches.⁶

G KARABELAS
N KALFAKIS
I KASVIKIS
D VASSILOPOULOS

Department of Neurology,
of Athens National University,
Eginition Hospital,
72 Vass. Sofias Ave, Athens,
Greece

References

- Guberman A, Stuss D. The syndrome of paramedian thalamic infarction. *Neurology (NY)* 1983;33:540-6.
- Horel J. The neuroanatomy of amnesia Critique of the hippocampal memory hypothesis. *Brain* 1978;101:403-45.
- Squire LR, Moore RY. Dorsal thalamic lesion in a noted case of human memory dysfunction. *Ann Neurol* 1979;6:503-6.
- Michel D, Laurent B, Foyatier N, Blanc A, Portafax M. Infarctus thalamique paramedian gauche. Etude de la memoire et du langage. *Rev Neurol (Paris)* 1982;138:533-50.
- Choi D, Sudarsky L, Schachter S, Biber M, Burke P. Medial thalamic hemorrhage with amnesia. *Arch Neurol* 1983;40:611-3.
- Percheron G. Les arteres du thalamus humain: II Arteres et territoires thalamiques paramedians de l'artere basilaire communicante. *Rev Neurol (Paris)* 1976;132:309-24.

Accepted 21 July 1984