

Microsurgical Excision of Paraventricular Arteriovenous Malformations

Hoi Sang U, M.D.

University of California Medical Center, San Diego, California

Periventricular arteriovenous malformations (AVMs) have often been deemed inoperable because of their location in critical structures. Furthermore, the excision of large lesions may be complicated by the potential for serious brain swelling and hemorrhage due to "autoregulation breakthrough." Nonetheless, the unfavorable natural history of the untreated disease in a symptomatic young patient has induced us to approach these lesions using staged microsurgical excision combined with elective barbiturate coma for maximal cerebral protection. Between 1979 and 1983, six patients (four female, aged 12 to 60 years, and 2 male, aged 14 and 29) who harbored large AVMs in the basal ganglia, thalamic, and hypothalamic areas presented with subarachnoid hemorrhage (2 cases), progressive neural deficits (3 cases), and intractable headache (1 case). Nineteen staged operations were performed for the complete excision of these lesions. Among the first three patients, there was one death due to "autoregulation breakthrough" hemorrhage into the lateral ventricle during the excision of a lesion approached through the sylvian fissure using standard anesthesia techniques. This led to the adoption of the transventricular surgical approach and elective barbiturate coma to facilitate exposure of the lesion and to protect the adjacent vital structures from potential ischemia. Three patients were treated in this fashion uneventfully. Of the five successfully treated patients, two have returned to their preoperative status and one has completely recovered from global hemispheric ischemia and hemiplegia. The hemiparesis in one patient worsened as a result of postoperative hypertensive intraventricular hemorrhage, and one patient developed mild dysphasia and hemiparesis. This experience suggests that this approach offers a valid therapeutic regimen for the treatment of this disease. During the same period, three patients—one man (age 23) and two women (aged 29 and 22)—harboring four intraventricular AVMs presented with intraventricular hemorrhage. After the acute effects of chemical ventriculitis and hydrocephalus were overcome with cerebrospinal fluid diversion, all four lesions were excised microsurgically using the transtemporal approach. One patient demonstrated significant and progressive improvement of her preoperative memory deficit. The remaining two patients have both returned to their preoperative employment. Homonymous visual defects in two patients were transient, and seizure activity developing after operation was easily controlled medically. This experience confirms that intraventricular AVMs can be excised with minimal morbidity and should be treated aggressively in the symptomatic young patient. (*Neurosurgery* 16:293-303, 1985)

Key words: Barbiturate coma, Basal ganglia, Intraventricular arteriovenous malformation, Microsurgical excision

Arteriovenous malformations (AVMs) located in functionally critical areas of the brain remain one of the most difficult therapeutic challenges in neurosurgery. Operation for the excision of lesions located in the motor or speech area carries the risks of paralysis and/or aphasia (11, 34). Complications in the excision of extensive paraventricular lesions may threaten the basal nuclei and thus the very survival of the patient. These latter AVMs have therefore frequently been deemed inoperable (12). Yet, when the natural history of these lesions is considered, the prognosis for a symptomatic young patient is not favorable (4, 5, 8, 14, 17, 18, 22-25, 31, 32). Up to 50% of the symptomatic patients will die from or be impaired by the AVM during their lifetime. With this in mind, we have taken an aggressive approach to the treatment of basal ganglia AVMs.

The surgical approach to AVMs located in paraventricular regions poses certain characteristic problems (1-3, 6, 10, 12, 13, 21, 27, 28, 30, 33, 35). Because of their location, hemorrhage is often directed into the ventricular system (26). Local parenchymal compressions may lead to focal neurological deficits. More frequently, however, intraventricular hematomas obstruct cerebrospinal fluid (CSF) circulation and produce chemical ventriculitis. CSF drainage is therefore necessary. The periventricular location of these lesions also frequently necessitates a transventricular approach for their surgical excision (4). Cerebral retraction to ensure adequate exposure may be severe, leading to troublesome postoperative brain swelling. In addition, intraoperative hemorrhages must

be meticulously controlled to prevent any insidious intraventricular bleeding. Last, manipulation of basal paraventricular nuclei can be associated with acute vasodilation (9, 20) and resultant massive cerebral swelling or hemorrhage. Such occurrences carry a significant mortality rate. Immediate reduction of intracranial blood flow is imperative to ensure survival and to prevent catastrophic neurological deficits (15, 16).

BASAL GANGLIA AVMs

Between 1979 and 1983, six patients harboring extensive basal ganglia AVMs were treated by staged surgical excision. The indications for operation were intracranial hemorrhage, progressive neurological deficits, and intractable headache. Each patient was evaluated with three-vessel angiography and axial, coronal, and sagittal computed tomographic (CT) scanning before each procedure and after the final operation.

Case 1

[This case has been reported previously (3) and is summarized briefly.]

A 30-year-old woman had a 12-year history of complex partial seizures accompanied by focal seizures of the left arm. Angiographic examination disclosed a right basal ganglia AVM (Fig. 1, A and B). An episode of severe headache suggestive of hemorrhage occurred 6 months before admission. The onset of progressive left-sided hemiparesis precipi-

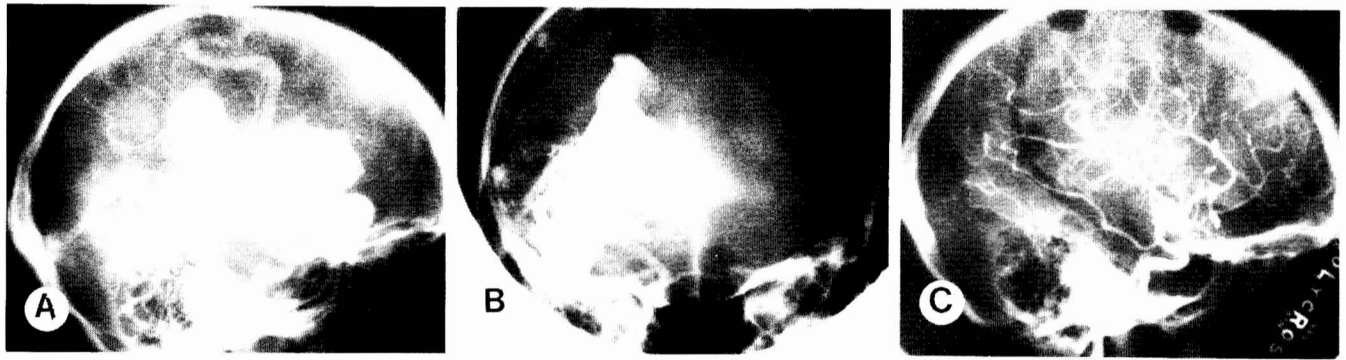


FIG. 1. Case 1. Right internal carotid angiogram shows the lateral (A) and anteroposterior (AP) (B) projections of the AVM. The large amount of arteriovenous (AV) shunting probably led to the formation of the large venous aneurysm and the paucity of opacification of the cerebral vessels. C, postoperative angiogram shows complete AVM excision.

tated her admission in November 1979. Increasing lethargy, nausea, vomiting, and left hemiplegia soon followed. A radiographic work-up disclosed no interval enlargement of the AVM or intracranial hemorrhage. Her symptoms were attributed to progressive vascular shunting.

The patient was immediately alert and oriented after the first operation through the right sylvian fissure, during which the lateral aspect of the AVM was isolated from the surrounding brain. Her sensorium returned to normal, but hemiplegia persisted. After the second operation using the same approach with complete excision (Fig. 1C), she became neurologically intact with the aid of intense rehabilitation. Her seizures have been adequately controlled with medication during the last 4½ years.

Case 2

A 14-year-old boy presented with a history of 4 years of severe, intractable pulsatile headache that was frequently associated with transient left homonymous hemianopia. The incapacitating nature of the headache had necessitated multiple hospitalizations that significantly disrupted his daily life. Increased frequency of these attacks led to angiographic examination that demonstrated a giant AVM involving most of the right temporal, occipital, and parietal lobe, as well as the basal ganglia (Fig. 2). The two distinct components of the malformation were fed by the anterior and posterior circulations, respectively.

Initial therapy included embolization with cyanoacrylic glue, which occluded only a small portion of the malformation. The decision was therefore made to excise the lesion in multiple stages. During the first procedure, multiple clusters of abnormal vessels were excised in the anterior temporal region. During the second stage, feeding arteries entering the malformation from the incisura were occluded. Part of the lesion was also isolated from the surrounding brain. Both procedures were uneventful. During the third operation, however, progressive occlusion of feeder vessels led to vigorous pulsation of the brain. This necessitated termination of the procedure.

During the fourth stage of the excision, most of the malformation was excised, but a persistent left supraquadransia developed. A final angiographic examination demonstrated two small nests of AVM—one anteriorly in the midtemporal region and one at the occipital pole fed by one large artery. The anterior component was removed without difficulty during a fifth procedure. However, approximately 30 minutes after removal of the occipital lesion, the perioccipital cerebral substance started to pulsate vigorously. This was soon followed by acute swelling and multiple hemorrhages at sites

distant from the AVM bed. The brain herniated through the craniotomy defect. Mannitol and the intravenous infusion of thiopental were necessary for brain relaxation and closure of the wound. An immediate postoperative CT scan demonstrated an intraoccipital hematoma. No attempt was made to evacuate the hematoma because the intracranial pressure (ICP) was controlled adequately with medical treatment.

Barbiturate coma was maintained with pentobarbital for 7 days. Full neurological recovery with the exception of a left homonymous visual field defect was attained after 1 month despite an initial transient left hemiparesis. The patient declined postoperative angiography. The AVM was presumed to be totally removed because surgical inspection at the end of the last operation did not disclose any abnormal vasculature.

Now, 3 years later, the patient is performing well at school and is able to drive and water-ski. He has had two seizures, which were controlled medically.

Case 3

A 60-year-old woman presented with a 5-year history of episodic left-sided paresthesia diagnosed angiographically as being due to a right basal ganglia AVM (Fig. 3). Left hemiparesis commenced 10 years before this evaluation and became progressive. It was the progressiveness of the weakness that led to the decision for therapy. At the time, the patient was leading an independent life requiring minimal assistance in her daily chores. Two sessions of preoperative embolization were attempted, and the second was complicated by a mild ischemic attack leading to worsening of her focal deficit.

Eight weeks later, the AVM was approached directly through the right sylvian fissure without any initial attempt at occluding the small lenticulostriate feeders. When the surface of the AVM was reached, its lateral surface was isolated from the surrounding brain through microsurgical dissection in the gliotic brain-lesion interface. There was no worsening of her neurological deficit postoperatively. The second stage of the excision was carried out 2 weeks later. The same lateral sylvian approach was followed without initial exposure of the lateral ventricle. However, as the dissection progressed, the brain pulsated somewhat more vigorously. Episodes of vascular oozing and bleeding became difficult to control by bipolar coagulation and were more frequent. One arterial bleeder was packed at the mesial aspect of the dissection. No further hemorrhage occurred during the ensuing 20 minutes, when there was no surgical manipulation of the wound. Suddenly, acute massive swelling of the entire frontal lobe occurred, with significant herniation of the brain out of the craniotomy defect. At some distance anterior to the operative

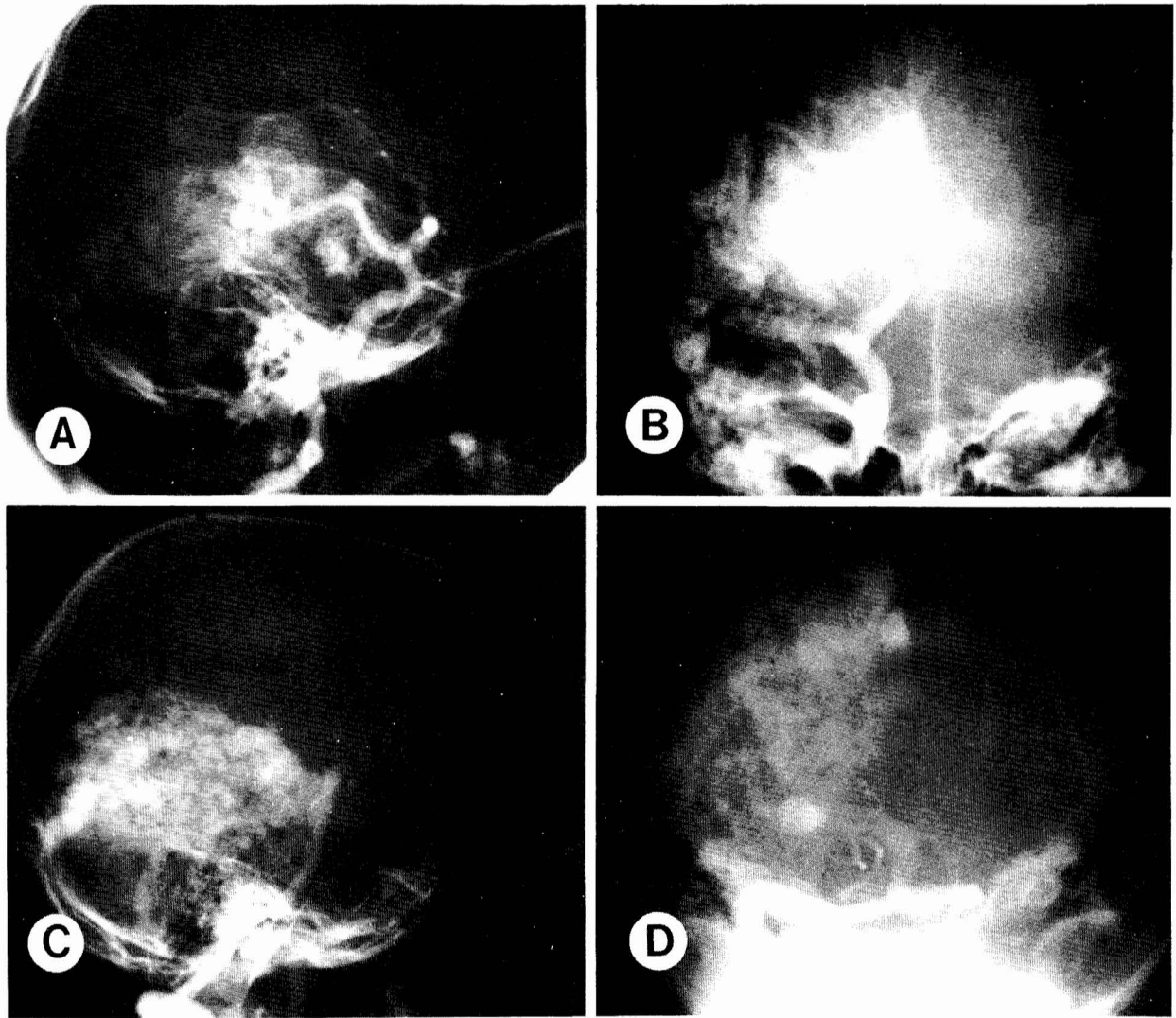


FIG. 2. Case 2. Right internal carotid angiogram demonstrates the temporal component of the AVM (*A* and *B*). Note multiple clusters of abnormal vessels in the anterior temporal region. The large AV shunt made it difficult to opacify the entire extent of the malformation. *C* and *D*, vertebral angiography shows the occipital component of the AVM, which extended to the midline and the occipital pole.

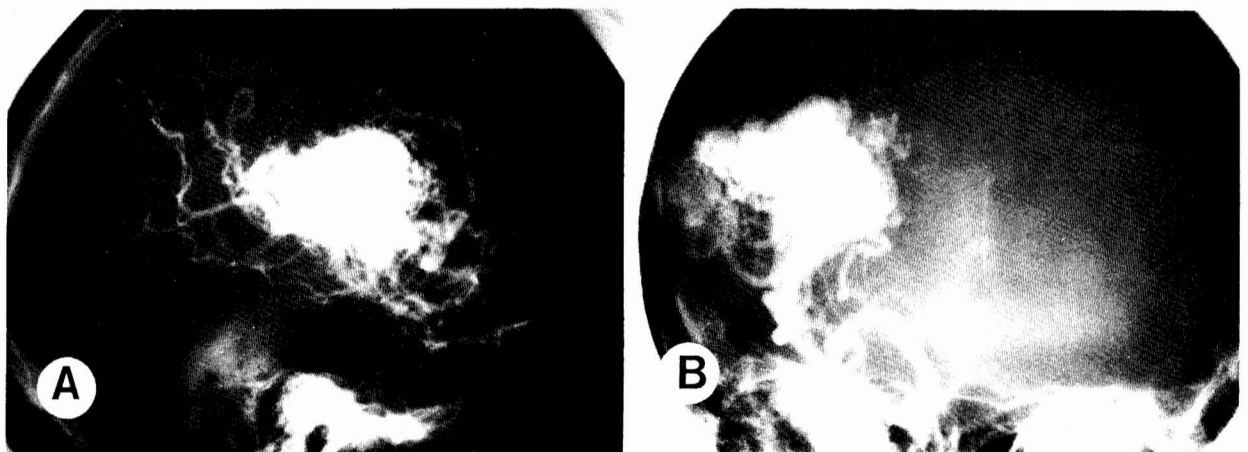


FIG. 3. Case 3. The basal AVM was fed mainly by the right internal carotid artery. The cloudlike clusters of abnormal vessels at the periphery of the AVM were fragile and produced intermittent intraoperative hemorrhages.

site, explosive hemorrhages appeared in the cerebral substance and some dissected through the cortex. Attempts to control these hemorrhages led to opening of the ventricular system, which was already filled with blood. This was due in part to the previously packed bleeder, which had retracted into the ventricle and was now actively bleeding. Attempts to control the hemorrhage with microsurgical coagulation were futile and direct pressure over the entire exposed brain was necessary to achieve hemostasis. Barbiturate coma using intravenous thiopental and pentobarbital was immediately instituted, together with mannitol infusion. The arterial pressure was reduced to approximately 65 mm Hg. The brain thereafter relaxed sufficiently to permit wound closure. In spite of postoperative barbiturate therapy, intracranial hypertension was only marginally controlled and a severe adult respiratory distress syndrome and coagulopathy soon overwhelmed the patient, leading to her death 3 weeks postoperatively.

Comment

In view of these occurrences, our approach to these extensive periventricular lesions was modified. First, bleeding vessels are meticulously coagulated (4). Packing of hemorrhages is reduced to a minimum to avoid retraction of the opened and bleeding vessel into another region of the CSF space. Second, all procedures are terminated when excessive pulsation of the surrounding brain or excessive oozing around the operative site does not subside after an observation period of 30 to 40 minutes because these latter conditions have been the prodrome to "autoregulation breakthrough" swelling or hemorrhages. Third, all lesions are approached transventricularly because this will allow the surgeon to monitor the intraventricular space. The surgeon can also approach the AVM through the ependymal surface, thus treating the AVM as a "superficial" lesion. Last, barbiturate coma and hypothermia (30°C) are instituted electively at the start of each operation to reduce cerebral metabolism and thus cerebral blood flow (15, 16). Barbiturate coma is induced by the intravenous infusion of thiopental over 1 hour with the infusion adjusted thereafter to maintain an isoelectric electroencephalogram. Intravascular volume is maintained and cardiovascular function is monitored with a Swan-Ganz catheter. Hypothermia is achieved using topical cooling (water blanket). Thiopental infusion is terminated at the end of any uneventful operation. Such procedures afford brain relaxation for adequate surgical exposure. In addition, reduction of brain metabolism and blood flow may also afford some degree of protection against acute vascular engorgement as a result of vasomotor paralysis or "autoregulation breakthrough" (19, 29, 34). At the termination of each procedure, the ICP is monitored with a subdural monitor until the patient awakens from coma.

Case 4

A 40-year-old, right-handed woman had had severe intractable vascular headaches for 5 years when an angiogram disclosed a large AVM in the left basal ganglia that extended to the hypothalamus. Because of its location, the lesion was deemed inoperable. However, as a result of progressive headache and the commencement of intermittent but progressive difficulty with vision, speech, and handwriting, the patient was referred for evaluation.

The admission neurological examination was normal. A repeat angiogram disclosed a left internal carotid aneurysm in addition to the deep basal AVM (Fig. 4, A to C). The aneurysm was clipped. Seven months later, the AVM was approached through the sylvian fissure and insular cortex.

The lateral aspect of the lesion was isolated. A transient receptive aphasia lasted 2 weeks postoperatively.

Stage 2 excision of the AVM was undertaken through the same approach but under elective deep barbiturate coma. After the lateral third of the AVM was isolated from the surrounding brain, acute swelling occurred in the presence of an initially relaxed brain and a mean arterial blood pressure of 70 mm Hg. With the administration of a small dose of mannitol, the brain became much more relaxed within 1 minute. The procedure was immediately terminated. No significant intracranial hypertension was encountered postoperatively. Barbiturate coma was maintained for 1 week. After emergence from induced coma, the patient demonstrated a moderate expressive aphasia and hemiparesis, which improved significantly over the following months. When she presented for the third stage of the AVM excision 9 months later, only a very mild anomia and hemiparesis was detectable.

A transventricular approach through the left midfrontal gyrus was performed with the patient under barbiturate coma during the third stage operation. Attention was directed toward isolating the mesial half of the AVM located in the hypothalamus and the anterior perforate substance. At the end of the procedure, the lateral left hypothalamus was removed and the carotid bifurcation was visualized. There were transient episodes of diabetes insipidus postoperatively, which responded to fluid replacement and vasopressin treatment.

The fourth stage and the final excision of the AVM was undertaken 11 months after the third stage. At this time, the patient was able to carry on a meaningful conversation despite a mild dysphasia. The right hemiparesis was barely detectable. Under barbiturate coma, the previous left frontal transventricular exposure was reopened and the remaining AVM in the lateral basal ganglia and internal capsule was removed. This was confirmed by a postoperative angiogram (Fig. 4, D and E). The patient awoke from coma 4 days later and is making satisfactory progress in recovering from a transient worsening of her speech impairment and hemiparesis. The patient currently converses with hesitancy in short sentences. Despite the hemiparesis, she is able to ambulate without assistance outside her home.

Case 5

The patient, a 29-year-old man, suffered an intracerebral hemorrhage in December 1979 as a result of a deep-seated AVM in the right hemisphere. Operation for evacuation of the hematoma and ligation of a large feeding artery was complicated by rebleeding and subsequent wound infection and cerebritis. He was left with a residual left homonymous hemianopia and left hemiparesis. Focal seizures were controlled medically. Two years after the initial hemorrhage, the patient was referred for surgical therapy.

A preoperative angiogram disclosed an AVM involving the dorsal and posterior right thalamus, mainly supplied by the thalamoperforators and the choroidal arteries (Fig. 5, A to D). Under barbiturate coma, a right transfrontal approach to the ventricular system was made. This allowed adequate access from the foramen of Monro to the trigone. The lesion was mainly subependymal with occasional vascular loops protruding into the floor of the body of the lateral ventricle. The superior half of the AVM was isolated through dissection in the perilesion gliotic plane. One bleeding vessel bordering the internal capsule had to be followed into this structure for coagulative control. The patient awoke from the operation with worsening of the left hemiparesis, which did not recover to his preoperative status despite intense rehabilitation.

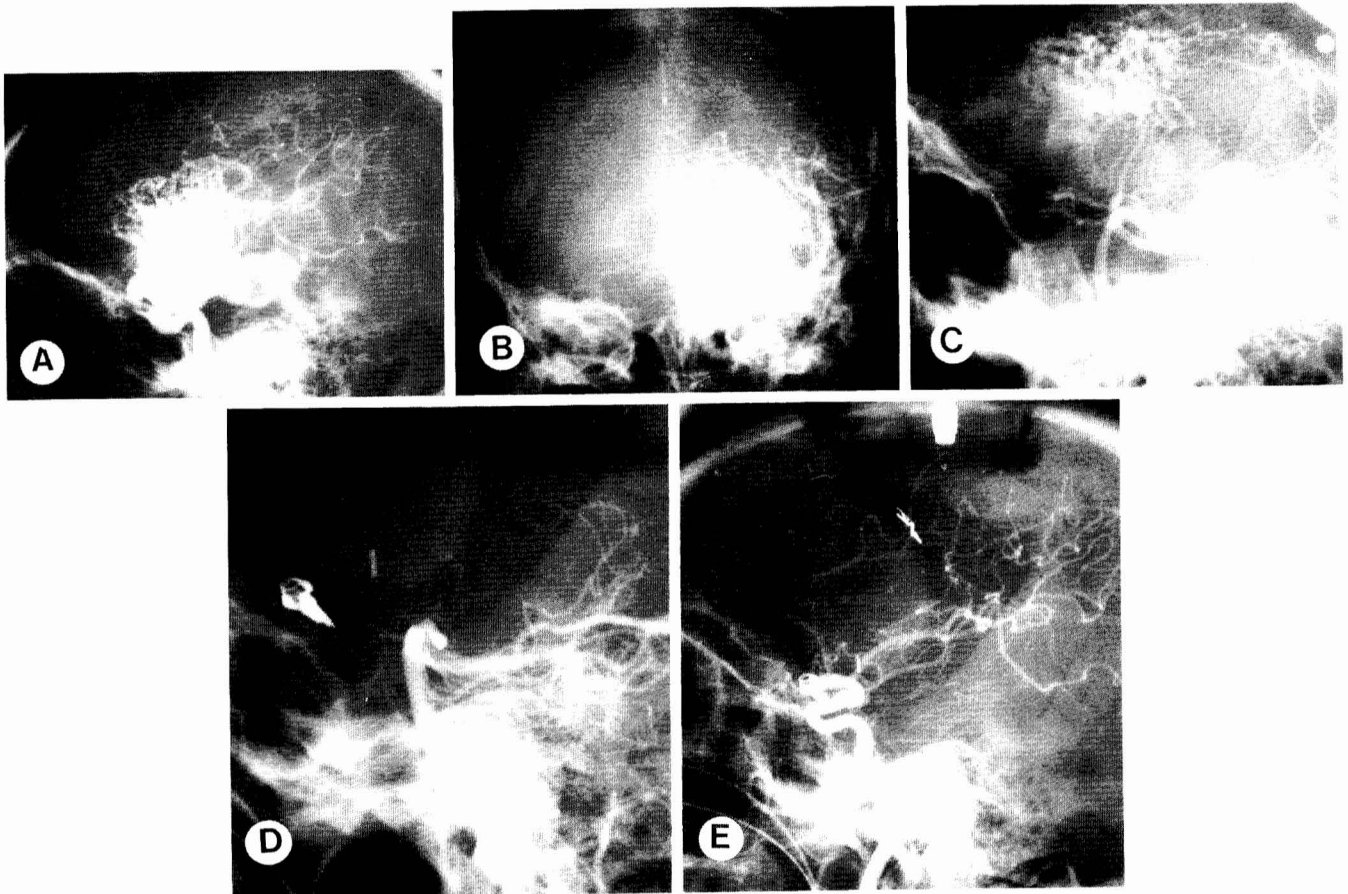


FIG. 4. Case 4. The AVM was fed by the left internal carotid artery (lateral (A) and AP (B) views) with the mesial aspect approaching the midline hypothalamus. The contribution from the posterior circulation (C) was minor, but these tortuous vessels were fragile and produced some incessant hemorrhage. They were eliminated during the third operative stage (D). The postoperative angiogram (E) confirmed total excision of the lesion.

Seven months later, the patient returned for the final removal of the AVM (Fig. 5E). This was accomplished with the same anesthetic and operative approach. The immediate postoperative course, however, was complicated by transient systemic hypertension as the patient was awakening from the barbiturate coma. This led to intraventricular hemorrhage. Despite immediate evacuation of the hematoma, recovery was markedly delayed. Communicating hydrocephalus had to be treated with CSF shunting. His mentation returned to normal after 2 months, but he still had significant difficulty with ambulation 1 year postoperatively.

Case 6

A subarachnoid hemorrhage led to the diagnosis of a right basal ganglia AVM in a 12-year-old girl. The lesion involved the dorsal and posterior aspect of the thalamus, with a portion extending around the trigone into the temporal horn (Fig. 6, A to D). Two subsequent hemorrhages left her with a severe left hemiparesis. Her mentation was, however, bright and she performed well at school. Despite her hemiparesis, she was physically active. Embolization with partial occlusion of the lesion was performed before referral to our center. When she presented for operation 4 years after the initial hemorrhage, her examination disclosed a left homonymous hemianopia and a severe left hemiparesis.

Under barbiturate coma, a right frontal transventricular approach was taken for isolation of the anterior portion of

the AVM. The lenticulostriate feeders entering from the inferior aspect of the AVM were easily identified with reflection of the isolated portion of the AVM. These were coagulated and divided. Three weeks later, a second stage operation was undertaken through an inferior temporal transventricular approach for isolation of the portion of the AVM in the temporal horn. The AVM was completely excised through the frontal transventricular approach in two additional stages spaced 2 and 1 month apart, respectively (Fig. 6E).

At discharge, the patient's neurological status was essentially the same as when she first presented for operation. Currently, she is active and attending school 1½ years after total AVM removal.

INTRAVENTRICULAR AVMs

Between 1979 and 1983, four AVMs located in the trigone of the dominant hemisphere were excised from three patients.

Case 7

A 23-year-old man had an intraventricular hemorrhage 2 years before operation. A 2.5- × 2.5- × 2.5-cm AVM in the left ventricular trigone was fed by both anterior and posterior choroidal arteries, as well as the middle cerebral artery (Fig. 7, A to C). His neurological function remained normal despite a second intraventricular hemorrhage.

Surgical excision was undertaken through a middle tem-

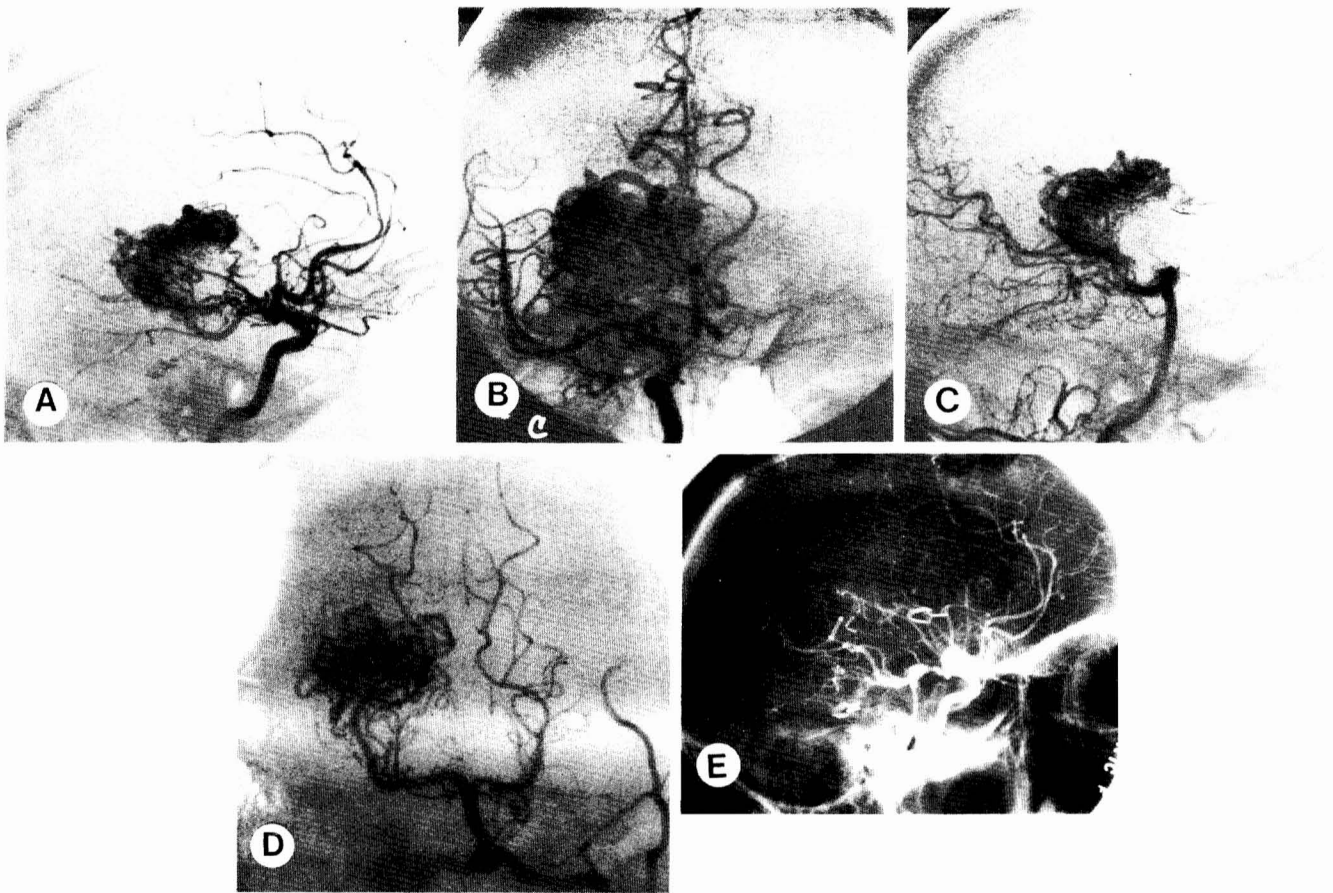


FIG. 5. Case 5. The AVM was supplied by both the right internal carotid (lateral (A) and AP (B) views) and the posterior cerebral (lateral (C) and Towne (D) views) arteries. It occupied the dorsoposterior thalamus, but also presented in the temporal horn. Postoperative angiography (E) demonstrated total excision.

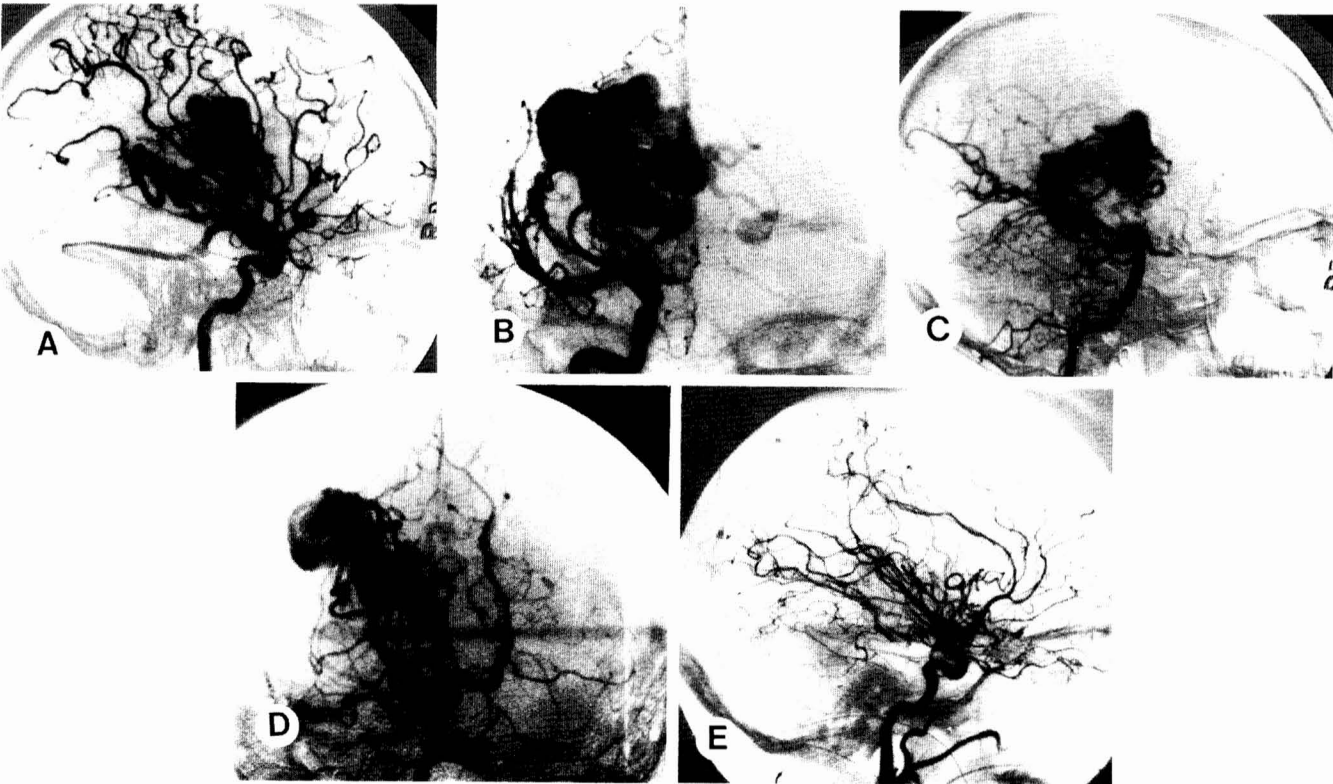


FIG. 6. Case 6. The AVM was similar to the one in Case 5, being supplied by both the right internal carotid (lateral (A) and AP (B) views) and the posterior cerebral (lateral (C) and Towne (D) views) arteries. Postoperative angiography (E) demonstrated total excision.

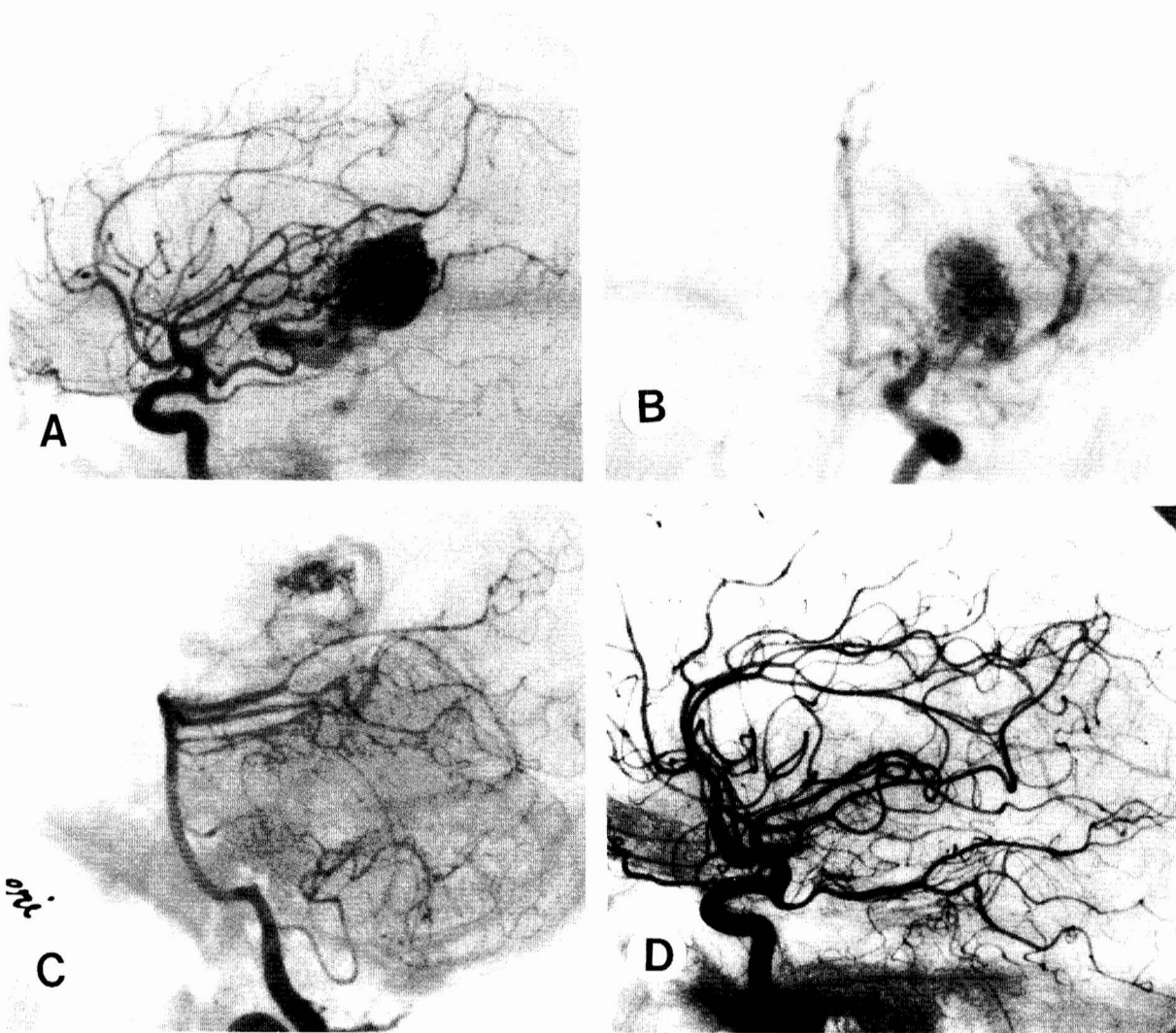


FIG. 7. Case 7. The dominant trigonal AVM was supplied by both the left internal carotid (lateral (A) and AP (B) views) and the posterior cerebral (lateral view (C)) arteries. The lesion filled the entire atrium. Complete excision was demonstrated by postoperative angiograms (D).

poral gyrus approach to the trigone. The lesion occupied and distended the entire ventricular atrium. Abnormal vessels were encountered before any release of CSF to indicate entry into the ventricular system. Total excision was accomplished after shrinkage of the lesion through coagulation of surface vessels (Fig. 7D). Even though the lesion was closely applied to the choroid plexus, it seemed to have originated from ependymal vessels.

A small homonymous right temporal visual field defect resolved after 1 year. The patient has remained neurologically intact without any memory deficits over the past 3 years. These were rare seizures, which have been controlled medically.

Case 8

Multiple seizures over a 2-year period led to the diagnosis of a left intraventricular AVM in a 29-year-old woman. A subsequent intraventricular hemorrhage forced the decision

to attempt definitive surgical treatment. Because of a dominant supply to the malformation from the posterior cerebral artery, which originated from the internal carotid artery (Fig. 8, A and B), an attempt at embolization was unsuccessful. No neurological deficit was present preoperatively.

The ventricular atrium was approached through the inferior temporal gyrus. Even though the majority of the lesion resided in the CSF space, a tongue of it extended through the white matter to the inferior occipital cortex. A complete removal was achieved and confirmed angiographically (Fig. 8C).

The patient regained her preoperative status without any change in her memory function. Her seizure activity has been controlled medically for the past 2½ years.

Case 9

A 22-year-old woman suffered intraventricular hemorrhage, which rendered her stuporous and aphasic. This apparently resulted from a small AVM located in the left ventricular

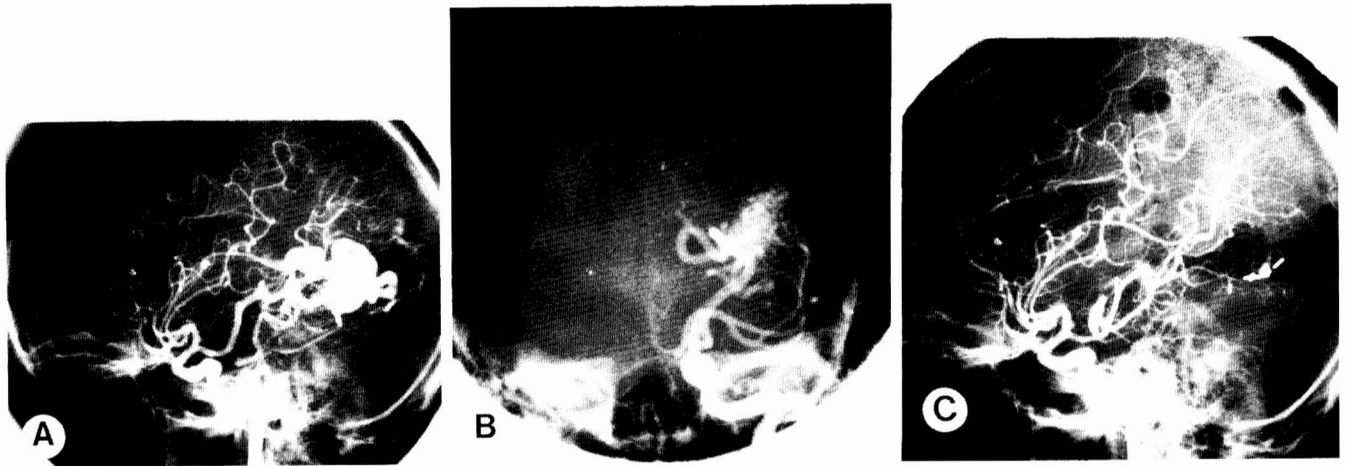


FIG. 8. Case 8. This AVM was supplied by the posterior cerebral artery, which originated from the left internal carotid artery (lateral (A) and AP (B) views). A small component of the lesion presented at the inferior occipital cortex. Complete excision was achieved (C).

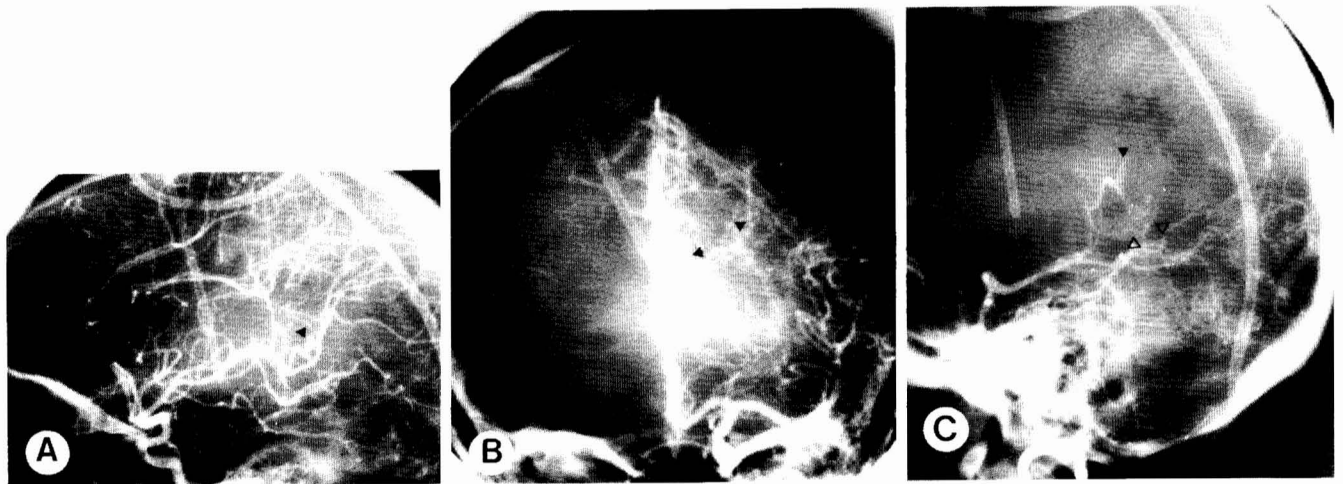


FIG. 9. Case 9. The small AVM (solid arrowheads) was demonstrated in the left internal carotid (lateral (A) and AP (B) views) and left posterior cerebral (lateral view (C)) angiograms. A less distinct cluster (open arrowheads) was not evident and had to be excised in a second operation.

trigone (Fig. 9). The patient's sensorium rapidly improved with the placement of a ventriculoperitoneal shunt for obstructive hydrocephalus, but her speech and orientation remained impaired. Eighteen days after her initial hemorrhage, a left temporal craniotomy was performed for excision of the AVM.

The left trigone was approached through an incision in the inferior temporal gyrus. After the removal of a liquified hematoma, a small cluster of abnormal vessels was removed from the posterolateral thalamic ependyma. Inspection of the remaining trigonal ependymal surface disclosed no other abnormality. A postoperative angiogram, however, revealed a residual cluster in the inferior trigone. A repeat craniotomy through the previous transcortical approach was therefore undertaken. The AVM was 1 cm in diameter and was located subependymally at the junction of the inferior trigone and temporal horn. A total removal was achieved and verified angiographically.

The patient demonstrated a transient right visual field defect postoperatively. Her major disability was short term memory loss and partial aphasia. Over the past year, these defects have improved significantly with intense rehabilita-

tion. She has been able to care for herself and conduct a meaningful conversation. Rare absence spells have been controlled medically. The patient currently is contemplating returning to school.

DISCUSSION

AVMs in the paraventricular region are uncommon (1, 4, 7, 10, 17, 18, 24, 25, 36). Their treatment represents a formidable therapeutic undertaking. Even though the excision of small lesions in the basal nuclei or ventricles has been reported (1, 2, 6, 10, 12, 21, 27, 28, 33, 35), extensive lesions are generally declared inoperable because of their relative inaccessibility and involvement with functionally critical areas. This report details a systemic approach to the microsurgical treatment of some extensive central AVMs. Six lesions involving the basal nuclei were treated with 19 staged operations. Three patients are back to their preoperative occupations, with one of these having fully recovered from a complete hemiplegia. One woman developed a mild speech deficit and hemiparesis postoperatively, and the mild hemiparesis in the 29-year-old man worsened markedly after the

excision of a thalamic lesion as a result of postoperative intraventricular hemorrhage. This led to severe disability in ambulation. The only mortality occurred in the oldest patient (60 years old), who succumbed to uncontrolled acute intracerebral swelling and hemorrhage. During the same period, four AVMs were removed from the trigone in the dominant hemisphere of three patients. Although two patients had transient homonymous quadrantanopia, only one still has the preoperative memory deficit, which is clearing with rehabilitation. These results suggest that microsurgical excision offers a valid therapeutic approach to extensive central AVMs.

Central AVMs pose specific therapeutic problems as a result of their paraventricular location, which predisposes them to hemorrhage within the ventricular system. Intraventricular hemorrhage is also a common presentation of intraventricular AVMs, and recurrent hemorrhage is more frequent in these lesions (26). The hemorrhagic episode most often leads to compromise in sensorium. This may be a result of acute obstructive hydrocephalus or chemical ventriculitis. Because these symptoms are usually subacute, immediate operative evacuation of the intraventricular clot is seldom necessary. Cerebrospinal fluid drainage for the relief of increased ICP and elimination of the lytic products of the hematoma suffices in most cases for clinical improvement. This temporizing measure permits the acute effects on the surrounding brain to subside. It also allows time for a detailed angiographic study of the vascular anatomy before surgical excision.

Extensive lesions were excised in multiple stages to allow graded redistribution of cerebral blood flow. In these instances, a complete angiographic and CT evaluation was undertaken before each procedure because different surgical exposures may have to be adapted to approach different aspects of an extensive lesion. Accurate delineation of the relationship of the feeding arteries and draining veins to the ventricular system and basal structures (visualized by CT scanning) is critical because this permits the surgeon to use the most direct transventricular or subarachnoid approach to the feeding vessels while protecting the integrity of the veins. In addition, large venous channels or aneurysmal dilatations are frequently reflections of the degree of arteriovenous shunting. The presence of large channels would thus alert the surgeon to the possibility of "autoregulation breakthrough" hemorrhages should an extensive excision be planned. Such venous channels, however, seldom present significant technical challenges intraoperatively because they collapse and thrombose after elimination of the arteriovenous shunts.

The location of AVMs in the basal nuclei usually renders them relatively inaccessible. Their periventricular presentation, however, can be turned to the surgeon's advantage if he adapts the transventricular approach. Once the ventricular system is entered, many of these AVMs can be seen to present through the ependyma or to be directly subependymal. In such situations, they can be handled in like fashion as superficial cortical lesions. Dissection planes can be developed in the perilesion gliotic plane (4). Coagulation of surface vessels will shrink the lesion, thus further developing the dissection plane and reducing the need for extensive brain retraction to provide exposure. The transventricular approach also affords the surgeon adequate monitoring of the intraventricular content so that any packed bleeder would not be overlooked should it retract and bleed into other portions of the intraventricular system. This may have been the situation in Case 3, where the sylvian approach was taken. Conceivably, the intraventricular hemorrhage could have been dealt with sooner if the transventricular approach had been pursued.

Acute vasodilatation has been observed with manipulation in the basal area (9, 20). This may be responsible for some

instances of acute brain swelling. Acute brain swelling or hemorrhage is also sometimes encountered during the elimination of extensive high flow AVMs (19, 29, 34, 36). This is presumed to result from engorgement of the maximally dilated, chronically ischemic perilesion cerebral vessels, which have lost autoregulation. When the physical integrity of such vessels is disrupted, uncontrolled catastrophic hemorrhages may ensue. The outcome of such occurrences has been uniformly dismal. One method of treatment is by induced hypotension to reduce regional blood flow through the use of agents such as sodium nitroprusside. Under such treatment conditions, the cerebral metabolism, however, remains unaltered in the face of reduced blood flow. On the other hand, agents that reduce both blood flow and cerebral metabolism theoretically would afford additional protection against ischemia. Barbiturates possess such properties and have been used to control intracranial hypertension as a result of head trauma. These agents have also been used successfully to control acute brain swelling during the surgical treatment of extensive AVMs (15, 16). In the latter situation, the patients commonly suffered devastating neurological deficits, probably as a result of damage sustained during the period (20 to 30 minutes) required to achieve brain relaxation. We reasoned that if barbiturate coma were induced before the event, not only would the brain be sufficiently relaxed to facilitate surgical exposure, cerebral blood flow would also be reduced to allow ischemic vessels to accommodate any acute blood redistribution. With this in mind, we used induced barbiturate coma for extensive basal AVMs. This was done with the full awareness that it would frequently be 4 to 7 days before the patient would emerge from induced coma. Our experience with Case 4, where acute swelling was successfully treated within 1 to 2 minutes with mild resultant clinical deficit, tends to support our contention. With continued experience, we are now able to titrate the barbiturate dose to achieve a much earlier wake-up time (24 to 36 hours). Staged operations with resultant limited but progressive redistribution of blood flow would potentially facilitate the circulation accommodation process as well (29, 33, 34, 36).

The need for multiple stages is suggested by the significant degree of arteriovenous shunting on the preoperative angiograms. It is difficult to determine the number of stages required at the beginning because the outcome of each stage cannot be foreseen. Excessive pulsation of the surrounding cerebral substance or unexplained oozing at sites distant from the operative field frequently indicate impending "autoregulation breakthrough" swelling and hemorrhage. Thus, each stage would proceed until such occurrences and be terminated; otherwise, as extensive a resection as possible will be carried out. Should the operation be uneventful, we have seldom encountered significant postoperative problems if the patient's cardiovascular status is well controlled. The hemorrhagic episode in Case 5 was a result of a hypertensive event due to the lack of patient sedation. This occurred early in our experience with elective barbiturate anesthesia. No such complication has since occurred.

Operations for the excision of intraventricular AVMs are similar to those for basal lesions because the transventricular approach is necessary. The surgical approach to the lateral and 3rd ventricular system is either transcortical or transcallosal (4, 10). The transfrontal approach not only allows access to the frontal horn and 3rd ventricle, but will also provide ample exposure to the trigone (4). Trigonal lesions can also be excised through incisions in the superior parietal or mid-temporal gyri or the splenium of the corpus callosum. One possible limitation of the transcallosal approach is in the lateral exposure of extensive lesions, as in Cases 7 and 8,

Exposure is nonetheless generally adequate through these "silent" areas without causing significant neurological defects. Visual deficits have been transient in our experience with the temporal approach. Any involvement of structures such as the limbic or thalamic systems, however, may lead to significant impairment of memory and language functions. It is therefore essential that the approach taken avoid retraction or dissection within these vital structures.

In conclusion, our experience with this series of extensive basal AVMs suggests that microsurgical excision coupled with cerebral protection using elective barbiturate coma offers a valid therapeutic regimen in the treatment of this devastating disease. In addition, our experience supports the contention that intraventricular AVMs can be excised with little morbidity. Their tendency to rebleed is an argument for an aggressive approach to their treatment.

ACKNOWLEDGMENTS

The author thanks Drs. M. Todd, J. Drummond, L. F. Marshall, and J. Alksne for continuous support and encouragement; the operating room personnel for technical assistance; and the neurosurgical house staff and the nursing staff, especially in the intensive care unit, for their devoted care of these critically ill patients. I also thank D. Rosati and B. Siaumau for excellent secretarial assistance.

Received for publication, March 3, 1984; accepted, October 19, 1984.

Reprint requests: Hoi Sang U, M.D., University of California Medical Center, 225 Dickinson Street, San Diego, California 92103.

REFERENCES

1. Bushe KA, Bockhorn J, Schafer ER: Macro- and microsurgery of central angiomas, in Pia HW, Gleave JRW, Grote E, Zierski J (eds): *Cerebral Angiomas*. New York, Springer-Verlag, 1975, pp 123-128.
2. Caram PC, Sharkey PC, Alvord EC: Thalamic angioma and aneurysm of the anterior choroidal artery with intraventricular hematoma. *J Neurosurg* 17:347-352, 1960.
3. Debrun G, Vinuela F, Fox A, Drake CG: Embolization of cerebral arteriovenous malformations with bucrylate: Experience in 46 cases. *J Neurosurg* 56:615-627, 1982.
4. Drake CG: Cerebral arteriovenous malformations: Considerations for and experience with surgical treatment in 166 cases. *Clin Neurosurg* 26:145-208, 1978.
5. Forster DMC, Steiner L, Hakanson S: Arteriovenous malformations of the brain: A long-term clinical study. *J Neurosurg* 37:562-570, 1972.
6. Garrido E, Stein B: Removal of an arteriovenous malformation from the basal ganglion. *J Neurol Neurosurg Psychiatry* 41:992-995, 1978.
7. Guidetti B, Delitala A: Intracranial arteriovenous malformations: Conservative and surgical treatment. *J Neurosurg* 53:149-152, 1980.
8. Henderson WR, Gomez RRL: Natural history of cerebral angiomas. *Br Med J [Clin Res]* 4:571-574, 1967.
9. Iadecola C, Mraovitch S, Meeley MP, Reis DJ: Do cholinergic neurons of the basal forebrain cholinergic system mediate the cortical vasodilation elicited by fastigial nucleus stimulation in rat? *J CBF Metab* 3:S178-S179, 1983.
10. Juhász J: Surgical treatment of arteriovenous angiomas localized in the corpus callosum, basal ganglia and near the brain stem. *Acta Neurochir (Wien)* 40:83-101, 1978.
11. Kunc Z: Surgery of arteriovenous malformations in the speech and motor-sensory regions. *J Neurosurg* 40:293-303, 1974.
12. Kunc Z: Deep-seated arteriovenous malformations: A critical review, in Carrea E, LeVoy D (eds): *Neurological Surgery with Emphasis on Non-invasive Methods of Diagnosis and Treatment*. Amsterdam, Excerpta Medica, 1978, pp 188-193.
13. Luessenhop AJ, Mujica PH: Embolization of segments of the circle of Willis and adjacent branches for management of certain inoperable cerebral arteriovenous malformations. *J Neurosurg* 54:573-582, 1981.
14. MacKenzie I: The clinical presentation of the cerebral angioma: A review of 50 cases. *Brain* 76:184-214, 1953.
15. Marshall LF, U HS: Treatment of massive intraoperative brain swelling. *Neurosurgery* 13:412-414, 1983.
16. Marshall LF, U HS, Barba D: Massive intraoperative brain swelling: Can it be treated?. In Isshi (ed): *ICP V*. Berlin, Springer-Verlag, 1983.
17. Moody RA, Poppen JL: Arteriovenous malformations: A report of 154 personal cases and a comparison between the results of surgical excision and conservative management. *J Neurosurg* 32:503-511, 1970.
18. Morello G, Borghi GP: Cerebral angiomas: A report of 154 personal cases and a comparison between the results of surgical excision and conservative management. *Acta Neurochir (Wien)*: 28:135-155, 1973.
19. Mullan S, Brown FD, Patronas NJ: Hyperemic and ischemic problems of surgical treatment of arteriovenous malformation. *J Neurosurg* 51:757-764, 1979.
20. Nakai M, Iadecola C, Reis DJ: Global cerebral vasodilation by stimulation of rat fastigial cerebellar nucleus. *Am J Physiol* 243:H226-H235, 1982.
21. Ng LKT, Schwarz G, Mishkin MM: Hematoma from arteriovenous malformation producing hydrocephalus and simulating a thalamic tumor: Report of two cases. *J Neurosurg* 34:229-235, 1971.
22. Olivecrona H, Riives J: Arteriovenous aneurysms of the brain: Their diagnosis and treatment. *Arch Neurol Psychiatry* 59:567-602, 1948.
23. Parkinson D, Bachers G: Arteriovenous malformations: Summary of 100 consecutive supratentorial cases. *J Neurosurg* 53:285-299, 1980.
24. Pellettieri L, Carlsson C-A, Grevsten S, Norlén G, Uhlemann C: Surgical treatment. *Acta Neurochir (Wien) Suppl* 29:1-86, 1979.
25. Perret G, Nishioka H: Report on the Cooperative Study of Intracranial Aneurysms and Subarachnoid Hemorrhage: Section VI. Arteriovenous malformations. *J Neurosurg* 25:467-490, 1966.
26. Pia HW: The acute treatment of cerebral arteriovenous angiomas associated with hematomas, in Pia HW, Gleave JRW, Grote E, Zierski J (eds): *Cerebral Angiomas*. New York, Springer-Verlag, 1975, pp 155-177.
27. Ralston BL, Papatheodorou CA: Vascular malformation of the left thalamus. *J Neurosurg* 17:505-510, 1960.
28. Ribaric II: Arteriovenous malformation in the basal ganglia: Case report. *J Neurosurg* 41:244-247, 1974.
29. Spetzler RF, Wilson CB, Weinstein P, Mehdorn M, Townsend J, Telles D: Normal perfusion pressure breakthrough theory. *Clin Neurosurg* 25:651-672, 1977.
30. Steiner L, Bachland EO, Greitz T, Leksell L, Noren G, Rahn T: Radiosurgery in intracranial arteriovenous malformations: II. A followup study, in Carrea R, LeVoy D (eds): *Neurological Surgery with Emphasis on Non-invasive Methods of Diagnosis and Treatment*. Amsterdam-Oxford, Excerpta Medica, 1978, pp 168-180.
31. Svien HJ, McRae JA: Arteriovenous anomalies of the brain: Fate of patients not having definitive surgery. *J Neurosurg* 23:23-28, 1965.
32. Troupp H: Natural history of arteriovenous malformations. Presented at the Symposium on Aneurysms, Arteriovenous Malformation and Carotid Cavernous Fistulae, 50th Anniversary, University of Chicago, Chicago, Illinois, November 1977.
33. U HS, Rosenberg J: Complete recovery from hemiplegia following excision of a giant basal ganglia arteriovenous malformation. *Surg Neurol* 15:328-330, 1981.
34. U HS, Wilson CB: Microsurgical treatment of intracranial vascular malformations. Presented at the 45th Annual Meeting of the American Association of Neurological Surgeons, Toronto, Ontario, April 24-28, 1977.
35. Viale GL, Turtas S, Pau A: Surgical removal of striate arteriovenous malformations. *Surg Neurol* 14:321-324, 1980.
36. Wilson CB, U HS, Domingue J: Microsurgical treatment of intracranial vascular malformations. *J Neurosurg* 51:446-454, 1979.

COMMENTS

The author of this article dealing with deep and intraventricular arteriovenous malformations records a number of instances of technical triumph with lesions that most people would consider inoperable. One might question the surgical indications of some of the larger lesions, especially the 60-year-old patient who had not had previous hemorrhage. This happened to be the one mortality, and many neurosurgeons would not have operated on this patient, considering the clinical history and the complexity of the lesion. With some of the other large, deep lesions, the surgical results were less than satisfactory, again raising the question of judgment in terms of the operability of these lesions. The use of up to four staged operations to remove some of the more complex lesions is interesting. In my experience, staging may be of benefit. On the other hand, it may lead to unpredictable disasters because portions of the AVM are isolated during the staging procedures and may explode postoperatively. In the cases with more complex lesions, a great deal of difficulty was experienced with brain swelling, venous congestion, and unexpected hemorrhages during operation and postoperatively. This probably bears witness to the partial removal during the initial operative stages and the massiveness of some of these lesions. Also of interest was that the author found no benefit from preoperative embolization. On the contrary, we have found embolization to be quite useful in reducing malformations, especially the deep ones, making them more accessible to surgical excision, often in a single operative intervention. Also, the use of CT scans in further analyzing the size and relationship of these deep malformations is not stressed by Dr. U. We have found that CT scanning is extremely useful in guiding the operative approach and in anticipating the relationship of these malformations to the deep structures.

Ventricular malformations represent some of the more difficult ones to treat and, as noted by the author, are some of the most dangerous AVMs. The exposed venous coils are treacherous areas where hemorrhage may occur during operative intervention.

Often, the arterial supply to these lesions is obscure to the surgeon working down a deep passageway. The various routes to the ventricle deserve an elaborate discussion because the choice of a route may determine whether the operation is successful or disastrous. Interestingly, some of the patients

reported here had malformations located in the region of the left trigone. We have encountered a number of patients similar to these who presented with hemorrhage, with the resultant primary neurological deficit of recent memory impairment. Similar impairment existed postoperatively. In one of the cases, the author mentioned that recent memory impairment was a problem, but cleared. The other cases were not detailed in terms of memory impairment. The presence of this neurological deficit suggested to us that cerebral dominance is important in terms of the deep paratrigonal structures often relating to memory such as the fornix, caudate, and corpus callosum and its connections. The author must be complimented on his tenacity and persistence in removing some of the more complex and larger lesions.

Bennett M. Stein, M.D.
New York, New York

The author reports nine cases of unusual AVMs. Six were very extensive paraventricular lesions mainly involving the basal ganglia region and beyond. Three were intraventricular lesions. This report is the first, to my knowledge, of surgical treatment of such extensive lesions in the depth of the brain. The author is to be congratulated for his excellent work and for sharing his experiences with the medical community. This report illustrates that such so-called inoperable lesions can, in fact, be totally removed with acceptable mortality and morbidity. It is obvious that much preoperative planning is needed to determine the surgical approach and the use of hypotension, hypothermia, and barbiturate coma in certain cases. Likewise, intraoperative judgment is critical in deciding when to terminate the procedure to allow the brain to accommodate to a drastically changed cerebral blood flow pattern before another trial of dissection and excision is attempted. In the author's first six cases, he performed 19 procedures, an average of about 3 procedures per case.

The author deserves credit for his courageous and persistent approach in managing such extensive AVMs in the depth of the brain.

Shelley N. Chou, M.D.
Minneapolis, Minnesota