

NOTE

APRAXIA OF THE LEFT LIMBS IN A CASE OF CALLOSAL DISCONNECTION: THE CONTRIBUTION OF MEDIAL FRONTAL LOBE DAMAGE ¹

Georg Goldenberg, Aurelia Wimmer, Felix Holzner, and Peter Wessely

(Neurologische Universitätsklinik Wien)

Liepmann's view that dominance of the left hemisphere concerns not only speech but also the intentional control of learned limb movements was based on two kinds of observations: the much greater frequency of apraxia of the non-paralyzed hand in patients with right-sided hemiplegia than in patients with left-sided hemiplegia, and the occurrence of left-sided apraxia in combination with eupraxia of the right hand after destruction of the corpus callosum (Liepmann, 1908).

Whereas later investigations have largely confirmed the first of these findings (Ajuriaguerra, Hécaen and Angelergues, 1960; Goodglass and Kaplan, 1963; Kimura and Archibald, 1974; De Renzi, Motti and Nichelli, 1980), the latter is challenged by the observation, that left-sided apraxia of patients who underwent surgical commissurotomy is confined to the lack of verbal control of movements which require the use of single digits of the left hand (Gazzaniga, Bogen and Sperry, 1967; Zaidel and Sperry, 1977), whereas imitation of movement is not impaired.

The severity of the left hand apraxia of patients whose corpus callosum was destroyed by tumor or infarction was attributed by some authors to akinesia, motor perseveration, and tonic grasping resulting from damage to the right frontal lobe (Ajuriaguerra et al., 1960; Goldberg, Mayer and Toglia, 1981). This argument is nonetheless contradicted by the reports on patients whose left hand was apractic in imitation and even in actual object use and whose right hemisphere was found to be intact (Liepmann and Maas, 1907; Bonhoeffer, 1914).

We recently observed a patient with a severe apraxia of the left hand who had damage to the corpus callosum and to both medial frontal lobes. On the basis of our observation and a review of reported cases of callosal apraxia, we hope to elucidate the contribution of medial frontal lobe damage to the genesis of left-sided apraxia.

CASE REPORT

A 40 year old right-handed housewife suffered a hemorrhage from an anterior cerebral artery aneurysm. Clipping was performed one day after the accident.

¹ Presented in part at the seventh European conference of the international neuropsychological society, Aachen, June 1984.
Cortex (1985) 21, 135-148

She remained in coma for a week, was then in a state of akinetic mutism, and later showed the picture of transcortical motor aphasia and aphonia.

Our observation began 6 months after the stroke. She was fully conscious and spoke normally, appeared friendly and cooperative, and reacted vividly to any demand, but when left alone she showed no spontaneous activity. She was disoriented to time and place and had a dense anterograde amnesia with confabulation. On the WAIS she scored a verbal IQ of 87 (the raw scores were 10 on general information, 10 on general comprehension, 6 on digit span, 6 on arithmetic, and 13 on similarities). With the exception of picture completion, on which she had a raw score of 8, she failed all subtests of the performance part of the WAIS because of slowness and constructional difficulties.

She used both hands to eat, to hold objects, or to scratch herself, but her legs remained akinetic, and she could walk only with support. Touching of either palm elicited grasping. She was doubly incontinent.

Asked when blindfolded to name touched fingers of the left hand, she confabulated. Tested when blindfolded for stereognosis of the left hand, she palpated the object skillfully, but confabulated as to its name. Given scissors she made cutting movements but continued to confabulate.

A preoperative CT-scan displayed a large hemorrhage extending over the whole interhemispheric fissure. CT at the time of our observation (Figure 1) was interpreted as showing infarction of at least the anterior two thirds of the corpus callosum, of both cingulate gyri, and of the white matter underlying the upper and medial parts of both frontal lobes. Apart from the right-sided lesion extending farther rostrally, there was no notable asymmetry of the lesion.

Motor control of eyes and face

During the first weeks of the observation, verbal commands to open or close the eyes sometimes elicited verbalizing instead of performing, while eye closure on imitation was prompt. In the later period the patient moved her eyelids, mouth and tongue correctly on verbal command and on imitation, while there was underinnervation of the left side of the mouth in talking and spontaneous facial expressions. A verbal command to look to the right or the left was seldom obeyed when the examiner sat in front of her, but she did so promptly, when he was either behind her or on the side she was asked to look to.

Praxis of the right limbs

Apart from a tendency to keep the elbow flexed, which disturbed the performance of movements that demanded full extension of the arm, and apart from akinesia of the leg, which allowed only slow and often incomplete performances of voluntary movements, praxis of the right limbs was normal on verbal command, imitation, and object use. Utilization of objects which are normally held by the left hand (e.g. a fork) was somewhat clumsy but adequate.

A first-edge-palm sequence of hand positions (Luria, 1980) was imitated correctly, but repetition thereof could not be maintained. In up to 50 trials she was not able to learn an alternating sequence of finger tapping (Roland, Larsen, Lassen and Skinhoj, 1980a). In these two tasks the performances of the left hand equalled those of the right.

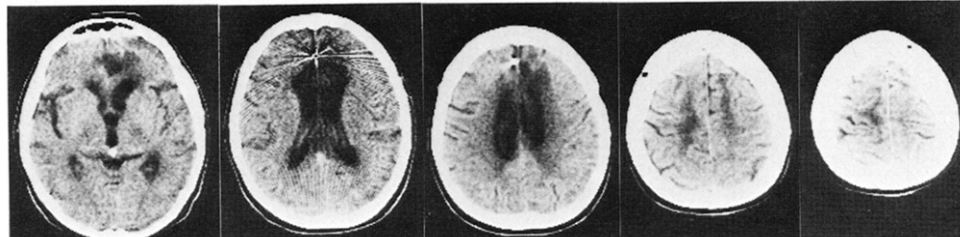


Fig. 1 — CT scan: 8 mm cuts at 28, 44, 60, 76 and 84 mm above the orbitomeatal line.

In writing and drawing with the right hand she used only the right half of the paper. Writing was correct, but there was marked constructional apraxia with hemi-neglect to the left.

Praxis of the left limbs

A testing program consisting of 8 finger postures (e.g. extend the index, form a ring with the thumb and the small finger), 4 hand positions (e.g. bend the hand downwards, make a fist), 6 simple movements of the arm (e.g. place the hand on the contralateral shoulder, draw a circle in the air) and 6 movements of the leg (e.g. place the foot behind the other, move the toes) was repeatedly carried out on verbal command and on imitation, and the patient was blindfolded and asked to repeat each movement with either the same or the opposite limb after it had been demonstrated by passively moving the limb (“kinesthetic-motor-transfer”). A prompt performance equalling that of the right limb was scored as two points; if the patient failed she was asked to correct the error, and if she then succeeded on a second trial, one point was given. A second program involving more complex and sequential movements of the whole upper extremity (Kimura and Archibald, 1974; Kolb and Milner, 1981) was carried out on imitation only, and the patient’s performances were recorded by verbal description and drawings. The performances of symbolic movements did not differ from those of arbitrary movements of the same complexity.

Figure 2 gives the scores on praxis testing with the set of simple movements. In the beginning the patient could execute no finger movements on verbal command, while in later stages she succeeded irregularly in extending the index or the thumb. Imitation of finger movements was perfect from the start. The dissociation between movements on verbal command and on imitation was less marked for the proximal upper extremity and the leg. The predominant type of errors changed: In the beginning there were most often only abortive movements or no movement at all, whereas automatic movements that often resembled closely those demanded in testing were preserved and were carried out even during the testing session. At a later stage spatial errors prevailed in testing arm positions. They were somewhat systematic in that the midline of the body and the oral region seemed to attract the left hand, hindering it from reaching more lateral parts of the body or from performing movements that did not cross the midline of the body (Figure 3). Later, imitation of limb positions became nearly perfect; by contrast, on testing complex movements the tendency to bring the end point of any movement to the midline of the body persisted, so that the proximal com-

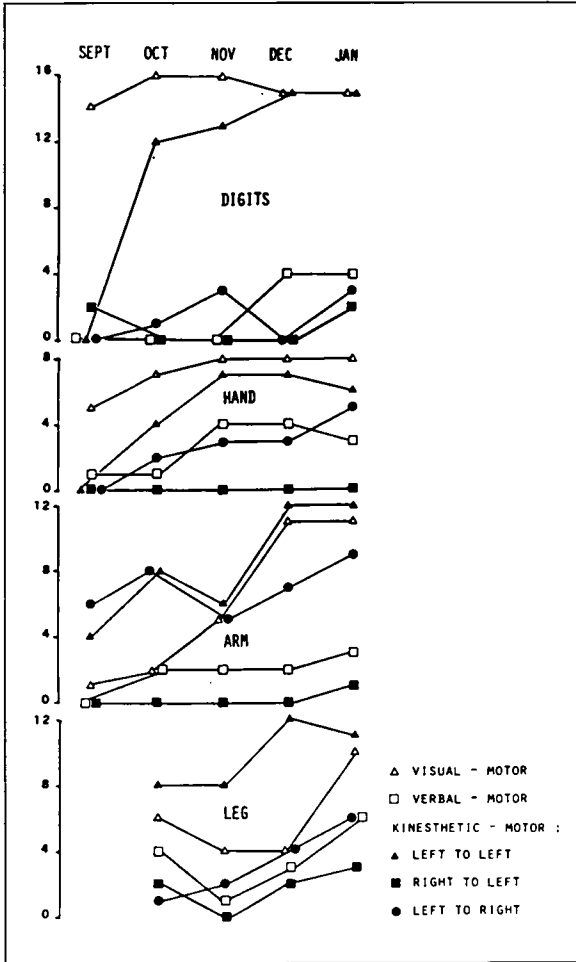


Fig. 2 — Scores in apraxia testing with the set of simple gestures.

ponents were most often reduced to a simple waving movement towards and away from the chest.

Transfer of kinesthetically induced arm movements was defective from left to right and virtually absent from right to left. The latter should have been possible either by ipsilateral sensory afference to the right hemisphere or by ipsilateral motor control of the left hemisphere (Gazzaniga, 1970; Brinkman and Kuypers, 1973; Zaidel and Sperry, 1977). It might be that the right hemisphere did not understand the task and consequently did not cooperate. However, the total lack of transfer indicates that left sided ipsilateral motor control was inefficient.

Manipulation of object by the left hand

The left hand correctly utilized a drinking glass, a spoon, a fork, a cigarette, and eye glasses.

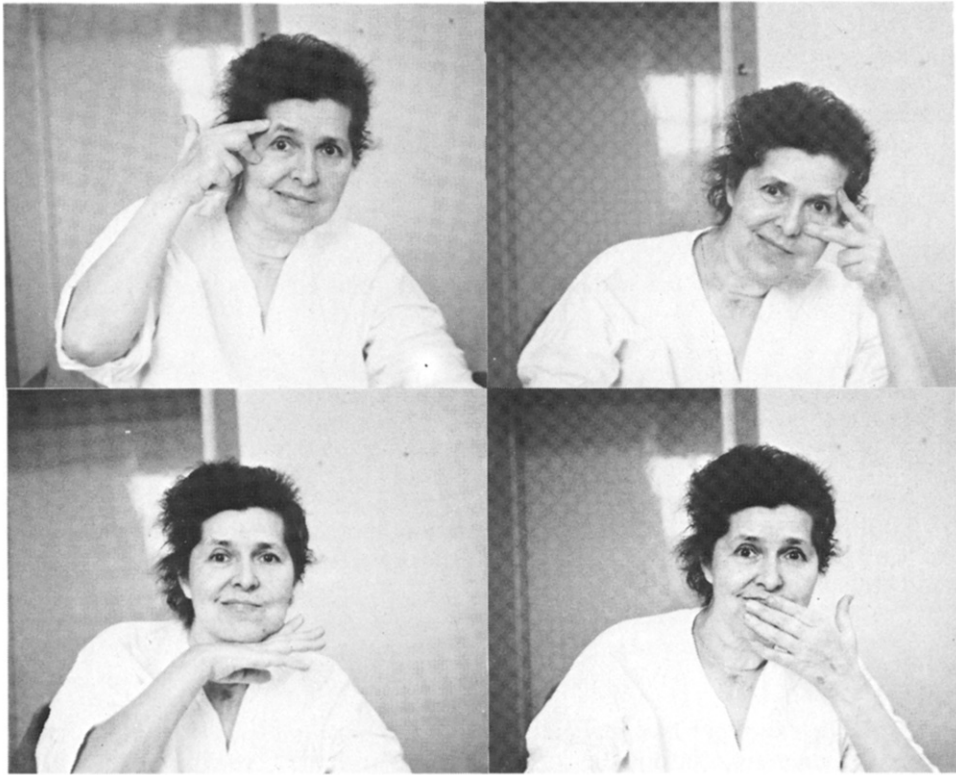

Fig. 3 — *Correct imitation of hand positions by the right hand, faulty performances of the left hand.*

Comb

The left hand held it without doing anything. When the examiner moved it towards the head, the patient combed the hair correctly on the left side, but touched the scalp with the back of the comb over the forehead and the right side of the head.

Knife

She held the knife with its blade parallel to the dish and pressed it into the food.

Key

She first held it without moving it. Then the right hand touched slightly the back of the left hand, and while it rested there the left hand introduced the key and opened the lock. When the right hand was prevented from intervening, the left hand eventually moved the key between the fingers and palpated it but did not bring it to the key hole.

Screwdriver

She scratched the surface of the table with the tip of the screwdriver.

Saw

She held it parallel to the table surface, then brought it to the mouth and put the blade to the lips.

Hammer

She first held it without moving it. When correct use was demonstrated, she made correct striking movements, but stopped the stroke before the hammer reached the table.

Gas lighter

She pressed the wheel with the thumb, but omitted the circular movement necessary to turn it.

Pen

She held it with the tip pointing upwards. When the tip was brought to the paper, she drew some lines, but then turned it back and finally put the pen in the mouth.

Toothbrush

To start the actions the hand had to be brought near the mouth. She then took the head of the brush into the mouth and sucked it, trying in vain with the right hand to get the brush moving.

Motor learning of the left hand


After the examiner had repeatedly corrected her hand positions the patient succeeded in manipulating the knife, the key and the screwdriver, but after distraction the apraxic behavior recurred, and repeated learning trials had no lasting effect. On the other hand, the learning effect of repeated corrections of pen position persisted, but she continued to hold the pen in a very acute angle to the paper and manipulated it almost exclusively by movements of the fingers and the hand without any support by arm movements. Toothbrushing was demonstrated to her while she sucked the toothbrush, and suddenly she opened the lips and started to brush. In further trials the sudden change of the movement pattern came ever earlier, until finally she started the correct action by herself and never fell back to sucking again. When later asked whether she had to learn drawing or toothbrushing with the left hand she denied.

It was noted that the eyes were deviated to the left when the left hand manipulated objects and that this deviation did not change with motor learning. We interpreted this as evidence that the right hemisphere controlled the acquisition of the skill (Kinsbourne, 1972).

Drawing and writing with the left hand (Figure 4)

In drawing and writing with the left hand the patient preferred the left half of the page, but the lateralization was less marked than with the right hand. Asked to draw with the left hand whatever she wanted, she named one object, but drew another, which was most often a human figure, sometimes a flower, a spiral, a "3", a "5" or a "C". The same thing happened when the object to draw was named by the examiner, or when the patient was asked to write. She made recognizable

Fig. 4 — Graphic performances of the left hand. Left column: A drawing session started with a copy of the Rey Osterrieth figure, which developed into an aberrant design resembling a human figure. In further trials the left hand drew manikins when the patient was demanded to copy simple geometrical designs; in another session (upper right column) these were copied adequately with the exception of the star and the cross, whose execution was succeeded only after three trials. Lower right: Two copies of the same model of a human figure and two copies of differently drawn human faces show the stereotypy of the left hand's designs. A right-handed copy of the face in half profile stresses exactly the details (ears, hairs, nose) which the left hand has disregarded. Bottom right: Copy of a word and of single letters.



copies of meaningless simple line drawings or of geometrical figures, but had difficulties to draw straight lines and sharp angles. Meaningful designs — a human figure, a face — were reproduced in a stereotyped manner regardless of the particular features of the individual model. Asked to copy letters or numbers, the patient did write letters or numbers, but they were most often different ones. On a typewriter she tapped the letter randomly.

When the drawing sessions took a long time, her performances became persevering and stereotyped and lost their relation to the model, but even in earlier stages and between two successful copies it happened that she drew a design which had nothing in common with the model she was to copy. The aberrant designs all belonged to the small repertoire which she employed in spontaneous drawing, and they were more likely to occur when the sample was either rectangular or rather complicated to draw for any graphically inexperienced person.

Bimanual coordination

When the patient was asked to transfer an object from the left to the right hand, the left hand often withdrew the object and held it tight, forcing the right hand to struggle to get it. When, however, the examiner approached his hand, the



Fig. 5 — *The left hand retrieves a pen from the patient's right hand but gives it deliberately to the examiner, regardless of whether she approaches from the left or from the right.*

left hand came towards it and deliberately gave the object it had previously retained (Figure 5). Withdrawal of the object held in the left hand sometimes disturbed the otherwise correct coordination of actions usually performed in a bimanual manner, as cutting a paper or sewing.

Lighting a candle

When a matchbox was placed in the patient's left hand, she succeeded in taking out a match, striking it, and lighting a candle, but occasionally the left hand closed the box while the right index was still in it about to pull out the match.

When the box was put in the right hand, the left hand made no attempt to get out a match. When the unlighted match was placed in the left hand, she put it in her mouth. The left hand continued to finger it, but could not get it out again. Eventually the right hand approached the matchbox to rub on the match.

When a burning match was given to the patient's left hand, she held it without bringing it to the candle and let it burn down to her fingers.

A jar and a drinking glass

The patient was asked to pour water into the glass. When the jar was given to her left hand, she drank out of it. When the jar was given to her right hand, the left hand touched the other side of it, and with a coordinated action of both hands she brought the jar to the mouth and drank again. When the left hand was prevented from interfering the right hand poured water into the drinking glass.

The patient uttered verbally her discontent over faulty performance of the left hand and sometimes tried to interfere with the right hand in order to hinder or rectify actions of the left hand. Being amnesic she confabulated about the symptoms and circumstances of her illness, but when asked whether there was something wrong with her hand, she would respond with some regularity that it disobeyed her. She often referred to her left hand as if it were a nasty child who "always pursues his will until he gets punished", but she insisted that it was her own hand and denied any feeling of strangeness (Brion and Jedynak, 1972).

DISCUSSION

Table I gives an overview of reported cases of left sided apraxia following destruction of the corpus callosum by ischemia or tumor. All of them had additional lesions to either the left or the right or to both medial frontal lobes.

We will now consider the possible contributions of right and left frontal lobe damage to the movement disorder in our case:

Damage to the right medial frontal lobe

The only detailed description of left sided apraxia with an exclusively right sided lesion was that of Goldstein (1908, 1909). In apraxia testing of this patient, the prevailing type of error was absence of any movement or abortive movements, which sometimes gave suddenly way to a slow but correct performance.

Hypokinesia of the contralateral extremities surmountable by a strong voluntary effort has been observed as a transient symptom of predominantly right-sided lesions that involve subcortical and medial parts of the frontal lobe but not the corpus callosum (Laplane and Degos, 1983). Lack of any apparent intention to initiate movement was the predominant failure in apraxia testing of our patient during the first month of observation, but at the same time spontaneous motility was preserved and gave rise to movements that might closely resemble those demanded in apraxia testing. This dissociation of automatic and propositional movements is characteristic of apraxia (Liepmann, 1908; Geschwind, 1975), but it is the reverse of what is observed in hypokinesia due to contralateral frontal lesions (Laplane and Degos, 1983).

Even in the presence of intact callosal connections, lesions of the medial frontal lobe can lead to motor perseverations and forced grasping of the contralateral hand which, being out of voluntary control, may result in intermanual conflict (Adie and Critchley, 1927; Goldberg et al., 1981; Gelmers, 1983), and there are reports of extracallosal right brain damage in patients who complain of persistent intermanual conflict after surgical dissection of the corpus callosum (Zaidel and Sperry, 1977, case W.J.; Akelaitis, 1945, case

TABLE I
Reported cases of callosal apraxia in right handers

	Additional lesion		Left-sided apraxia			Tonic grasping	Intermanual conflict
	Left frontal	Right frontal	On verbal command	In imitation	In object use		
Van Vleuten, 1907	+		+	+	+	R	
Liepmann and Maas, 1907	+		+	+	+		
Maas, 1907	+		+	*			
Bonhoeffer, 1914	+		+	+	+	R	+***
Hoff, 1931	+		+	+	?	R	
Sweet, 1941	+		+	+		R	
Geschwind and Kaplan, 1961	+		+			R	
Goldstein, 1908, 1909		+	+	+	+	L	+
Pineas, 1924		+	+	?	?	L	
Hartmann, 1907 (case 2)	+	+	+	+	+		
Klein and Ingram, 1958	+	+	+	+	+		+
Watson and Heilman, 1983	+	+	+	+	+	L	+

R = Symptom present in the right hand, L = Symptom present in the left hand.

*Limitation of gestures was not examined, but agraphia did not improve with copying.

** No autopsy reported, but there was paresis of the right leg and transient aphonia.

*** caused by forced grasping of the right hand and a left hand's tendency to bring objects to the mouth.

**** Because of parapraxias in right handed writing, word finding difficulties, and forced grasping and tremor of the right hand, the author felt, that the lesion had involved the left frontal lobe; autopsy, however, revealed only bilateral lacunes of the infero-callosal gyri cinguli in addition to the callosal destruction.

1).² But in contrast to patients with contralateral medio-frontal lesions and intact callosal connections, the left hand of our patient as well as those of Goldsteins's (1908) and of Watson and Heilman's (1983) patients not only grasped the object but withdrew it away from the right hand. Our patient's left hand behavior to withhold objects from her right hand, but to give them readily to the examiner's hand — regardless which hand and from what direction he approached — invokes a right hemisphere's recognition of the patient's self (Sperry, Zaidel and Zaidel, 1979) which goes above and beyond a purely reflex level of motor control.

The left hand's tendency to bring objects to the mouth appears to be a primitive mechanism indicating diffuse right brain damage, but it has been observed in patients whose right hemisphere was intact (Bonhoeffer, 1914; Liepmann and Maas, 1907). This would rather point to disinhibition of an impulse originating in the intact right hemisphere.

Damage to the left medial frontal lobe

Stimulation of the supplementary motor area on the medial surface of the frontal lobe may elicit bilateral limb movements (Penfield and Welch, 1951). Bilateral SMA activation in unimanual complex motor tasks has been shown by measurement of cerebral blood flow in man (Roland et al., 1980a, 1980b) and by single neuron recording in monkeys (Brinkman and Porter, 1979). Though a great part of the SMA-motor control is exerted via cortico-cortical connections to the primary motor area (Tanji and Kurata, 1982; Eccles, 1983) and is abolished with excision of the precentral motor cortex (Penfield and Welch, 1951), there is now increasing evidence for a direct corticospinal pathway from the SMA (Woolsey, 1975; Macpherson, Wiesendanger, Maragoz and Miles, 1982a, 1982b) which projects bilaterally to spinal motor neurons of predominantly proximal muscles (Brinkman and Porter, 1979). Neither pyramidotomy nor extended precentral and frontal ablations abolish ipsilateral motor control, but the latter lesions, which encroach upon the SMA, impair the accuracy of ipsilaterally guided reaching movements (Brinkman and Kuypers, 1973). The SMA thus appears as a plausible candidate for being a major source of direct ipsilateral motor control. Its function as a supramotor area which initiates and coordinates complex motor programs via its connections to the primary motor area (Orgogozo and Larsen, 1979; Roland et al., 1980a, 1980b; Tanji and Kurata, 1982; Eccles, 1983) rather supports the assumption of additional direct efferences to bilateral proximal muscles, since they would enable the SMA to provide in an economical manner the postural background to the complex actions it controls via its cortico-cortical connections.

A lesion of the left SMA or of its cortico-spinal efferences should then produce a deficit in ipsilateral motor control, which may not only deprive the left limbs of a means to compensate the lack of callosal transfer, but may also impair movements whose execution has been aided by ipsilateral motor efferences from the dominant hemisphere already in the presence of an intact corpus callosum.

Ipsilateral motor control may, however, be effected by parallel acting systems whose fibers originate from different cortical areas and whose respective acti-

² Poncet et al. (1978) reported the case of a left-handed girl who had destruction of the left frontal lobe in addition to callosal damage and who complained of antagonistic actions of the right hand.

vation depends on the modality of the task (Zaidel and Sperry, 1977; Creutzfeld, 1983). In our case left ipsilateral motor control appeared to be poor or absent on kinesthetic afference via the right limbs. If the adequate performance of a movement on verbal command is taken as evidence for an activity of left hemispheric motor control, then the better results in verbal apraxia testing of the left limbs and the largely intact verbal control of bilateral eye and face movements indicate, that for these tasks left ipsilateral motor control was more effective. It may have been exerted by fibers which originate directly from the speech areas or closely surrounding structures (Geschwind, 1975).

CONCLUSIONS

Our patient presented unilateral apraxia of the left limbs on verbal command, imitation, and actual object use following an approximately symmetric lesion. This cannot be explained without assuming an asymmetry in the motor control capacities of both hemispheres which involves not only the performance of movements on verbal command, but also the imitation of movement and the manipulation of objects. The eupraxia of the right hand proves the superiority of the left hemisphere in all these regards.

Our interpretation of the respective contributions of right and left frontal damage to the apraxia further stresses the motor dominance of the left hemisphere in pointing out that left frontal damage further deteriorated the performances of the left limbs by impairing an alternative pathway of left hemisphere motor control.

The motor effects of right frontal damage did not manifest themselves as apraxia. Right brain damage may however have contributed to the poor results of motor learning of the right hemisphere and may thus have impaired its ability to compensate for the lack of interhemispheric transfer.

ABSTRACT

A 40 year old right-handed woman suffered hemorrhage from an anterior cerebral artery aneurysm. CT scan showed destruction of the anterior two thirds of the corpus callosum, both cingulate gyri, and the white matter underlying the medial frontal lobes. The left limbs displayed apraxia on verbal command, in imitation, and in actual object use. There were antagonistic actions of both hands, and the patient accused her left hand of disobeying her. We interpret the left-sided apraxia as resulting from a lack of interhemispheric transfer combined with a deficit in ipsilateral motor control stemming from damage to the left supplementary motor area. Right frontal lobe damage may have impaired the motor learning capacity of the right hemisphere and thus its ability to compensate for the lack of left hemisphere motor control.

Acknowledgements. We wish to express our gratitude to Professor Norman Geschwind for his helpful criticism and comments, and we thank Dr. Willi Kieffer for improving the English.

REFERENCES

- AKELAITIS, A.J. Studies on the corpus callosum IV: Diagonistic dyspraxia in epileptics following partial and complete section of the corpus callosum. *Amer. J. Psych.*, 101: 594-599, 1945.
- ADIE, W.J., and CRITCHLEY, M. Forced grasping and groping. *Brain*, 50: 142-170, 1927.
- AJURIAGUERRA, J. DE, HÉCAEN, H., and ANGELERGUES, R., Les apraxies. Variétés cliniques et lateralisation lésionnelle. *Rev. Neurol.*, 102: 566-591, 1960.
- BONHOEFFER, K. Klinischer und anatomischer Befund zur Lehre von der Apraxie und der "motorischen Sprachbahn". *MSchr. Psych. Neurol.*, 35: 113-128, 1914.
- BRINKMAN, J., and KUYPERS, H.G.J.M. Cerebral control of contralateral and ipsilateral arm, hand and finger movements in the split-brain rhesus monkey. *Brain*, 96: 653-674, 1973.
- BRINKMAN, J., and PORTER, R. Supplementary motor area in the monkey: Activity of neurons during performance of a learned motor task. *J. Neurophys.*, 42: 681-709, 1979.
- BRION, S., and JEDYNAK C.P. Troubles du transfer interhémisphérique (callosal disconnection). A propos de trois observations de tumeurs du corps calleux. Le signe de la main étrangère. *Rev. Neurol.*, 126: 257-266, 1972.
- CREUTZFELD, O.D. *Cortex cerebri*. Berlin, Heidelberg, New York: Springer, 1983.
- DE RENZI, E., MOTTI, F., and NICHELLI, P. Imitating gestures — a quantitative approach to ideomotor apraxia. *Arch. Neurol.*, 37: 6-10, 1980.
- ECCLES, J.C. The initiation of voluntary movements by the supplementary motor area. *Arch. Psych. Nervenkr.*, 31: 423-441, 1982.
- GAZZANIGA, M.S. *The Bisected Brain*. New York: Appleton-Century Crofts, 1970.
- GAZZANIGA, M.S., BOGEN, J.E., and SPERRY, R.W. Dyspraxia following division of the cerebral commissures. *Arch. Neurol.*, 16: 606-612, 1967.
- GELMERS, H.J. Non paralytic motor disturbances and speech disorders: The role of the supplementary motor area. *J. Neurol. Neurosurg. Psych.*, 46: 1052-1054, 1983.
- GESCHWIND, N., and KAPLAN, E.A. A human cerebral deconnection syndrome. *Neurology*, 12: 675-685, 1962.
- GOLDBERG, G., MAYER, H.N., and TOGLIA, J.U. Medial frontal cortex infarction and the alien hand sign. *Arch. Neurol.*, 38: 683-686, 1981.
- GOLDSTEIN, K. Zur Lehre von der motorischen Apraxie. *J. Psychol. Neurol.*, 11: 169-187, 270-283, 1908.
- GOLDSTEIN, K. Der makroskopische Hirnbefund in einem Fall von linksseitiger Apraxie. *Neurol. Cbl.*, 28: 898-906, 1909.
- GOODGLASS, H., and KAPLAN, E. Disturbance of gesture and pantomime in aphasia. *Brain*, 86: 703-720, 1963.
- HARTMANN, F. Beiträge zur Apraxielehre. *MSchr. Psych. Neurol.*, 21: 97-108, 1907.
- HOFF, F. Balkentumor mit linksseitiger Astereognosis und Apraxie. *D. Zschr. f. Neuropsychiat.*, 123: 89-100, 1931.
- KIMURA, D., and ARCHIBALD, Y. Motor functions of the left hemisphere. *Brain*, 97: 337-350, 1974.
- KINSBOURNE, M. Eye and head turning indicates cerebral lateralization. *Science*, 176: 539-545, 1972.
- KLEIN, R., and INGRAM, I.M. Functional disorganization of the left limbs in a tumor of the corpus callosum infiltrating the hemispheres. *J. Ment. Sci.*, 104: 732-742, 1958.
- KOLB, B., and MILNER, B. Performance of complex arm and facial movements after focal brain lesions. *Neuropsychologia*, 19: 491-503, 1981.
- LAPLANE, D., and DEGOS, J.D. Motor neglect. *J. Neurol. Neurosurg. Psychiat.*, 46: 152-158, 1983.
- LIEPMANN, H. *Drei Aufsätze aus dem Apraxiegebiet*. Berlin: Karger, 1908.
- LIEPMANN, H., and MAAS, O. Fall von linksseitiger Agraphie und Apraxie bei rechtsseitiger Lähmung. *J. Psychol. Neurol.*, 10: 214-227, 1907.

- LURIA, A.J. *Higher Cortical Function in Man*. New York: Basic Books, 1980.
- MAAS, O. Ein Fall von linksseitiger Apraxie und Agraphie. *Neurol. Cbl.*, 26: 789-792, 1907.
- MACPHERSON, J., WIESENDANGER, M., MARANGOZ, C., and MILES, T.S. Corticospinal neurons of the supplementary motor area in the monkey. *Exp. Brain Res.*, 48: 81-88, 1982a.
- MACPHERSON, J., MARANGOZ, C., MILES, T.S., and WIESENDANGER, M. Microstimulation of the supplementary motor area (SMA) in the awake monkey. *Exp. Brain Res.*, 45: 410-416, 1982b.
- OOGOGOZO, J.M., and LARSEN, B. Activation of the supplementary motor area during voluntary movement in man suggests it works as a supramotor area. *Science*, 206: 847-850, 1979.
- PENFIELD, W., and WELCH, K. The supplementary motor area of the cerebral cortex. *Arch. Neurol. Psych.*, 66: 118-136, 1951.
- PINEAS, J. Ein Fall von linksseitiger motorischer Apraxie nach Balkenerweichung. *Msschr. Psychol. Neurol.*, 56: 43-46.
- PONCET, M., ALI CHÉRIF, A., CHOUX, M., BOUDOURESQUES, J., and LHERMITTE, F. Etude neuropsychologique d'un syndrome de déconnexion calleuse totale avec hémianopsie latérale homonyme droite. *Rev. Neurol.*, 134: 633-653, 1978.
- ROLAND, P.E., LARSEN, B., LASSEN, N.A., and SKINHOJ, E. Supplementary motor area and other cortical areas in the organization of voluntary movements in man. *J. Neurophysiol.*, 43: 118-136, 1980a.
- ROLAND, P.E., SKINHOJ, E., LASSEN, N.A., and LARSEN, B. Different cortical areas in man in organization of voluntary movements in extrapersonal space. *J. Neurophysiol.*, 43: 137-150, 1980b.
- SPERRY, R.W., ZAIDEL, E., and ZAIDEL, D. Self-recognition and social awareness in the disconnected minor hemisphere. *Neuropsychologia*, 17: 153-166, 1979.
- SWEET, W.H. Seeping intracranial aneurysm simulating neoplasm. Syndrome of the corpus callosum. *Arch. Neurol. Psych.*, 45: 86-104, 1941.
- TANJI, J., and KURATA, K. Comparison of movement-related activity in two cortical motor areas of primates. *J. Neurophys.*, 48: 633-653, 1982.
- VAN VLEUTEN, C.F. Linksseitige motorische Apraxie — Ein Beitrag zur Physiologie des Balkens. *Z.f. Psychiatrie*, 64: 203-239, 1907.
- WATSON, R.T., and HEILMAN, K.M. Callosal apraxia. *Brain*, 106: 391-403, 1983.
- WOOLSEY, C.N. Cortical motor map of macaca mulatta after chronic section of the medullary pyramid. In K.J. Zülch, O.D. Creutzfeld, G.C. Galbraith (Ed.), *Cerebral Localization*. Berlin, Heidelberg, New York: Springer, 1975.
- ZAIDEL, D., and SPERRY, R.W. Some long term motor effects of cerebral commissurotomy in man. *Neuropsychologia*, 15: 193-204, 1977.