

CROSSED APHASIA: ONE OR MORE SYNDROMES?

**Anna Basso*, Erminio Capitani **, Marcella Laiacona
and Maria Ester Zanobio**

(Neuropsychology Centre, *Istituto di Clinica Neurologica, and **Clinica
Neurologica I of Milan University)

INTRODUCTION

In recent years a few cases of crossed aphasia (CA) have been published (Yarnell, 1981; Carr, Jacobson and Boller, 1981; Assal, Perentes and Deruaz, 1981; Denes and Caviezel, 1981; Puel et al., 1982; Henderson, 1983) but the syndrome is still rare and many aspects remain a matter of dispute. It has been held that right-handed patients whose right hemisphere is language dominant show a pattern of organization different from that present in normal right-handers (Angelergues, Hécaen, Djindjian and Jarrié-Hazan, 1962; Brown and Hécaen, 1976; Urbain et al., 1978) as pointed out by the fact that, regardless of the locus of lesion, their aphasia is non fluent, characterized by agrammatism, moderately impaired comprehension and good recovery.

This view is challenged by other authors who have reported in CA aphasic syndromes similar to those seen following a lesion of the dominant left hemisphere and compatible with the locus of the lesion (Carr et al., 1981; Henderson, 1983). More recently it was suggested that there is a relationship between the occurrence of CA and involvement of deep structures whose functional organization may well be less lateralized than those of cortical structures (Habib, Joannette, Ali-Cherif and Poncet, 1983).

Visuo-spatial disorders in CA patients have attracted less attention and have not always been reported.

This paper describes seven right-handed patients with persistent language disturbances following right cerebral infarct or hematoma confirmed by computerized tomography. We have tried to correlate their language disturbances with the locus of the damage and with the standard aphasic syndromes seen in left-hemisphere-brain-damaged patients.

MATERIALS AND METHODS

Subjects

1439 records of patients examined in the Aphasia Unit of Milan University Neurological Clinic between January 1976 and February 1984 were reviewed. Patients conforming to the following conditions were selected for further study: (1) Right-handedness according to the Edinburgh Inventory (Oldfield, 1971) (minimum score 10/12 and no history of left-handedness in ascendency); (2) at least three years of schooling; (3) unilingual; (4) no previous lesion of the central nervous system; (5) a right vascular lesion ascertained by CT scan and (6) clear aphasic symptoms. Seven patients fulfilled these conditions.

Tests and Procedures

Subjects were examined with the following tests:

Aphasia testing: a Standard Language Examination (Basso, Capitani and Vignolo, 1979) currently in use in our Aphasia Unit.

Token Test: a shortened version of the Token Test (De Renzi and Faglioni, 1978) with 36 items and a cut off score for normals of 29 correct responses.

Raven's Coloured Progressive Matrices 47 (PM): administered with a time limit of 10' (Basso, De Renzi, Faglioni, Scotti and Spinnler, 1973). The mean score found in 119 normal controls is 29.09 ± 5.50 with only 5% of the controls scoring less than 17.

Oral apraxia (OA): evaluated with a 10-item test requiring the execution of movements of the buccofacial apparatus (De Renzi, Pieczuro and Vignolo, 1966). Cut off score: 16 out of a maximum score of 20.

Ideomotor apraxia (IMA): evaluated with two different tests. Until 1980 a 10-item test was used (De Renzi, Pieczuro and Vignolo, 1968). Patients were required to imitate 10 single movements with the hand ipsilateral to the lesion. Cut off score: 17/20. Since 1980 a new test has been introduced (De Renzi, Motti and Nichelli, 1980), consisting of 24 movements of the whole arm or fingers, single or in sequences, meaningful or meaningless, which the patient had to imitate with the hand ipsilateral to the lesion. Cut off score: 53/74 (De Renzi, Faglioni and Sorgato, 1982).

Apraxia of use (AU): evaluated with a 7-item test requiring the use of 7 different objects (De Renzi, Pieczuro and Vignolo, 1968). Cut off score: 14/14.

Constructional apraxia (CAp): evaluated by asking the patient to reproduce 10 geometrical figures (Arrigoni and De Renzi, 1964). Cut off score: 15/20.

Acalculia: patients were asked to execute simple written additions, subtractions, divisions and multiplications (Basso and Capitani, 1979). Cut off score: 74/101.

CASE SUMMARIES

The sex, age, etiology, site of lesion, time post onset, type of aphasia and results of the various tests for the seven CA patients are given in Table I.

TABLE I
Clinical Data and Test Results of the Seven CA Patients in the Various Examinations

Case	Sex	Age	Schooling	Site of lesion	Hemiparesis	Hemianopia	Days post-onset	Aphasia type	TT	OA	IMA	AU	CAP	PM	Acalculia	Position preference
I	F	64	5	Middle frontal and precentral gyri; anterior limb of internal capsule	-	-	22 462	Broca	30 31	18 17	20/20 18/20	14 14	12* 15	23 26	70*	-
II	F	53	8	Inferior and middle frontal, central and post-central gyri	-	-	15 116	Wernicke	16* 29	15* 20	20/20 20/20	14 14	18 18	11* 27	26*	+ -
III	M	55	6	Parietal and occipital lobe with mesial occipital cortex	-	+	82	Wernicke		19	34/72*	4*	2*			ULN
IV	F	63	5	Temporal and inferior parietal lobe	+	+	53 232 344	Wernicke	14* 24* 23*	12* 17 18	54/72 66/72 67/72	14 14 14	13* 16	15* 19 23	17* 36* 41*	- - -
V	F	49	5	Frontal, temporal and parietal lobe	+	+	25 128	Agraphia	27* 27*	6* 9*	46/72* 55/72	14 14	12* 13*	9* 17	21* 26*	+ +
VI	M	56	8	Basal ganglia, insula and internal and external capsules	+	-	19 196	Wernicke	22* 35	16 20	61/72 71/72	14 14	18 18	13* 35	54* 104	-
VII	F	64	8	Frontal and temporal lobe	+	-	18 141	Broca	28* 31	20 18	60/72 68/72	14 14	9* 19	9* 25	95 105	+

TT = Token Test score; OA = oral apraxia score; IMA = ideomotor apraxia score; AU = apraxia of use score; CAP = constructional apraxia score; PM = Progressive Matrices score; ULN = unilateral neglect; + = present; - = absent; pathological scores are marked with an *.

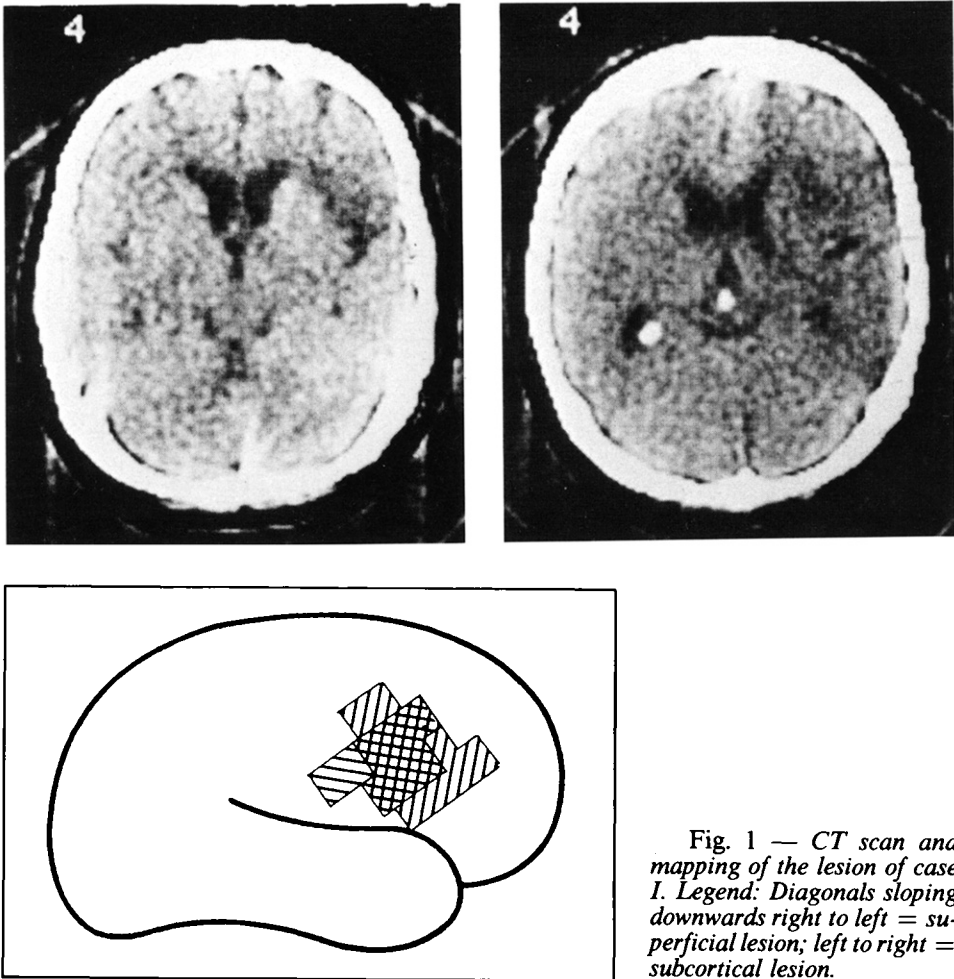


Fig. 1 — CT scan and mapping of the lesion of case I. Legend: Diagonals sloping downwards right to left = superficial lesion; left to right = subcortical lesion.

Case I

A 64-year-old woman with 5 years of schooling, retired shop-keeper had a stroke on June 1, 1977. She was admitted to another hospital with left upper limb paresis and unspecified aphasic disturbances. A second neurological examination performed twenty-two days later at the same time as the neuropsychological testing showed moderate cutaneous sensation defects in the left limbs. A CT scan performed 33 days after the stroke evidenced two areas of low density in the right hemisphere, one involving the middle frontal and precentral gyri and the other the anterior limb of the internal capsule (Figure 1). The Language Examination showed a fairly informative but reduced and slightly agrammatic verbal

output with some errors probably due to articulatory difficulties. Oral confrontation naming was 80% correct with a few anomias. Written expression (Figure 2) was much more impaired, with spelling errors ("aupobobilo" for "automobile", for example); writing a letter was nearly impossible as the patient refused to keep after the first four words. Auditory and written comprehension of single words and simple sentences were normal. So was her performance on the Token Test, on which she scored 30. Repetition and reading aloud of isolated words and sentences were good, but reading aloud of non-words was impaired. There were no praxic deficits except for a moderate CAP (12). On PM she scored 23. Acalculia was not tested for. In conclusion, the patient presented a mild Broca aphasia with writing more impaired than speech and with a moderate CAP. She did not undergo rehabilitation. A second Language Examination 14 months later was normal, without any evidence of aphasic deficits except for reduced output and a few paragraphic errors. There was mild CAP (15) and acalculia (70).

Fig. 2 — Written confrontation naming of cases I, II, V, VI.

TAVOLO (TABLE)	<i>Carabolo</i>	<i>il tavolo</i>	<i>tavolanna</i>	<i>stacolino</i>
OMBRELLO (UMBRELLA)	<i>Obio</i>	<i>il fiorello</i>	<i>algannbra</i>	<i>ombrello</i>
AUTOMOBILE (CAR)	<i>Aupobobilo</i>	<i>la barchetta</i>	<i>olbraunau</i>	<i>ol avienlene</i>
CILIEGIA (CHERRY)	<i>Ughiege</i>	<i>la barchetta</i>	<i>ceglaugia.</i>	<i>obblintre</i>
TAMBURO (DRUM)	<i>Debe</i>	<i>la lalobopetta</i>	<i>tau bianca</i>	<i>fonticello</i>
OCCHIALI (GLASSES)	<i>Ciek'</i>	<i>la occhiaraffi</i>	<i>olugugimiliao</i>	<i>obbiello</i>
PITTORE (PAINTER)	<i>Bijozzi</i>	<i>il gonocuffo</i>	<i>patienteuto</i>	<i>penoblenle</i>
OROLOGIO (WATCH)	<i>Orologio</i>	<i>la gonocuffe</i>	<i>obliquog.</i>	<i>obbiello</i>
BORSA (HANDBAG)	<i>B.B.</i>	<i>il febyerolopu</i>	<i>labbra</i>	<i>obruello</i>
LETTERA (LETTER)	<i>Busta</i>	<i>il monastotto</i>	<i>letienti</i>	<i>Vin</i>

Case II

A 53-year-old nun with 8 years of schooling, affected by diabetes mellitus, had a stroke with transient loss of consciousness on July 18, 1977. The previous day she had had a transient ischaemic attack with left central facial paresis and severe aphasia that improved in a few hours. On hospitalization the neurological examination showed only left central facial paresis, leftward deviation of the protruded tongue, and a severe aphasia without motor, sensory or visual field defects. Two weeks later a second neurological examination confirmed normal strength and cutaneous sensation in the left limbs and showed no deficits in the left visual field on confrontation. A CT-scan four days later showed a hypodense area involving the inferior and middle gyri of the right frontal lobe, partially extending to the central and postcentral gyri. Both gray and white matter were affected by the lesion. The right frontal horn was compressed and shifted leftward. A second CT-scan three months later (Figure 3) confirmed the site and extent of the previous lesion but the right frontal lobe was neither compressed nor shifted.

Fifteen days after the stroke the patient was tested. Oral expression was abundant but devoid of meaningful information because of frequent semantic paraphasias, word-finding difficulties and perseverations. On oral confrontation naming, she fluently produced verbal paraphasias, circumlocutions and perseverations correctly naming only one of twenty figures. Writing too was abundant, without semantic errors. In written confrontation naming, words were misspelled, often longer than the stimulus word (Figure 2) and for the most unrecognizable. Only the definite articles ("il", "lo", "la") were spelled correctly and were appropriate to the first letter of the following non-word. When trying to write a letter, she started correctly, but after a few words writing became completely incomprehensible because of misspellings. Orthographic rules were, however, observed. Writing to dictation was severely impaired, with many spelling errors. Auditory and written comprehension of single words and simple sentences were correct; however, she scored 16 on the Token Test. Repetition of isolated words and non-words was normal but in long sentences she sometimes omitted the last words. Reading aloud of isolated words and sentences was correct, but there was misreading of some non-words (2 out of 5). She had mild oral apraxia (15) but there was no IMA (20), UA (14) or CAp (18). On the PM she scored 11, with a position preference effect: 16 answers on the right and 6 on the left. The acalculia score was 26.

In conclusion, the patient presented a moderate Wernicke aphasia with many semantic errors in oral utterance and spelling errors in written tasks. Mild oral apraxia and acalculia were also present. The patient

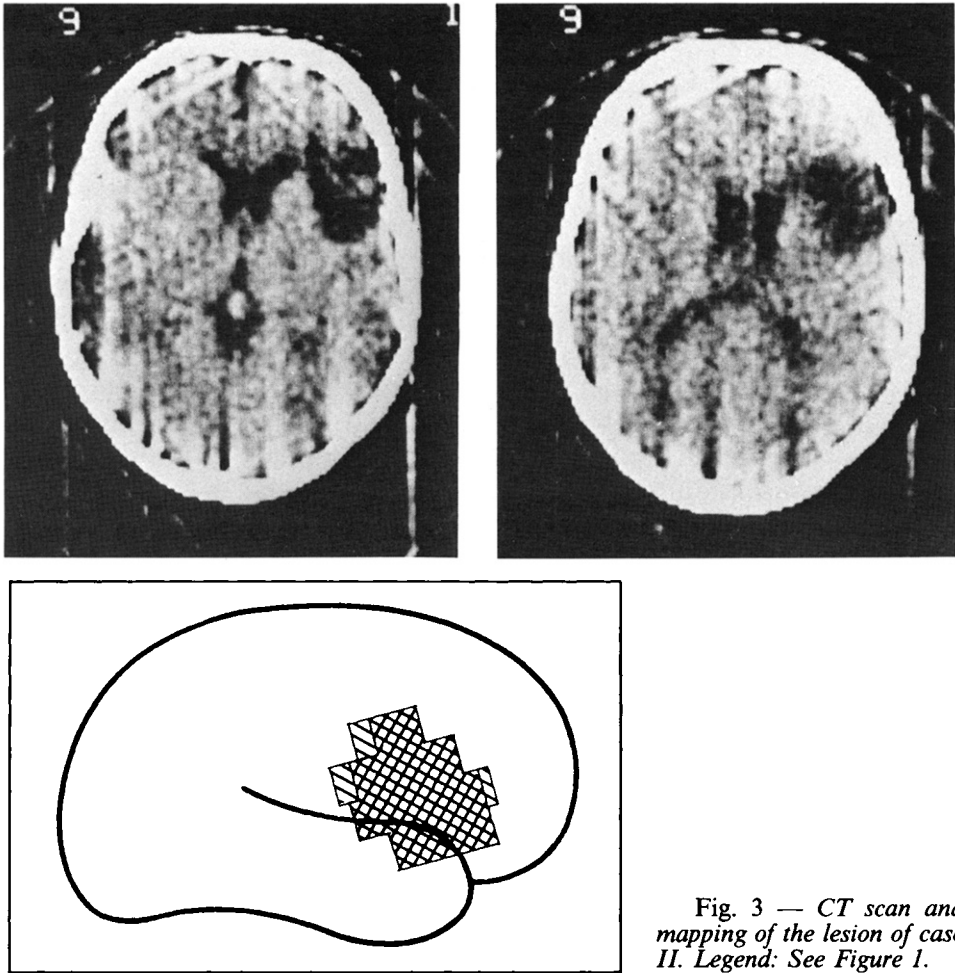


Fig. 3 — CT scan and mapping of the lesion of case II. Legend: See Figure 1.

underwent a three month course of rehabilitation. After 20 sessions therapy was discontinued because the patient had recovered. On a second language examination the performance was entirely normal: she scored 29 in the Token Test, her speech was informative, with no semantic paraphasias and no spelling errors in written confrontation naming or in letter writing. Oral apraxia was no longer present. Acalculia was not tested for.

Case III

A 55-year-old man with 6 years of schooling had a first stroke on December 1978. The neurological examination on admission to another

hospital showed severe temporo-spatial disorientation, aphasia and anosognosia; left hemianopia was also present, without motor or sensory deficits. Thirteen days later he suddenly developed a left hemiparesis that cleared in a few days and diplopia due to a deficit of the third cranial nerve. He was dismissed with diagnosis of Weber's syndrome. A CT-scan performed 80 days after the first stroke showed an area of low density in the distribution of the right posterior cerebral artery (Figure 4). The patient underwent a neuropsychological examination in March 1979. He had a severe unilateral neglect that rendered it impossible to test him adequately. Asked to cross out all the circles on a sheet he ignored all the circles on the left side; when trying to write he used only the right half of the sheet and never explored to the left. His oral output was fluent, with frequent verbal paraphasias ("picture" for "umbrella", "cat" for "cherries", "magician" for "lizard", for example) and perseverations; oral comprehension was sufficient for him to comprehend simple questions. Repetition of single words and sentences was correct. Copying and reading aloud were not attempted because of diplopia. Writing to dictation was severely affected, with spatial and spelling errors; he refused to write a letter but his signature was correct. He could not pass the Token Test or the PM, since he never explored the items on his left. He also could not pass a written calculation test, but responded correctly when asked to orally perform simple additions, subtractions, multiplications and divisions. He had no OA (19) but a severe IMA (34) his errors being generally due to perseveration of previous gestures. Asked to demonstrate the use of seven different objects he could use only two correctly. CAp was also present: he scored 2 on the CAp test.

In conclusion, the patient presented unilateral neglect, Wernicke aphasia, ideomotor and constructional apraxia and apraxia of use. The frequent perseverations and the presence of severe unilateral neglect, however, rendered it impossible to evaluate his deficits more precisely. The patient underwent rehabilitation directed at overcoming his neglect and compulsory perseverations. Seven months later he was unchanged and rehabilitation was discontinued.

Case IV

A 63-year-old housewife with 5 years of schooling and hypertension for 10 years, had a stroke without loss of consciousness on November 14, 1980. She was admitted to a hospital with aphasia and without evident motor defects. An EEG performed on December 1980 showed focal lesional activity in the right temporal lobe. A Doppler sonography did not show a carotidean or subclavian occlusion and a CT-scan showed a

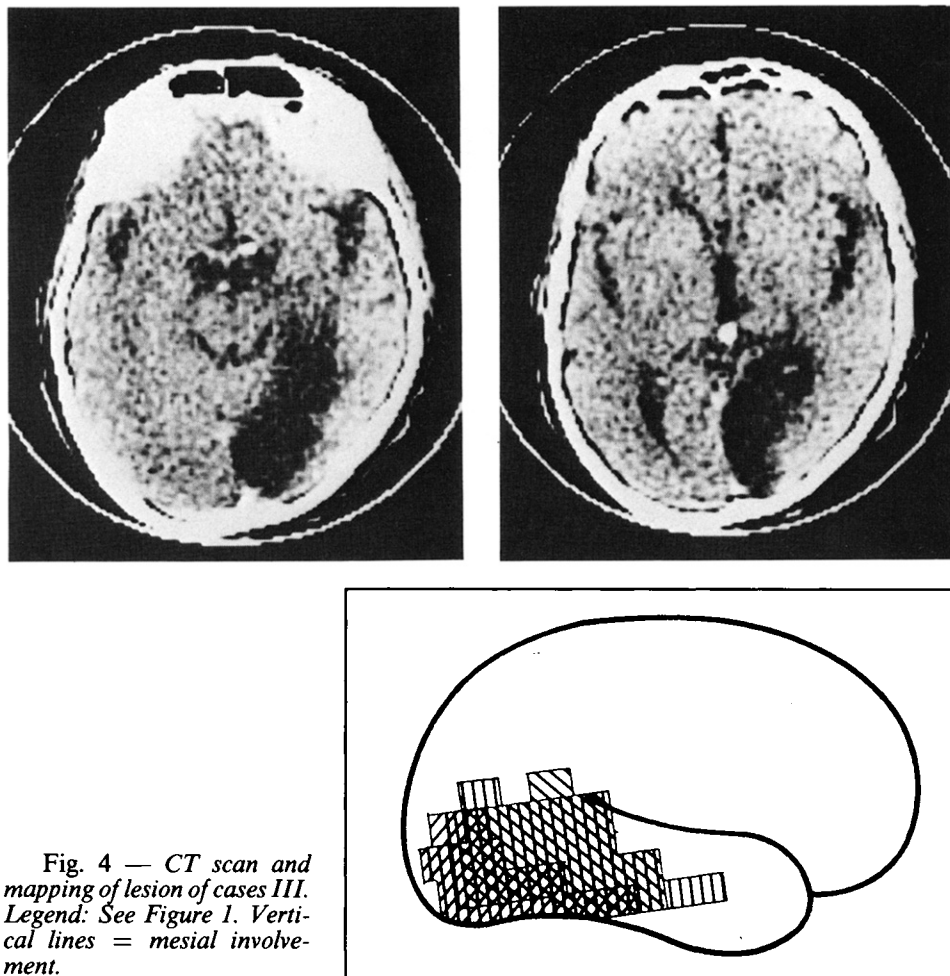


Fig. 4 — CT scan and mapping of lesion of cases III. Legend: See Figure 1. Vertical lines = mesial involvement.

temporoparietal infarct in the right hemisphere. Two months later a second CT-scan confirmed the localization of the hypodense area in the right anterior, middle and posterior temporal and inferior parietal regions. Both the gray and the white matter were affected by the lesion and the lateral ventriculi were slightly enlarged (the right more than the left) (Figure 5).

About two months after the original stroke a neurological examination showed a mild left hemiparesis and a mild ipsilateral hemianopia with normal cutaneous sensation. Fifty-three days after the stroke, she was given the Standard Language Examination. Oral expression was reduced, with frequent word finding difficulties, semantic paraphasias, a few inflectional errors and perseverations. Written expression was similarly

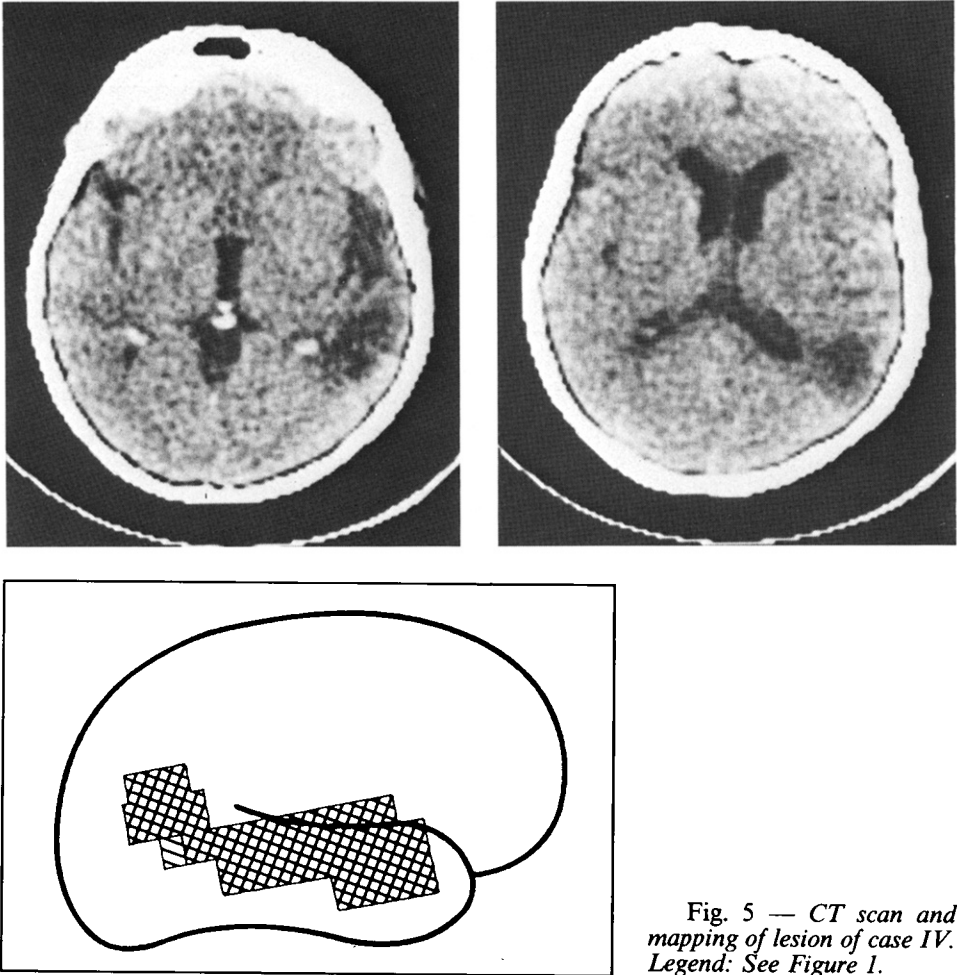


Fig. 5 — CT scan and mapping of lesion of case IV. Legend: See Figure 1.

affected, with some spelling errors and frequent semantic substitutions in the written confrontation naming task: she wrote “flower” for “lamp”, “school” for “car”, “watch” for “cherry”. Auditory and written comprehension of isolated words and simple commands were impaired. On the Token Test she scored 14. Repetition, reading aloud and writing to dictation were all affected. There were OA (12) and CAp (13) but not IMA (54) and UA (14). On the PM she scored 15, without position preference (12 choices in the right half and 11 in the left half of the display) and 17 on the Acalculia test.

In conclusion, the patient showed a severe Wernicke aphasia with verbal semantic errors in oral and written output, oral and constructional apraxia and acalculia. The patient underwent language rehabilitation for

six months. Eight months after the stroke she was given a second language examination that showed considerable improvement in all modalities. Oral and written expression were good, with some word finding difficulties and a few verbal errors some of which semantic. Auditory and written comprehension appeared adequate and she scored 24 on the Token Test. Reading aloud was normal, but repetition and writing of sentences to dictation were still somewhat impaired. She was still acalculic (36), but no longer apraxic.

CAP was not tested for. On the PM she scored 19. Language rehabilitation was continued to overcome word finding difficulties and four months later she was given a third language examination, with unchanged results. Word finding difficulties and auditory comprehension defects (Token Test = 23) were still present, as was acalculia (41). The patient decided to discontinue rehabilitation as she was completely self-sufficient in her everyday domestic life.

Case V

A 49-year-old housewife with 5 years of schooling on May 1981 had a stroke one month after a transitory ischaemic attack. She was immediately admitted to a neurological ward and presented left hemiparesis, hemianesthesia and hemianopia and rightward head and eye deviation. A neurological examination a month after the stroke showed a severe sensory-motor deficit in the upper left limb, a mild sensory-motor deficit in the lower left limb and hemianopia. A CT-scan performed the day after the stroke showed a fronto-temporo-parietal infarct in the right hemisphere that was confirmed by a second CT-scan four months later (Figure 6). She was given the Standard Language Examination 25 days post-onset. Oral expression was informative, with mild word finding difficulties for unfamiliar words and mild dysarthria (phonemes were articulated badly in a rather undifferentiated way). Oral confrontation naming was correct except for two phonemic paraphasias. On the contrary, spontaneous writing as well as writing to dictation were severely impaired and characterized by jargonagraphia (Figure 2). Auditory and written comprehension were good, but the patient had to be constantly reminded to consider the left half of the space when pointing to a figure named by the examiner. This, however, was not necessary during the execution of the Token Test, on which she scored 27. Repetition and reading aloud were correct for isolated words but not for sentences, in which she changed or omitted some words. There was OA (6), mild IMA (46) and CAP (12) but no UA (14). On the PM she scored 9, with position preference (30 pointings on

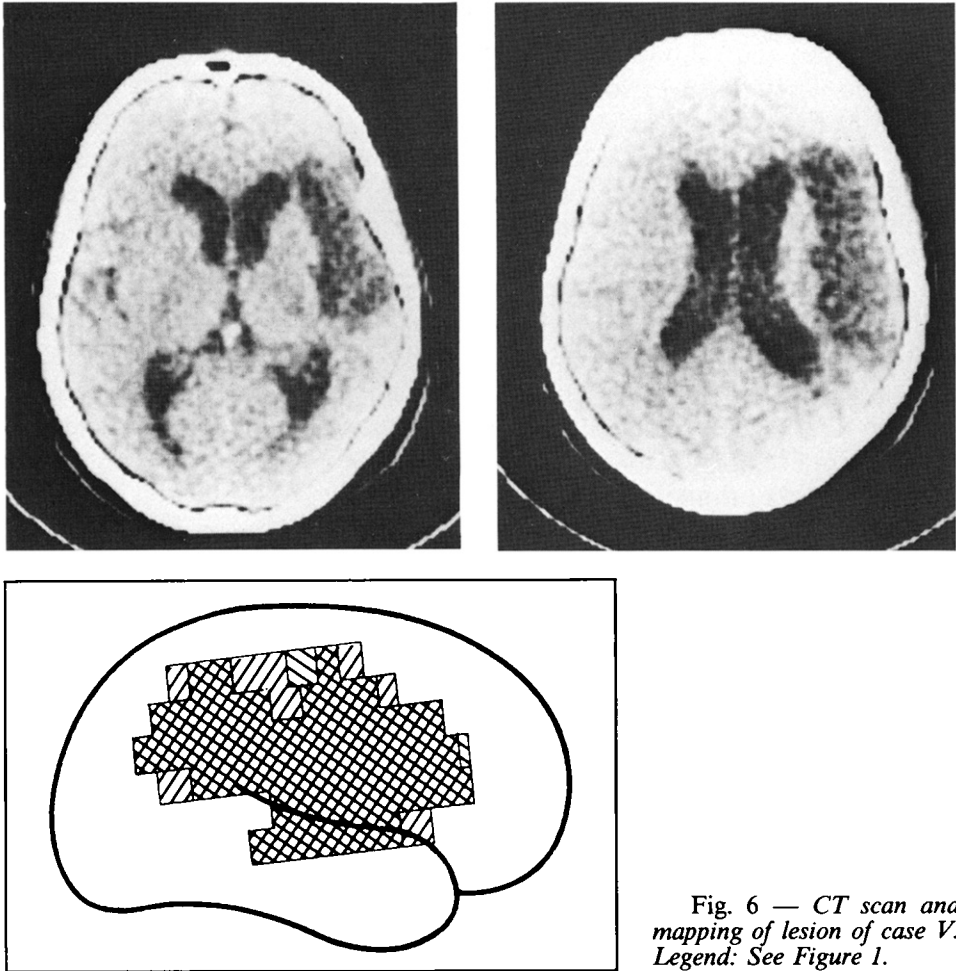


Fig. 6 — CT scan and mapping of lesion of case V. Legend: See Figure 1.

the right and 1 on the left of the display). Unilateral neglect was not evaluated with *ad hoc* tests. She scored 21 on the Acalculia test.

In conclusion, the patient showed a marked discrepancy between a very mild impairment in speech and a severe disruption of written expression. The patient did not undergo rehabilitation and three months later she was given a second language examination. Oral expression was good but speech was a little hesitant and slow. Spontaneous writing and writing to dictation were less abundant but still severely affected and there were many spelling errors that gave rise to non-words. Comprehension was good: she scored 27 on the Token Test. On reading aloud she sometimes substituted one word for another. There was OA (9) and CAP (13) but no IMA (55) or UA (14). On the PM she scored 17, with some

preference for the right half of the display (11 choices) over the left (6 choices). She scored 26 on the Acalculia test.

In conclusion, the performance of the patient had not much changed with respect to the first neuropsychological testing.

Case VI

A 56-year-old man, retired office clerk, with 8 years of schooling, on April 1982 had a stroke with loss of consciousness, left hemiparesis, hemianesthesia and aphasia. A CT-scan on the same day showed an intracerebral hematoma affecting the deep regions of the right hemisphere, including the basal ganglia, the insula and the internal and external capsules. He was admitted to a neurological ward and a neurological examination 19 days after the stroke showed a mild left hemiparesis and hemianesthesia. A second CT-scan two months later showed a mildly hypodense area in the region of the external capsule and basal ganglia (Figure 7).

The patient was given the Standard Language Examination 19 days after the stroke. Oral expression was poor, with frequent word finding difficulties and some phonemic paraphasias and phonemic groping, which were much more evident in a telling-of-an-event test than in confrontation naming. Spontaneous writing was severely impaired, with some spelling errors even in the rare words that were recognizable; on written confrontation naming (Figure 2) there were frequent neologisms that bore no resemblance to the stimulus word and resembled each other

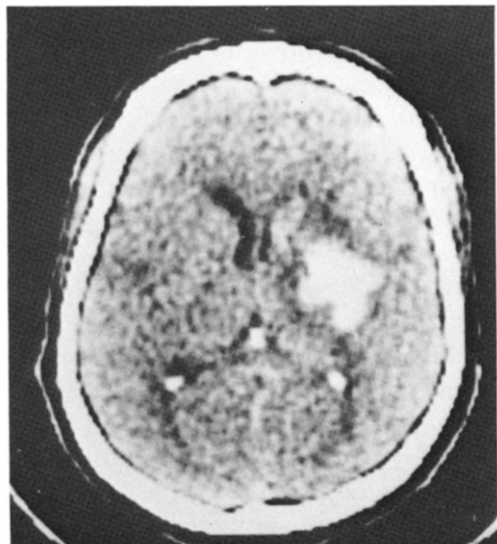


Fig. 7 — *CT scan of case VI.*

(for example: “obiello” for “orologio”, “briebbo” for “bilancia”, “biello” for “casa” and “piebbo” for “pesce”). Writing to dictation was a little better. Auditory and written comprehension were good for isolated words and simple sentences: he scored 22 on the Token Test. Repetition and reading aloud were normal. There were no praxic deficits.

The patient scored 13 on the PM and 54 on the Acalculia test. To sum up, the patient showed a mild fluent aphasia and agraphia, without other deficits.

He made a remarkable spontaneous recovery during the first month and 20 days after the first examination he scored 31 on the Token Test, but still presented frequent word finding difficulties. He underwent three months of language rehabilitation and seven months after the stroke was given a second language examination that proved to be normal apart from some word finding difficulties for uncommon words in spontaneous speech and a poor performance on the verbal fluency test. On both the Token Test and the PM he scored 35. Acalculia had cleared (104). There were no praxic deficits.

Case VII

A 64-year-old woman with 8 years of schooling, on May 30, 1982, suffered a stroke with transient loss of consciousness. The following day she was admitted to the Neurological Wards, with mild left hemiparesis, hemianesthesia, hemianopia and conjugate gaze deviation to the right. Left-side neglect and considerable reduction of spontaneous speech were mentioned in the clinical records. Eighteen days later a neurological examination showed only a mild sensory-motor deficit. Unilateral neglect partially cleared in a few days. A CT-scan three days after the stroke showed a medium size infarct in the right fronto-temporal region that was confirmed by a second CT-scan (Figure 8) carried out three months later. At the first language examination, 18 days after the stroke, oral expression was fairly informative and no longer reduced although agrammatic: articles and other function-words were omitted and verbs were in the infinitive form. Oral and written confrontation naming were correct. Auditory and written comprehension were good: she scored 28 on the Token Test. Repetition and reading aloud of isolated words were correct, with the occasional omission of function words in sentences. Spontaneous writing showed rare spelling errors and frequent incorrect use of function words but verbs were correctly conjugated. Writing to dictation was poor and she often repeated words (“the children go go children go to school”). Acalculia was not present (95) nor were praxic deficits. However she

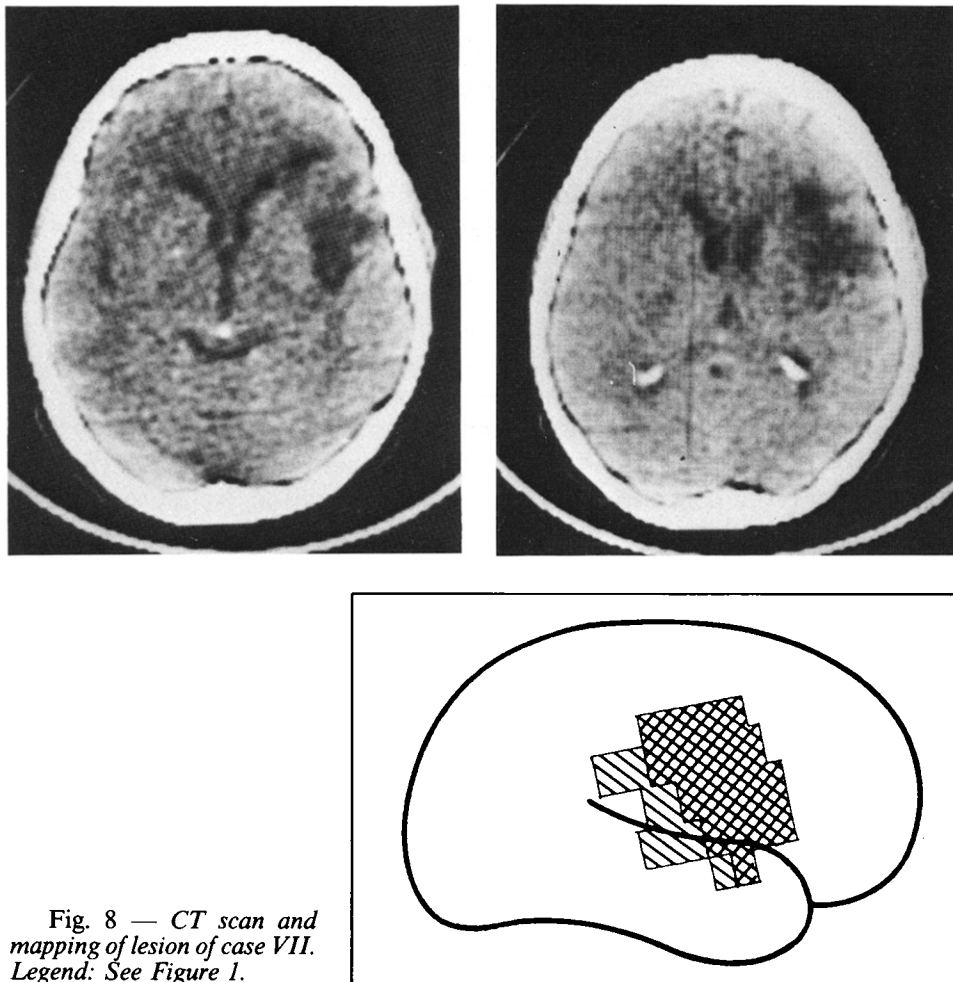


Fig. 8 — *CT scan and mapping of lesion of case VII.*
 Legend: See Figure 1.

showed severe constructional apraxia (9) and scored 9 on the CAP test.

A strong right position preference (29 versus 2) thwarted the performance on the PM (where she scored 9), but not that on the Token Test. Unfortunately, unilateral neglect was no further examined.

To sum up, the patient showed a mild Broca aphasia with agrammatism. She underwent language rehabilitation and four months later was given a second language examination that showed only mild agrammatism in oral expression and a good communicative capacity. The other neuropsychological deficits seen on first evaluation had cleared: on the PM the patient scored 25 (with 11 answers on the right and 11 on the left) and 19 on the CAP test.

DISCUSSION

Our cases seem to fit all the criteria necessary for correct diagnosis of CA and provide a data basis for discussing the issues related to the shifting of language dominance to the right hemisphere.

The main issue is whether CA constitutes a mirror picture of aphasia linked with left hemisphere disease or has distinguishing features, suggestive of a different organization of language functions when they are represented on the right hemisphere. Based on the similarity between the clinical pictures of CA and children aphasia, Brown and Hécaen (1976) advanced the view that both forms suggest a pattern of diffuse language representation and an earlier stage in the process of differentiation of function. Evidence for this assumption was sought in the finding that while left brain damage in the adult right handers produces discrete aphasic symptom complexes depending on its location, both CA patients and aphasic children would always show the same pattern of disorder characterized by reduced output, agrammatism and phonemic paraphasias. Fluent Wernicke aphasia, which is common in standard aphasics, would be extremely rare in crossed aphasics and aphasic children.

Our data undermine the validity of this construct. Two patients (cases I and VII) had Broca aphasia with agrammatism, three (cases II, IV and VI) Wernicke aphasia and one subject (case V) was agraphic with rare word finding difficulties. Case III too, had Wernicke aphasia but the presence of severe unilateral neglect prevented an adequate assessment of his language functions. Thus there is no basis for assimilating CA to children aphasia and contrasting it with standard aphasia. The lesion sites too are in most cases (cases I, III, IV and VII) what one would expect from classical teaching.

However, these patients were slightly different from prototypical left-hemisphere-brain-damaged patients with aphasia. To investigate the severity of their aphasia, as measured by the Token Test, we selected from a sample of sequentially admitted 867 left-hemisphere-brain-damaged patients those who could be matched with respect to etiology (i.e., ischaemic vs. hemorrhagic cerebrovascular accidents), sex, length of illness (maximum difference: 10 days) and type of aphasia, to each of six CA patients (case III has not been considered). The numbers of matchable subjects varied for each CA patient from 1 to 10. In each case, a paired Token Test score was calculated from the average of the matched subjects. Results are shown in Table II: CA patients always had higher Token Test scores. On this basis, it may be argued that more resources relevant to language comprehension are left undamaged in CA than in left-hemisphere-damaged aphasics, possibly due to a greater participation of the non-specialized hemisphere. With respect to the recovery rate of CA patients,

TABLE II

Token Test Scores of Six CA Cases and of 30 Left Brain-Damaged Aphasic Controls Matched for Sex, Etiology, Length of Illness and Type of Aphasia

Case	Sex	Etiology	Days post-onset	Aphasia type	TT	Matched controls (number of subjects)	Mean TT score
I	F	Infarct	22	Broca	30		
VII	F	Infarct	18	Broca	28	8	13.62
II	F	Infarct	15	Wernicke	16	10	13.90
IV	F	Infarct	53	Wernicke	14	4	9.00
V	F	Infarct	25	Agraphia	27	1	24.00
VI	M	Hemorrhage	19	Wernicke	22	7	16.57
Mean Token Test score					22.83 ± 6.07		15.12 ± 4.55

Student's $t=2.27$; $d.f. = 10$; $p < .05$.

no reliable comparison with left hemisphere damaged aphasics could be made, due to the impossibility of matching subjects of the two groups properly.

Another difference which is worth stressing is the frequent dissociation between oral and written expression found in our cases: four patients (cases I, V, VI and VII) were much more severely compromised in their written output, which was totally incomprehensible in two (cases V and VI) of the three patients whose oral expression was less impaired. Moreover, case II, whose oral and written output were equally impaired, made frequent semantic substitutions in her oral expression while her writing was characterized by non-words. The relationship between written language and language lateralization has been considered by a number of papers. Wechsler (1976) reported a case of an illiterate CA patient and advanced the hypothesis that the integrity of neural mechanisms involved in learning written language is necessary for the complete establishment and maintenance of language dominance. Gloning (1977) compared 75 right-handed and 57 non-right-handed patients with similar lesions in one cerebral hemisphere and found a significant influence of the location of the writing hand, in that patients who wrote with the hand ipsilateral to the lesion were significantly less impaired in reading and writing than those who wrote with the hand contralateral to the lesion. Erkulvawatr (1978) also describes a non-right-handed patient with alexia and mild agraphia after a right occipital infarction; an injection of Amytal Sodium into the left, but not into the right, common carotid artery rendered the patient aphasic for several minutes, suggesting that speech was located in

the left hemisphere and reading and writing in the right hemisphere. We have no explanation for why our patients often had writing more impaired than oral language. We can only say that this is not a new finding. Pillon, Desi and Lhermitte's (1979) two CA cases also had more severely impaired written than oral language, particularly case I. The hypothesis put forward by Wechsler (1976) postulates that writing with the right hand contributes to a leftward transfer of all the language modalities from an early bilateral representation; if the lateralization process is not completed, we should expect the written language, being the leading modality for left-sided lateralization, to be more strongly left represented than the other aspects of language, and consequently to be less damaged after right hemisphere lesions. Unfortunately for this hypothesis, however, many observations can now be found to show the opposite pattern of dissociation.

The location of the lesions in our patient does not confirm Habib et al.'s (1983) hypothesis of the importance of deep structures in the genesis of CA. In five cases, the lesion had spared all the deep structures, in one it encroached on the internal capsule and only in case VI was the lesion confined to the basal ganglia. This patient had a deep lesions affecting the basal ganglia, the insula and the internal and external capsules, and presented with a picture of Wernicke aphasia. Case V had a large fronto-temporo-parietal lesion which essentially spared Wernicke's area. In the language examination, she disclosed mild word finding difficulties in her oral expression and a severe agraphia which remained unchanged in a second examination three months later. In case II, the CT clinical correlation was rather unexpected: a fluent aphasia with semantic errors was associated with an anterior lesion that spared all the posterior language areas. The occurrence of fluent aphasia with anterior lesion is certainly rare, but a few cases have been reported. Basso, Lecours, Moraschini and Vanier (1985) found seven patients with anterior left hemisphere lesion and fluent aphasia in a sample of 35 right-handed patients with lesions not extending behind the post-rolandic convolution.

An interesting question is whether language shifting to the right hemisphere has consequences on the organization of motor planning (praxia) and spatial abilities (neglect and other spatial disorders). As to apraxia, its presence has not been systematically investigated in all the patients with CA reported in the literature. Oral apraxia was mentioned in the case reports of Brown and Wilson (1973), Urbain et al. (1978), Assal et al. (1981) and Denes and Caviezel (1981); limb apraxia in Pillon et al. case (1979), Assal et al. (1981) and Henderson cases 2 and 3 (1983). In our series, oral apraxia was present in three, limb apraxia in one but no apraxia of use was found. We have too few data at the moment to draw

any firm conclusion about the relationship between language and apraxia lateralization in CA.

As to the presence of spatial symptoms in crossed aphasics, Henderson (1983) after a review of the literature concluded that "right-sided language representation does not usually affect right hemisphere dominance for attention and visuospatial perception". Also Bryden, Hécaen and De Agostini (1983) analyzed 270 patients with unilateral brain damage and concluded that aphasia and spatial disorders are statistically independent, lateralization of verbal and non-verbal skills being determined by different factors. In our patients a severe and longlasting neglect was strikingly manifest in case III, while it was reported in the early days of disease in case VII and subsequently cleared. Case V also had to be constantly reminded to look to the left when taking the single word comprehension test (on which she eventually scored 100% correct) and omitted one digit to the left in writing three numbers in the course of the acalculia test. Formal tests of neglect were not given, but clues of its presence could be derived from the patients' behaviour in tasks requiring to scan an array of horizontally arranged stimuli; such as the auditory and written version of single word comprehension (five figures in a row), the Token Test (five tokens in a row) and Progressive Matrices (three items in a row) and from his performance in writing operations and copying drawings. Position preference for stimuli lying to the right was noted in Progressive Matrices in patients II, V and VII. No patient showed signs of neglect on the Token Test and the CAP test, nor there were manifestations of spatial disorganization in writing arithmetical operations or errors considered typical of right hemisphere constructional apraxia (Gainotti and Tiacci, 1970) on the CAP test.

In conclusion, of the symptoms pointing to the derangement of spatial abilities neglect was striking in the patient with parieto-occipital softening (case III), transient in a second patient with fronto-temporal softening (case VII) and mild in a third patient with fronto-temporo-parietal softening (case V). With reference to the cases of our series who did not show any sign of spatial disorder, reversed dominance for both language and visuo-spatial skills is possible, but not definitely ascertained, as the lack of spatial disorders is equally consistent with a right-hemisphere lesion than spares right hemisphere areas crucial for these tasks. The same argument applies to the cases of Brown and Wilson (1973); Zangwill (1979); Denes and Caviezel (1981) and Henderson (1983, case I). The observation of patients affected by spatial disorders and aphasia after right hemisphere lesion indicates that these patients mainly resort to right hemisphere resources for both tasks. However, it is left unexplored whether their left hemisphere ability to take over spatial functions after right damage is different from that of the general right-handed population.

ABSTRACT

Seven strongly right-handed patients developed aphasia following a right hemisphere vascular lesion documented by computerized tomography. One patient had a severe unilateral neglect, indication of its presence were evident in three and absent in three patients. The Token Test scores were significantly higher than in matched controls. Two patients had Broca aphasia, four had Wernicke aphasia and one had agraphia. The correlation between type of aphasia and locus of lesion was not much different from that normally found in standard left hemisphere brain damaged aphasics.

Acknowledgements. This research was supported by a grant from CNR. We are grateful to Dr. Yves Joanette for his helpful comments on a previous draft of the paper and to Dr. Claudio Luzzatti who kindly assisted us with the drawing of the maps. Names of authors are listed in alphabetical order.

REFERENCES

- ANGELERGUES, R., HÉCAEN, H., DJINDJIAN, R., and JARRIÉ-HAZAN, N. Un cas d'aphasie croisée. *Revue Neurologique*, 107: 543-545, 1962.
- ARRIGONI, G., and DE RENZI, E. Constructional apraxia and hemispheric locus of lesion. *Cortex*, 1: 180-197, 1964.
- ASSAL, G., PERENTES, E., and DERUAZ, J.P. Crossed aphasia in a right-handed patient. Postmortem findings. *Archives of Neurology*, 38: 455-458, 1981.
- BASSO, A., and CAPITANI, E. Un test standardizzato per la diagnosi di acalculia. Descrizione e valori normativi. *AP-Rivista di applicazioni psicologiche*, 1: 551-564-1979.
- BASSO, A., CAPITANI, E., and VIGNOLO, L.A. Influence of rehabilitation on language skills in aphasic patients. A controlled study. *Archives of Neurology*, 36: 190-196, 1979.
- BASSO, A., DE RENZI, E., FAGLIONI, P., SCOTTI, G., and SPINNLER, H. Neuropsychological evidence for the existence of cerebral areas critical to the performance of intelligence tasks. *Brain*, 96: 715-728, 1973.
- BASSO, A., LECOURE, A.R., MORASCHINI, S., and VANIER, M. Anatomico-clinical correlations of the aphasias as defined through computerized tomography: on exceptions. *Brain and Language*, 1985 (in press).
- BROWN, J.W., and HÉCAEN, H. Lateralization and language representation. Observations on aphasia in children, left-handers, and "anomalous" dextrals. *Neurology*, 26: 183-189, 1976.
- BROWN, H.W., and WILSON, F.R. Crossed aphasia in a dextral. A case report. *Neurology*, 23: 907-911, 1973.
- BRYDEN, M.P., HÉCAEN, H., and DE AGOSTINI, M. Patterns of cerebral organization. *Brain and Language*, 20: 249-262, 1983.
- CARR, M.S., JACOBSON, T., and BOLLER, F. Crossed aphasia: analysis of four cases. *Brain and Language*, 14: 190-202, 1981.
- DENES, G., and CAVIEZEL, F. Dichotic listening in crossed aphasia. "Paradoxical" ipsilateral suppression. *Archives of Neurology*, 38: 182-185, 1981.
- DE RENZI, E., and FAGLIONI, P. Normative data and screening power of a shortened version of the Token Test. *Cortex*, 14: 41-49, 1978.
- DE RENZI, E., FAGLIONI, P., and SORGATO P. Modality-specific and supramodal mechanisms of apraxia. *Brain*, 105: 301-312, 1982.

- DE RENZI, E., MOTTI, F., and NICHELLI, P. Imitating gestures: a quantitative approach to ideomotor apraxia. *Archives of Neurology*, 37: 6-10, 1980.
- DE RENZI, E., PIECZURO, A., and VIGNOLO, L.A. Oral apraxia and aphasia. *Cortex*, 2: 50-73, 1966.
- DE RENZI, E., PIECZURO, A., and VIGNOLO, L.A. Ideational apraxia: a quantitative study. *Neuropsychologia*, 6: 41-52, 1968.
- ERKULVRAWATR, S. Alexia and left homonymous hemianopia in a non-right-hander. *Annals of Neurology*, 3: 549-552, 1978.
- GAINOTTI, G., and TIACCI, C. Patterns of drawing disability in right and left hemispheric patients. *Neuropsychologia*, 8: 379-384, 1970.
- GLONING, K. Handedness and aphasia. *Neuropsychologia*, 15: 355-358, 1977.
- HABIB, M., JOANETTE, Y., ALI-CHERIF, A., and PONCET, M. Crossed aphasia in dextrals: a case report with special reference to site of lesion. *Neuropsychologia*, 21: 413-418, 1983.
- HENDERSON, V.W. Speech fluency in crossed aphasia. *Brain*, 106: 837-857, 1983.
- OLDFIELD, R.C. The assessment and analysis of handedness: the Edinburgh Inventory. *Neuropsychologia*, 9: 97-113, 1971.
- PILLON, B., DESI, M., and LHERMITTE, F. Deux cas d'aphasie croisée avec jargonographie chez des droitiers. *Revue Neurologique*, 135: 15-30, 1979.
- PUEL, M., JOANETTE, Y., LEVRAT, M., NESPOULUS, J.M., VIALA, H.F., LECOURS, A., and RASCOL, A. Aphasie croisée chez les droitiers - II: étude neurolinguistique et neuropsychologique d'un cas. Evolution sur 2 ans. *Revue Neurologique*, 138: 587-600, 1982.
- URBAIN, E., SERON, X., REMITS, A., COBBEN, A., VAN DER LINDEN, M., and MOUCHETTE, R. Aphasie croisée chez une droitère. A propos d'une observation. *Revue Neurologique*, 134: 751-759, 1978.
- WECHSLER, A.F. Crossed aphasia in an illiterate dextral. *Brain and Language*, 3: 164-172, 1976.
- YARNELL, P.L. Crossed dextral aphasia: a clinical radiological correlation. *Brain and Language*, 12: 128-139, 1981.
- ZANGWILL, O.L. Two cases of crossed aphasia in dextrals. *Neuropsychologia*, 17: 167-172, 1979.

Dr. A. Basso, Clinica Neurologica, Policlinico, via F. Sforza 35, 20100 Milano (Italy).