

## Pure Motor Hemiparesis due to Hypertensive Putaminal Haemorrhage

S. Jain<sup>a</sup>, M.C. Maheshwari<sup>a</sup>, R.M. Dhamija<sup>a</sup>, N.K. Mishra<sup>b</sup>

Departments of <sup>a</sup>Neurology and <sup>b</sup>Neuroradiology, All India Institute of Medical Sciences, New Delhi, India

**Key Words.** Pure motor hemiparesis · Hypertensive putaminal haemorrhage · CT scan

**Abstract.** A hypertensive woman presenting as pure motor hemiparesis with rapid and complete recovery from the neurological deficit is described. The probable aetiology was primary hypertensive putaminal haemorrhage, as revealed by CT scan. This rare presentation has been described only once earlier and emphasizes the value of CT scanning as a tool for diagnosis of such cases.

### Introduction

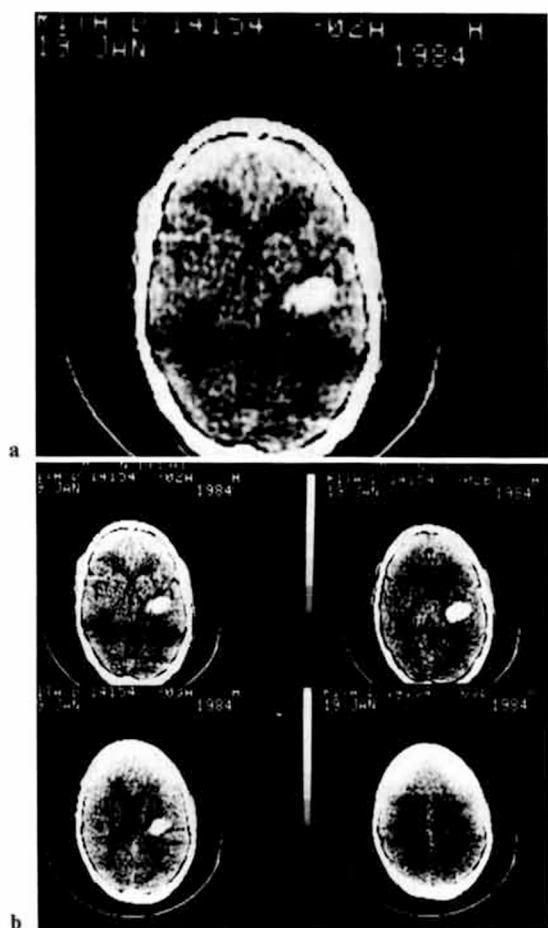
Pure motor hemiplegia (PMH) is a well-defined syndrome usually caused by ischaemic lesions of lacunar type located either in the internal capsule or in the pons [1]. Subsequently, several isolated cases were published revealing the other possible sites of ischaemic lesions: infarcts of cortical [2], pyramidal [1, 3, 4] or midbrain location [5]. In addition, other aetiologies of PMH have been described and include: post-craniotomy haemorrhage [6], haemorrhages in the basis pontis [7] or internal capsule [2, 8, 9], multiple sclerosis [2], metastasis [2, 3] and abscess [10]. A haemorrhagic origin of PMH is considered classically to be rare. Only 1 clear-cut case of PMH in the setting of primary hypertensive

putaminal haemorrhage (HPH) has been described [11]. We report one such case presenting as PMH due to putaminal haemorrhage with subsequent total recovery.

### Case Report

A 41-year-old right-handed hypertensive female noticed heaviness and weakness of the left upper limb on January 17, 1984. About half an hour later she noticed weakness of the left leg and was unable to stand unaided. She complained of headache and vomited once while she was still in the office. When examined 4 h after the onset, she was conscious, oriented and described her illness accurately. Her speech was slightly dysarthric but she had no dysphasia.

Cranial nerve testing revealed a left supranuclear facial paresis. The visual fields, extraocular movements and pupils were normal. There was no nystag-



**Fig. 1. a, b** CT scan (unenhanced) showing a well-defined haematoma at the level of the right midposterior putamen.

mus. The facial sensations and palatal and tongue movements were intact. Motor examination showed a moderate paresis of left upper limb, power grade I/V MRC [12] and mild weakness of the left lower extremity (III/V). The deep tendon reflexes were diminished in the left arm and leg and plantar reflexes were bilaterally flexor. Coordination was intact. There was no dyspraxia. Sensory examination for touch and pin prick was normal. Joint position and vibration sense was intact. There was no sensory extinction on double

simultaneous tactile stimulation. Stereognosis, barognosis and trace figure identification were normal and symmetric.

Routine blood chemistry was normal. ECG revealed evidence of left ventricular hypertrophy. CT scan on admission showed a well-defined area of high attenuation (Mean 66 Hounsfield units) at the level of right midposterior putamen, consistent with fresh haemorrhage (fig. 1a, b). There was a thin zone of perifocal low attenuation with slight compression of the body of the right lateral ventricle. The volume of this haematoma was estimated to be 8.72 ml.

The left hemiparesis progressively improved over the next 4 days following admission. At the time of discharge (7 days from the onset) power in the left arm and leg was IV/V. Left facial weakness had recovered completely. When seen on follow-up 3 weeks from onset, the motor strength of the left limbs had returned to normal and she was back to her office work.

## Discussion

PMH constitutes a neurological syndrome usually associated with ischaemic lesions of lacunar type located at various sites [1–5]. Only 6 CT-documented cases of PMH due to haemorrhage into the internal capsule have been described [2, 8, 9]. 5 of these cases, being part of two large series of PMH patients [2, 8], lack the detail description of their clinical features. Only 1 clear-cut case of PMH with detailed neurological evaluation has been described [11]. In this case the aetiology was a primary HPH.

HPH has been described to present with a wide variety of neurological deficits. The clinical spectrum of HPH includes combinations of motor, sensory, oculomotor, visual, language and behavioural deficits [13, 14]. It has only recently been emphasized that PMH may also be a rare manifestation of HPH [11]. Visualization of such rare things has been made possible by the advent of CT scan in the last few years.

The size of HPH and its location are also important. In the only case of HPH presenting as PMH reported earlier [11], it measured 8.5 mm<sup>3</sup> and was located along the mid and posterior aspects of the putamen. In our patient, the volume of this haematoma was estimated to be 8.72 ml and it was located at almost a similar site. It has been presumed that the posterior and lateral location of the haematoma is responsible for pressure effects, rather than acutal destruction of the adjacent internal capsule [11]. Similar anatomical features in our case can account for the clinical presentation (PMH) and complete recovery within 3 weeks of the onset. However, HPH presenting as pure motor hemiparesis with complete recovery remains a distinctly uncommon clinical situation. PMH with good prognosis may rarely be included into the wide variety of clinical presentations as a result of primary HPH.

## References

- 1 Fisher, C.M.; Curry, H.B.: Pure motor hemiplegia of vascular origin. *Archs Neurol.* 13: 30–44 (1965).
- 2 Weisberg, L.A.: Computed tomography and pure motor hemiparesis. *Neurology*, N.Y. 29: 490–495 (1979).
- 3 Chokroverty, S.; Rubino, F.A.: 'Pure' motor hemiplegia. *J. Neurol. Neurosurg. Psychiat.* 38: 896–899 (1975).
- 4 Ropper, A.H.; Fisher, C.M.; Kleinman, G.M.: Pyramidal infarction in the medulla: a cause of pure motor hemiplegia sparing the face. *Neurology*, N.Y. 29: 91–95 (1979).
- 5 Ho, K.L.: Pure motor hemiplegia due to infarction of the cerebral peduncle. *Archs. Neurol.* 39: 524–526 (1982).
- 6 Igapashi, S.; Mori, K.; Ishijimi, Y.: Pure motor hemiplegia after recraniotomy for post-operative bleeding. *Arch. jap. Chir.* 41: 32–37 (1972).
- 7 Gobernado, J.M.; Fernandez de Molina, A.R.; Gimeno, A.: Pure motor hemiplegia due to haemorrhage in the lower pons. *Archs Neurol.* 37: 393 (1980).
- 8 Rascol, A.; Clanet, M.; Manelfe, C.; Guiraud, B.; Bonafe, A.: Pure motor hemiplegia: CT study of 30 cases. *Stroke* 13: 11–17 (1982).
- 9 Obeso, J.A.; Marti-Masso, J.F.; Carrera, N.; Austudillo, W.: Pure motor quadriplegia secondary to bilateral capsular hematomas. *Archs Neurol.* 37: 248 (1980).
- 10 Weintraub, M.I.; Glasser, G.H.: Neocardial brain abscess and pure motor hemiplegia. *N.Y. St. J. Med.* 70: 2717–2721 (1970).
- 11 Tapia, J.F.; Kase, C.S.; Sawyer, R.H.; Mohr, J.P.: Hypertensive putaminal hemorrhage presenting as pure motor hemiparesis. *Stroke* 14: 505–506 (1983).
- 12 MRC: Motor testing; in *Aids to the examination of the peripheral nervous system*. Memorandum No. 45 (Medical Research Council, London 1976).
- 13 Fisher, C.M.: Clinical syndromes in cerebral hemorrhage; in *Fields, Pathogenesis and treatment of cerebrovascular disease*, pp. 318–342 (Thomas, Springfield 1961).
- 14 Hier, D.B.; Davis, K.R.; Richardson, E.P.; Mohr, J.P.: Hypertensive putaminal hemorrhage. *Ann. Neurol.* 1: 152–159 (1977).

Received: February 29, 1984

Accepted: August 1, 1984

M.C. Maheshwari, MD,  
Department of Neurology,  
AIIMS, New Delhi – 110029 (India)