

Transient Neurological Deficits Due To Embolic Occlusion and Immediate Reopening Of The Cerebral Arteries

MAMORU TANEDA, M.D., NOBUMITSU SHIMADA, M.D., AND TAKASHI TSUCHIYA, M.D.

SUMMARY The authors present two cases of transient occlusion of the major cerebral arteries which occurred during transfemoral catheterization of the carotid artery. Right hemiplegia and aphasia developed suddenly in both cases, and disappeared completely within 14 hours in one case and 25 minutes in the other. On the angiograms performed at the moment of onset of the symptoms, the site of the occlusion was the left internal carotid artery in one case and the left middle cerebral artery in the other. Angiograms which were repeated soon after clinical improvement revealed complete dissolution of the occluding emboli. These cases present direct radiographic evidence that embolic occlusion of a major cerebral artery and its disappearance is the mechanism of the transient manifestation of the neurological deficits associated with cerebrovascular catheterization.

Stroke Vol 16, No 3, 1985

CATHETER CEREBRAL ANGIOGRAPHY is sometimes accompanied by cerebral complications, and they are most frequently transient.¹ The following cases angiographically show that one of the mechanisms of transient neurological deficits during cerebrovascular catheterization was complete embolic occlusion of a major cerebral artery and its immediate disappearance.

Case 1

This 42-year-old woman had been in good health until 2 hours before her admission to our department, when she suddenly developed severe headache and vomiting. On admission, she was almost alert with mild neck stiffness. A computerized tomography (CT) scan demonstrated blood collecting in the subarachnoid space. Four-vessel study by Seldinger's method revealed an aneurysm of the right internal carotid artery at the origin of the anterior choroidal artery.

On the day after subarachnoid hemorrhage (SAH), the aneurysm was clipped and subarachnoid blood was removed as much as possible via a right pterional approach. Postoperatively the patient was alert and developed no neurological deficits.

On the 9th day after SAH, angiographic examination was performed via a transfemoral catheter. Right carotid angiogram showed that the aneurysm was satisfactorily occluded. During the subsequent catheterization of the left carotid artery, she suddenly became drowsy and a right hemiplegia and aphasia developed. Anteroposterior view of the left carotid angiography revealed complete occlusion of the internal carotid artery, just distal to the carotid bifurcation (fig. 1, left). Lateral view injected immediately afterwards showed peripheral movement of the occluding mass. The internal carotid artery was now patent. The middle cerebral

artery appeared almost occluded, however, and only one branch filled. The anterior cerebral artery was completely occluded (fig. 1, center).

About one and a half hours later, while preparing her for embolectomy, right hemiplegia completely resolved. Ultrasonic Doppler study for examination of the cervical arterial blood flow at this moment showed normal flow pattern of the left internal carotid artery, indicating that reopening of the occluded arteries had occurred. Repeat angiography, when subsequently performed, showed that previously identified occlusions disappeared completely (fig. 1, right). Aphasia gradually resolved and completely disappeared 14 hours later. The patient was discharged without neurological deficits.

Case 2

This 29-year-old man was admitted to our department 3 hours after head injury. On admission he was drowsy and restless. A CT scan demonstrated a subdural hematoma over the left occipital lobe. An emergency operation was carried out to remove the hematoma. Postoperatively, there was considerable improvement in the level of consciousness. On the third day, the patient was completely alert without neurological deficits.

On the 7th day, measurement of the cerebral blood flow (CBF) was planned. CBF of the right hemisphere was measured without difficulty by ¹³³Xe injection through a transfemoral catheter introduced into the right internal carotid artery. During manipulation to pass the catheter into the left internal carotid artery for CBF measurement of the left hemisphere, the patient became aphasic and a profound right hemiplegia developed. Angiograms immediately performed injecting contrast medium through the catheter showed an obstruction of the main stem of the middle cerebral artery (fig. 2, left), and emergency embolectomy was scheduled. About 20 minutes later, however, there was significant improvement of the strength of the right extremities, especially of the lower one. Within the subsequent five minutes, aphasia and hemiparesis completely disappeared. Angiography which was repeated at this moment revealed complete patency of

From the Departments of Neurosurgery and Medicine, Hanwa Memorial Hospital, Osaka, Japan.

Address correspondence to: Mamoru Taneda, M.D., Department of Neurosurgery, Hanwa Memorial Hospital, Karita-7, Sumiyoshi-ku, Osaka 558, Japan.

Received September 10, 1984; revision #1 accepted November 21, 1984.

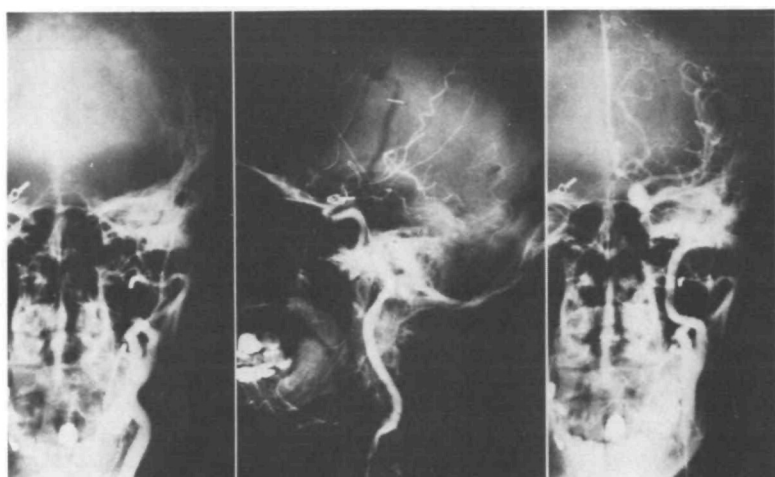


FIGURE 1. Case 1. Left carotid angiograms. Left: Anteroposterior view showing occlusion of the internal carotid artery just distal to the carotid bifurcation. Center: Lateral view, performed immediately after, showing the patent internal carotid artery, the occluded anterior cerebral artery, and occlusion of the large branches of the middle cerebral artery. Right: Anteroposterior view repeated two hours later showing normal appearance.

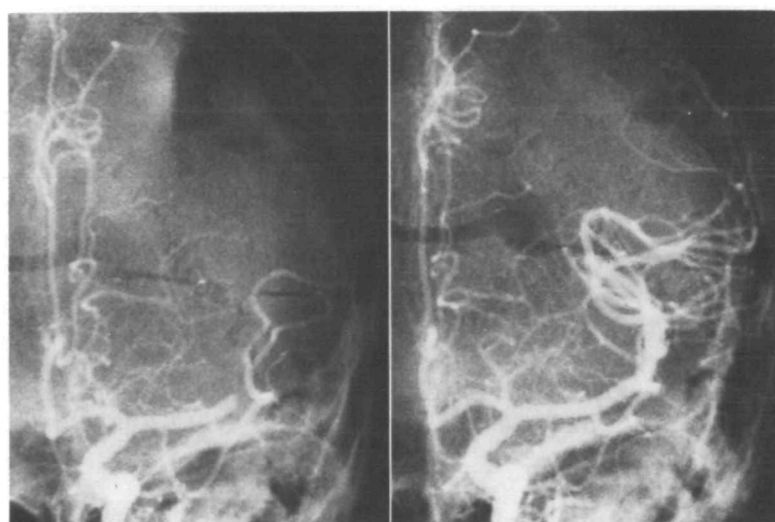

FIGURE 2. Case 2. Left carotid angiograms, anteroposterior views. Left: Initial appearance showing occlusion of the main stem of the middle cerebral artery. Right: Repeat study, 25 minutes later, showing normal appearance.

the middle cerebral artery (fig. 2, right). The patient was discharged without any neurological deficit.

Discussion

Thrombus is sometimes formed on intravascular catheters. The incidence of thrombus formation was reported to be more than 50% of 93 diagnostic catheterization.² The emboli in our cases probably originated from thrombotic material which was formed on catheters, and they were large enough to occlude the major cerebral arteries. In both cases, angiography demonstrated immediate disappearance of the occlusion. The process of distal migration of embolus was typically demonstrated in Case 1.

Although it is generally recognized that spontaneous disappearance of intracerebral occlusions could occur,³⁻⁸ the recovery of the neurological deficit was not observed or was incomplete despite evidence of angiographic restoration of the circulation to normal. In our two cases, complete recovery of the neurological deficits followed disappearance of occlusion of a major cerebral artery. The reason for complete recovery can be attributed to short time interval between the onset of arterial occlusion and recanalization.

There are reports of complete resolution of neurological deficits possibly due to complete clearing of occlusion or stenosis of the small arterial branches.^{9, 10} Unfortunately, in those reports, contribution of recanalization to complete neurological recovery was not necessarily unequivocal, because restoration of circulation was not confirmed immediately after clinical improvement.

Our cases indicate that the mechanism of the transient nature of the neurological deficits during transfemoral catheterization of the brachiocephalic vessels is embolic occlusion of a large cerebral artery and its immediate disappearance, and also suggest that early reopening of cerebral arterial occlusion ensures the functional recovery of the central nervous system.

References

1. Mini RL, Eisenberg RL, McDonald EJ Jr, Pollock JA, Mani JR: Complications of catheter cerebral angiography: Analysis of 5,000 procedures. 1. Criteria and incidence. *Am J Roentgenol* **131**: 861-865, 1978
2. Formanek G, Frech RS, Amplatz K: Arterial thrombus formation during clinical percutaneous catheterization. *Circulation* **41**: 833-839, 1970

3. Lehrer GM: Arteriographic demonstration of collateral circulation in cerebrovascular disease. *Neurology* **8**: 27-32, 1958
4. Dalal PM, Shah PM, Sheth SC, Deshpande CK: Cerebral embolism. Angiographic observations on spontaneous clot lysis. *Lancet* **1**: 61-64, 1965
5. Ettinger MG, Ryan RL: Transient vascular occlusions in acute strokes. *Minnesota Med* **48**: 863-866, 1965
6. Hollin SA, Silverstein A: Transient occlusion of the middle cerebral artery. *JAMA* **194**: 243-247, 1965
7. Allcock JM: Occlusion of the middle cerebral artery. Serial angiography as a guide to conservative therapy. *J Neurosurg* **27**: 353-363, 1967
8. Yarnell PR, Earnest MP, Sanders B, Burdick D: The "Hot Stroke" and transient vascular occlusions. *Stroke* **6**: 517-520, 1975
9. Zatz LM, Iannone AM, Eckman PB, Hecker SP: Observations concerning intracerebral vascular occlusions. *Neurology* **15**: 389-401, 1965
10. Cronqvist S, Efsing HO, Palacios E: Embolic complications in cerebral angiography with the catheter technique. *Acta Radiol (Diag) (Stockh)* **10**: 97-107, 1970

Primary Thrombocythemia In A Patient With Cerebellar Infarction

THIERRY DELANGRE, M.D.,* BRUNO MIHOUT, M.D.,* JEANNE-YVONNE BORH, M.D.,† AND MICHEL SAMSON, M.D.*

SUMMARY A patient suffering from essential thrombocythemia presented manifestations of digital thromboses and two cerebral ischemic strokes. Anomalies of platelet function are discussed in relation to published data and the efficacy of antiaggregant treatment is stressed.

Stroke Vol 16, No 3, 1985

THE ROLE OF PLATELETS in cerebral ischemic pathology,^{1,2} the frequency of thrombotic manifestations in myeloproliferative syndromes³ and the frequent neurological complications of essential thrombocythemias⁴ are all known. We report the case of a cerebellar infarction including the detailed study of platelet anomalies which are discussed in relation to published data.

Clinical Observation

Jean Jacques V . . . , a stevedore, was born on April 7, 1950, and was splenectomized in 1978 during a caudal pancreatectomy for a pancreatic pseudocyst. The platelet count became normal during the fourth post-operative month, at which time excessive tobacco and alcohol consumption had been stopped. In 1981, he developed painful peripheral vascular disease of the hands and feet, with subungual cyanosis. On May 4, 1982, he was hospitalized 3 hours after the sudden onset of head pain, vomiting and paresthesias of the four extremities. Examination revealed a moderate impairment of gait and station, hypermetria and asynergia of the right arm, as well as a paresis of lateral gaze to the right. A right superior cerebellar ischemia was observed: a hypodense area on the CT scan without contrast enhancement and also a fixation image of ⁵⁷Co labeled bleomycin radionuclide scan. Arterial pressure was 140/80 in both arms and there was no vascular murmur. Bilateral brachial arteriography, cardiac function tests (ECG, echography, holter) and routine

laboratory tests were normal. The VDRL reaction and TPHA were negative and there was no inflammatory syndrome or cryoglobulinemia. The only pathologic signs encountered were a granulocytic leucocytosis (16,1 giga/l) and a thrombocytosis at 839 giga/l with disturbances in platelet function (long bleeding time; defective aggregation induced by adenosine diphosphate, collagen and arachidonic acid). Spontaneous platelet aggregation could not be detected. An antiaggregant treatment was begun (1000 mg of acetyl salicylate, 450 mg of Dipyridamole per day). Response peripheral vascular syndrome to treatment was spectacular; the neurological signs regressed within two weeks. The platelet count was always high (1105 giga/l) and no malondialdehyde (MDA) production was obtained after platelet stimulation. Therapy was suspended 11 months later, followed by a recurrence of the vascular syndrome and the appearance of a central scotoma in the left eye in spite of chronic heparin therapy (5,000 IU per 8 hours). Thrombocytosis (1015 giga/l) and leucocytosis (12,1 giga/l) persisted. Study of platelets function revealed abnormal spontaneous aggregation (patient 80%, normal 10%), defective epinephrine and adenosine diphosphate induced aggregation, increased factor 3 activity and MDA formation. Factor VIII-von Willebrand factor (VIII-vWF) anti-thrombin III, alpha 2 antiplasmin, plasminogen and basic fibrinolytic activity with the von Kaula method⁵ were always normal. All the other examinations were normal (myelogram, bone marrow biopsy, blood and marrow karyotype, hemoglobin electrophoresis, leucocyte alkaline phosphatases), with the exception of the bone marrow culture. The latter was judged to be pathologic as a result of the growth of the erythroblast progenitor line (CFU-E) in the absence of erythropoietin. Hydroxyurea treatment (1500 then 500 mg) led to

From the Clinique Neurologique,* and Laboratoire d'Hemostase,† Hopital Charles Nicolle, C.H.U., Rouen, France.

Address correspondence to: Dr. Thierry Delangre, Clinique Neurologique, C.H.U., 76031 Rouen CEDEX, France.

Received August 8, 1984; revision #1 accepted November 21, 1984.