

Spontaneous Disappearance of Intracranial Arterio-venous Malformations

A. Pasqualin, C. Vivenza, L. Rosta, R. Scienza, R. Da Pian, and M. Colangeli*

Department of Neurosurgery, Verona City Hospital, Verona, and *Division of Neurosurgery, S. Camillo Hospital, Rome, Italy

Summary

4 cases of spontaneous disappearance of intracranial arterio-venous malformations are reported. All the malformations were in the rolandic-parietal area, and fed in most cases by the MCA. In one case, the malformation was associated with a proximal aneurysm. One malformation was large, one medium-sized, and two small. Venous drainage was towards the longitudinal sinus in all cases. Presenting symptoms consisted of epilepsy in 2 cases, and intracerebral haemorrhage in 2 cases. Disappearance of the AVM was documented by angiography from 1 to 15 years after diagnosis, and was preceded by a new haemorrhage in 2 cases. Acute or gradual thrombosis of the AVM is suggested as the most likely cause of the disappearance of an AVM. Spontaneous thrombosis of an AVM should be considered as an aspect of the pathological entity known as "thrombosed AVM". Guidelines for the management of patients exhibiting spontaneous disappearance of an AVM are briefly discussed.

Keywords: Intracranial arterio-venous malformation; spontaneous thrombosis; haemorrhage; epilepsy.

Introduction

Few cases of arterio-venous malformations (AVMs) with a spontaneous cure documented by angiography have been reported in the literature^{2–4, 9–11, 14, 15, 23, 25, 27–29, 31, 33–35, 38}; they were generally individual case reports, with a total of less than 25 cases to date. Even partial spontaneous regression in the size of an AVM is an infrequent occurrence^{19, 22, 30, 34, 39, 42}.

The aim of this study is to present 4 cases of spontaneous disappearance of intracranial arterio-venous malformations, and to discuss the features and possible causes of this phenomenon.

Analysis of Cases

Out of a total of 180 patients with intracranial AVMs admitted to our Department in the years 1970–1982, 4 patients showed spontaneous disappearance of the angioma at a later period. There were 3

males and 1 female, whose ages ranged from 15 years to 56 years, all harbouring rolandic-parietal AVMs (Tab. 1): 1 AVM was large, 1 medium-sized (2–5 cm), and 2 small. The middle cerebral artery fed the malformation in 3 cases, the anterior cerebral artery in 2 cases and a lenticulo-striate artery in one case. Venous drainage was towards the longitudinal sinus in all 4 cases. In only 2 cases CT scan was performed at the time of the diagnosis of the AVM, and in all of the cases at a recent follow-up investigation.

The clinical picture (Tab. 2) was presented by intracranial haemorrhage in 2 cases, a progressive neurological deficit with epilepsy in one case, and epilepsy alone in one case. All patients—except one—exhibited neurological deficits at admission.

No therapeutical procedures were undertaken in all of the cases, for different reasons. After diagnosis of the AVM one patient did not show further disturbances, 2 patients suffered from repeated seizures, followed most likely by intracranial bleeding in one case, and one patient experienced an intracerebral haematoma. Control angiography showed disappearance of the AVM at an interval of 1–15 years from diagnosis. At follow-up examination, ranging from 2 to 16 years, all the patients led normal lives, despite one being moderately disabled from a hemiparesis and dysphasia, and another suffering from infrequent epileptic seizures.

Report of Cases

Case 1: A 41-year-old man had been complaining of progressive right hemiparesis since 1969, associated one year later with episodic Jacksonian seizures affecting the right upper limb. When referred to our Department from another hospital, awake and with a right hemiparesis, bilateral carotid angiography (December 1970) revealed (Fig. 1 a and b) a large left rolandic AVM, with extension into the gyrus cinguli, fed by the left anterior cerebral artery (ACA), by the left middle cerebral artery (MCA), and by a left lenticulo-striate artery. An aneurysm of the left MCA was also present at the proximal bifurcation. The venous drainage was towards the longitudinal sinus. Small paramedian calcifications were present in the skull X-rays. Owing to the operative risk and to the limited experience at that time of this kind of lesion, it was decided to treat the patient conservatively. Due to frequent episodes of paraesthesias of the right limbs in the following years and persistence of epilepsy, the patient was admitted to our Department 7 years later. At this time, a left carotid angiography (Fig. 1 c and d) showed complete disappearance of the AVM, and a decrease in size of the aneurysm. At a later follow-

Table 1. *Anatomical Features of 4 Cases Exhibiting Spontaneous Disappearance of Intracranial Arterio-venous Malformations*

Sex, age	Location	Size	Feeders	Drainage
1. m, 41 years	lt. rolandic-paracallosal AVM	large	lt. MCA, ACA & lenticulo-striate art.	longitudinal sinus
2. m, 56 years	lt. sylvian-rolandic AVM	medium	lt. MCA	longitudinal sinus
3. m, 15 years	rt. mesial rolandic AVM	small	rt. ACA	longitudinal sinus
4. f, 40 years	rt. parietal AVM	small	rt. MCA	longitudinal sinus

Table 2. *Clinical Features of 4 Cases Exhibiting Spontaneous Disappearance of Intracranial Arterio-venous Malformations*

Presenting sympt.	Examination	Course	Time of disappear.	Outcome
1. progressive neurol. deficit, epilepsy	mild rt. hemiparesis & hypesthesia	epilepsy	7 years	epilepsy & rt. paraesthesia
2. intracranial haemorrhage (twice)	dysphasia, rt. hemiparesis	intracranial haemorrhage	9 years	dysphasia, mild rt. hemiparesis
3. intracranial haemorrhage	mild lt. hemiparesis	uneventful	1 year	no deficits
4. epilepsy	no deficits	epilepsy, intracranial haemorrhage	15 years	lt. hemianopia

up examination, a CT scan showed an area of increased density in the left parietal region (Fig. 2), with partial peripheral enhancement after contrast medium injection. The calcium deposits in the skull X-rays were unchanged. In the following years, the patient presented with infrequent episodic seizures; disturbing paraesthesias and hypaesthesia were still present affecting the right limbs at a follow-up examination (April 1983), while the hemiparesis had disappeared.

Case 2: A 56-year-old man experienced headache and aphasia of sudden onset in September 1972. He was admitted to another hospital where a left carotid angiography showed a medium-sized left sylvian-rolandic AVM, fed by branches of the left MCA, with venous drainage towards the longitudinal sinus*. The patient refused the operation and was discharged with no speech disturbances, but he experienced sudden loss of consciousness 9 years later, followed by stupor, right hemiparesis and dysphasia. Admitted to the previous hospital, a CT scan showed a left intracerebral haematoma, with a mass effect. The patient was transferred to our Department, awake, dysphasic, and recovering from a right hemiparesis. Left carotid angiography (November 1981) showed complete disappearance of the AVM. In the following months, the patient showed further recovery from his neurological deficits, despite hemiparesis and dysphasia being still present at a follow-up examination. The control CT scan was not undertaken in this patient.

Case 3: A 15-year-old boy experienced sudden loss of consciousness, followed by generalized seizures, starting from the left upper limb, on June 1981. He was admitted to another hospital with mild left hemiparesis and drowsiness, and the CT scan showed a right

parietal haematoma, while right carotid angiography (Fig. 3 a) showed a small right rolandic paramedian AVM, fed by a branch of the right callosomarginal artery. Venous drainage was towards the superior longitudinal sinus. Treated conservatively, he was admitted to our Department for surgical treatment one year later, when neurologically intact. At this time, a right carotid angiography (Fig. 3 b) showed complete disappearance of the AVM and the CT scan showed no abnormalities, even after contrast medium enhancement. When discharged, the patient was symptom-free and remained so at a recent examination (July 1983).

Case 4: A 40-year-old female had been complaining of repeated generalized seizures since April 1967; in June 1967, she was admitted to another hospital, neurologically intact. At this time, a right carotid angiography (Fig. 4 a) showed a small right parietal AVM, fed by branches of the right MCA, with venous drainage towards the longitudinal sinus. Having been discharged after refusing an operation, in the following years she complained of infrequent seizures affecting the left limbs and headache associated with high blood pressure values. In April 1982, a control CT scan showed a right capsular hypodensity. In August 1982, the patient experienced a sudden onset of vertigo, headache, vomiting, and left-sided Jacksonian seizures. Admitted to our Department 12 days after this episode, the patient was awake, with neck stiffness and severe headache, left sensory-motor paresis, and left hemianopia. The CT scan was unchanged, while a right carotid angiography (Fig. 4 b) showed the complete disappearance of the AVM. When discharged under antiepileptic treatment, she still complained of left hemianopia one year later, while the left hemiparesis had completely disappeared. After her discharge the patient experienced only one episode of left Jacksonian seizures.

* Films unsuitable for documentation.

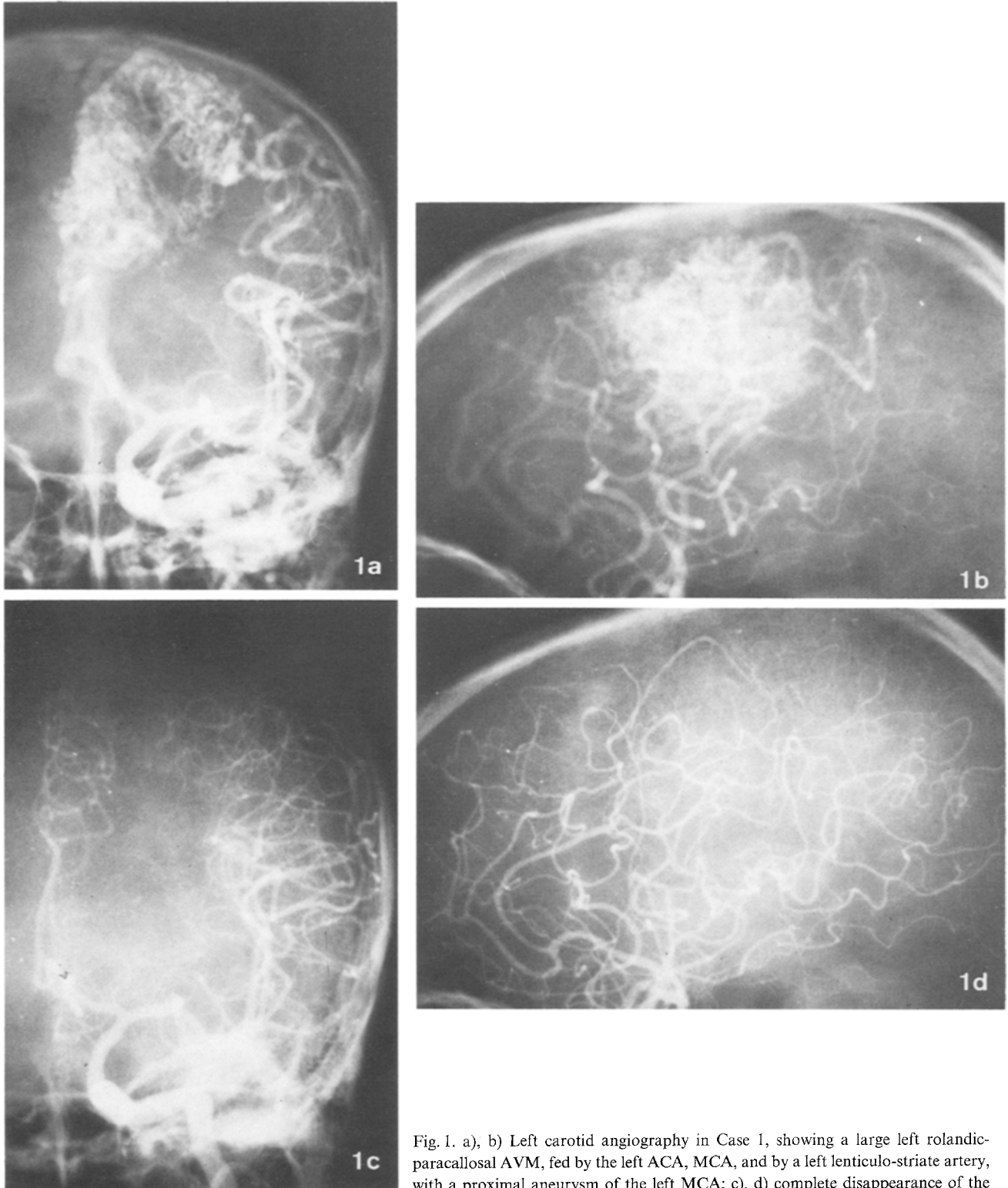


Fig. 1. a), b) Left carotid angiography in Case 1, showing a large left rolandic-paracallosal AVM, fed by the left ACA, MCA, and by a left lenticulo-striate artery, with a proximal aneurysm of the left MCA; c), d) complete disappearance of the AVM and reduction in size of the aneurysm on left carotid angiography 7 years later

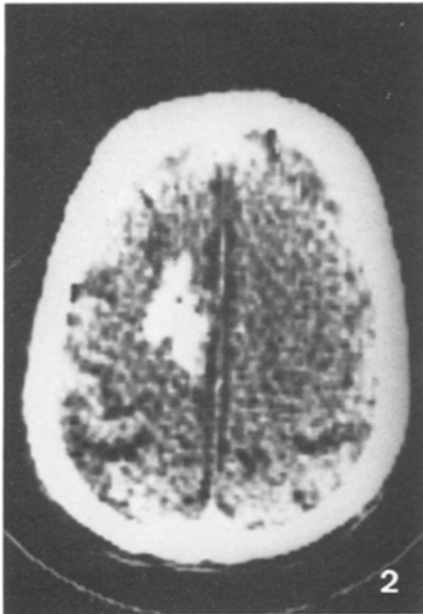


Fig. 2. CT scan in Case 1, showing a left paramedian parietal hyperdensity with partial peripheral enhancement after contrast medium injection

Discussion

The spontaneous disappearance of intracranial AVMs has been quite frequently reported in the literature^{2-4, 9-11, 14, 15, 23, 25, 27-29, 31, 33-35, 38}, and about 25 cases have been documented to date. Complete regression of an AVM has been reported not only for cerebral, but also for dural angiomas^{2, 10, 14, 28}. Also partial regression of an AVM has been documented, either by angiography^{22, 30, 34, 39, 42}, or brain scans¹⁹.

The natural incidence of this phenomenon is not known: in our series it occurred in 2-3% of all intracranial AVMs.

The time-lapse from diagnosis to disappearance of the AVM has varied from 7 months^{14, 27} to 21 years^{15, 31}, according to the literature. In our experience, this period has varied from 1 to 15 years. While in most cases there was no documented regression in the size before the complete disappearance of the AVM, a few authors were able to demonstrate by repeated angiographical studies a gradual regression in size before the complete disappearance of the AVM^{22, 23}.

With a few exceptions, spontaneous regression of the AVM has been observed only in adult patients under 60 years of age. Only a few authors^{10, 14, 27, 31, 34} have documented this phenomenon before the age of 30, and we add another case from our series.

Table 3. Proposed Theories Regarding the Spontaneous Disappearance of Intracranial Arterio-venous Malformations

- | |
|---|
| 1. Acute thrombosis due to intracranial haemorrhage |
| — mass effect |
| — oedema |
| — vasospasm |
| 2. Subacute or gradual thrombosis |
| — coagulation disorders |
| — increased blood turbulence |
| — alterations in flow dynamics (dural AVMs) |
| 3. Occlusion of feeding vessels |
| — arteriosclerosis |
| — thrombo-embolism |
| 4. Disruption with haemorrhage |
| (for small or cryptic AVMs) |

Complete spontaneous regression of an AVM should be differentiated from complete regression following conventional radiation treatment^{6, 43}. In this respect, the role of conventional radiotherapy in the treatment of inoperable AVMs has been recently stressed, with encouraging results¹⁷.

Various theories have been proposed in order to explain the disappearance of an intracranial AVM and, for practical purposes, they are summarized in Tab. 3.

Acute thrombosis due to intracranial haemorrhage is at present considered to be the most frequent cause of disappearance of an AVM^{1, 7, 9, 21}. Also in our experience, it represented the most likely cause of disappearance of the AVM in case 2. It is possible that compression by an adjacent intracranial haematoma reduces the flow through the malformation, thus leading to widespread thrombosis⁹.

Subacute or gradual thrombosis may be another cause of regression for an AVM, as stated by various authors^{4, 7, 28, 29, 41-44}. Possible reasons for a gradual thrombosis include coagulation disorders⁴¹, increased blood turbulence^{7, 29}, and alterations in flow dynamics, especially for dural AVMs^{28, 44}. Our cases 1 and 3 may represent examples of gradual thrombosis. In case 1, no haemorrhage occurred in the clinical history, and thrombosis could be documented in the CT scan; in case 3, who did not experience another haemorrhage after the diagnosis of the AVM, gradual thrombosis may have occurred, even if thrombosis was not detected in the CT scan, possibly due to the limited size of the AVM.

Regardless of the time-lapse for occurrence of complete thrombosis, it has been suggested that this phenomenon is more likely to occur when the AVM is

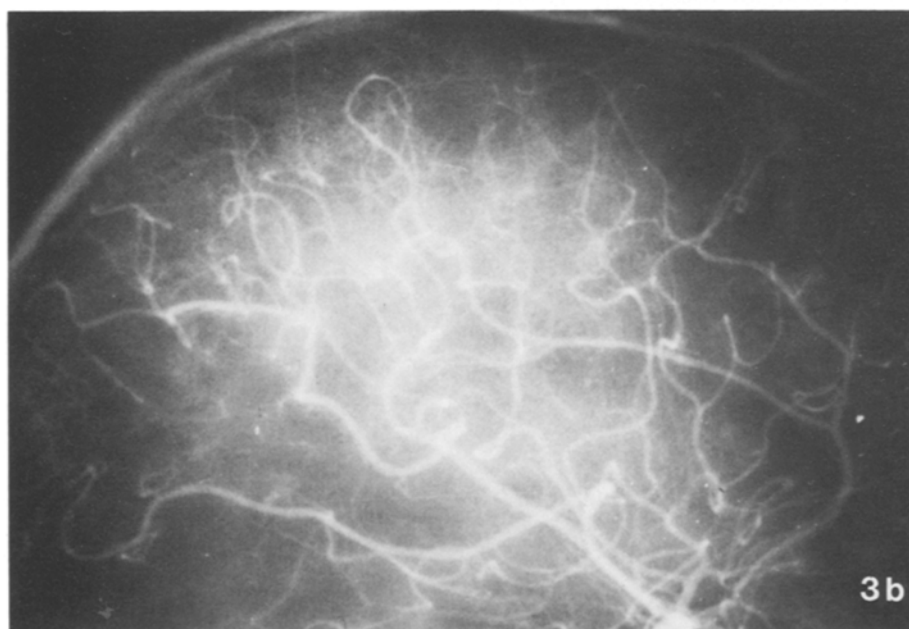
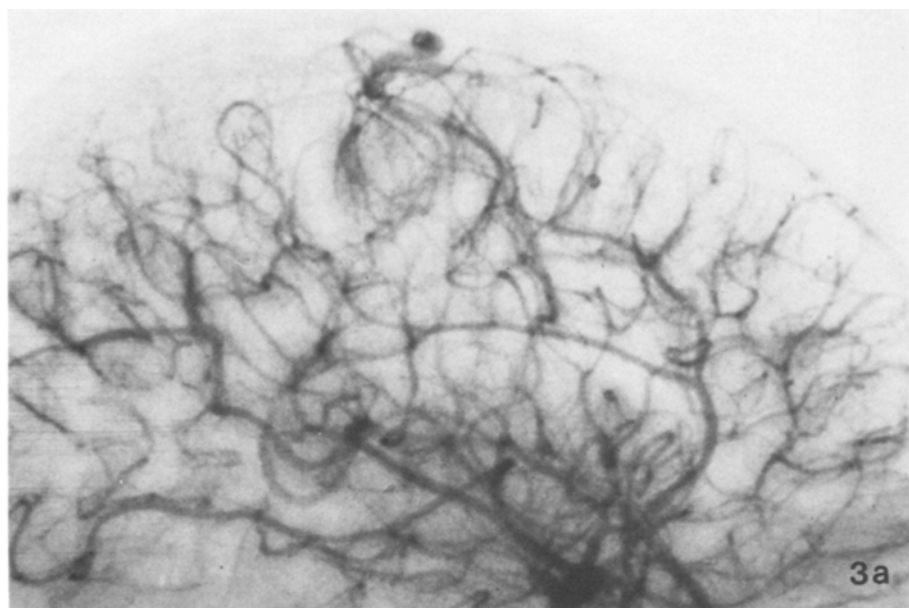


Fig. 3. a) Right carotid angiography in Case 3, showing a small right mesial rolandic AVM, fed by the right callosomarginal artery; b) complete disappearance of the AVM on right carotid angiography 1 year later

small, and drained by a single vein^{4,31} and our experience would seem to confirm especially the second point.

Other less recognized causes of regression for an AVM should also be mentioned, such as occlusion of feeding vessels by arteriosclerosis^{29,36} or by thrombo-embolism^{22,31}, and disruption with haemorrhage, especially for small or cryptic AVMs^{1,18,37}, as in our case 4.

The presence of an aneurysm proximally to the AVM, as in the case by Nehls²⁹ and in our case 1, has

never been reported before, in cases of AVMs undergoing complete regression. In our opinion, it is unlikely that thrombo-embolism as the case of complete obliteration has occurred from a small aneurysm.

The spontaneous disappearance of an AVM by thrombosis should be most likely considered to be an aspect of the pathological entity known as “thrombosed AVM”, discovered in recent years and documented in CT scans by various authors^{1, 7, 12, 16, 20, 21, 24, 26, 41, 44–46}. The classic appearance of a thrombosed AVM in the CT scan consists of a mass of increased

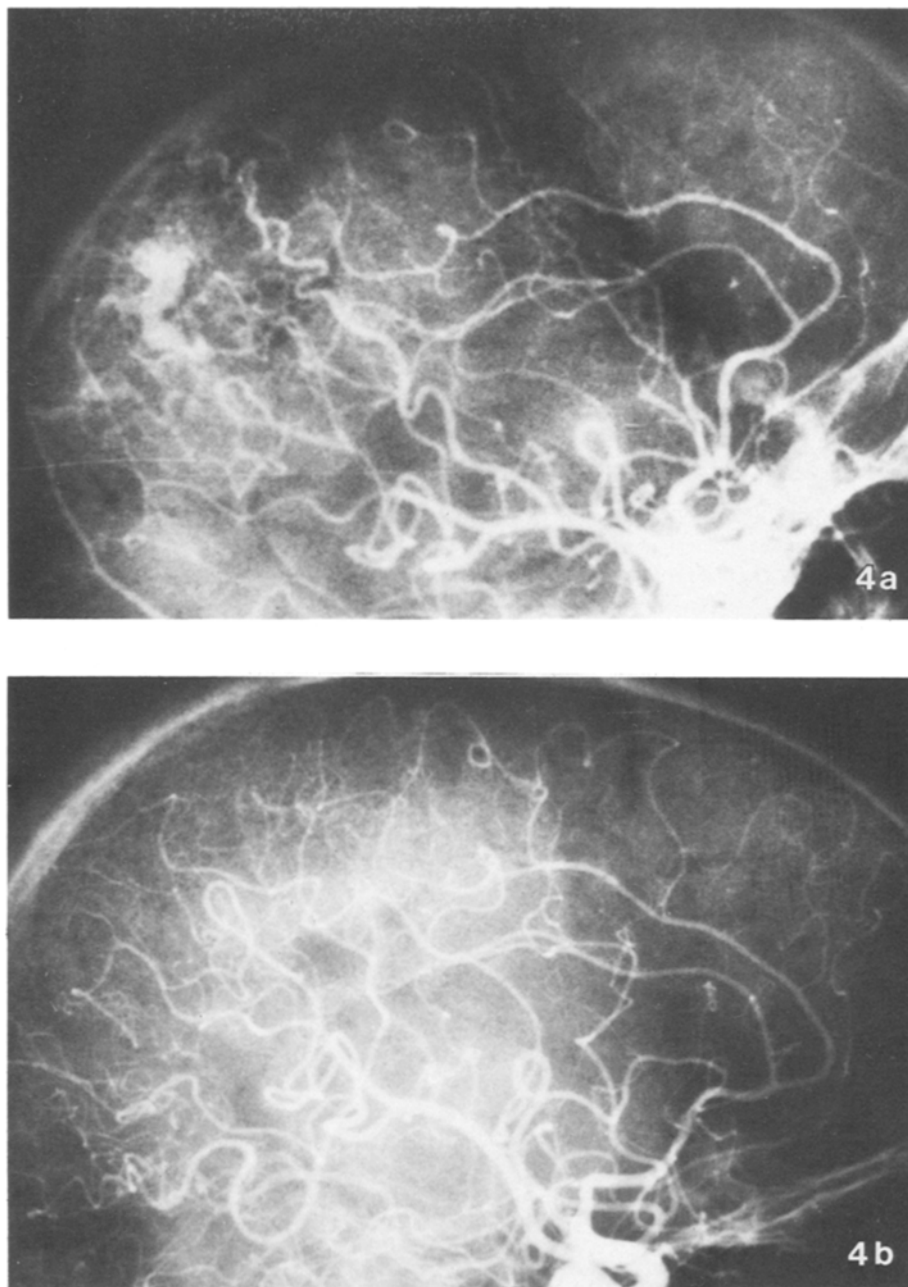


Fig. 4. a) Right carotid angiography in Case 4, showing a small right parietal AVM, fed by branches of the right MCA; b) complete disappearance of the AVM on right carotid angiography 15 years later

density, which enhances slightly with contrast medium administration. This tomographical picture was observed in our case 1, when complete disappearance of the AVM had been already documented by angiography. Completely thrombosed intracranial AVMs may not be rare, and probably correspond to the previously reported cases of AVMs without any angiographically demonstrable circulation, observed at operation or at autopsy^{3, 5, 8, 13, 18, 32, 34, 37, 40}. Thus, a “thrombosed AVM” could be the final stage of a gradual or abrupt process, as for the spontaneous

disappearance of AVMs, or could be a primary lesion, in which thrombosis may have occurred during foetal development.

Regardless of the aetiology of this phenomenon, the angiographical disappearance of an AVM may not always be considered as a cure for the patient, especially when the AVM is still detectable in the CT scan, owing to complete thrombosis. In this respect, the high incidence of epilepsy in cases with thrombosed AVMs reported by a few authors^{1, 8, 16, 46} is probably an indication for surgical removal of the lesion. As regards

haemorrhage, this should be unlikely for a thrombosed AVM, and has never been reported in the literature.

In conclusion, the disappearance of the previously diagnosed AVM is a rare but possible occurrence. Therefore, in cases in which treatment of an AVM diagnosed months or years before is planned, angiography should always be repeated. Should the AVM have undergone complete thrombosis as documented by the CT scan, and should epilepsy still be present in spite of adequate medical treatment, surgical removal of the lesion could be considered in selected cases.

References

- Bell, B. A., Kendall, B. E., Symon, L., Angiographically occult arteriovenous malformations of the brain. *J. Neurol. Neurosurg. Psychiatry* 41 (1978), 1057—1064.
- Bitoh, S., Sakaki, S., Spontaneous cure of dural arteriovenous malformation in the posterior fossa. *Surg. Neurol.* 12 (1979), 111—114.
- Castaigne, P., Buge, A., Pertuiset, B., Laplane, D., Corbin, J., Angiome thrombosé radiologiquement exclu. *Bul. Mém. Soc. Méd. Hôp. Paris* 77 (1961), 923—930.
- Conforti, P., Spontaneous disappearance of cerebral arteriovenous angioma. *J. Neurosurg.* 34 (1971), 432—434.
- Crawford, J. V., Russell, D. S., Cryptic arteriovenous and venous hamartomas of the brain. *J. Neurol. Neurosurg. Psychiat.* 19 (1956), 1—11.
- Cushing, H., Bailey, P., Tumors Arising from the Blood Vessels of the Brain: Angiomatous Malformations and Hemangioblastomas. Springfield, Ill.: Ch. C Thomas. 1982.
- Dyck, P., Spontaneous thrombosis of an arteriovenous malformation. *Neurosurgery* 1 (1977), 287—290.
- Edgar, R., Baldwin, M., Vascular malformations associated with temporal lobe epilepsy. *J. Neurosurg.* 17 (1960), 638—656.
- Eisenman, J. I., Alekoumbides, A., Pribram, H., Spontaneous thrombosis of vascular malformations of the brain. *Acta Radiol. (Diagn.)* 13 (1972), 77—85.
- Endo, S., Kosu, K., Suzuki, J., Spontaneous regression of posterior fossa dural arteriovenous malformation. *J. Neurosurg.* 51 (1979), 715—717.
- Fisher, G., Brunon, J., Thierry, A., Aimard, D., Rochet, N., Mansuy, L., Thrombose au cours de l'évolution des anéurysmes artério-veineux cérébraux (a propos de 2 observations). *J. Méd. Lyon* 50 (1969), 623—625.
- Golden, J. B., Kramer, R. A., The angiographically occult cerebrovascular malformation. Report of three cases. *J. Neurosurg.* 48 (1978), 292—296.
- Hammon, W. M., An unusual angiographic appearance of cerebral arteriovenous malformations. *Amer. J. Roentgen. Radium. Ther. Nucl. Med.* 105 (1969), 326—330.
- Hansen, J. H., Søggaard, I. B., Spontaneous regression of an extra- and intracranial arteriovenous malformation. Case report. *J. Neurosurg.* 45 (1976), 338—341.
- Hoök, O., Johanson, C., Intracranial arteriovenous aneurysms: A follow-up study with particular attention to their growth. *Arch. Neurol. Psychiat.* 80 (1958), 39—54.
- Jabbari, B., Huott, H., Di Chiro, G., Surgically correctable lesions solely detected by CT scan in adult-onset chronic epilepsy. *Ann. Neurol.* 7 (1980), 344—347.
- Johnson, R. T., Radiotherapy of cerebral angiomas. With a note on some problems in diagnosis. In: *Cerebral Angiomas. Advances in Diagnosis and Therapy* (Pia, H. W., *et al.*, eds.), pp. 256—266. Berlin-Heidelberg-New York: Springer. 1975.
- Kamrin, R. B., Buchsbaum, H. W., Large vascular malformation of the brain not visualized by serial angiography. *Arch. Neurol.* 13 (1965), 413—420.
- Kelly, D. L., Alexander, E., Davis, C. H., Maynard, D. C., Intracranial arteriovenous malformations: clinical review and evaluation of brain scans. *J. Neurosurg.* 31 (1969), 422—428.
- Kendall, B. E., Claveria, L. E., The use of computed axial tomography (CAT) for the diagnosis and management of intracranial angiomas. *Neuroradiology* 12 (1976), 141—160.
- Kramer, R. A., Wing, S. D., Computed tomography of radiographically occult cerebral vascular malformations. *Radiology* 123 (1977), 649—652.
- Kushner, J., Alexander, E., Partial spontaneous regressive arteriovenous malformation. *J. Neurosurg.* 32 (1970), 360—366.
- Lakke, J. P. W. F., Regression of an arteriovenous malformation of the brain. *J. Neurol. Sci.* 11 (1970), 489—496.
- Leblanc, R., Ethier, R., Little, J. R., Computed tomography findings in arteriovenous malformations of the brain. *J. Neurosurg.* 51 (1979), 765—772.
- Levine, J., Misko, J. C., Seres, J. L., Snodgrass, R. G., Spontaneous angiographic disappearance of a cerebral arteriovenous malformation. *Arch. Neurol.* 28 (1973), 195—196.
- Lukin, R. R., Chambers, A. A., Tomsick, T. A., Cerebral vascular lesions: infarction, hemorrhage, aneurysm, and arteriovenous malformation. *Semin. Roentgenol.* 12 (1977), 77—89.
- Mabe, H., Furuse, M., Spontaneous disappearance of a cerebral arteriovenous malformation in infancy. Case report. *J. Neurosurg.* 46 (1977), 811—815.
- Magidson, M. A., Weinberg, P. E., Spontaneous closure of dural arteriovenous malformation. *Surg. Neurol.* 6 (1976), 107—110.
- Nehls, D. G., Pittman, H. W., Spontaneous regression of arteriovenous malformations. *Neurosurgery* 11 (1982), 776—780.
- Norlén, G., Arteriovenous aneurysms of the brain. Report of ten cases of total removal of the lesion. *J. Neurosurg.* 6 (1949), 475—494.
- Omojola, M. F., Fox, A. J., Vinuela, F. V., Drake, C. G., Spontaneous regression of intracranial arteriovenous malformations. Report of three cases. *J. Neurosurg.* 57 (1982), 818—822.
- Papatheodorou, C. A., Gross, S. W., Hollin, S., Small arteriovenous malformations of the brain. *Archives of Neurology (Chicago)* 5 (1961), 666—672.
- Pascual-Castroviejo, I., Pascual-Pascual, J. I., Blazquez, M. G., Lopez-Martin, V., Spontaneous occlusion of an intracranial arteriovenous malformation. *Child's Brain* 3 (1977), 169—179.
- Paterson, J. H., McKissock, W., A clinical survey of intracranial angiomas with special reference to their mode of progression and surgical treatment: a report of 110 cases. *Brain* 79 (1956), 233—266.
- Pecker, J., Sabouraud, O., Javalet, A., Les thromboses spontanées des anéurysmes artério-veineux cérébraux. *Neurochirurgie* 7 (1961), 155.
- Pool, J. L., Potts, D. G., Aneurysms and Arteriovenous Anomalies of the Brain. *Diagnosis and Treatment*. New York: Hoeber Medical, Harper and Row. 1965.

37. Porter, A. J., Bull, J., Some aspects of the natural history of cerebral arteriovenous malformation. *Br. J. Radiol.* 42 (1969), 667—675.
38. Sartor, K., Spontaneous closure of cerebral arteriovenous malformation demonstrated by angiography and computed tomography. *Neuroradiology* 15 (1978), 95—98.
39. Sasaki, U., Itagaki, T., Shimizu, H., Almost complete regression of cerebral arteriovenous malformation. Report of a case. *Surg. Neurol.* 4 (1976), 175—178.
40. Scott, B. B., Seegar, J. F., Schneider, R. C., Successful evacuation of a pontine hematoma secondary to rupture of a pathologically diagnosed “cryptic” vascular malformation. Case report. *J. Neurosurg.* 39 (1973), 104—108.
41. Shuey, H. M., Day, A. L., Quisling, R. G., Sypert, G. W., Angiographically cryptic cerebrovascular malformations. *Neurosurgery* 5 (1979), 476—479.
42. Sukoff, M. H., Barth, B., Moran, T., Spontaneous occlusion of a massive arteriovenous malformation. Case report. *Neuroradiology* 4 (1972), 121—123.
43. Svien, H. S., Peserico, L., Regression in size of arteriovenous anomaly. *J. Neurosurg.* 17 (1960), 493—496.
44. Terao, H., Hori, T., Matsutani, M., Okeda, R., Detection of cryptic vascular malformations by computerized tomography. Report of two cases. *J. Neurosurg.* 51 (1979), 546—551.
45. Terbrugge, K., Scotti, G., Ethier, R., Melancon, D., Tchang, S., Milner, K., Computed tomography in intracranial arteriovenous malformations. *Radiology* 122 (1977), 703—705.
46. Wharen, R. E., Scheithauer, B. W., Laws, E. R., Thrombosed arteriovenous malformations of the brain. An important entity in the differential diagnosis of intractable focal seizure disorders. *J. Neurosurg.* 57 (1982), 520—526.

Authors' address: Dr. A. Pasqualin, Dipartimento di Neurochirurgia, Ospedale Civile di Borgo Trento, Verona, Italy.