

Focal Motor Seizures Herald Stroke in Full-term Neonates

Robert Clancy, MD; Seth Malin, MD; Danielle Laraque, MD; Stephen Baumgart, MD; Donald Younkin, MD

• We describe the clinical syndrome, medical management, etiology, and neurologic outcome of stroke diagnosed by computed tomographic scan in 11 full-term neonates encountered during a two-year period. Neonatal stroke is relatively common and may appear in the setting of diverse cerebrovascular disorders such as hypoxic-ischemic encephalopathy, polycythemia, acute severe hypertension, and embolization. Repetitive, persistently unifocal motor seizures heralded localized cerebral injuries in eight infants. The majority of patients did not display any other lateralized clinical neurologic signs. An electroencephalogram revealed a focal or lateralized functional central nervous system abnormality in ten cases. All of the initial computed tomographic scans were focally abnormal. However, cranial ultrasound examinations were insensitive to stroke in nine patients. Medical management included careful cardiorespiratory support, correction of coexisting metabolic or system abnormalities, and aggressive administration of anticonvulsants to promptly eliminate seizures. Limited follow-up suggests that many affected infants may enjoy favorable outcomes.

(AJDC 1985;139:601-606)

Localized nontraumatic cerebral infarction is infrequently diagnosed antemortem in the term neonate.¹⁻⁴ Diffuse encephalopathy is more prevalent, encountered secondary to global

cerebral injuries such as birth asphyxia⁵ or hypoglycemia. Whereas much attention has been focused on the neurologic characteristics and prognosis of the more common diffuse cerebral hypoxia-ischemia, no detailed report has described the simultaneous clinical, neuroradiologic, and electroencephalographic (EEG) correlates and neurologic sequelae of localized cerebral infarction. The clinical recognition of neonatal stroke has been hampered by the low frequency of associated lateralized neurologic signs^{1,3} and the wide recognition that focal motor seizures in the term neonate do not necessarily indicate an underlying discrete structural central nervous system (CNS) lesion. As a result, no general approach for the detection, diagnostic evaluation, medical management, and neurologic prognosis of neonate stroke has emerged.

The purpose of this report is to delineate the clinical syndrome, medical management, etiology, and prognosis of neonatal stroke by describing 11 term neonates with localized cerebral infarction confirmed by computed tomographic (CT) scan. The infants typically presented with a cerebrovascular disorder heralded by repetitive, persistently unifocal motor seizures and definite focal EEG abnormalities but no lateralized abnormality of clinical neurologic and cranial ultrasound examinations.

PATIENT REPORTS

Eleven consecutive full-term infants with CT scan-verified localized cerebral infarction were evaluated by the authors during a 24-month period at three affiliated intensive care nurseries in a large metropolitan area. The cases are summarized in the Table. Three representative patients are described below.

PATIENT 1.—A 3.0-kg female infant was the product of a full-term gestation complicated only by maternal smoking. Apgar scores were 8 and 9 at one and five minutes, respectively, and results of the newborn physical examination were normal. A screening hematocrit determination at the age of 12 hours was 71% and a repeated value at 28 hours was 67%. The infant was orally hydrated and appeared well until her first focal seizure at 48 hours of age. Results of extensive testing for metabolic abnormalities, intoxication, and sepsis were normal. Blood viscosity was 18 centipoise (normal values, 6 to 9 centipoise at a shear rate of 10 s⁻¹). A partial exchange transfusion reduced her hematocrit and blood viscosity to normal. Cerebrospinal fluid, cranial ultrasound examination results, and an echocardiogram were normal. Her EEG revealed voltage attenuation and the absence of a normal transient, *encoche frontale*, in the left frontal area. A CT scan obtained 18 hours after the first seizure revealed a discrete lucency in the left lateral-frontal cortex. She experienced repeated focal seizures characterized by coarse clonic jerking of the right arm and leg and conjugate ocular deviation to the left. Neurologic examination disclosed inactivity, lethargy, and hypotonia but no persistent lateralized signs. A mild postictal right hemiparesis lasted 12 hours. A follow-up CT scan at the age of 3 months showed a persistent stroke (Fig 1). She was neurologically and developmentally normal at 17 months of age.

PATIENT 6.—A 4.2-kg male infant was the product of an uncomplicated full-term gestation to a healthy primigravid 17-year-old woman. Three hours prior to delivery, severe variable fetal heart rate decelerations were observed and meconium was passed. The one-minute Apgar score was 1 and he required vigorous resuscitation in the delivery suite. On the first day of life, he was stuporous, inactive, and hypotonic. His eyes were briefly deviated conjugately to the left but no other lateralized clinical abnormalities were present. Subtle and focal right-sided tonic seizures were recog-

From the Divisions of Neurology (Drs Clancy and Younkin), Neonatology (Drs Malin and Baumgart), and General Pediatrics (Dr Laraque), The Children's Hospital of Philadelphia; and the Departments of Neurology (Drs Clancy and Younkin) and Pediatrics (Drs Clancy, Malin, Laraque, Baumgart, and Younkin), The University of Pennsylvania School of Medicine, Philadelphia.

Reprint requests to Division of Neurology, The Children's Hospital of Philadelphia, 34th Street and Civic Center Boulevard, Philadelphia, PA 19104 (Dr Clancy).

Clinical, EEG, and Radiologic Findings in 11 Infants With Focal Cerebral Injuries*

Patient/Apgar Scores (1 and 5 min)/Birth Weight, kg	Etiology	Coexisting Metabolic Abnormalities	Neurologic Examination	EEG	Cranial Ultrasound	CT Scan	Outcome
1/(8 and 9)/3.0	Polycythemia, hyperviscosity	None	Focal motor seizures, lethargy, transient right hemiparesis, hypotonia	Absent left-sided <i>enchoe frontale</i> , voltage attenuation	Normal (day 1)	Left lateral frontal infarction (day 1)	Normal at 17 mo
2/(8 and 9)/3.5	Polycythemia	None	Focal motor seizures, normal interictal examination results	Focal slowing, sharp waves, seizures right central region	Normal (days 2 and 7)	Infarction in distribution of middle cerebral right artery (day 2)	Normal at 24 mo
3/(5 and 7)/3.9	Postpartum ischemia from acute blood loss	Hypoglycemia (seizures persisted after correction)	Focal motor seizures, lethargy, inactivity, hypotonia, subtle right hemiparesis	Persistently attenuated voltage of left central-temporal regions	Normal (day 3), generalized edema (day 8)	Infarction left temporoparietal areas (day 4)	Right hemiparesis, developmental delay at 17 mo
4/(1 and ?)/3.1	Intrapartum asphyxia	None	Focal motor seizures, lethargy, inactivity, hypotonia	Electrographic seizures confined to left hemisphere	Generalized edema (day 1)	Infarction of left temporoparietal area (day 3)	Normal at 17 mo
5/(4 and 7)/3.3	Intrapartum asphyxia	Hypoglycemia (seizures persisted after correction)	Focal motor seizures, lethargy, inactivity, hypotonia	Electrographic seizures confined to right occipital-central region	Normal (days 1 and 7)	Infarction of right occipitoparietal area (day 2)	Normal at 8 mo
6/(1 and 5)/4.2	Intrapartum asphyxia	None	Subtle and focal motor seizures, lethargy, inactivity, transient gaze paresis	Persistently attenuated voltage of left temporal region, multifocal onset seizures (mostly from left hemisphere)	Normal (day 2)	Infarction in distribution of left middle cerebral artery (day 5)	Survived with no lateralized neurologic signs

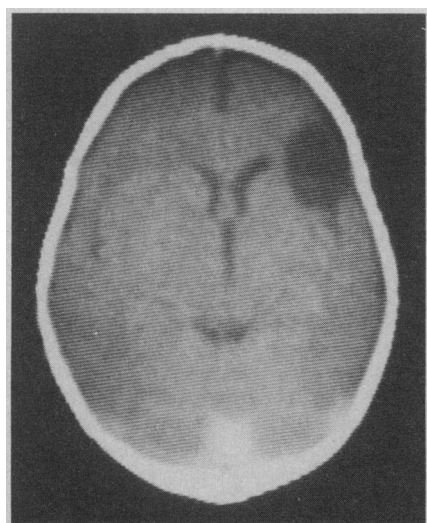


Fig 1.—Patient 1. Follow-up computed tomographic scan at 3 months of age following neonatal polycythemia, hyperviscosity, and right-sided focal clonic seizures shows localized superficial infarction in left frontal cortex in anterior distribution of middle cerebral artery.

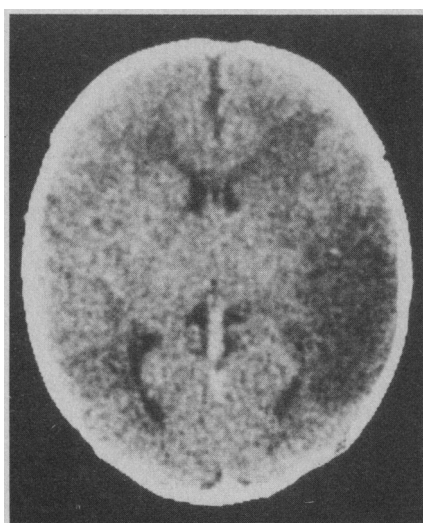


Fig 2.—Patient 10. Computed tomographic scan at 2 days of age demonstrates infarction in distribution of left middle cerebral artery. Cerebral angiography revealed embolic occlusions of trifurcation of left middle cerebral artery and left posterior cerebral artery.

nized clinically. Cranial ultrasound examination results on the second day of life were normal. His EEG was markedly abnormal due to status epilepticus. Over 90% of numerous electrographic seizures arose from the left frontal, central, or temporal regions. An occasional electrographic seizure appeared independently in the right central area. The interictal EEG displayed a striking voltage attenuation and periodic sharp-slow waves in the left temporal area. A phosphorus 31 nuclear magnetic resonance (NMR) spectroscopy examination during recurrent clinical seizures revealed a marked left hemisphere depletion of phosphocreatine and accumulation of inorganic phosphates.⁶ Subsequent NMR spectra did not improve until seizure control was achieved with phenobarbital sodium and phenytoin sodium. A CT scan obtained on the fifth day of life revealed an infarction in the distribution of the left middle cerebral artery. No lateralized clinical neurologic signs were observed on hospital discharge at 2 weeks of age.

PATIENT 10.—A male infant was the

Clinical, EEG, and Radiologic Findings in 11 Infants With Focal Cerebral Injuries (cont)

Patient/Apgar Scores (1 and 5 min)/Birth Weight, kg	Etiology	Coexisting Metabolic Abnormalities	Neurologic Examination	EEG	Cranial Ultrasound	CT Scan	Outcome
7/(9 and 10)/3.2	Hypernatremia, dehydration	Hypernatremia, acidosis, azotemia, hypercalcemia (seizures appeared after metabolic correction)	Focal motor seizures, lethargy, inactivity, hypotonia	Focal slowing and positive sharp waves in right temporal region	Increased echogenicity in right temporal lobe (day 2)	Hemorrhagic infarction, right temporal lobe (day 5)	Normal at 22 mo
8/(8 and 9)/2.0	Acute, prolonged hypertension from renal compression by a mesoblastic nephroma	Hypoglycemia, hyperkalemia, azotemia, acidosis, (seizures persisted after correction)	Multifocal clonic seizures, coma, hypotonia	Focal status epilepticus in both occipitotemporal regions	Diffuse edema (days 2 and 10)	Bioccipital infarctions with luxury perfusion (days 2 and 5)	Microcephaly, developmental delay at 18 mo
9/(9 and 9)/3.7	Embolisms from left atrial wall mass (? mural thrombus vs atrial myxoma)	None	Focal motor seizures, alert, active, normal tone	Normal	Normal (day 3)	Bifrontal infarctions (day 5)	Normal at 20 mo
10/(9 and 10)/4.1	Embolic occlusions of left posterior and middle cerebral arteries from unidentified venous source	None	Focal motor seizures, lethargy, inactivity, mild hypotonia, brief facial asymmetry following seizures	Focal slowing, sharp waves and seizures confined to left central-temporal regions	Absent vascular pulsations of left middle cerebral artery, compression of left lateral ventricle (day 2)	Infarction in distribution of left middle cerebral artery (day 2)	Normal at 5 mo
11/(5 and 9)/3.2	Presumed embolic occlusion from unidentified venous source	None	Lethargy, inactivity, and apnea and bradycardia; minimal right-sided facial flattening; congenital infarction of right arm with angiographically demonstrated subclavian artery embolic occlusion	Marked persistent voltage attenuation of entire left hemisphere	Diffuse edema (day 1)	Infarction in distribution of left internal carotid artery (day 4)	Survived, minimal right-sided facial flattening

*EEG indicates electroencephalography; CT, computed tomographic.

4.1-kg product of a full-term, uncomplicated gestation to a healthy woman. He was delivered by cesarean section for poor labor progress. Apgar scores were 9 and 10 at one and five minutes, respectively, and the newborn physical examination results were normal. His first right-sided focal clonic seizure appeared at 24 hours of age. He became mildly lethargic, inactive, and hypotonic. A transient subtle facial asymmetry briefly followed his seizures but no other lateralized clinical findings were apparent. Cranial ultrasound examination at the age of 2 days revealed absent vascular pulsations in the left middle cerebral artery and an apparent mass effect with compres-

sion and narrowing of the width of the left lateral ventricle. No parenchymal abnormalities were noted. An EEG demonstrated focal slowing, sharp waves, and several seizures confined to the left central and temporal regions. An infarction in the distribution of the left middle cerebral artery was demonstrated by CT scan at 2 days of age (Fig 2). No metabolic or cardiac abnormalities were found. Cerebral angiography revealed normal carotid arteries and embolic occlusions of the left posterior cerebral and the trifurcation of the left middle cerebral arteries. He was developmentally and neurologically normal at 5 months of age.

RESULTS

Clinical Neurologic Signs of Stroke

There were few definite clinical signs revealing the presence of a stroke. Clinical seizures were observed in ten of 11 infants. Unifocal clonic seizures were present in eight patients, multifocal clonic in one patient, and both subtle and unifocal tonic seizures in another patient. In all infants with concurrent metabolic abnormalities (eg, hypoglycemia), seizures persisted despite correction of the derangement. Clinical seizures

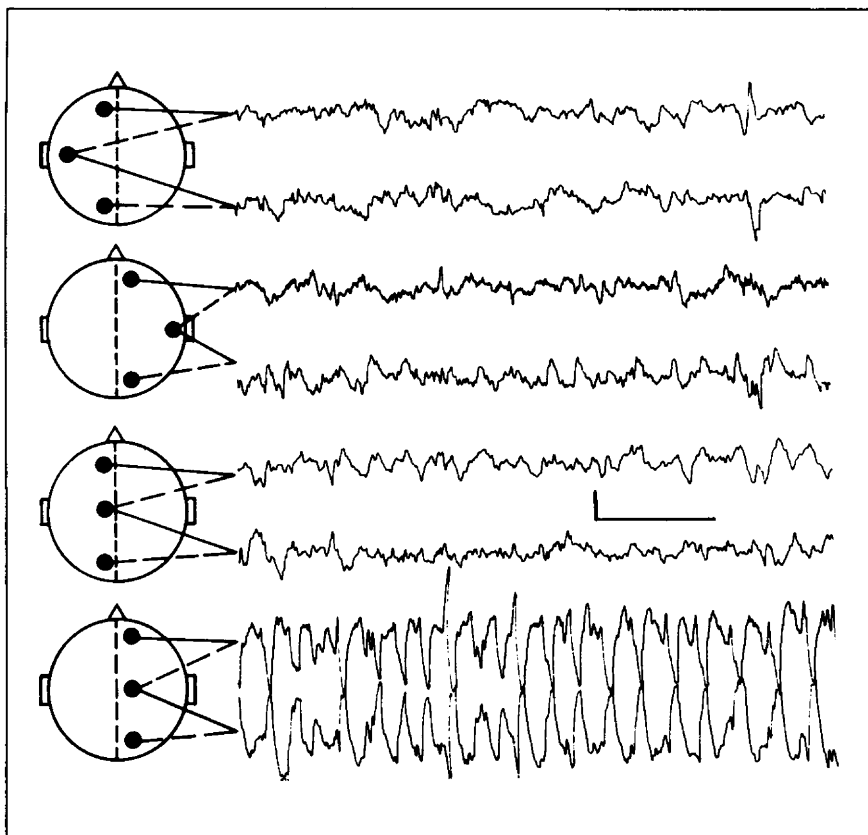


Fig 3.—Patient 2. Electroencephalogram recorded on second day of life from infant with infarction in distribution of right middle cerebral artery. Electrographic seizure is exquisitely confined to right central region (calibration: 50 μ V, 2 s).

were confirmed by recording simultaneous electrographic seizures in six patients. However, clinical observation frequently underestimated the true frequency or duration of seizures. In five infants, one or more definite electrographic seizures were recorded that were not clinically detectable.

The majority of infants showed no interictal lateralized clinical abnormalities. Results of interictal clinical neurologic examinations were normal in two patients; nonlateralized abnormalities (inactivity, generalized hypotonia, and lethargy) appeared in four patients; and a subtle transient postictal hemiparesis appeared in three patients. Only two infants had a mild hemiparesis that persisted through the neonatal period.

EEG

Electroencephalography revealed clear evidence of a localized functional CNS abnormality and correctly sug-

gested the presence and location of a focal structural lesion in ten of 11 patients. The electrographic abnormalities that most consistently correlated with an underlying structural lesion included persistent, localized voltage reduction or attenuation (four cases), prominent focal slowing and sharp waves (four cases), and exquisitely focal or lateralized seizures (five cases) (Fig 3). There was excellent agreement between the site of origin of electrographic seizures and the location of stroke on CT scan.

Cranial Imaging

All of the initial CT scans obtained one to five days following the onset of neurologic signs revealed a localized infarction. The CT appearance of all the lesions was consistent with stroke but none was verified neuropathologically. One was confirmed angiographically. Persistent localized infarction was noted in all seven infants who

underwent a follow-up CT scan examination obtained one to three months after the acute encephalopathy. In comparison, cranial ultrasound examinations obtained one to ten days after the onset of illness were frequently insensitive to stroke. Results of all cranial ultrasound examinations in nine patients were normal or showed diffusely increased "echogenicity." Even with knowledge of the CT location of focal injury, follow-up studies within two weeks of the injury in four patients failed to recognize a discrete lesion.

Etiology

The etiology of stroke in our patients was diverse. No patient had suffered sufficient birth trauma to account for a focal CNS injury and none had undergone temporal artery catheterization.⁷ A definite cerebrovascular disorder was present in ten patients. Four infants sustained a stroke following intrapartum or postpartum hypoxia-ischemia. Two infants were polycythemic at birth and hyperviscosity was documented in one. Acute, severe, prolonged hypertension arising from renal compression and insufficiency was the presumed etiology in one infant. Suspected or definite emboli were responsible for focal CNS injuries in three patients. One infant had two separate frontal infarctions and a left atrial mass on echocardiography compatible with myxoma or a mural thrombus. The second infant had angiographically documented cerebral emboli of an unknown source that may have arisen in the venous system and entered the cerebral circulation through the foramen ovale, which is patent until birth. The third infant was born with a massive infarction of the left cerebral hemisphere and ischemic necrosis of the right arm due to subclavian artery occlusion proved by an arteriogram. Although two separate emboli were strongly suspected as the cause, independent thrombosis of the subclavian and carotid arteries remains a possible explanation.

Medical Management

Initial therapy was directed to general medical support and the aggres-

sive administration of anticonvulsants to control recurrent seizures. General medical treatment included temporary mechanical ventilation in five patients, correction of coexisting metabolic abnormalities in four patients, and systemic conditions (polycythemia and hypertension) in three patients. None of the infants with presumed cerebral emboli were anticoagulated to avoid precipitating a hemorrhagic infarction. Serial EEGs were recorded from the five infants in whom electrographic seizures were inconsistently accompanied by clinical seizures. Combinations of phenobarbital, phenytoin, and diazepam were administered aggressively until all clinical and electrographic seizures were controlled. Anticonvulsants were discontinued at 3 to 6 months of age without recurrence of seizures in nine patients.

Neurologic Outcome

The short-term neurologic outcome of these patients was mixed. Seven infants have been followed up for one year or more. Five appeared entirely well and exhibited normal development, neurologic examination results, and EEGs. The hypertensive infant who experienced prolonged coma and status epilepticus (Table, patient 8) was subsequently microcephalic and developmentally delayed but not hemiparetic. Only one infant (Table, patient 3) had a persistent hemiparesis.

COMMENT

The clinical syndrome of neonatal stroke has been delineated in 11 infants evaluated during a two-year period. Stroke is relatively common in the term neonate but difficult to recognize by clinical examination alone. The majority of infants presented with a cerebrovascular disorder heralded by repetitive, persistently unifocal motor seizures and clear EEG evidence of a focal or lateralized functional abnormality. Although focal seizures may follow diffuse encephalopathies, such as asphyxia or metabolic abnormalities,^{8,10} the persistence of seizures after metabolic correction and the close agreement between the site of origin of electrographic seizures and the CT scan location of the lesions indicate that the strokes caused the

focal seizures. In contrast to the high incidence of unifocal seizures in this group (eight [73%] of 11 patients), a significantly lower incidence (two [8%] of 24 patients) ($\chi^2=12.33$ with 1 df; $P<.01$) of repetitive unifocal EEG seizures was recorded during the same time period in 24 other full-term neonates with strictly global encephalopathies.

The focal or lateralized EEG abnormalities observed in these infants are etiologically nonspecific and are not pathognomonic for stroke. However, their presence emphasizes the value of neonatal EEG in signaling the presence of focal parenchymal injuries as has been recently described by Scher et al.¹¹

Despite the high incidence of unifocal motor seizures and localized EEG abnormalities, the interictal clinical neurologic and cranial ultrasound examinations were frequently insensitive to stroke. These observations are in general agreement with previous reports of stroke in neonates.¹⁴ Barmada et al¹³ reported a 5.4% incidence of cerebral infarctions of arterial origin determined by post-mortem examinations of 592 infants during a four-year period. No lateralized clinical abnormality had been appreciated in any patient but 17% suffered neonatal seizures. Mannino and Trauner¹ described five neonates with strokes diagnosed by CT scan. Four infants had normal cranial ultrasound examination findings. Four also had focal seizures but none displayed lateralized clinical abnormalities. However, Hill et al¹² and Wilson-Davis et al⁴ reported ultrasound stroke detection in a total of seven patients of whom six experienced seizures. Only three patients displayed lateralized clinical signs.

The etiologies of stroke were heterogeneous, but it is apparent that a variety of generalized cerebrovascular disorders can cause localized cerebral infarction in the neonate. Although diffuse cerebral injury usually follows global asphyxia, focal injury may also result.¹² A possible mechanism for this has been suggested by Voorhies et al¹³ who demonstrated cerebral artery occlusion by digital intravenous angiography in two of six severely as-

phyxiated neonates. Similarly, stroke, neonatal seizures, and developmental delay may follow the diffuse encephalopathy of polycythemia and hyperviscosity.¹⁴⁻¹⁶ The pathophysiology of encephalopathy in the hypertensive neonate is unknown but the neurologic signs include coma, hemiparesis, and seizures.¹⁷

Medical treatment of neonatal stroke was conservative and included careful management of cardiopulmonary status and the correction of concurrent metabolic or systemic abnormalities. The treatment of seizures was vigorously pursued. Although these infants' seizures were the result of their stroke, it remains possible that the seizures were not innocent sequelae but were partially responsible for the extent or severity of the focal parenchymal injury. Experimentally induced focal seizures in newborn monkeys elicit a sharp increase of cerebral glucose utilization in several ipsilateral cortical and subcortical structures.¹⁸ Electroencephalographic seizures in the human newborn are virtually always focal or multifocal in onset.¹⁹ Ten of our patients experienced repeated focal seizures and probably had a local increase in the cerebral metabolic rate. An NMR spectroscopy examination in one patient during recurrent seizures arising from the left temporal-central-occipital regions showed a virtual depletion of regional high-energy metabolites that persisted until the seizures were stopped with anticonvulsants. The ischemic nature of these focal cerebral injuries may limit the regional availability of glucose and other metabolic substrates. The resulting uncoupling of cerebral blood flow and metabolism could extend a limited initial injury to cause more severe or extensive localized infarction. The therapeutic implication of these observations is the aggressive use of anticonvulsants to promptly and completely terminate seizures.

Although we are encouraged that many affected infants are neurologically and developmentally normal on short-term follow-up, the long-term effects of stroke on language, cognitive, social, and fine motor development are unknown.

References

1. Mannino FL, Trauner DA: Stroke in neonates. *J Pediatr* 1983;102:605-610.
2. Hill A, Martin DJ, Daneman A, et al: Focal ischemic cerebral injury in the newborn: Diagnosis by ultrasound and correlation with computed tomographic scan. *Pediatrics* 1983;71:790-793.
3. Barmada MA, Moossy J, Shuman RM: Cerebral infarcts with arterial occlusion in neonates. *Ann Neurol* 1979;6:495-502.
4. Wilson-Davis SL, Lo W, Filly RA: Limitations of ultrasound in detecting cerebral ischemic lesions in the neonate. *Ann Neurol* 1983;14:249-251.
5. Fitzhardinge PM, Flodmark O, Fitz CR, et al: The prognostic value of computed tomography as an adjunct to assessment of the term infant with post-asphyxiated encephalopathy. *J Pediatr* 1981;99:777-781.
6. Younkin D, Delivoria M, Wagerle C, et al: In vivo 31-P-NMR spectroscopy in neonatal neurological disorders, in Plum F, Pulsinelli W (eds): *Cerebrovascular Disease: Proceedings of the 14th Princeton-Williamsburg Conference on Cerebrovascular Disorders*. New York, Raven Press, 1985, pp 146-156.
7. Bull MJ, Schreiner RL, Garg BP, et al: Neurologic complications following temporal artery catheterizations. *J Pediatr* 1980;96:1071-1073.
8. Fenichel GM: Convulsions, in Livingstone C (ed): *Neonatal Neurology: Clinical Neurology and Neurosurgery Monographs*. New York, Churchill Livingstone Inc, 1980, pp 20-44.
9. Lombroso CT: Seizures in the newborn period, in Vinken PJ, Bruyn GW (eds): *Handbook of Clinical Neurology*. New York, Elsevier North Holland Inc, 1974, vol 15, pp 189-218.
10. Volpe JJ: Neonatal seizures. *N Engl J Med* 1973;289:413-416.
11. Scher MS, Tharp BR, Sylvestri L: Significance of focal abnormalities in neonatal electroencephalograms: Radiological correlations and outcome, abstracted. *Ann Neurol* 1982;12:217.
12. Fenichel GM, Webster DL, Wong WKT: Intracranial hemorrhage in the term newborn. *Arch Neurol* 1984;41:30-34.
13. Voorhies TM, Lipper EG, Lee BCP, et al: Occlusive vascular disease in severe neonatal hypoxia-ischemia, abstracted. *Ann Neurol* 1983;14:370-371.
14. Black VD, Lubchenco LO, Luckey DW, et al: Developmental and neurological sequelae of neonatal hyperviscosity syndrome. *Pediatrics* 1982;69:426-431.
15. Goldberg K, Wirth FH, Hathaway WE, et al: Neonatal hyperviscosity: II. Effect of partial plasma exchange transfusion. *Pediatrics* 1982;69:419-425.
16. Oski FA, Naiman JL: Polycythemia and hyperviscosity in the neonatal period, in Oski FA (ed): *Hematologic Problems in the Newborn*. Philadelphia, WB Saunders Co, 1982, pp 87-97.
17. Adelman RD: Neonatal hypertension. *Pediatr Clin North Am* 1978;25:99-110.
18. Kato M, Malamut BL, Caveness WF, et al: Local cerebral glucose utilization in newborn and pubescent monkeys during focal motor seizures. *Ann Neurol* 1980;7:204-212.
19. Watanabe K, Hara K, Miyazaki S, et al: Electroclinical studies of seizures in the newborn. *Folia Psychiatr Neurol Jpn* 1977;31:383-392.

In Other AMA Journals

JAMA

Motor Vehicle Childhood Injuries Caused by Noncrash Falls and Ejections

P. F. Agran, MD, MPH; D. E. Dunkle, PhD; D. G. Winn, RN, MPH (*JAMA* 1985;253:2530-2533)

Current and Future Directions for Hospital and Physician Reimbursement

R. G. Petersdorf, MD (*JAMA* 1985;253:2543-2548)

SI Units for Clinical Laboratory Data

Council on Scientific Affairs (*JAMA* 1985;253:2253-2254)

AMA's 'Medicine Today' TV Program

L. D. Grouse, MD, PhD, T. Rockwell, MD (*JAMA* 1985;253:2558-2559)