

Seizures and Cerebral Infarction in the Full-Term Newborn

Susan R. Levy, MD,* Israel F. Abroms, MD,* Paul C. Marshall, MD,* and Elizabeth E. Rosquete, MD†

Cerebral arterial infarction is a more common cause of neonatal seizures than has been previously appreciated. In 50 full-term newborns with seizures studied, 7 had cerebral infarction which was the second most common definable cause of seizures. We describe these 7 full-term infants with cerebrovascular accidents who presented with focal or generalized seizures. Obstetrical histories were normal in 5 of these patients. Their neurological examinations demonstrated lethargy and generalized hypotonia. Electroencephalograms demonstrated focal abnormalities in 4 infants. Computed tomographic scans in the first week of life showed infarctions in 6 newborns and in another at age 6 months. Neonatal stroke should be considered as a cause of seizures in a full-term newborn in spite of a normal obstetrical history and a nonfocal neurological examination.

Levy SR, Abroms IF, Marshall PC, Rosquete EE: Seizures and cerebral infarction in the full-term newborn. *Ann Neurol* 17:366-370, 1985

Cerebral infarction is known to occur in older infants and children [2, 7, 8, 10, 12, 22, 23]. However, arterial cerebral infarction has been documented in a limited number of patients in the neonatal period [1-6, 9, 11, 13, 14, 16, 17, 19-22, 24]. The majority of cases reported have been diagnosed at postmortem examination [2, 3, 5, 6, 9, 11, 20-22]. In a large neonatal postmortem series, the incidence of cerebral infarctions in an arterial distribution in full-term infants was 17% [3]. There have been approximately 25 cases of cerebral arterial infarction reported in living infants, and these were diagnosed recently by cerebral computed tomographic (CT) scanning [1, 4, 13, 14, 16, 17, 19, 24]. The majority of cases occurred in full-term infants presenting with seizures.

We retrospectively studied all cases of seizures in full-term infants admitted to our neonatal nursery over a three-year period to determine the frequency of stroke as a cause. Seven cases of focal cerebral infarction were diagnosed over this period. All infants were full term, and the presenting symptom of stroke was focal or generalized seizures.

Methods

All full-term infants (37 weeks or older) with seizures admitted to the regular newborn nursery or neonatal intensive care unit between December 1980 and December 1983 were studied. Fifty infants were included. Their medical records were reviewed and the etiological nature of the seizures was established on the basis of clinical and laboratory data. Their prenatal and obstetrical records were also analyzed.

Case Reports

Patient 1

A 2,860-gm male infant was delivered at term by cesarean section after an uncomplicated pregnancy. Three hours prior to delivery, fetal monitoring recorded prolonged variable decelerations and late decelerations. At cesarean section, a partial placental abruption was found. The amniotic fluid was thickly meconium stained. Apgar scores were 1 and 6 at 1 and 5 minutes, respectively. Attempts at intubation were unsuccessful but the infant responded to oxygen administered by mask. In the first hours of life, problems included hypotension and bilateral pneumothorax.

At 12 hours of age, he had a right focal motor tonic-clonic seizure lasting 15 minutes. Neurological examination demonstrated generalized hypotonia. There were no further seizures after the administration of phenobarbital. An electroencephalogram (EEG) performed several hours later demonstrated intermittent focal rhythmic, moderate-voltage sharp activity in the left central and midtemporal regions. At 4 days of age, CT scan showed an area of low density in the territory of the left middle cerebral artery.

At 11 months of age, he had a 20-minute generalized seizure associated with a high fever which was treated with phenobarbital. At this writing the patient is 14 months of age and has a mild right hemiparesis, but cognitive development is normal.

Patient 2

A 3,650-gm male infant was born to a healthy woman at term. Pregnancy was complicated by mild hypertension during the last three weeks. Five hours after the onset of labor, epidural anesthesia was administered. The maternal blood

From the *Departments of Pediatrics and Neurology, University of Massachusetts Medical School, 55 Lake Ave, North, and †Department of Pediatrics, University of Massachusetts Medical School and Department of Neonatology, Worcester Memorial Hospital, Worcester, MA 01605.

Received June 26, 1984, and in revised form Sept 26. Accepted for publication Sept 28, 1984.

Address reprint requests to Dr Abroms.

pressure fell immediately to 50/0. Ephedrine and oxygen were given. Coincidental with maternal hypotension, there was fetal bradycardia and decreased variability in the fetal heart rate. The maternal blood pressure and fetal heart record returned to normal within 20 minutes. Delivery took place 8 hours later, and the amniotic fluid was meconium stained. Apgar scores were 8 and 8 at 1 and 5 minutes, respectively. The infant lost approximately 10 ml of blood after the cord clamp became dislodged in the delivery room. He developed respiratory distress and peripheral vasospasm. After volume expansion, these problems resolved and at that time the findings on neurological examination were normal.

At 3 days of age, he had the first of several generalized seizures which responded to treatment with intravenous phenobarbital. The neurological examination in the interictal period and after phenobarbital administration demonstrated lethargy and generalized hypotonia. An EEG performed on the fourth day after birth demonstrated short bursts of moderate-voltage sharp activity over the left frontotemporal area. A CT scan done on the same day showed an area of decreased density in the territory of the left anterior cerebral artery (Fig 1). The infant was discharged on the eighth day with normal neurological findings. At the time of this report he is 14 months of age and has had no further seizures. He has a mild right hemiparesis but has normal cognitive skills. A follow-up CT scan showed an area of decreased density in the distribution of the left anterior cerebral artery and atrophy of the left hemisphere (see Fig 1).

Patient 3

A 3,770-gm male infant was delivered by cesarean section because of a footling-breech presentation at term, after an uncomplicated pregnancy. There was no apparent fetal distress. Apgar scores at 1 and 5 minutes were 9 and 10, respectively.

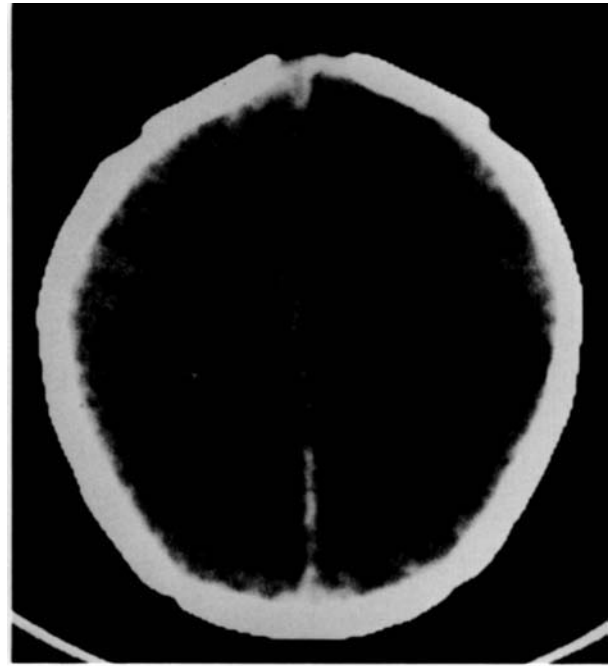The newborn neurological findings were normal. At 27 hours of age, he had a generalized seizure. He had several more generalized seizures in the ensuing 12 hours despite treatment with phenobarbital and phenytoin. The neurological examination after medication demonstrated generalized hypotonia. An EEG done within several hours of the onset of seizures contained spike and sharp-wave activity throughout the left hemisphere. A CT scan done at age 2 days showed an area of low density in the left frontoparietal area.

At the time of discharge, there was less spontaneous movement of the right hand than the left. At the time of this report the patient is 3 years old and has had no further seizures. He does have a spastic right hemiparesis and is language delayed.

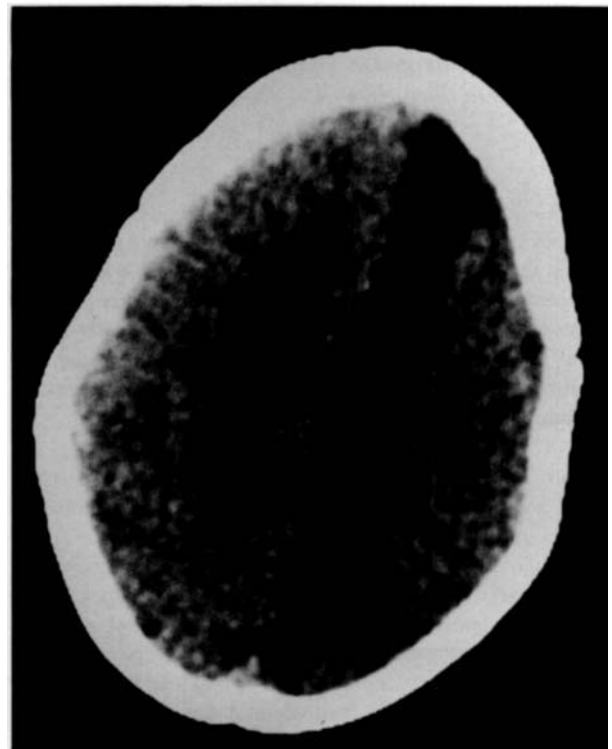Patient 4

A full-term 3,080-gm male infant was born after an uncomplicated pregnancy. Delivery was by repeat cesarean section under epidural anesthesia. Apgar scores were 8 and 9 at 1 and 5 minutes, respectively.

The infant was normal until 12 hours of age when he had the first of several right focal tonic-clonic seizures of the right extremities with head and eye deviation to the right. The infant was found to be hypoglycemic and required intravenous glucose supplementation over the ensuing four days.



A



B

Fig 1. Patient 2: (A) Initial CT scan at 4 days of age showing area of hypodensity in the territory of left anterior cerebral artery (right side of figure). (B) Follow-up CT scan at 6 months of age demonstrating smaller left cerebral hemisphere and further definition of hypodense area.

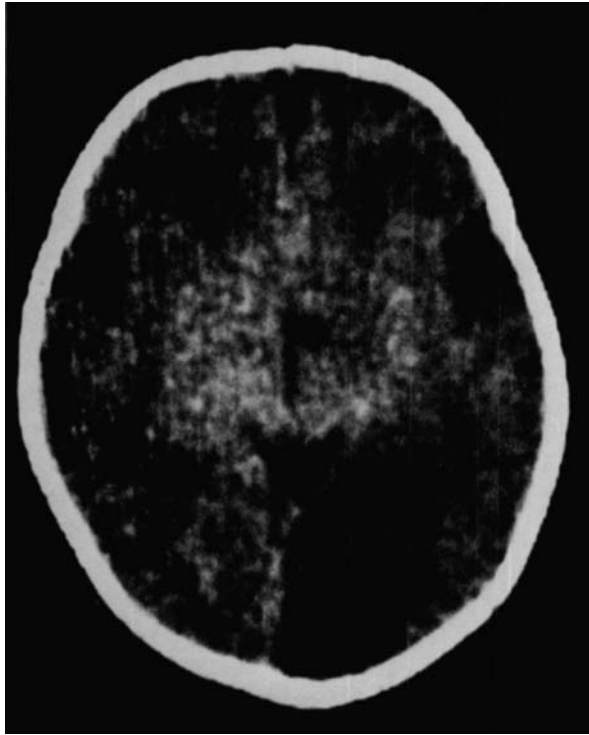


Fig 2. Patient 4: CT scan at 5 days of age demonstrating hypodense region in the distribution of the left posterior cerebral artery.

An EEG done on the day following seizures when the head and eyes were still deviated to the right was normal. A CT scan on the fifth day of life showed an area of low density in the distribution of the left posterior cerebral artery (Fig 2).

The infant was discharged on the eighth day with a persistent right gaze preference. At 22 months of age, he was developmentally normal but had a right homonymous hemianopia.

Patient 5

A 3,800-gm full-term male infant was born after an uncomplicated pregnancy and labor by spontaneous vaginal delivery. Fetal monitoring during labor revealed no abnormalities. Apgar scores were 9 and 10 at 1 and 5 minutes, respectively.

The infant appeared normal until 36 hours of age when he had a generalized tonic-clonic seizure. There were no further seizures after an intravenous phenobarbital load was administered. Later the same day, neurological examination demonstrated generalized hypotonia. An EEG performed at 2 days of age was normal. A CT scan at 7 days of age showed an area of low density in the left parietal lobe.

At the time of discharge, the findings on neurological examination were normal. At 4 months of age, the infant had had no further seizures and was developmentally normal.

Patient 6

A 3,870-gm male infant was born at term after an uncomplicated pregnancy, labor, and delivery. Apgar scores were 9 and 9 at 1 and 5 minutes, respectively.

The infant did well for the first 2 days of life except for some difficulties with feeding secondary to a poor sucking reflex. At age 48 hours, there was a right-sided focal tonic-clonic seizure. Administration of intravenous phenobarbital terminated the seizure. Later, neurological examination demonstrated generalized hypotonia. An EEG done on the day following the seizure was normal. A CT scan done on the fifth day of life showed small areas of infarct in the left thalamus and left frontal lobe.

At 14 months of age the patient had had no further seizures. His motor development has been normal, but he has a mild language delay.

Patient 7

A full-term 3,400-gm male infant was born after an uncomplicated pregnancy. There were no signs of fetal distress during labor. Delivery was vaginal and vacuum extraction was utilized. Apgar scores were 8 and 9 at 1 and 5 minutes, respectively. The infant appeared normal until 8 hours of age when he had the first of five cyanotic episodes associated with generalized stiffening and eye fluttering. After the administration of intravenous phenobarbital, there were no further seizures and the neurological examination revealed generalized hypotonia. An EEG done on the second day of life showed intermittent moderate-voltage sharp activity over the left central and posterior temporal regions. A CT scan was performed at 24 hours of age and showed diffuse cerebral edema.

At 6 months of age the infant had a mild right hemiparesis. He had had no further seizures. A CT scan performed at that time showed an area of low density in the area supplied by the left middle cerebral artery.

Discussion

During the three-year period, 50 full-term infants in the newborn unit were studied because of seizures. The causes of the seizures are listed in the Table. Twenty-six infants were asphyxiated at the time of birth and subsequently seizures developed. CT scans were not routinely performed at that time on asphyxiated infants in our nursery; however, 14 patients in this group were scanned and no focal abnormalities were found. In the other 24 patients, cerebral infarction was the most common definable cause of seizures and occurred in 7 newborns. There were single cases of holoprosencephaly, Arnold-Chiari malformation, encephalocele, group B streptococcal meningitis, viral encephalitis, subarachnoid hemorrhage, narcotic withdrawal, and citrullinemia. One of the 2 patients with intraventricular hemorrhage was also hypocalcemic. No cause could be found in the 7 remaining cases.

Six of the 7 full-term male infants with generalized or focal seizures had been admitted to the normal newborn nursery. Only 1 of these infants (Patient 2) had had any difficulties during labor and delivery. One other infant (Patient 1) was admitted to the intensive care unit because of documented distress during labor and delivery. This was the only infant with low Apgar

Causes of Seizures in Full-Term Newborns, 1980–1983

Hypoxic-ischemic encephalopathy	26
Cerebral infarction	7
Cerebral malformation	3
Central nervous system infection	2
Subarachnoid hemorrhage	1
Intraventricular hemorrhage	2
Drug withdrawal	1
Inborn error of metabolism	1
Unknown	7
Total	50

scores. Obstetrical histories were therefore normal in 5 of the 7 patients.

The seizures occurred between 8 and 72 hours after birth and were controlled with phenobarbital except in Patient 3 in whom a second anticonvulsant was required. Three had focal motor seizures and 4 had generalized seizures. In 6 of the patients, the neurological findings were nonfocal and examination demonstrated lethargy and generalized hypotonia. Six cerebral infarcts were diagnosed by CT scan between 2 and 7 days of age. One infarct was not diagnosed until 6 months of age when focal neurological signs were recognized, and the CT scan was repeated (Patient 7). In 4 of the patients, including 3 with generalized seizures, EEG showed abnormal focal sharp activity on the side of the infarction. In all patients, metabolic studies, hematocrits, platelet counts, and cerebrospinal fluid studies were normal and none had had arterial catheters inserted or had congenital heart disease. All infarctions occurred in the left hemisphere, and in 4 patients the middle cerebral artery territory was affected. One infarct involved the distribution of the left anterior cerebral artery and one the left posterior cerebral artery. In Patient 6 there were multiple areas of infarct. It is curious that all infarcts were in the left hemisphere. There were no angiographic studies done to evaluate the cranial vasculature.

Follow-up in our series ranges from four months to three years. All patients continued to exhibit mild abnormalities on neurological examination as of this writing. Four have a right hemiparesis. Two patients are language delayed. Additional neurological sequelae, including further language difficulties, may become apparent in later childhood. Only 1 child has had further seizures. It is worth noting that in a large follow-up series of infants who had had perinatal asphyxia, later seizures were uncommon unless motor deficits were also present [18].

The pathogenesis of the arterial occlusions for most reported cases has been speculative. Theories have included cerebral embolism from the placenta or systemic circulation. Gross [11] in 1945 described 2 in-

fants with massive cerebral infarction. He postulated the cause to be embolization of thrombi formed in involuting fetal vessels. Clark and Linell [5] in 1954 reported a case of an infant with erythroblastosis with embolic occlusion of the internal carotid artery at its bifurcation. It was postulated that the necrotic material occluding the vessel was placental tissue as the placenta contained small infarcts. Cocker and associates [6] reported 2 cases of middle cerebral artery occlusion that were believed to be secondary to emboli from the fetal veins of the placenta. Embolism derived from catheterized vessels has also been reported [22]. In Barmada's [3] autopsy series, disseminated intravascular coagulation and sepsis were believed to play a significant role in the pathogenesis of cerebral embolic arterial occlusions. The finding of multiple infarcts in our Patient 6 suggests cerebral embolism although no source was found. Thrombosis of major cerebral vessels may occur with polycythemia [1] and trauma [21, 25]. Yates [25] in 1959 in a neonatal autopsy series reported several cases of direct trauma to the vertebral arteries. In one case, there was complete occlusion of the left vertebral artery by a thrombosis. Roessman and Miller [21] in 1980 described an infant who died at 4 days of age after a traumatic delivery. At postmortem examination there was a thrombosis of the middle cerebral artery that was considered to be secondary to direct trauma. It remains unclear why, in certain instances, generalized perfusion disturbances have resulted in focal cerebral abnormalities. Volpe [24] has questioned whether there may be some variability in the development of brain metabolism yielding differences in regional vulnerability to ischemia.

There are similarities between our 7 cases and other previously reported cases of neonatal cerebral infarction. It is important to stress that the obstetrical histories were normal in 5 of our patients. This finding is in concordance with 2 recent cases reported [17]. In those cases, cerebral infarction occurred without evidence of predisposing clinical conditions. Most cases have presented with focal or generalized seizures, or both [4, 13, 14, 16, 17]. Neurological examinations have not demonstrated lateralizing signs in most cases. In other reported cases patients have also exhibited signs of hemiparesis on follow-up. EEGs have shown focal abnormalities in several previously reported cases. CT scans have revealed infarction in all living patients and the middle cerebral artery distribution has been the site most frequently affected. CT scanning is imperative to make this diagnosis. If initial CT scans are normal in full-term infants with focal or generalized seizures, the scan may need to be repeated, especially if the EEG shows persistent focal abnormalities. It is clear that the absence of focal seizures and lateralizing signs on neurological examination does not exclude the possibility of a focal cerebral infarction. It is

noteworthy that in a recent review of neonatal seizures, Lombroso [15] detailed the changing trends in the incidences of etiological factors in two 10-year studies of neonates ending in 1979. Neonatal stroke is not included as a cause in that report as the studies reflect a population of patients evaluated prior to frequent neonatal CT scanning.

Perhaps as more infants with focal cerebral insults are studied with newer techniques, such as positron emission tomography and the different modalities of magnetic resonance imaging, additional information will be gained regarding the metabolism of the developing brain and its reaction to ischemia. It is possible these techniques may uncover clinically silent neonatal infarctions that could be a cause of focal seizures later in infancy or childhood.

References

1. Amit M, Camfield PR: Neonatal polycythemia causing multiple cerebral infarcts. *Arch Neurol* 37:109-110, 1980
2. Banker BQ: Cerebral vascular disease in infancy and childhood. *J Neuropathol Exp Neurol* 20:127-140, 1961
3. Barmada MA, Moossy J, Shuman RM: Cerebral infarcts with arterial occlusion in neonates. *Ann Neurol* 6:495-502, 1979
4. Clancy RR, Malin S, Laraque D, Baumgart S: Focal motor seizures heralding strokes in neonates and infants (abstract). *Ann Neurol* 14:370, 1983
5. Clark RM, Linell EA: Case report: prenatal occlusion of the internal carotid artery. *J Neurol Neurosurg Psychiatry* 17:295-297, 1954
6. Cocker J, George SW, Yates PO: Perinatal occlusion of the middle cerebral artery. *Dev Med Child Neurol* 7:235-243, 1965
7. Daniels SR, Bates S, Lukin RR, et al: Cerebrovascular arteriopathy (arteriosclerosis) and ischemic childhood stroke. *Stroke* 13:360-365, 1982
8. Eeg-Olofsson O, Ringheim Y: Stroke in children. Clinical characteristics and prognosis. *Acta Paediatr Scand* 72:391-395, 1983
9. Friede RL: *Developmental Neuropathology*. New York, Springer-Verlag, 1975
10. Gold AP, Challenor YB, Gilles FH, et al: Report of Joint Committee for Stroke Facilities. IX. Strokes in children. Part I. *Stroke* 4:835-894, 1973
11. Gross RE: Arterial embolism and thrombosis in infancy. *Am J Dis Child* 70:61-73, 1945
12. Harvey FH, Alvard EC: Juvenile cerebral arteriosclerosis and other cerebral arteriopathies of childhood—six autopsied cases. *Acta Neurol Scand* 48:479-509, 1972
13. Hill A, Martin DJ, Daneman A, Fitz CR: Focal ischemic cerebral injury in the newborn: diagnosis by ultrasound and correlation with computed tomographic scan. *Pediatrics* 71:790-793, 1983
14. Korobkin R: Congenital hemiplegia. In Korobkin R, Guilleminault C (eds): *Progress in Perinatal Neurology*, Vol 1. Baltimore, Williams & Wilkins, 1981
15. Lombroso CT: Prognosis in neonatal seizures. Delgado-Escueta AV, Wasterlain CG, Treiman DM, Porter RJ (eds): *Advances in Neurology*, Vol 34. New York, Raven, 1983
16. Mannino FL, Trauner DA: Stroke in neonates. *J Pediatr* 102:605-609, 1983
17. Mantovani JF, Gerber GJ: "Idiopathic" neonatal cerebral infarction. *Am J Dis Child* 138:359-362, 1984
18. Nelson KB, Ellenberg JH: An epidemiologic approach to the problems of cerebral palsy. In Fukuyama Y, Arima M, Maekawa K, Yamaguchi K (eds): *Child Neurology (International Congress Series #579)*. Amsterdam, Excerpta Medica, 1981, pp 341-350
19. Ong BY, Ellison PH, Browning C: Intrauterine stroke in the neonate. *Arch Neurol* 40:55-56, 1983
20. Pollack MA, Llena JF, Fleischman A, Fish B: Neonatal brainstem infarction. *Arch Neurol* 40:52-53, 1983
21. Roessmann U, Miller RT: Thrombosis of the middle cerebral artery associated with birth trauma. *Neurology* 30:889-892, 1980
22. Ruff RL, Shaw C-M, Beckwith JB, Iozzo RV: Cerebral infarction complicating umbilical vein catheterization. *Ann Neurol* 6:85, 1979
23. Schoenberg BS, Mellinger JF, Schoenberg DG: Cerebrovascular disease in infants and children: a study of incidence, clinical features and survival. *Neurology* 28:763-768, 1978
24. Volpe JJ: *Neurology of the Newborn*. Philadelphia, Saunders, 1981
25. Yates PO: Birth trauma to the vertebral arteries. *Arch Dis Child* 34:436-441, 1959