

THE ANATOMICAL BASIS OF SYMPTOMATIC HEMIDYSTONIA

by C. D. MARSDEN¹, J. A. OBESO², J. J. ZARRANZ³ and A. E. LANG⁴

(From the ¹University Department of Neurology, King's College Hospital Medical School and Institute of Psychiatry, London, ²Movement Disorders Unit, Department of Neurology, Clinica Universitaria, University of Navarra Medical School, Pamplona, ³Section of Neurology, Ciudad Sanitaria, 'Enrique Sotomayor' and Catedra de Neurologia, University of Bilbao, Bilbao, Spain and ⁴Division of Neurology, Toronto Western Hospital, Toronto, Ontario, Canada)

SUMMARY

Twenty-eight patients with focal (arm or leg) or hemidystonia due to tumour, arteriovenous malformation, infarction, haemorrhage or hemiatrophy are described. All had typical dystonic movements and/or postures, identical to those seen in idiopathic (primary) torsion dystonia. The site(s) of the lesion responsible, as defined by CT (computerized tomography) scan or pathological examination, was in the contralateral caudate nucleus, lentiform nucleus (particularly the putamen) or thalamus, or in a combination of these structures. Review of 13 other patients in the literature with hemidystonia and lesions defined by CT scan, and of 7 other patients with pathologically discrete lesions associated with hemidystonia, also indicated involvement of these structures. Dystonia may be due to abnormal input from thalamus to premotor cortex, due to lesions either of the thalamus itself, or of the striatum projecting by way of the globus pallidus to the thalamus.

INTRODUCTION

Torsion dystonia is characterized by inappropriate prolonged muscle contractions which forcefully distort the body into typical postures. Dystonia often initially occurs on action, but if more advanced it may be present at rest. Clinical and electrophysiological observations have shown that dystonic movements and postures are due to prolonged abnormal cocontraction of agonist and antagonist muscles, with abnormal recruitment ('overflow') of distant muscles during movement (Oppenheim, 1911; Foerster, 1921; Herz, 1944; Rothwell *et al.*, 1983). These characteristics distinguish torsion dystonia from other abnormal movements and from other abnormal postures such as decerebrate rigidity, spastic dystonia due to corticomotoneuron damage or the flexion dystonia of Parkinson's disease (Denny-Brown, 1968). The term athetosis, as introduced by Hammond in 1871, refers to dystonic movements of the fingers and toes.

Torsion dystonia is generally considered to be a disease of the basal ganglia, but the evidence for this is still inconclusive. Disorders which may produce torsion dystonia, such as Wilson's and Leigh's diseases or carbon monoxide intoxication, are often not restricted pathologically to the basal ganglia. On the other hand, well-documented reports of patients with dystonia secondary to focal brain lesions are rare (Zeman and Whitlock, 1968; Narbona *et al.*, 1984). We have reviewed a series of 28 personally studied patients with focal dystonia or hemidystonia, in whom a localized brain lesion could be defined. A few of these patients, who showed special clinical features, have been reported before as separate cases (Brett *et al.*, 1981; Narbona *et al.*, 1984; Obeso *et al.*, 1984).

TABLE 1. CLINICAL DATA OF 28 PATIENTS WITH SYMPTOMATIC FOCAL OR HEMIDYSTONIA

Case	Sex	Age at study (yrs)	Age at onset of dystonia (yrs)	Duration of dystonia (yrs)	Interval between onset of lesion and onset of dystonia	Site of onset of dystonia	Spread of dystonia
1	F	13	12	1	0	L hand	None
2 ^a	M	8	8	0.3	0	L hand	L arm and leg
3	M	38	37	0.5	0	Neck	None
4	F	44	43	1	0	Neck	None
5	F	10	9	1	0	R hand	R arm and leg
6	M	20	1	19	0	L arm and leg	None
7 ^b	F	15	5	10	1 wk	R arm and leg	None
8	M	14	8	6	2 yrs	L hand	L arm and leg
9	F	23	4	19	0	L foot	None
10	F	76	68	8	2 mo	R hand	None
11 ^c	F	22	21	2	2 mo.	L arm and foot	None
12	F	64	62	2	6 mo	L hand	None
13	M	61	60	1	9 mo	L arm and leg	None
14	F	32	22	10	0	L foot	L leg and arm
15	M	14	9	5	0	R arm	None
16	M	17	17	0.2	0	L hand	L arm
17	M	10	10	0.1	0	R hand	R arm and leg
18	M	36	7	29	4 yrs	R arm and leg	None
19	F	55	52	3	4 mo	R hand and foot	None
20	M	55	51	4	6 mo.	R foot	None
21	F	53	50	2	1 yr	L limbs	None
22	F	60	51	9	3 yrs	L hand	L arm and leg
23	M	62	62	0.3	0	L hand	None
24	F	12	6	6	0	L arm	None
25	M	11	4	7	4 mo.	R arm and leg	None
26	F	17	1	16	1 yr	L arm and leg	None
27	F	21	17	4	14 yrs	R foot	R leg and arm
28	M	12	7	5	1 mo.	L arm and leg	None

^a Previously reported by Narbona *et al.* (1984). ^b Previously reported by Brett *et al.* (1981). ^c Previously reported by Obeso *et al.* (1984).

TABLE 2. TOPOGRAPHY AND AETIOLOGY OF DISCRETE LESIONS CAUSING FOCAL OR HEMIDYSTONIA IN 13 PATIENTS

<i>Case</i>	<i>Site of dystonia</i>	<i>Type of dystonia*</i>	<i>Aetiology</i>	<i>Topography by CT scan</i>
1	L hand	SA	Glioma ^a	R lenticulocapsulothalamic
2	L hemidystonia	SAM	Astrocytoma ^c	R lentiform nucleus
3	Torticollis (head rotated to L)			
4	Torticollis (head rotated to L)	SM	A-V malformation ^c	Head of R caudate nucleus
5	R hemimyoclonic dystonia	SM	A-V malformation ^a	Head of R caudate nucleus
6	L hemidystonia	AM	A-V malformation ^b	R lenticular nucleus
7	R hemidystonia	SAM	Infarction ^a	Head of R caudate nucleus
8	L hemidystonia	SAM	Traumatic infarction ^a	L lentiform nucleus
9	L foot	SAM	Traumatic infarction ^b	R capsulolenticular
10	R hand	SAM	Infarction ^a	R capsulolenticular
11	L hand	AM	Infarction ^a	L posterolateral thalamus
12	L hand	AM	Infarction ^b	R posterolateral thalamus
13	L hemidystonia	SAM	Infarction ^a	R posterolateral thalamus
			Haemorrhage ^a	R posterolateral thalamus

* Type of dystonia: S = spontaneous dystonia. A = intensified by action. M = mobile dystonic spasms causing repetitive dystonic postures. F = fixed, present at rest and action, but not intensified by action; no mobile dystonic spasms.

^a Diagnosis established by CT scan. ^b Diagnosis established by CT scan and angiography. ^c Diagnosis established by histology.

THE PATIENTS

The 28 patients with focal dystonia or hemidystonia secondary to a localized brain lesion included in this study were selected from a larger group of patients with symptomatic dystonia. Inclusion criteria were that the clinical characteristics of the focal dystonia or hemidystonia were identical to dystonic movements and postures present in patients with idiopathic torsion dystonia. The topography and aetiology of the lesions were defined by CT scan studies in all patients. Postmortem pathological study was carried out in 1 patient and biopsy of the lesion was undertaken in 4 cases.

The general clinical data of the 28 patients are summarized in Table 1. The pathology and CT scan localization of their lesions are shown in Tables 2 and 3. From the point of view of clinicopathological correlation we have separated our patients into two groups: (1) patients with dystonia secondary to a relatively small discrete brain lesion (Table 2); (2) patients with dystonia secondary to a large lesion affecting several brain structures (Table 3). Within each group the patients have been ordered according to the pathological nature of their lesion. Representative cases are illustrated at length.

TABLE 3. TOPOGRAPHY AND AETIOLOGY OF LARGE LESIONS CAUSING FOCAL OR HEMIDYSTONIA IN 15 PATIENTS

Case	Site of dystonia	Type of dystonia*	Aetiology	Topography by CT scan
14	L foot	A	Astrocytoma ^c	R frontocaudate
15	R arm	SAM	Glioma ^b	L lenticulothalamocaudate
16	L arm	SAM	Astrocytoma ^c	R lenticulothalamocaudate
17	R hemidystonia	AM	A-V malformation ^c	L frontolenticulothalamocaudate
18	R hemidystonia	SAM	Traumatic infarction ^a	L lenticulocapsulocaudate
19	R hemidystonia	SA	Thrombotic infarction ^a	L lenticulocapsulocaudate
20	R foot	SA	Thrombotic infarction ^a	L lenticulocapsulocaudate
21	L hemidystonia	SA	Embolic infarction ^a	R lenticulocapsulocaudate
22	L hemidystonia	SAM	Thrombotic infarction ^a	R lenticulocapsulocaudate
23	L hand	SAM	Embolic infarction ^b	R parietothalamic
24	L hemidystonia	SAM	Tuberculous meningitis	R hemiatrophy, R frontocaudate infarction
25	R hemidystonia	SAM	Birth anoxia ^a	L hemiatrophy
26	L hemidystonia	SAM	Birth anoxia ^a	R hemiatrophy
27	R hemimyoclonic dystonia	SAM	Infantile epilepsy and hemiplegia ^a	L hemiatrophy
28	L hemidystonia	SAM	Infantile epilepsy and hemiplegia ^a	R hemiatrophy

* Type of dystonia: abbreviations as in Table 2. ^a Diagnosis established by CT scan. ^b Diagnosis established by CT scan and angiography. ^c Diagnosis established by histology.

CASE HISTORIES

Discrete Lesions

Focal or Hemidystonia Secondary to Restricted Basal Ganglia Tumour

Case 1. A 13-year-old girl was the product of a normal pregnancy and birth, and psychomotor development was normal. There was no family history of neurological disease. Involuntary movements affecting her left hand started insidiously around April 1978. She did not describe weakness, sensory loss or paresthesiae. Examination in May 1979 revealed a marked dystonic posture of the left upper limb at rest. This consisted of extension of the wrist and first metacarpophalangeal joints with flexion of the fingers and abduction of the thumb (fig. 1A, B). There were no superimposed dystonic spasms, but the abnormal posture was greatly aggravated by actions such as holding the arm outstretched or writing. Dystonia interfered with tests of coordination of the left arm. Tone in the left hand, wrist and forearm was increased in all directions of passive movement throughout the range of movement. There was no tremor. Power was normal as were the tendon reflexes, and both plantar responses were flexor. Sensory examination, speech, the cranial nerves and intelligence were all normal. CT brain scan showed a lesion of the right lentiform nucleus, intruding into the right ventrolateral thalamic nuclei, which enhanced after contrast injection (fig. 1C); it distorted the third ventricle, and higher CT cuts indicated mild hydrocephalus. A right carotid angiogram ruled out an arteriovenous malformation. The CT scan appearance suggested a glioma. Accordingly, the ventricles were shunted and the patient received radiotherapy directed to the lesion (50 Gy per day over eight weeks). Subsequently, the dystonia of the left arm gradually improved and the CT scan lesion resolved. When she was last examined in December 1983, the dystonia of the left hand had almost disappeared (fig. 1D). The patient was then capable of carrying out all kinds of manual tasks, such as typing and writing.

Case 2. This patient has been reported in detail previously by Narbona *et al.* (1984). The present description is therefore a summary. An 8-year-old boy was first seen in August 1979 with a four-month history of abnormal postures and involuntary movements of the left limbs. His past medical and family

history was unremarkable. Symptoms had begun with the left hand adopting unwanted postures on action. This progressed to involve all manual activity. Three months after the onset of symptoms in the left hand, the left foot also became affected, showing plantar flexion and inversion on walking. Examination revealed a dystonic posture of the left arm on action, with the wrist going into ulnar deviation and slight flexion, and the fingers extending. The outstretched left arm also adopted a similar posture, with additional excessive pronation. At rest, the left foot was inverted and plantar flexed, with a tendency for the left hallux to extend spontaneously. Power, sensation and tendon reflexes were normal in the affected limbs. The rest of the neurological examination was normal. A CT scan in September 1979 revealed a high density lesion with an area of low attenuation within its anterior extent, which enhanced with contrast, in the right lentiform nucleus; it did not cause displacement. Six

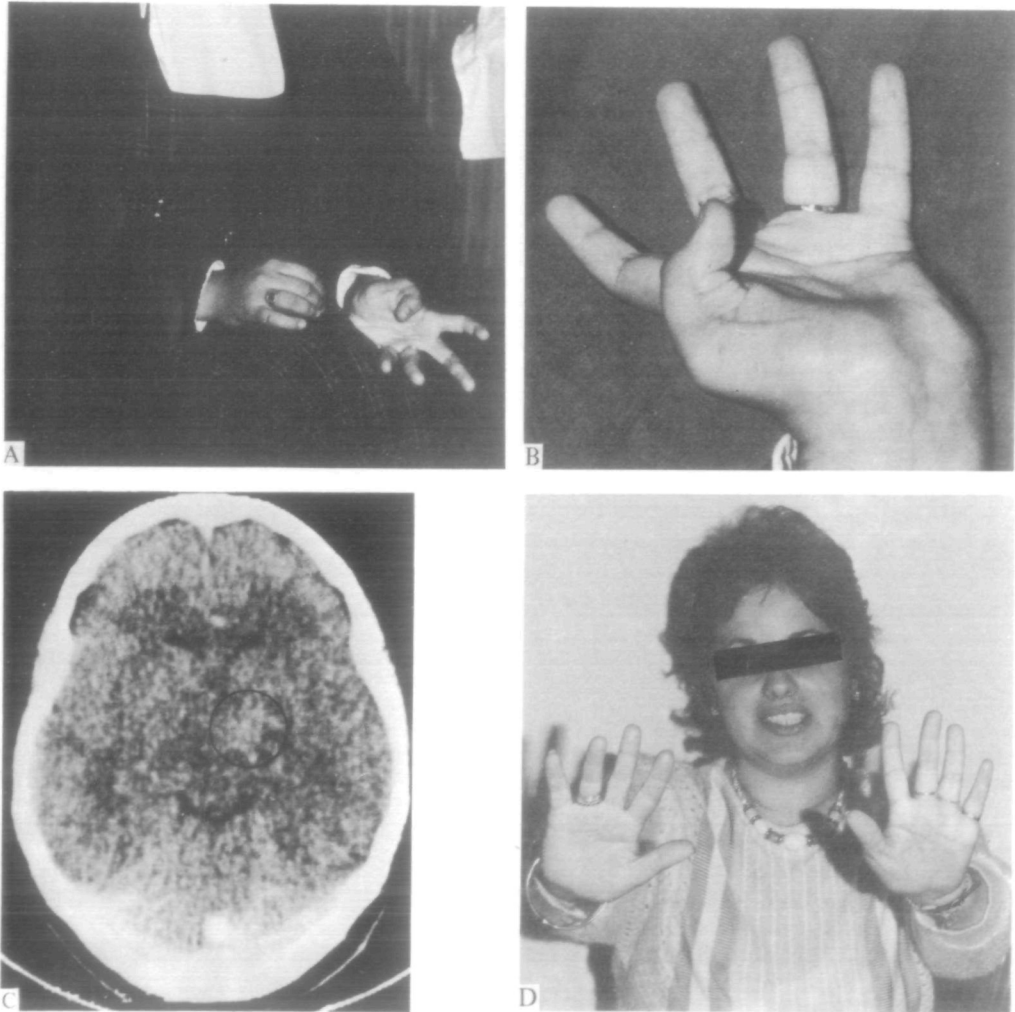


FIG. 1. *Case 1.* A and B show dystonic posture of left hand. C, CT scan with contrast showing high density lesion in region of right lenticular nucleus, internal capsule and thalamus (enclosed in circle). D, same patient four years later after treatment with radiotherapy.

months after the onset of the hemidystonia, the left arm became clumsier and walking was very difficult. He had developed pyramidal signs in the form of slight weakness of extensor muscles of the foot, exaggerated tendon reflexes in the left leg and arm, and a left extensor plantar response. The CT scan appearance suggested a glioma. He was treated with dexamethasone (4 mg daily) and radiotherapy (20 sessions of 5 Gy each) directed towards the lesion. The left-sided weakness resolved, but twelve months later the hemidystonia worsened and the left hemiplegia recurred. Intrathecal methotrexate was commenced but four days later he died of a massive gastric haemorrhage. Necropsy was performed four hours after death. The brain weighed 1530 g and looked normal in external appearance. After formalin fixation, serial coronal slices revealed slight hydrocephalus and a tumour predominantly in the inferolateral segments of the left putamen and adjacent external segment of the globus pallidus. Histology showed the features of a grade II astrocytoma, with moderate hypercellularity and only a few undifferentiated cells. The tumour was confined histologically within the basal ganglia to the putamen and external segment of the globus pallidus, with slight extension inferiorly into the hypothalamus and anterior commissure (fig. 2).

Anteriovenous Malformation of the Head of the Caudate Nucleus Causing Torticollis

Case 3. A 38-year-old man, without previous history of neurological or systemic disease, was admitted in March 1980 for investigation and treatment of torticollis. He had been the product of a normal pregnancy and delivery, and psychomotor development was normal. There was no history of drug intake. The torticollis started gradually with jerky movements six months before admission, increasing progressively to produce permanent rotation of the head to the left. Neurological and general physical examination was normal, except for the presence of spasmodic torticollis with the chin directed to the left. In addition to the abnormal posture, there were spasms jerking the chin to the left. There also was slight rotation of the trunk to the right (fig. 3A, B). A CT scan showed a partially calcified mass in the head of the right caudate nucleus, which enhanced after contrast injection (fig. 3C). The right lateral ventricle also was slightly dilated. A right carotid angiogram did not reveal any abnormality of the arterial circulation, but the caudate and septal veins were abnormally increased in size. Surgical resection was attempted. The pathological report of the excised specimen was consistent with a partially calcified angioma, probably a venous angioma (fig. 3E). Following the operation the

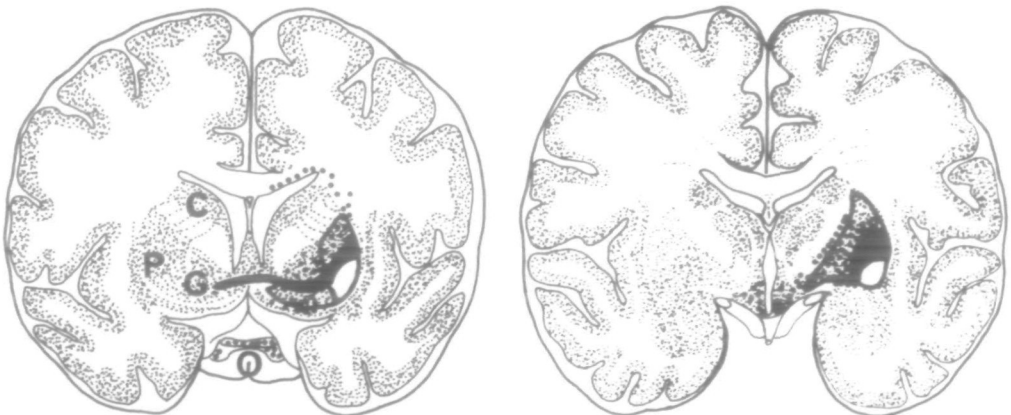


FIG. 2. *Case 2.* Reconstruction of distribution of tumour at the level of the anterior commissure based on pathological examination of serial brain slices. The white area in the inferolateral portion of the putamen (P) was the zone of cystic necrosis. The solid black area indicates solid tumour, extending into the anterior commissure. The black dots indicate perivascular infiltration into the globus pallidus (G), optic chiasma (O) and white matter around the lateral margin of the caudate nucleus (C) and corpus callosum.

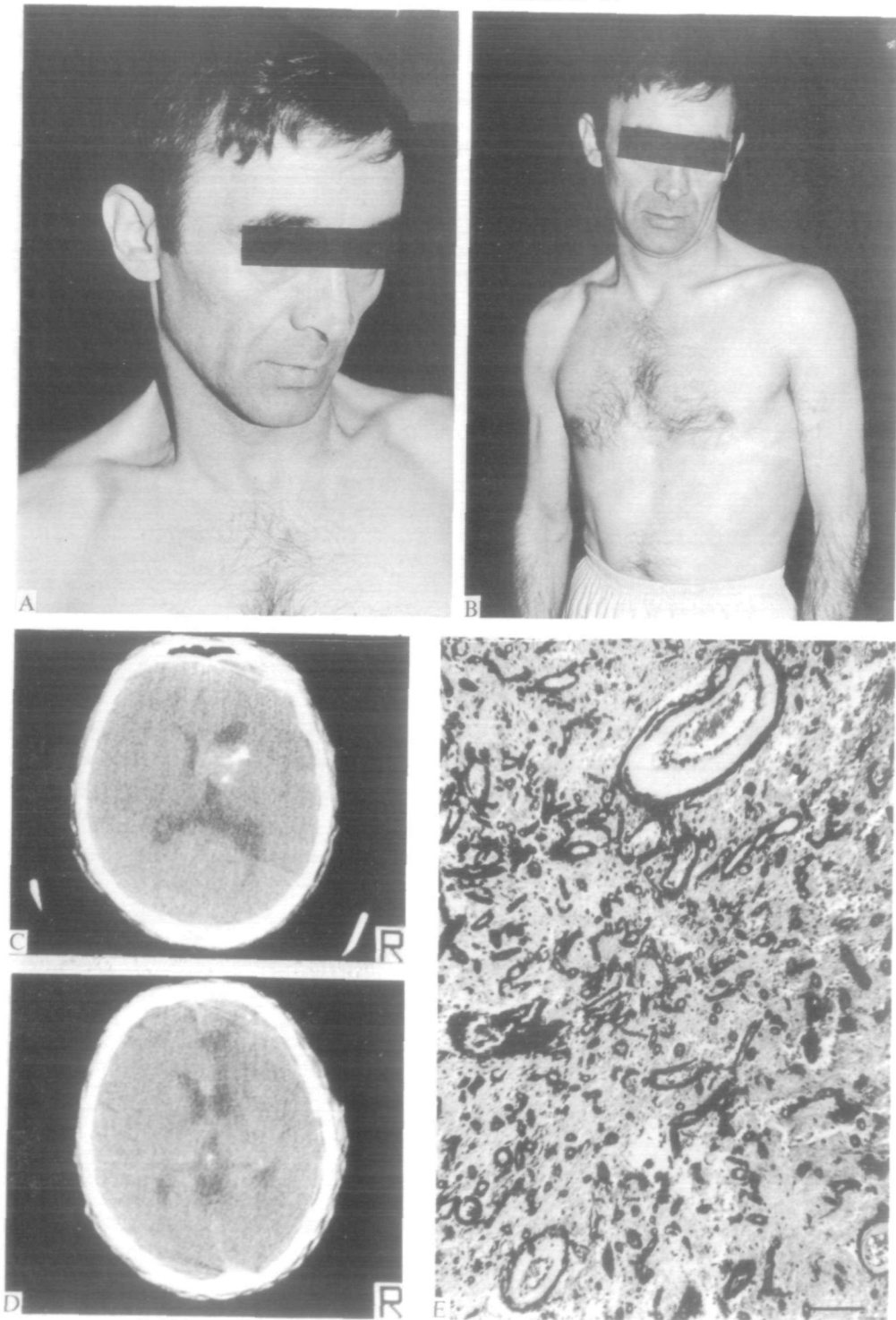


FIG. 3. *Case 3.* A and B show the patient's torticollis. C and D show CT scans before (C) and after surgery (D). E shows histology of the partially calcified angiomatous lesion removed at operation. Haematoxylin and eosin. Horizontal bar = 250 μ m.

patient had an anomic aphasia, was apathetic and disorientated. The torticollis disappeared for two or three weeks, but returned thereafter. A repeat CT scan showed a small part of the malformation remaining attached to the anterior part of the septum pellucidum and a low density area in the right frontal lobe (fig. 3D). Four months later the patient was admitted in coma with severe neck stiffness. Lumbar puncture revealed fresh blood. He died within a few hours from an intraventricular haemorrhage. Necropsy was not allowed.

Focal Lesion of the Right Lentiform Nucleus of Posttraumatic Origin Causing Left Hemidystonia

Case 8. This boy was quite healthy until the age of 6 years when he sustained a mild head injury while playing football in 1972. Pregnancy, delivery and early development had been normal. His parents were healthy and two sibs were normal. The head injury itself was not severe, consisting only of a clash of heads, but he fell to the ground, conscious but with a weak left arm and leg. There was no headache or speech disturbance. The left leg recovered over the next month, leaving him with a mild hemiplegic gait, but the left arm did not regain much use and remained paretic. Skull x-rays, EEG, static and functional isotope brain scans and a right carotid arteriogram were all normal. He remained well until about 1977, when he gradually began to develop writhing dystonic movement of the left arm and leg. These abnormal movements gradually became worse. In 1977 he began to experience rare left-sided focal sensorimotor seizures lasting a few seconds, sometimes followed by weakness of the left limbs for 1–2 h.

On examination in 1980, at the age of 14 years, he was an intelligent lad with a very mild left hemiparesis affecting face, arm and leg, with increased tendon reflexes in the left limbs, and an extensor left plantar response. There was no sensory abnormality. The left hand was held flexed at the wrist and extended at the fingers and exhibited continuous dystonic spasms of pronation and excessive flexion of the wrist. The left arm hyperpronated when outstretched and dystonic spasms were intensified by any attempted use of the arm. The left foot also exhibited spasms of plantar flexion and inversion,

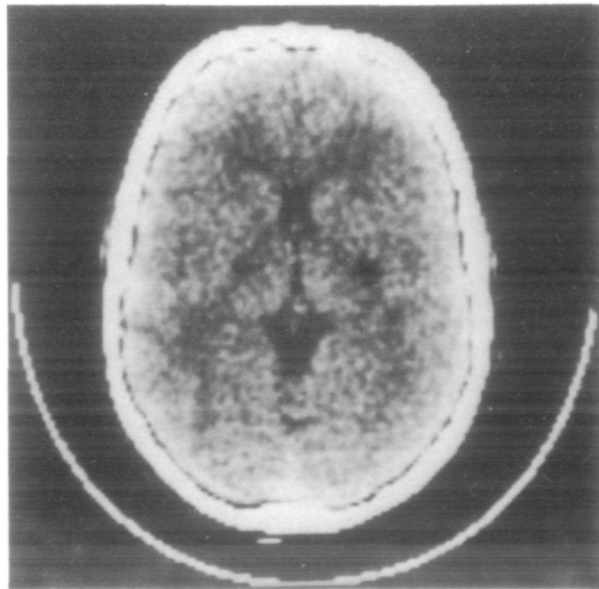


FIG. 4. *Case 8.* CT scan without contrast showing low density lesion in right lentiform nucleus. Clinical examination also indicated involvement of the internal capsule.

especially when walking. Investigation in 1980 revealed normal skull x-rays, serum copper and caeruloplasmin, liver function and plasma proteins and electrolytes, normal CSF cell count, protein and syphilitic serology. An EEG showed an asymmetry of the alpha rhythm and an excess of slow wave activity over the left hemisphere, but no evidence of spikes or sharp waves. A CT scan revealed an area of low attenuation adjacent to the right internal capsule in the lentiform nucleus (fig. 4).

Focal Thalamic Infarction Causing Hand Dystonia

Case 10. A 67-year-old lady with a past history of hypertension (180/120) suffered a stroke in January 1976. Her right upper limb was paralysed and there was a complete right hemisensory loss. Visual fields, speech, mentation and eye movements were normal. An isotopic brain scan indicated an abnormal area of uptake in the left thalamus. She recovered full motor power, but two-point sensory discrimination remained abnormal. In addition, spontaneous pain in the right limbs developed, which was intensified by tactile stimulation. In 1978, the pain and sensory loss had subsided considerably. She then started to develop an abnormal posture of the right hand. Examination at that time revealed a dystonic posture of the right hand (fig. 5A, B) with flexion of the metacarpophalangeal joints and separation and extension of the fingers. This dystonic posture was exacerbated by voluntary movement

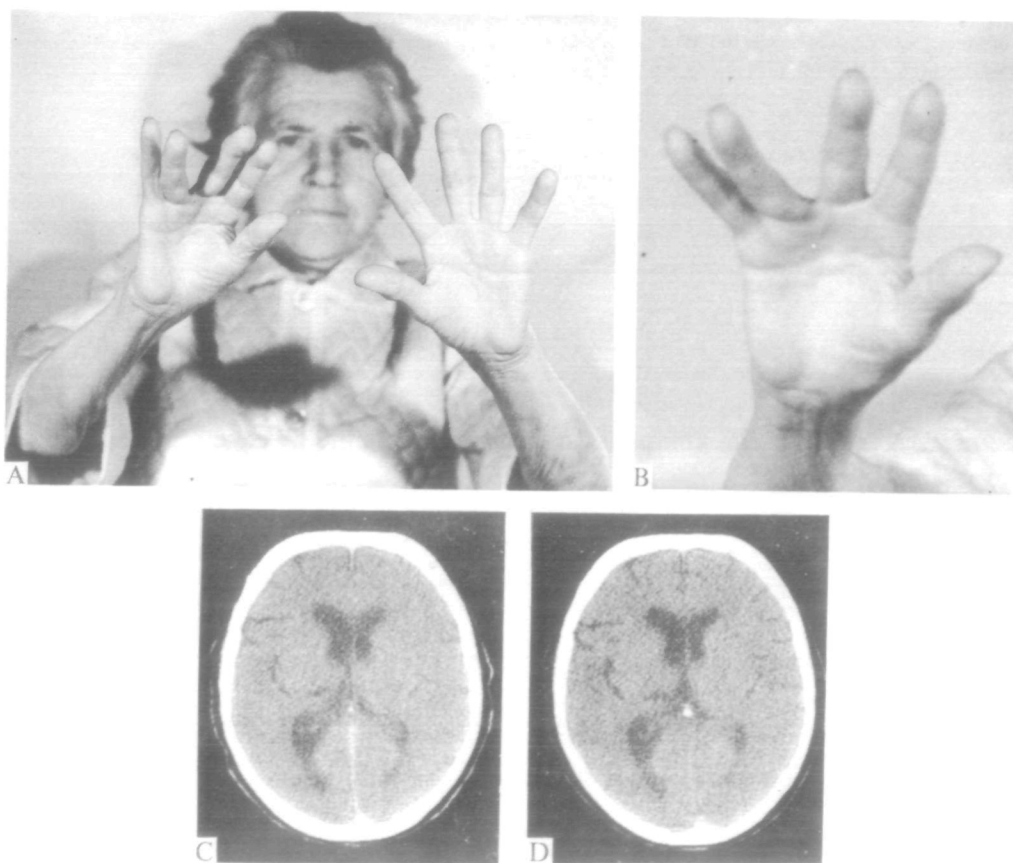


FIG. 5. *Case 10.* A and B show dystonic posture of right hand. C and D are CT scans, C without and D with contrast, showing low density lesion in left posterolateral thalamus.

of the right hand. Motor power in the right limbs was normal, as were the tendon reflexes; the plantar responses were flexor. Position sense and vibration sense were normal, but pain and temperature threshold was increased in the right arm. Coordination of the right limbs was normal. A CT brain scan showed a small low density lesion affecting the left posterolateral thalamus (fig. 5c, d).

Case 11. This patient has been described in detail previously by Obeso *et al.* (1984). A brief summary is included here. A 22-year-old pregnant woman developed a left hemiplegia in November 1981 during an episode of migraine lateralized to the right side of her head. The initial neurological examination revealed complete left hemiplegia and sensory loss. Visual fields were normal. Detailed cardiovascular examinations, including ECG and echocardiography were normal. A CT brain scan showed a large area of low density affecting the right posterolateral thalamus, internal capsule and lentiform nucleus within a week of the episode. The patient recovered motor power almost completely, and only a minimal hypoaesthesia of the finger tips could be detected on sensory examination. A few weeks later she developed spontaneous pain and a feeling of burning in the left arm. The pain was also provoked by tactile stimulation of the affected limb. Over the following two months mobility returned to normal and the abnormal sensation disappeared. However, she developed progressive difficulty in controlling the left arm and a tendency of the left foot to twist inwards on walking. Ten months after the acute

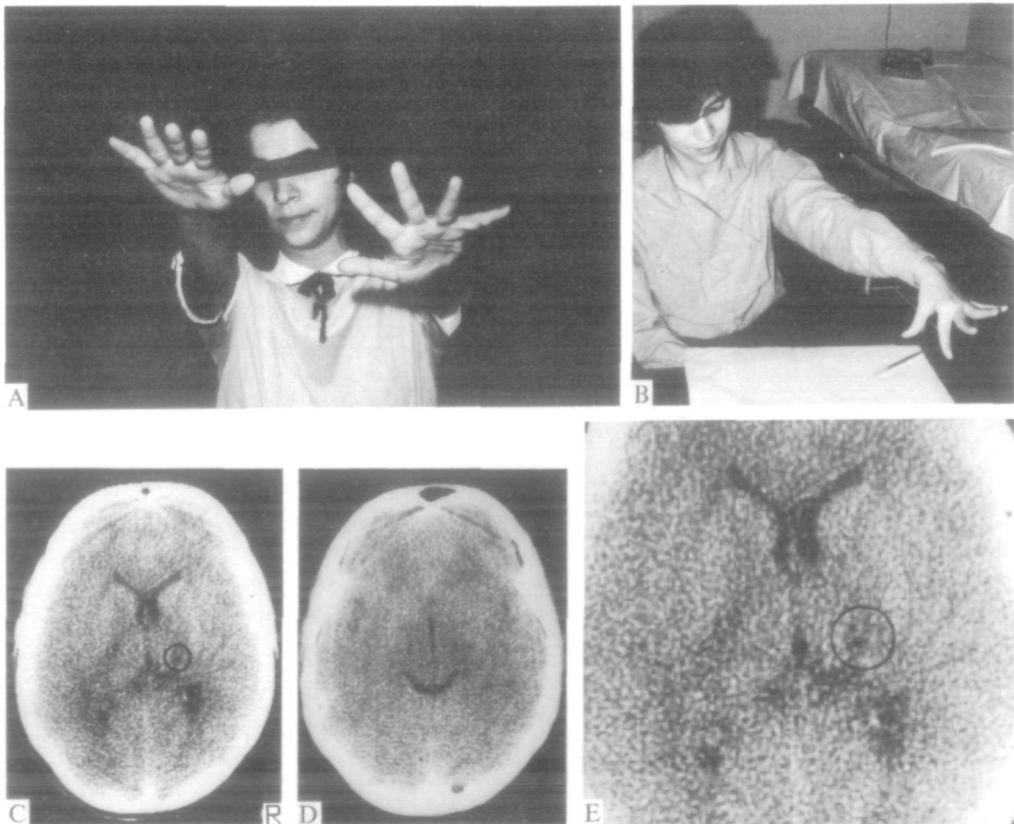


FIG. 6. *Case 11.* A and B show dystonic left hand and arm. C, D and E are CT scans without contrast showing a low-density lesion in right posterolateral thalamus (ringed).

episode, examination showed left arm dystonia on action of distal distribution (fig. 6A, B), and a coarse postural and kinetic tremor, of proximal distribution. A further CT brain scan showed a small area of low density in the right posterolateral thalamic nuclei (fig. 6C-E).

Large Lesions

Right Frontal Lobe Glioma Invading the Basal Ganglia Causing Left Foot Dystonia

Case 14. A 32-year-old nurse presented with her first major seizure in 1971. Occasional grand mal seizures, without focal onset or aftermath, continued until the age of 35 years, when she began to develop a progressive left hemiplegia, beginning in the leg. A CT brain scan at that time revealed a large area of low attenuation in the right frontotemporal region extending down to the midline, with compression of the anterior horn and body of the right lateral ventricle. There was no enhancement with contrast. Management was complicated by travel, but eventually she was admitted for surgical exploration in 1977, at the age of 36 years.

On examination then, she walked with a bizarre dystonic posture of the left leg and arm, and had a moderate left hemiparesis. The remainder of the neurological examination was normal.

A right frontal lobectomy was performed. Histology revealed a grade I astrocytoma. Thereafter she gradually improved, so that by 1979 her walking had returned to normal and she returned to work as a nurse. No further grand mal seizures occurred while on carbamazepine and phenobarbitone, although she did have occasional absence attacks. In 1981, however, the dystonic gait rapidly recurred over a matter of three weeks.

Re-examination then revealed an abnormality of gait similar to that seen previously. When attempting to walk forwards, the left knee would bend and the whole body would tilt to the left and sag towards the floor. She could run forwards without difficulty and could walk backwards normally. Also, she could hop on the affected leg without difficulty. Examination of the left leg on the bed revealed no change in tone and no weakness; the tendon jerks in the legs were normal and the plantar responses were flexor. There was no sensory loss in the legs. However, there was a mild left faciobrachial weakness of cortical distribution affecting both flexors and extensors and most marked proximally. The tendon jerks in the arms were normal and there was no sensory loss. The cranial nerves were normal.

A repeat CT scan showed recurrence of the tumour, with a large low density lesion occupying the right frontal and temporal regions, and extending posteriorly and across the midline to involve the caudate nucleus, compressing and displacing the right frontal horn of the lateral ventricle. The lesion showed patchy enhancement with contrast.

Left Hemidystonia Secondary to Right Lenticulocapsulocaudate Infarction

Case 22. This 60-year-old woman suffered a stroke in 1972 resulting in a complete left hemiplegia, without disturbance of speech or vision. The weakness improved over the next few months and she could walk and use her left hand almost normally. In 1975, the left upper limb began to tighten with the fingers flexing into the palm, the arm abducted to the side and the elbow flexing. This abnormal posture increased over the next five years. Forearm pains produced by the muscle spasms were an additional complication.

On examination in 1984, the left arm was held flexed at the elbow and abducted at the shoulder. Most of the time the fingers were flexed into the palm, but she was able to extend the first two fingers voluntarily. The other fingers could also be extended for a short period of time, but adopted a dystonic flexor posture as soon as any voluntary movement of the left upper limb was attempted. The left leg also went into forceful extension at the knee with ankle inversion upon action. In addition, the leg extended involuntarily when she was sitting or when she tried to execute any other motor task. There was mild pyramidal weakness in the left arm, but power in the legs was normal. The tendon jerks were difficult to elicit in the left arm because of the marked dystonic posture, but those in the leg were normal and symmetrical. The plantar responses were flexor. Sensation, speech, vision, the cranial nerves and

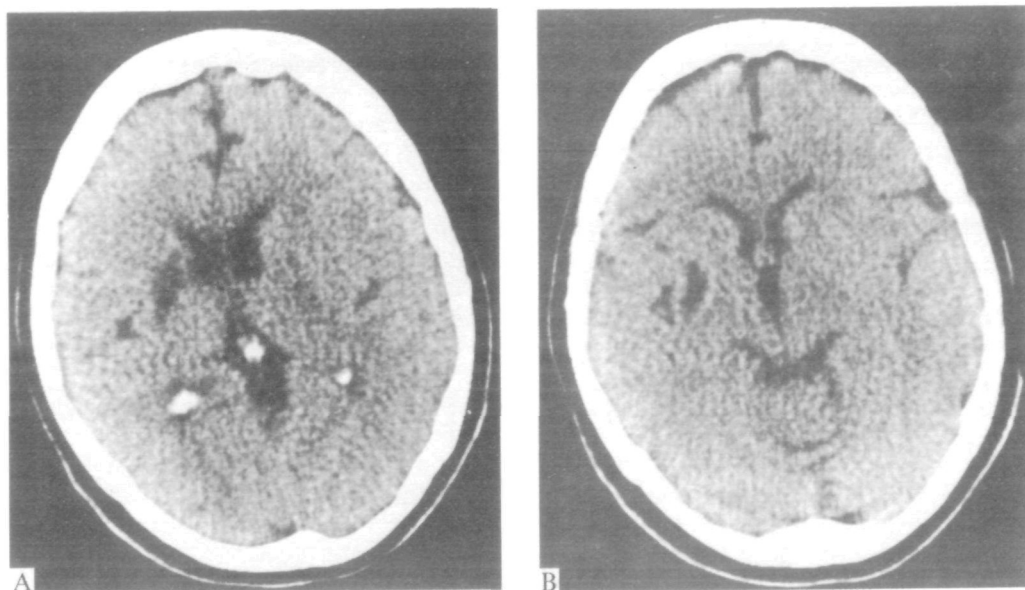


FIG. 7. *Case 22.* A and B are CT scans without contrast showing low density lesion in right (note different presentations of sides from previous scans) caudate nucleus and lentiform nucleus. Clinical examination also indicated involvement of the internal capsule.

intellect were normal. A CT brain scan showed a large infarct involving the right putamen (anterior third) and caudate nucleus (fig. 7A, B).

Left Hand Dystonia and Arm Action Tremor Secondary to Right Parietothalamic Infarction

Case 23. A 62-year-old man admitted in June 1983 in acute cardiac failure secondary to left ventricular infarction with partial rupture of the ventricular wall. An emergency cardiac repair was carried out, the patient recovering normal haemodynamic function over the next few days. Two weeks after admission he started to complain of clumsiness of the left hand, particularly when undertaking fine manipulative motor tasks. This progressed to frank incoordination of the left arm. Examination showed coarse postural and kinetic tremor of the left upper limb affecting mainly proximal muscles. There was an abnormal flexed posture of the third to fifth fingers with slight ulnar deviation of the wrist (fig. 8A). There was a minimal paresis of the small hand muscles and of the long finger extensors of the affected limb, but no sensory loss. Visual fields, speech, the tendon reflexes and plantar responses were normal. Three days later the tremor suddenly stopped. Examination then showed profound sensory loss for all modalities in the left upper limb and severe hypoaesthesia in the left side of the face and left leg. The dystonic hand remained unchanged. A CT brain scan showed a large parietal infarct extending deeply into the thalamocortical projections and probably also affecting the posterior thalamic nuclei (fig. 8B-E). Over the following weeks the dystonia disappeared completely and the sensory loss improved, but severe spontaneous pain of the left upper limb supervened. He was treated with carbamazepine (1200 mg/day) with partial improvement.

Right Hemiatrophy and Frontocaudate Infarction Causing Left Hemidystonia

Case 24. A 3-year-old Indian girl developed tuberculous meningitis, which was treated briefly for four months with antituberculous drugs. At the age of 6 years she again developed tuberculous

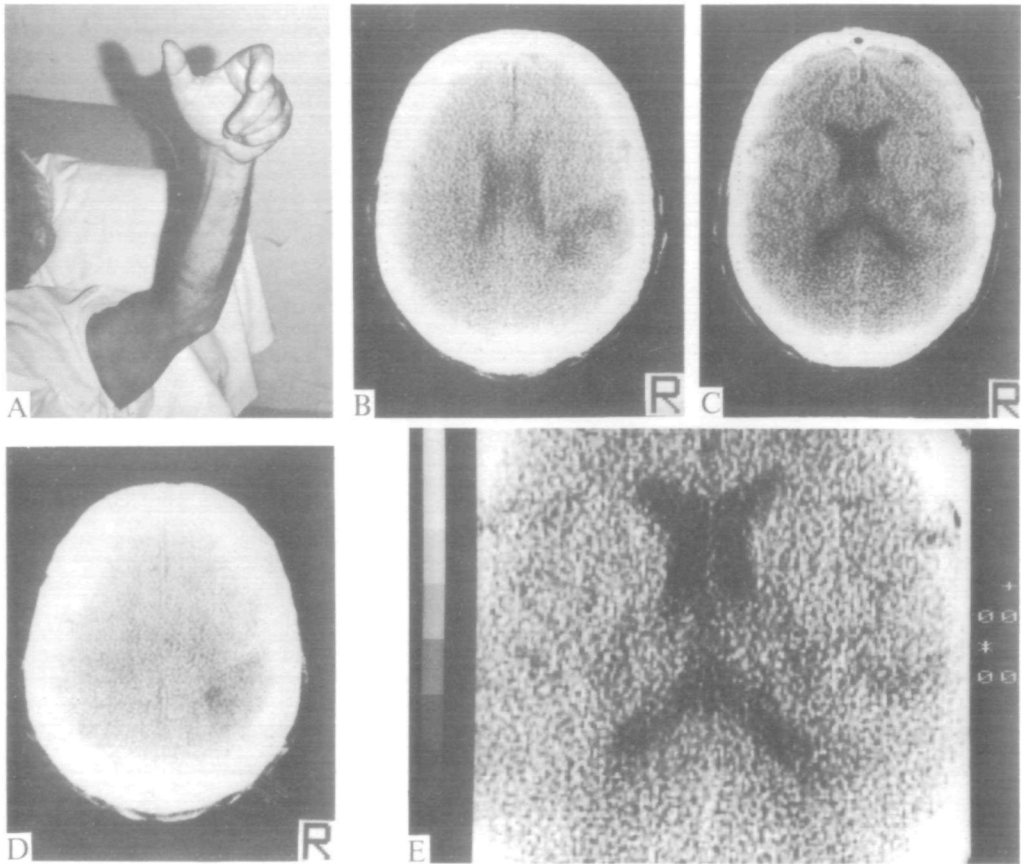


FIG. 8. Case 23. A shows dystonic left hand. B, C, D and E are CT scans without contrast showing large low density lesion in right parietothalamic region.

meningitis during which she suddenly developed a left hemiparesis. A right carotid arteriogram showed evidence of an arteritis. Again she was treated briefly with antituberculous drugs, but suffered a relapse of her meningitis. She developed bilateral papilloedema, stupor, and continuous dystonic movements of the left arm, with intermittent similar movements of the left leg. Investigation then revealed the CSF to be under increased pressure, and to contain 370 white cells (52% polymorphs and 48% mononuclear cells), protein 1.25 g/l, sugar 2.9 mmol/l (blood sugar 7.8 mmol/l); acid fast bacilli were seen with fluorescent staining. She was treated with streptomycin, isoniazid, rifampicin and dexamethasone, as well as ventricular drainage for hydrocephalus. Eventually she recovered, but was left with a left hemiparesis with dystonic movements.

On review at the age of 12 years, she was alert and intelligent, but disabled by dystonic posturing of the left limbs. The left arm, which was more affected than the leg, tended to abduct, spontaneously and suddenly, sufficiently strongly to strike those nearby. On attempting to hold the left arm outstretched, it adopted a typical dystonic posture with hyperpronation, and flexion of wrist with extended fingers. On walking, the left leg extended with plantar flexion and inversion of the foot. Power was normal, but the tendon reflexes on the left were brisk and the left plantar response was extensor; there was no

sensory deficit. A CT brain scan at that time showed hemiatrophy of the right side of the cerebrum, with enlargement of the ventricles, particularly of the right frontal horn. There was an area of low attenuation deep in the right frontal lobe adjacent to the anterior horn, and the basal structures of the floor of the right ventricle were grossly atrophied.

Left Hemiatrophy Secondary to Anoxia at Birth. Right Hemidystonia

Case 25. A right hemiparesis was first found when this lad was aged 6 months, at which time he preferentially used the left hand. Pregnancy, delivery, and early development until then were normal. His unrelated parents were in good health, and there was no family history of any movement disorder. By the age of 4 years it was evident that the right arm was spastic with the wrist pronated and the fingers extended. In addition, there was mild spasticity of the right leg, and the plantar responses were extensor bilaterally. Schooling proved difficult and an IQ estimation at the age of 8 years gave a verbal score of 80 and a performance score of 90. From the age of about 4 years onwards it was noticed that the right arm would adopt a bizarre dystonic posture on any attempted action.

On examination at the age of 11 years the striking abnormality was the dystonia of the right arm. At the slightest attempt to move the arm, it would abduct at the shoulder, flex at the elbow, pronate at the forearm, flex at the wrist and extend at the fingers. The arm was useless and he had to employ the left hand for everything. The cranial nerves were normal, but the right foot was slightly plantar-flexed and inverted. The tendon reflexes were brisk on the right, and the right plantar response was extensor. A CT scan undertaken at the age of 11 years revealed a well-circumscribed atrophic area containing CSF which appeared to connect inferiorly with the junction of the insula and the sylvian fissure; it extended upwards to replace the temporal operculum and stretched down to the level of the left frontal horn. The left hemisphere as a whole was slightly smaller than the right, the left ventricular system was enlarged, and there was some atrophy of the cortical gyri on the left. The picture was of left hemiatrophy, with a discrete focal area of brain loss.

DISCUSSION

Focal brain lesions occasionally produce typical focal or hemidystonia. The lesions described here were tumours, arteriovenous malformations, infarcts (post-traumatic, thrombotic or embolic), or haemorrhages. Such lesions involved a variety of cerebral regions including the thalamus, caudate nucleus, lentiform nucleus (putamen and globus pallidus), internal capsule and cortex. Sometimes generalized hemiatrophy, also involving these structures, was found.

All these patients had typical features of torsion dystonia when examined. Thus 24 of the 28 patients exhibited spontaneous dystonic movements or postures at rest, 26 had dystonic movements or postures on action, and 23 had mobile dystonic spasms either at rest and/or on action. Some of these patients had slow writhing movements, others had more myoclonic jerks as described in myoclonic dystonia (Obeso *et al.*, 1983).

Focal or hemidystonia was the only neurological abnormality in many of these patients. However, 15 of the 28 cases had a history of a previous hemiparesis or hemiplegia due to cerebral infarction. These patients therefore had posthemiplegic dystonia. In 13 of these 15 patients the dystonia appeared after a delay of between two months to four years, often as the hemiparesis resolved. Hammond (1871) is credited with the first description of posthemiplegic 'athetosis' and Gowers (1886)

clearly recognized the sequence of events occurring in those who developed delayed onset posthemiplegic dystonia. Indeed, Gowers (1886) also drew attention to the variety of abnormal movements and postures that might follow a stroke, varying from quick clonic spasms, to slow mobile spasms and tonic immobile spasms. All these are included in what now is termed dystonia; they are identical to the movements and postures seen in patients with idiopathic (primary) torsion dystonia, whether inherited or sporadic. Why there should be a delay in the appearance of dystonia following a stroke is not certain. The hemiplegia itself may prevent the appearance of dystonia, but this cannot be the only explanation. Some patients in this series (e.g. Case 8) had only the mildest hemiparesis yet dystonia did not appear for two years after a head injury associated with a lenticular infarct. In Case 7, a similar posttraumatic infarct in the lentiform nucleus was accompanied by virtually no pyramidal deficit, yet dystonia appeared a week later and became progressively worse over the next two years (Brett *et al.*, 1981). Delayed-onset dystonia is recognized after perinatal cerebral anoxia (Burke *et al.*, 1980), and was seen in Cases 25 and 26 in the present series, both of whom had hemiatrophy on CT scan, as did Case 1 of Burke *et al.* (1980). Perhaps delayed onset dystonia is the result of slowly evolving aberrant neuronal sprouting, stimulated by the original lesion, as suggested by Burke *et al.* (1980).

We felt it justifiable to include patients with posthemiplegic dystonia in the series because their dystonia was identical to that seen in other cases of symptomatic hemidystonia, and because they had lesions similar to those seen in patients with hemidystonia without a prior hemiplegia (with the exception of involvement of the internal capsule).

The purpose of this paper is to analyse those anatomical sites most frequently involved in patients with symptomatic focal or hemidystonia. Localization was most often obtained by CT scan, which may have underestimated the extent of cerebral damage, particularly in vascular lesions. However, the CT scan has provided a means of identifying lesions during life in those with focal or hemidystonia, and is likely to have revealed the regions of greatest cerebral damage. Table 4 analyses the sites of lesions identified in the 28 patients described here. Those patients with single isolated lesions are shown separate from those in whom the lesions involved more than one structure. It is difficult to distinguish lesions of the

TABLE 4. SUMMARY OF DISTRIBUTION OF LESIONS RESPONSIBLE FOR DYSTONIA IN THE PRESENT STUDY

Site of dystonia	Thalamus		Caudate nucleus		Lentiform nucleus		Internal capsule		Cortex		Hemiatrophy	
	Single	Combined	Single	Combined	Single	Combined	Single	Combined	Single	Combined	Single	Combined
Hemidystonia	1	1	1	6	3	6	—	5	—	2	4	1
Arm dystonia	—	2	—	2	—	2	—	—	—	—	—	—
Hand dystonia	3	2	—	—	—	1	—	1	—	1	—	—
Foot dystonia	—	—	—	2	—	2	—	2	—	1	—	—
Torticollis	—	—	2	—	—	—	—	—	—	—	—	—
Total	4	5	3	10	3	11	0	8	0	4	4	1
	9		13		14		8		4		5	

putamen from those of the globus pallidus in CT scans, so these are combined as the lentiform nucleus. However, the lenticular lesions were often placed laterally and were most likely to involve the putamen more than the globus pallidus. Certainly this was the situation in Cases 2, 7, 8 and 22. In the other 10 patients with lenticular lesions, the globus pallidus as well as the putamen was likely to be involved. However, none of these lenticular lesions appeared to involve the globus pallidus alone.

It is also notable that symptomatic hemidystonia or generalized dystonia has not been identified with isolated cortical or brainstem lesions. Torticollis can be produced by experimental brainstem lesions in animals (Foltz *et al.*, 1959) and is very rarely encountered in patients with syringomyelia or spinal cord tumour (Kiwak *et al.*, 1983). There also is a single report of torticollis which disappeared after surgical resection of a frontal cortical scar (David *et al.*, 1952) and another with torticollis associated with a colloid cyst of the third ventricle (Avman and Arasil, 1969). Blepharospasm also can be produced by lesions of the upper brainstem (Jankovic and Patel, 1983). However, patients with torticollis or blepharospasm due to identified brainstem lesions have not been reported to develop more widespread dystonia.

To extend the number of cases, Tables 5 and 6 summarize other patients with focal or hemidystonia described in the literature, either with CT scan localization (13 patients) (Table 5) or pathological verification (7 patients) (Table 6). The cases

TABLE 5. SYMPTOMATIC DYSTONIA WITH CT SCAN LESIONS IN THE LITERATURE

<i>Author</i>	<i>Site of dystonia</i>	<i>Aetiology and pathology</i>	<i>Topography</i>
1 Messimy <i>et al.</i> (1977)	L arm dystonia	Traumatic haemorrhage	Head of R caudate nucleus
2 Maki <i>et al.</i> (1980)	Transitory L torticollis (4 days)	Trauma	Infarction of R caudate and putamen
3 Mauro <i>et al.</i> (1980)	1 R hemidystonia	Traumatic infarction	Atrophy L caudate nucleus (head)
	2 L hemidystonia	Traumatic infarction	R putamen
4 Grimes <i>et al.</i> (1982)	1 L arm dystonia	Infarction	R caudate nucleus and putamen
	2 L arm dystonia	Infarction	R caudate nucleus and putamen
5 Demierre and Rondot (1983)	3 L hemidystonia	Infarction	R lenticulocapsulocaudate
	1 R hemidystonia	Trauma Angioma? Infarction	L lenticulocapsulocaudate infarction
	2 L hemidystonia	Infarction	R lenticulocapsulocaudate
	3 L hemidystonia	Embolic infarction	R lenticulocapsulocaudate
6 Russo (1983)	L arm dystonia	Infarction	R lentiform nucleus
7 Traub and Ridley (1982)	L hand dystonia	Infarction	R lentiform nucleus
8 Burton <i>et al.</i> (1984)	L hemidystonia	Thromboembolic infarction	R lenticulocapsulocaudate nucleus

TABLE 6. DISCRETE FOCAL LESIONS CAUSING DYSTONIA STUDIED PATHOLOGICALLY IN THE LITERATURE

Author	Site of dystonia	Aetiology	Topography			
			Thalamus	Internal capsule	Striatum	Globus pallidus
1 Bouttier <i>et al.</i> (1922)	L forearm and hand. Fixed dystonia	Fibroma	R postero-lateral	No	No	No
2 Urechia <i>et al.</i> (1942-1943)	R hemidystonia	Glioblastoma	No	No	L lentiform and caudate nuclei	
3 Barraquer-Bordas and van Bogaert (1954)	L hand. Mobile dystonia	Tuberculoma	R ventro-lateral	Yes	No	Internal segment
4 Garcin (1955)	L hand dystonia	Infarction	R postero-lateral	No	No	No
5 López Aydillo and Sanz Ibáñez (1956)	L forearm and hand Mobile dystonia	Infarction	No	No	R putamen and head caudate nucleus	No
6 Denny-Brown (1962)	R hemidystonia. Mobile	Infarction	Left	No	L $\frac{2}{3}$ putamen, $\frac{1}{3}$ caudate nucleus	No
7 Oppenheimer (1967)	L fixed hemidystonia	Infarction	No	No	R putamen and body of caudate nucleus	No

shown in Table 6 all had discrete focal lesions. The 5 patients described in the important paper of Dooling and Adams (1975), which will be considered in detail below, are not included for all had widespread cortical infarcts and other pathological changes. It should be noted that when the lentiform nucleus was affected, as judged either by CT scan (Table 5) or pathological examination (Table 6), the putamen was specifically mentioned in 7 of 14 cases. No example of a lesion of the globus pallidus sparing the putamen was recorded in the literature. The data from the present paper and from the literature for a total of 48 patients are combined for analysis in Table 7.

Patients with cerebral hemiatrophy are not informative, for it is impossible to attribute their dystonia to specific anatomical structures. Attention is focused on the remaining patients with discrete lesions. No cases of symptomatic dystonia due to an isolated lesion of the brainstem, internal capsule or cerebral cortex have been found, although the latter structures often are involved in large lesions (the internal capsule on 13 occasions and the cerebral cortex on 4 occasions in the combined material). Small isolated lesions of the thalamus (6 patients), caudate nucleus

TABLE 7. SUMMARY OF DISTRIBUTION OF LESIONS RESPONSIBLE FOR DYSTONIA IN 13 PATIENTS WITH CT SCAN LOCALIZATION AND 7 PATIENTS WITH PATHOLOGY, COMBINED WITH 28 PATIENTS FROM THE PRESENT STUDY

Site of dystonia	Thalamus		Caudate nucleus		Lentiform nucleus		Internal capsule		Cortex	
	Single	Combined	Single	Combined	Single	Combined	Single	Combined	Single	Combined
Hemidystonia	—	1	1	7	1	8	—	5	—	—
Arm dystonia	1	—	1	3	1	3	—	—	—	—
Hand dystonia	1	1	—	—	1	1	—	—	—	—
Foot dystonia	—	—	—	—	—	—	—	—	—	—
Torticollis	—	—	—	1	—	1	—	—	—	—
Total	2	2	2	11	3	13	0	5	0	0
		4		13		16		5		0
Data in Table 7 combined with Table 4	6	7	5	21	6	24	0	13	0	4
		13		26		30		13		4

(5 patients) or lentiform nucleus (6 patients) were found to produce dystonia. Larger lesions causing dystonia involved the thalamus on 7 occasions, the caudate nucleus on 21 occasions, and the lentiform nucleus on 24 occasions. Combining small and large lesions causing dystonia reveals that the thalamus was involved on 13 occasions, the caudate nucleus on 26 occasions and the lentiform nucleus on 30 occasions. The frequency of involvement of these structures in the present study was very similar to that reported in the literature. We conclude that symptomatic dystonia may be produced by lesions in the thalamus, or the caudate or lentiform nuclei (particularly the putamen), or in a combination of these structures.

This conclusion confirms the earlier proposition of Dooling and Adams (1975), based upon pathological study of 4 patients with severe posthemiplegic dystonia. 'The principle lesion lay in the striatum in each of the 4 cases. The dorsolateral part of the caudate nucleus and the dorsolateral or lateral parts of the putamen had been destroyed. . . . The lesion was much more extensive in the putamen than in the caudate. The globus pallidus was largely intact.' In addition, there was loss of striopallidal and pallidothalamic fibres, and retrograde cell degeneration in the thalamus (nuclei ventralis lateralis, ventralis anterior and centrum medianum). Grimes *et al.* (1982) also commented on thalamic atrophy in CT scans of their 3 patients with posthemiplegic dystonia. Dooling and Adams (1975) compared their findings with those in 9 cases of adult-onset hemiplegia without dystonia, noting the additional extensive involvement of the internal capsule and subcortical white matter in the latter cases. They concluded that 'the essential anatomical lesion in our cases of hemiathetosis was an extensive involvement of the striatum, secondary involvement of striatopallidal fibres and to some extent of the ventral and lateral thalamic nuclei, and a relative preservation of the descending cortical motor pathways'. To this we would add from our data that isolated thalamic lesions also may cause hemidystonia, particularly involving the hand, as had been remarked by Bouttier *et al.*, (1922), Garcin (1955) and perhaps by Barraquer-Bordas and van Bogaert (1954).

There is some suggestion that lesions in each of these three structures may cause a different distribution of dystonia. Each of the 3 patients with torticollis (Maki *et al.*, 1980; Cases 3 and 4, present series) had lesions in the caudate nucleus, usually in its head. In the 16 patients with symptomatic dystonia of the hand and arm, the thalamus was involved in 9, alone in 5 (Bouttier *et al.*, 1922; Garcin, 1955; Cases 10, 11 and 12, present series) and combined with the caudate and/or lenticular lesions in the others. However, symptomatic arm dystonia also was caused by an isolated lesion in the caudate nucleus (Messimy *et al.*, 1977), by an isolated lesion in the lentiform nucleus (Traub and Ridley, 1982; Russo, 1983), or by lesions in both the caudate and lentiform nuclei (López Aydillo and Sanz Ibáñez, 1956). Symptomatic focal foot dystonia was uncommon; the caudate nucleus was involved in 1 patient (Case 14), the lentiform nucleus in another (Case 9) and both in a third (Case 20).

Most patients exhibited symptomatic hemidystonia involving both the arm and leg (26 of the 48 patients). Such hemidystonia was caused by isolated lesions of the

thalamus (Case 13), the caudate nucleus (Case 1 of Mauro *et al.*, 1980; Case 6), the putamen or lentiform nucleus (Case 2 of Mauro *et al.*, 1980; Burton *et al.*, 1984; Cases 2, 5, 7, 8) or by larger lesions involving these three structures, or by generalized hemiatrophy. It is difficult on the basis of these observations to draw any firm conclusions on topographical localization of dystonia with lesions in different sites. The type of dystonia produced by lesions of thalamus, caudate nucleus or lentiform nucleus was very similar. Lesions at any of these three sites could produce spontaneous dystonia, dystonia on action, fixed dystonic postures, or a combination of all types of dystonia.

Mention must be made of symptoms and signs that were not present in these patients. Despite extensive unilateral striatal and thalamic lesions, none of the patients exhibited dysphasia (9 of our 28 cases and 4 of the 20 cases in the literature had lesions in the left hemisphere). None had evidence of obvious incapacitating cognitive change or of postural instability. None had hemichorea or hemiballism, although both are recognized complications of unilateral basal ganglia lesions.

How could lesions of thalamus, caudate nucleus or lentiform nucleus produce dystonia? These three structures are intimately related. The caudate nucleus and putamen project topographically to the globus pallidus, which itself projects to the thalamus. The resolution of CT scanning, or of pathological findings, makes it difficult to identify specific areas of these structures damaged in symptomatic hemidystonia, but it is reasonable to assume that the region of the thalamus involved is that to which the globus pallidus projects. Lesions in all three sites that may cause symptomatic focal or hemidystonia have in common their ability to disrupt the thalamic input to frontal cortex, and ultimately to the motor area. Accordingly, it seems likely that dystonia is due to delivery of inappropriate commands to premotor and motor cortex. The major output to frontal cortex from those regions of the thalamus that receive basal ganglia input is to the premotor cortex, including the supplementary motor area. Dystonia therefore may be viewed as a consequence of release of premotor cortical activity from thalamic control. We believe that the data presented here suggest that idiopathic dystonia may be due to some unidentified lesion (perhaps biochemical) in the thalamus, caudate nucleus or lentiform nucleus (particularly the putamen).

ACKNOWLEDGEMENTS

We are grateful to the many physicians who have referred patients with dystonia to us for evaluation.

REFERENCES

- AVMAN N, ARASIL E (1969) Spasmodic torticollis due to colloid cyst of the third ventricle. *Acta Neurochirurgica*, **21**, 265-268.
- BARRAQUER-BORDAS L, VAN BOGAERT L (1954) Sur l'évolution tardive de certaines hémipariés cérébrales infantiles. *Monatsschrift für Psychiatrie und Neurologie*, **127**, 31-39.

- BOUQUIER H, BERTRAND I, MARIE A P (1922) Sur un cas anatomo-clinique de syndrome thalamique dissocié. *Revue Neurologique*, **38**, 1492-1502.
- BRETT E M, HOARE R D, SHEEHY M P, MARSDEN C D (1981) Progressive hemi-dystonia due to focal basal ganglia lesion after mild head trauma. *Journal of Neurology, Neurosurgery and Psychiatry*, **44**, 460.
- BURKE R E, FAHN S, GOLD A P (1980) Delayed-onset dystonia in patients with 'static' encephalopathy. *Journal of Neurology, Neurosurgery and Psychiatry*, **43**, 789-797.
- BURTON K, FARRELL K, LI D, CALNE D B (1984) Lesions of the putamen and dystonia: CT and magnetic resonance imaging. *Neurology, Cleveland*, **34**, 962-965.
- DAVID M, HECAEN H, CONSTANS J (1952) Torticolis spasmodique consécutif à une lésion corticale traumatique. Discussion du résultat favorable obtenu après excision de la lésion corticale. *Revue Neurologique*, **86**, 57-61.
- DEMIERRE B, RONDOT P (1983) Dystonia caused by putamino-capsulo-caudate vascular lesions. *Journal of Neurology, Neurosurgery and Psychiatry*, **46**, 404-409.
- DENNY-BROWN D (1962) *The Basal Ganglia and Their Relation to Disorders of Movement*. London: Oxford University Press, pp. 55-56.
- DENNY-BROWN D (1968) Clinical symptomatology of diseases of the basal ganglia. In: *Handbook of Neurology*, Volume 6. Edited by P. J. Vinken and G. W. Bruyn. Amsterdam: North-Holland, pp. 133-172.
- DOOLING E C, ADAMS R D (1975) The pathological anatomy of posthemiplegic athetosis. *Brain*, **98**, 29-48.
- FOERSTER O (1921) Zur Analyse und Pathophysiologie der striären Bewegungsstörungen. *Zeitschrift für die Gesamte Neurologie und Psychiatrie*, **73**, 1-169.
- FOLTZ E L, KNOPP L M, WARD A A (1959) Experimental spasmodic torticollis. *Journal of Neurosurgery*, **16**, 55-72.
- GARCIN R (1955) Syndrome cérébello-thalamique par lésion localisée du thalamus. *Revue Neurologique*, **93**, 143-149.
- GOWERS W R (1886) *A Manual of Diseases of the Nervous System*. London: J. and A. Churchill.
- GRIMES J D, HASSAN M N, QUARRINGTON A M, D'ALTON J (1982) Delayed-onset posthemiplegic dystonia: CT demonstration of basal ganglia pathology. *Neurology, New York*, **32**, 1033-1035.
- HAMMOND W A (1871) *A Treatise on Diseases of the Nervous System*. New York: Appleton.
- HERZ E (1944) Dystonia. II. Clinical classification. *Archives of Neurology and Psychiatry, Chicago*, **51**, 319-355.
- JANKOVIC J, PATEL S C (1983) Blepharospasm associated with brainstem lesions. *Neurology, Cleveland*, **33**, 1237-1240.
- KIWAK K J, DERAY M J, SHIELDS W D (1983) Torticollis in three children with syringomyelia and spinal cord tumor. *Neurology, Cleveland*, **33**, 946-948.
- LÓPEZ AYDILLO N R, SANZ IBÁÑEZ J (1956) A propósito de un caso de distonia de torsión (variante miostática o paralítica) en una diabética glucosúrica. *Trabajos del Instituto Cajal de Investigaciones Biológicas*, **48**, 81-108.
- MAKI Y, AKIMOTO H, ENOMOTO T (1980) Injuries of basal ganglia following head trauma in children. *Child's Brain*, **7**, 113-123.
- MAURO A J, FAHN S, RUSSMAN B (1980) Hemidystonia following 'minor' head trauma. *Transactions of the American Neurological Association*, **105**, 229-231.
- MESSIMY R, DIEBLER C, METZGER J (1977) Dystonie de torsion du membre supérieur gauche probablement consécutive à un traumatisme crânien. *Revue Neurologique*, **133**, 199-206.
- NARBONA J, OBESO J A, TUÑÓN T, MARTINEZ-LAGE J M, MARSDEN C D (1984) Hemi-dystonia secondary to localised basal ganglia tumour. *Journal of Neurology, Neurosurgery and Psychiatry*, **47**, 704-709.
- OBESO J A, ROTHWELL J C, LANG A E, MARSDEN C D (1983) Myoclonic dystonia. *Neurology, Cleveland*, **33**, 825-830.

- OBESO J A, MARTINEZ-VILA E, DELGADO G, VAAMONDE J, MARAVI E, MARTINEZ-LAGE J M, (1984) Delayed onset dystonia following hemiplegic migraine. *Headache*, **24**, 266-268.
- OPPENHEIM H (1911) Über eine eigenartige Krampfkrankheit des kindlichen und jugendlichen Alters (Dysbasia lordotica progressiva, Dystonia musculorum deformans). *Neurologisches Zentralblatt*, **30**, 1090-1107.
- OPPENHEIMER D R (1967) A case of striatal hemiplegia. *Journal of Neurology, Neurosurgery and Psychiatry*, **30**, 134-139.
- ROTHWELL J C, OBESO J A, DAY B L, MARSDEN C D (1983) Pathophysiology of dystonias. *Advances in Neurology*, **39**, 851-863.
- RUSSO L S (1983) Focal dystonia and lacunar infarction of the basal ganglia: a case report. *Archives of Neurology, Chicago*, **40**, 61-62.
- TRAUB M, RIDLEY A (1982) Focal dystonia in association with cerebral infarction. *Journal of Neurology, Neurosurgery and Psychiatry*, **45**, 1073-1074.
- URECHIA C-I, DRAGOMIR L, USINIEVICI G (1942-1943) Spasme de torsion unilatéral causé par une tumeur cérébrale. *Confinia Neurologica*, **5**, 271-280.
- ZEMAN W, WHITLOCK C C (1968) Symptomatic dystonias. In: *Handbook of Neurology*, Volume 6. Edited by P. J. Vinken and G. W. Bruyn, Amsterdam: North Holland, pp. 544-566.

(Received August 31, 1984. Revised October 25, 1984. Accepted October 30, 1984)