

Intracerebral Haemorrhage And Angiographic Beading Following Ingestion Of Catecholaminergics

A.J. STOESSL, M.D., G.B. YOUNG, M.D., AND T.E. FEASBY, M.D.

SUMMARY We report two cases of serious intracerebral haemorrhage occurring in young women following their first use of oral medications containing catecholaminergic agents (phenylpropanolamine in combination with ephedrine or pseudoephedrine). Both women were previously well, and there was no evidence for systemic vasculitis, coagulopathy, aneurysm or arteriovenous malformation. Angiography in both cases, performed approximately forty hours following drug ingestion, revealed the beading pattern typical of that seen in previously reported cases of presumed amphetamine-induced "vasculitis." We believe that this arteriographic abnormality is non-specific and should not be construed as necessarily indicative of arteritis.

Stroke Vol 16, No 4, 1985

THE INGESTION OF AMPHETAMINES by either oral or parenteral route has been associated with intracranial haemorrhage and with the angiographic appearance of "beading."¹⁻³ Following the demonstration by Citron et al⁴ of a syndrome in drug abusers that is clinically and pathologically reminiscent of polyarteritis nodosa, it has been usual to attribute such occurrences to drug-induced cerebral vasculitis. In many instances, the pathological support for this contention has been weak. We report two cases seen recently in which haemorrhage following ingestion of amphetamine congeners could not reasonably be attributed to an inflammatory angiopathy.

Case Histories

Patient 1

This 20 year old woman, previously in good health, ingested two capsules of a purported amphetamine look-alike twelve hours prior to her admission to hospital. There was no history of previous drug intake. Two hours later, she experienced severe headache and nausea, and after another hour, she developed right hemiparesis and aphasia, followed by progressive drowsiness. On admission, her blood pressure was 130/70 and the general physical examination was normal. She was drowsy and mute, and her eyes opened in response to voice. She had a right homonymous hemianopsia, deviation of her eyes to the left and a dense right spastic hemiparesis.

Normal laboratory investigations included complete blood count (CBC), sedimentation rate, prothrombin time (PT), partial thromboplastin time (PTT), anti-nuclear antibody (ANA), rheumatoid factor, hepatitis B surface antigen, C3, C4, CH50, Clq binding, urinary vanillylmandelic acid (VMA) metanephrine and free catecholamines. Blood and urinary toxic screens were negative. A computerized tomographic (CT) scan (fig. 1) revealed a left external capsular haemorrhage with shift of the midline structures. Cerebral angiography (fig. 2), performed 36 hours following drug ingestion, showed alternating narrowing and dilata-

tion of several branches of the middle cerebral artery. Analysis of the capsules demonstrated the presence of ephedrine, phenylpropanolamine and caffeine.

She was managed conservatively and made a slow but incomplete recovery. Three years later, she had minimal word-finding difficulty, normal visual fields and was fully ambulatory with a moderately severe spastic hemiparesis.

Patient 2

This 23 year old woman was previously in good health. Fifteen hours prior to admission, she ingested a single "black beauty" as a "wake-up" pill. She had not used these or similar agents in the past. One hour later, she experienced sudden headache, nausea and vomiting, and this was followed within an hour by aphasia and right hemiparesis. On admission, her BP was 130/90 and the general physical examination was unremarkable. She was obtunded and had a non-fluent aphasia, a right homonymous hemianopsia and a dense spastic right hemiparesis.

Normal laboratory values included CBC, sedimentation ratio, PT, PTT, Bleeding Time, immunoglobulins, ANA, rheumatoid factor and VDRL. A CT scan (fig. 3), showed a left ganglionic haemorrhage with mass effect. Angiography (fig. 4), performed approximately 40 hours after drug ingestion, revealed an avascular mass and patchy areas of spasm in branches of the middle and anterior cerebral arteries. Analysis of the ingested capsules revealed caffeine, phenylpropanolamine, pseudoephedrine and a barbiturate.

This woman was also managed conservatively and made a modest improvement. One year later, her language was normal, but she still had a moderate right arm paresis.

Discussion

The chronic abuse of drugs has been clearly associated with the development of a systemic necrotizing vasculitis that may be difficult to distinguish from polyarteritis nodosa, and amphetamines have been identified as common agents among the multitude of preparations ingested.⁴ Intracranial haemorrhage and the cerebral angiographic appearance of alternating narrowing and dilatation of vessels ("beading") have been reported in association with the chronic use of amphet-

From the Department of Clinical Neurological Sciences, University of Western Ontario, London, Ontario, Canada.

Address correspondence to: G.B. Young, M.D., Department of Clinical Neurological Sciences, Victoria Hospital, 375 South Street, London, Ontario, Canada N6A-4G5.

Received October 26, 1984; accepted January 10, 1985.

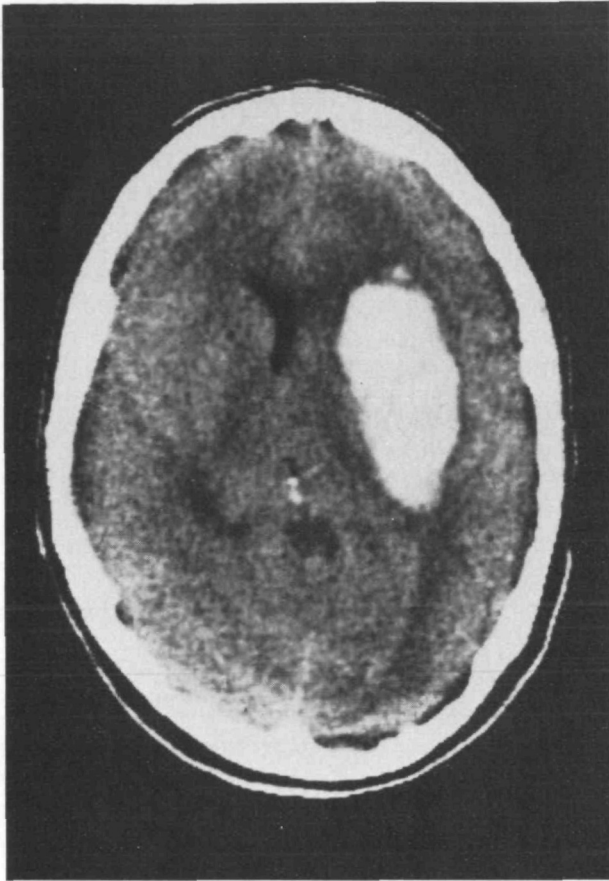


FIGURE 1 CT Scan (patient 1) showing a large left external capsular haemorrhage with mass effect.

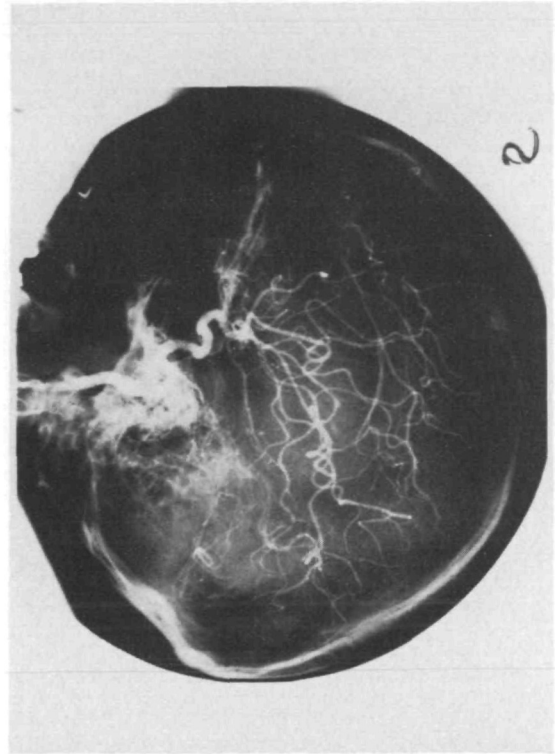


FIGURE 2 Left Carotid Angiogram (patient 1) reveals alternating narrowing and dilatation of several middle cerebral artery branches.

amines and have been attributed to cerebral vasculitis.¹⁻³

More recently, intracranial haemorrhage has been seen following the use of phenylpropanolamine^{5,6} and as a complication of pseudoephedrine overdose.⁷ Reports have also implicated the chronic abuse of nasal decongestant sprays⁸ and abuse of ephedrine.⁹ These drugs are used as decongestants, stimulants and appetite suppressants, and are readily available without prescription. Angiography has again demonstrated beading;⁷⁻⁹ in one case, this was seen following single-time use.⁷

The appearance of beading is non-specific, and has been noted in meningitis and encephalitis,¹⁰ and following aneurysmal subarachnoid haemorrhage.¹¹ In adult rhesus monkeys, transient angiographic changes were seen within ten minutes of intravenous administration of methamphetamine.¹² The abnormalities reverted to normal by 24 hours, but were again noted at one week. Further analysis suggests, however, that such animal studies are not truly representative of the human disorder, in that all of the monkeys experienced significant hypertension, and there was a high incidence of cardiac dysrhythmia, focal cerebral ischaemia and diffuse cerebral edema, as well as gross subarachnoid haemorrhage. Angiographic evidence of

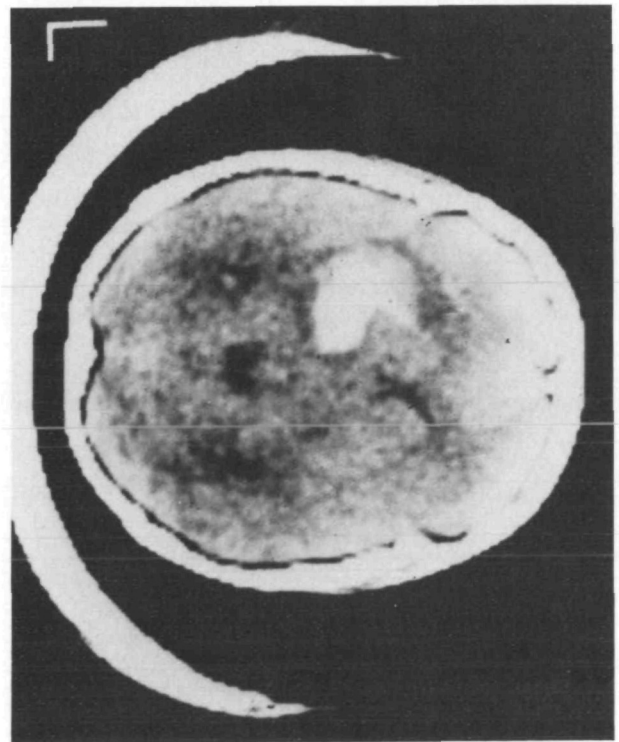


FIGURE 3 CT Scan (patient 2): left ganglionic haemorrhage with mass effect.

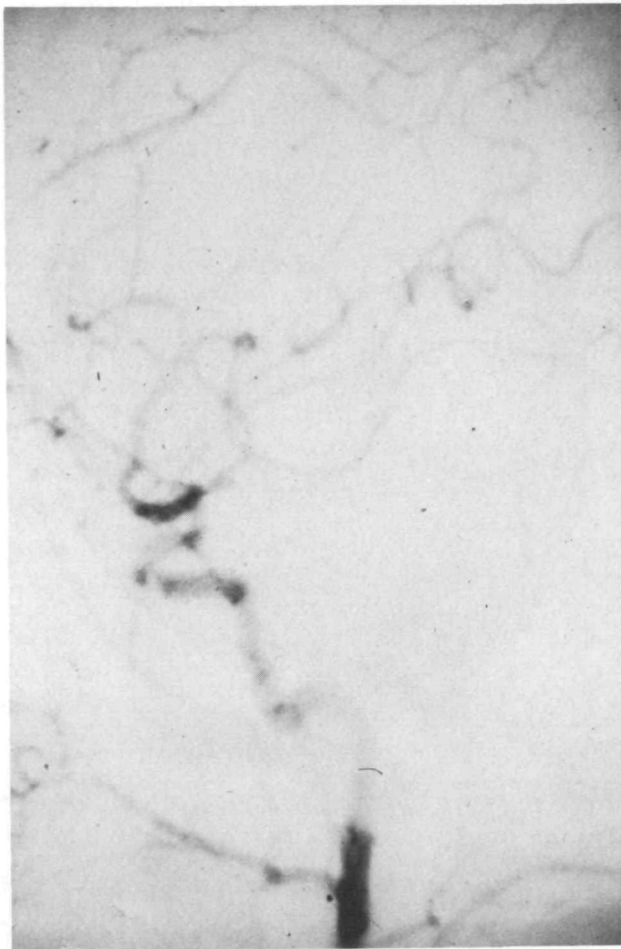


FIGURE 4 Left Carotid Angiogram (patient 2): patchy areas of spasm in anterior and middle cerebral artery branches.

spasm has also been seen acutely following the intracisternal injection of norepinephrine.¹³

Although extracerebral angiitis has been well demonstrated in drug abusers,^{4, 14} few attempts have been made to correlate cerebral arteriographic changes with histopathology. In 16 amphetamine-related haemorrhages reviewed by Delaney and Estes,³ 10 patients underwent angiography and beading was demonstrated in only 4. Of these, pathological study was lacking in 3, and necrotizing cerebral angiitis was demonstrated in the remaining patient.¹⁵ All 4 patients had subarachnoid haemorrhage.

In the case of ephedrine-related haemorrhage recently reported by Wooten and colleagues,⁹ beading was not seen on the initial angiogram, but was found at followup study. The second angiogram was, however, complicated by symptoms of ischaemia in the distribution of the injected artery (left carotid), and the beading may therefore have been related to contrast-induced spasm.

In our own cases, the early appearance of haemorrhage and associated angiographic changes following single use of oral catecholaminergics in systemically healthy young women does not support the diagnosis of an immunopathologic illness such as vasculitis. The beading is more likely to result from catecholamine-mediated vasospasm in part directly related to the drugs, and possibly also secondary to the haemorrhage, which may have been due to transient hypertension.

We feel that the angiographic appearance of beading associated with ingestion of catecholaminergics is non-specific and subject to over-interpretation. Furthermore, we share the concerns expressed by others^{6, 16, 17} regarding the potential risks of such readily and often legally available agents.

Editor's Note:

This article was guest edited by J.P. Mohr in accordance with *Stroke* policy.

References

1. Rumbaugh CL, Bergeron RT, Fang HCH, McCormick R: Cerebral angiographic changes in the drug abuse patient. *Radiology* **101**: 335-344, 1971
2. Olsen ER: Intracranial haemorrhage with amphetamine abuse. *Angiology* **28**: 464-470, 1976
3. Delaney P, Estes M: Intracranial haemorrhage with amphetamine abuse. *Neurology* **30**: 1125-1128, 1980
4. Citron BP, Halpern M, McCarron M et al: Necrotizing angitis associated with drug abuse. *N Engl J Med* **283**: 1003-1011, 1970
5. King J: Hypertension and cerebral haemorrhage after Trimollets ingestion. *Med J Aust* **2**: 258, 1979
6. Bernstein E, Diskant BM: Phenylpropanolamine, a potentially hazardous drug. *Ann Emerg Med* **11**: 311-315, 1982
7. Loizou LA, Hamilton JG, Tsementzis SA: Intracranial haemorrhage in association with pseudoephedrine overdose. *J Neurol Neurosurg Psychiatr* **45**: 471-472, 1982
8. Garcia-Albea E: Subarachnoid haemorrhage and nasal vasoconstrictor abuse. *J Neurol Neurosurg Psychiatr* **46**: 875-876, 1983
9. Wooten MR, Khangure MS, Murphy MJ: Intracerebral haemorrhage and vasculitis related to ephedrine abuse. *Ann Neurol* **13**: 337-340, 1983
10. Leeds NE, Goldberg HI: Angiographic manifestations in cerebral inflammatory disease. *Radiology* **98**: 595-604, 1971
11. Wood EH: Intracranial aneurysms. *Radiologic Clinics of North America* **4**: 217-233, 1966
12. Rumbaugh CL, Bergeron RT, Scanlan RL et al: Cerebral vascular changes secondary to amphetamine abuse in the experimental animal. *Radiology* **101**: 345-351, 1971
13. Alksne JF, Greenhoot JH: Experimental catecholamine-induced chronic cerebral vasospasm. *J Neurosurg* **41**: 440-445, 1974
14. Stafford CR, Bogdanoff BM, Green L, Spector HB: Mononeuropathy multiplex as a complication of amphetamine angiitis. *Neurology* **25**: 570-572, 1975
15. Kessler JT, Jortner BS, Adapon BD: Cerebral vasculitis in a drug abuser. *J Clin Psychiatr* **39**: 559-564, 1978
16. Mueller SM: Phenylpropanolamine — a non-prescription drug with potentially fatal side effects. *N Engl J Med* **308**: 653, 1983
17. Mueller SM: Neurologic complications of phenylpropanolamine use. *Neurology* **33**: 650-652, 1983