

Universal Dissociated Anesthesia due to Bilateral Brain-Stem Infarcts

Nagapal Venna, MD, MRCP(I), MRCP(UK), Thomas D. Sabin, MD

● A 59-year-old man had loss of pinprick and temperature sensation over his head, face, neck, trunk, and all extremities while light touch, vibration, joint position sense, and deep pain were preserved. This was the cumulative result of infarctions in the territories of the right superior cerebellar and left posterior inferior cerebellar arteries that occurred three years apart. To our knowledge, a syndrome of bilateral discrete interruption of spinothalamic tracts and of the spinal tracts of the trigeminal system in the brain stem has not been reported. Dissociated sensory loss enveloping the entire body accompanied by truncal and limb ataxia without weakness demonstrated a striking clinical picture. The preservation of deep somatic and visceral pain when cutaneous pain sensation was lost was another notable feature. We review the causes of widespread dissociated sensory loss and discuss the implications of the dissociation of deep from superficial pain.

(*Arch Neurol* 1985;42:918-922)

Infarction in the territory of the posterior inferior cerebellar artery (PICA) produces the unique and well-recognized Wallenberg's lateral medullary syndrome. Infarction in the pons and cerebellum due to occlusion of the superior cerebellar artery (SCA) is much less common. We had the opportunity to observe a patient who suffered an SCA distribution

infarction followed three years later by contralateral PICA syndrome. We paid particular attention to the unusual sensory abnormalities that accrued from these strategically placed lesions.

REPORT OF A CASE

At age 52, the patient experienced new onset of intermittent headaches spreading from the back of the neck to the forehead. Six months later, in June 1976, the patient was struck by a brief loss of consciousness followed by dizziness and imbalance. Physical examination showed markedly slurred speech, left central facial weakness, transient, mild left hemiparesis, and severe, persistent ataxia of the right upper and lower extremities. This picture was consistent with infarction in the distribution of right SCA. There was no evidence of diabetes mellitus or hypertension, but occult rheumatic mitral stenosis without atrial fibrillation was detected. Warfarin sodium (Coumadin) therapy was started on the assumption that the brain-stem infarction was secondary to cardiogenic embolism.

In January 1979, the patient experienced an abrupt onset of syncope, headache, dizziness, slurred speech, and unsteadiness. Physical examination demonstrated a normal mental state, skew deviation of the eyes, constant rotatory nystagmus that became left-beating on left gaze, and left Horner's syndrome. Sensation to pinprick and temperature was diminished on the left half of the face and movement of the left half of the soft palate was decreased. There was ataxia of the left upper and lower extremities but no comment was made about the sensation on the body. Distressing hiccups that persisted for two weeks completed the clinical picture of left lateral medullary infarction. Two weeks later dense macular-sparing right homonymous hemianopia due to infarction of the left calcarine cortex developed. A four-vessel angiogram showed nearly complete occlusion of the vertebral arteries at the C-1 to C-2 level.

A year later, when the patient was seen for myoclonic jerks of the upper extremities and abrupt momentary lapses of posture, cuts and cigarette burns were observed on the fingers of which he was unaware. Two years after the last stroke, distressing burning and stinging sensations appeared over the face, extremities, and trunk and the patient had become deeply depressed. Both the mood and dysesthesias improved gradually on tricyclic antidepressant drug therapy.

Examination in June 1982

This article is based chiefly on this examination six years after the first stroke. The patient was depressed but his mental state was otherwise normal. Right homonymous hemianopia, left-sided Horner's syndrome, and constant rotatory nystagmus intensified by left gaze and variably altered by head position, bilateral depression of corneal reflex, markedly dysarthric speech, and decreased movements of the left side of the palate were noted. Ataxia of the cerebellar type was pronounced in all extremities along with postural tremor of the upper extremities. The knee reflexes were pendular and the left plantar reflex was upgoing. His gait was wide-based and unsteady.

Sensory Examination

Figures 1 and 2 showed a marked decrease in the sensation of pinprick over the head and face including the external ear and on the neck, trunk, extremities, perineal region, scrotum, and penis. Pinprick was markedly diminished over the mucous membranes of the lips, gums, cheeks, tongue, and palate, while taste and smell sensations were normal. There was marked decrease in appreciation of hot and cold as tested by test tubes of hot water and ice water in the same distribution, except over the paraspinal area of the lower trunk. Temporal summation was demonstrated with repeated pinpricks over all the extremities and application of cold to the legs caused a disagreeable sensation.

Accepted for publication July 3, 1984.

From the Department of Neurology, Boston University School of Medicine, and the Neurological Unit, Boston City Hospital.

Reprint requests to Neurological Unit, Boston City Hospital, 818 Harrison Ave, Boston, MA 02118 (Dr Venna).

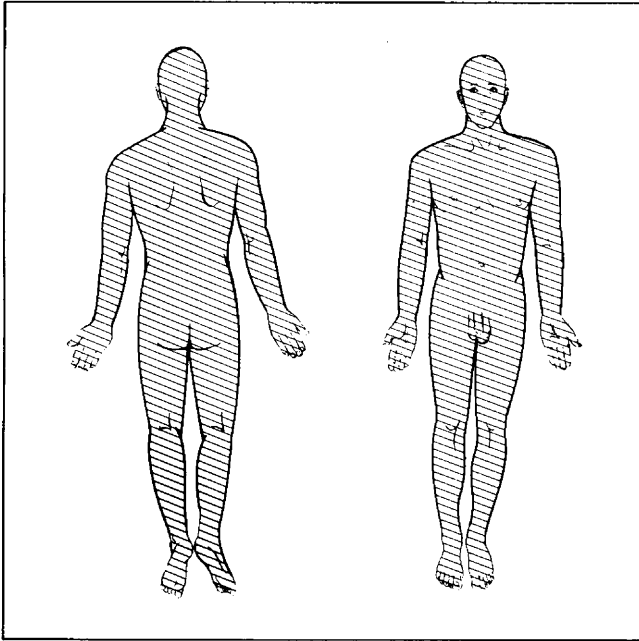


Fig 1.—Sensory examination showing marked decrease in pinprick sensation (slanted lines) over head, face, external ear, neck, trunk, extremities, perineal region, scrotum, and penis.

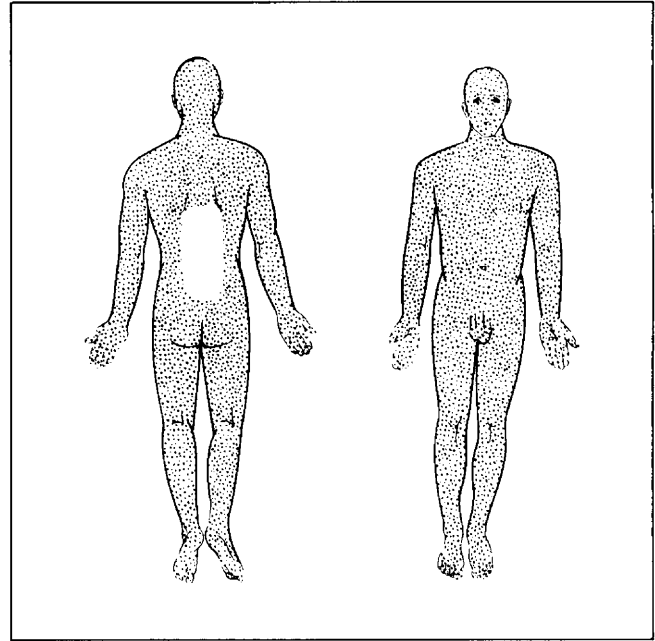


Fig 2.—Sensory examination showing marked decrease in thermal sensation (dots) over most of body except paraspinal area of lower trunk.

Deep pain was tested in the lower extremities by squeezing the Achilles tendons and calf muscles, pinching full thickness of the skin of the thighs, deep pressure on the pretibial regions, and passive hyperextension of the toes. All these maneuvers provoked pain described by the patient and readily observed in his facial expression. Pressure over the anterior superior iliac spines, squeezing the testicles, and pressure over the sternum also easily elicited pain. In the upper extremities, pain was produced by pinching the axillary fold, squeezing the forearm and upper arm muscles, and passive hyperextension of the fingers. Pressure over the supraorbital region, frontal and maxillary sinuses, and the stylomastoid processes was equally painful. Immersion of upper limbs to the elbows in ice water for two minutes failed to produce the deep aching pain normally felt in the shoulder area within 20 s. Light touch, vibration, and passive movements of joints were normal over the entire body.

A month after this examination severe and typical left pleuritic chest pain due to left upper lobe pneumonia developed in the patient. A short time later he fell and sustained a contusion of his right thigh and hip and in another fall, contusion of the foot and toes. Both episodes caused normal deep pain for over two weeks. At the time of foot contusion, moving the bruised toes was markedly painful, while pinprick over the same toes was not felt.

Laboratory Tests

A computed tomographic (CT) scan (Fig 3, left and right) of the brain in June 1982 demonstrated a right cerebellar low density consistent with right SCA territory infarction. In addition, left calcarine

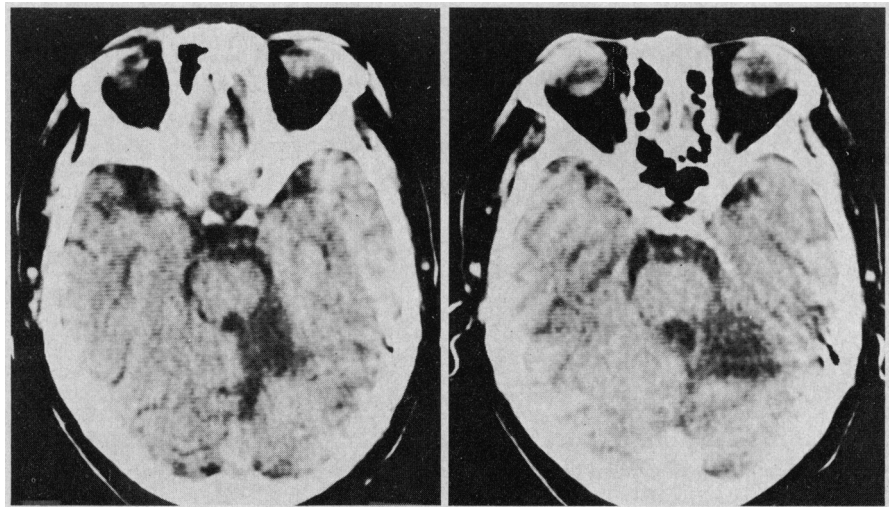


Fig 3.—Computed tomographic (CT) scan of brain in June 1982 showing infarction in territory of right superior cerebellar artery. Left, Low density in right half of cerebellar vermis. Right, Low density in superior aspect of right cerebellar hemisphere. In both CT scans, low-density area abuts on fourth ventricle.

and left posterior parietal infarctions were seen.

COMMENT

The first stroke is consistent with infarction in areas of the pons and cerebellum supplied by the SCA.^{1,3} The structures usually affected by SCA occlusion are in the lateral superior segment of the pons and include the lateral spinothalamic tract, spinal tract of the fifth cranial nerve, the descending sympathetic fibers, the superior and middle cerebellar peduncles, and the superior surface of the

cerebellum and dentate nucleus (Fig 4). The second stroke is typical of Wallenberg's lateral medullary syndrome (Fig 5) resulting from infarction in the distribution of PICA though the occlusion is usually in the vertebral artery at the mouth of the PICA.^{4,5} The infarction in the lateral corner of the medulla affects the descending tract and nucleus of the fifth cranial nerve, lateral spinothalamic tract, the descending sympathetic chain, the nucleus ambiguus of the vagus nerve, and vestibular nuclei,

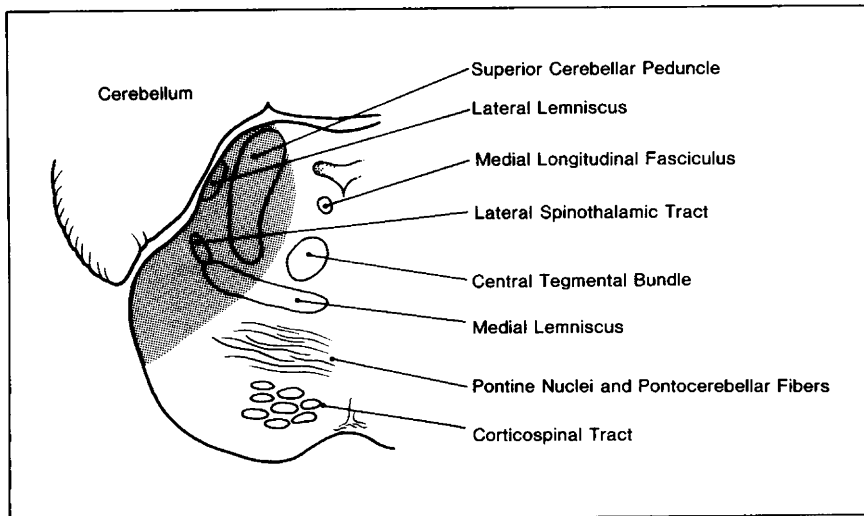


Fig 4.—Outlines structures usually affected by superior cerebellar artery occlusion resulting in lateral superior pontine infarction.

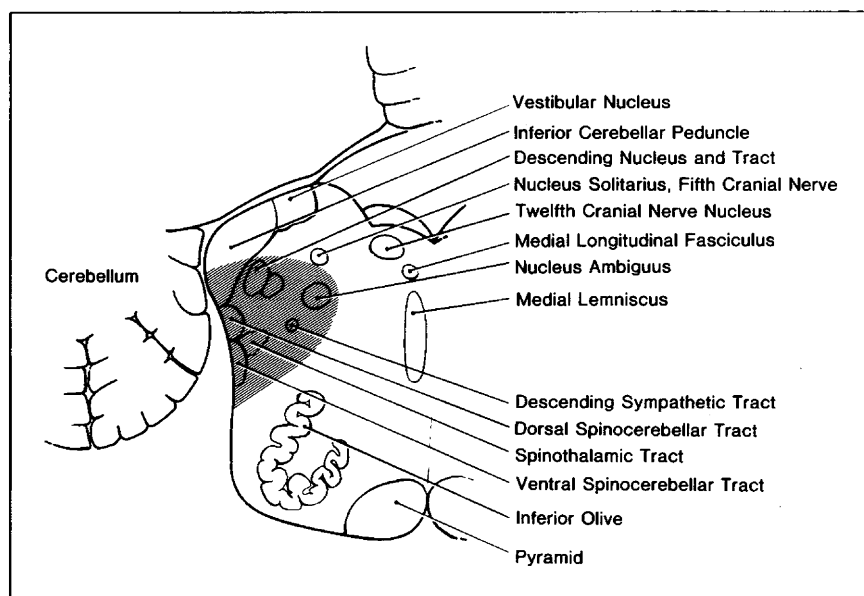


Fig 5.—Stroke pattern typical of Wallenberg's lateral medullary syndrome.

as well as the inferior cerebellar peduncle and the inferior surface of the cerebellum. In addition, the patient had an infarction in the left calcarine cortex and a left parietal infarction without evidence of aphasia or Gerstmann's syndrome. The basis of these lesions seemed to be vertebrobasilar atherosclerosis-thrombosis and cardiogenic embolism due to mitral stenosis.

Sensory Abnormalities

The outstanding feature in this patient is the cutaneous analgesia to pinprick and temperature stimuli that enveloped the body from the vertex to the toes and analgesia of the buccolingual mucous membranes. In contrast,

light touch, vibration, and joint position sense were exquisitely preserved. This picture of total body dissociated sensory loss (loss of pinprick and temperature with preservation of light touch and proprioception) without weakness due to brain-stem lesions has not been previously described to our knowledge. The strategic location and unusual combination of the brain-stem infarcts led to the appearance of this remarkable syndrome. Based on clinicopathologic features of SCA and PICA infarctions, we conclude that the sensory abnormality resulted from the interruption of the lateral spinothalamic tracts and the spinal tracts of the trigeminal systems of both sides of the brain stem. Thus the

chief nociceptive pathways of the extremities, trunk, head, and neck have been discretely interrupted, while principle proprioceptive pathways in the medial lemnisci and the corticospinal motor system were unaffected. The intactness of sensation over the trunk, as depicted in Fig 2, is difficult to explain on an anatomic basis because the trunk fibers are located between the cervical and sacral fibers in the lateral spinothalamic tract laminations of the brain stem. It may be that recovery of thermal sensation had begun in this area.

The question of asymbolia to pain^{6,7} is addressed here because the patient was found to have an infarction in the posterior left parietal lobe on CT scan. Such a lesion in the vicinity of the left supramarginal and angular gyri may cause this rare syndrome of striking absence of the normal defensive and facial reactions to painful stimuli applied to either side of the body. Patients may inflict severe injury on themselves accidentally or deliberately. Sometimes this abnormal response extends to other threatening stimuli such as loud noises or sudden flashes of light. However, the patients can distinguish pinprick and temperature and perceive touch and proprioception. In most instances there are neighborhood signs of aphasia, fragments of Gerstmann's syndrome, apraxia, and extinction of double simultaneous stimulation with touch. Therefore, our patient's sensory abnormalities are not consistent with asymbolia to pain.

The possibility of coexisting cerebral hemispheric lesions causing bilateral dissociated sensory loss must also be considered. Cerebral lesions near the somatosensory cortex can produce impairment of pain and temperature sensibility in the contralateral half of the body, but this is usually evanescent. However, Bie-mond⁸ described unusual cases of enduring impairment of pinprick and thermal sensation on the contralateral half of the body including the face and trunk with preservation of light touch, position, and vibration sense and stereognosis but the state of deep pain was not described. The lesions were located in or under the parietal operculum. This chronic dissociated hemianesthesia is the reverse of the usual pattern of suprathermal lesions where proprioception, light touch, deep pain, and stereognosis are severely decreased while pain and temperature are little affected. Bie-mond⁸ postulated that this syndrome

of dissociated anesthesia may be due to the involvement of the secondary somatosensory area located in the parietal operculum. In our patient there is only one parietal lesion and it is retrosylvian and thus unlikely to cause the sensory disturbance.

The syndrome of universal dissociated sensory loss without paralysis observed in our patient is seen in only a few other rare diseases. In congenital indifference to pain,^{9,10} the patients, from early childhood, show an astonishing lack of normal reflex and affective and vegetative responses to superficial and deep pain. They sustain repeated cuts, burns, fractures, and visceral catastrophes without pain. However, neurological examination demonstrates that they can discriminate pinprick, heat, touch, and joint movement, and pressure at a normal threshold and tendon reflexes are normal. Thus the hallmark of the disease is the altered reaction to superficial and deep pain. No pathologic substrate has been found, but a recent study indicates that the endogenous opiate system may be hyperactive.^{11,12}

Congenital insensitivity to pain with anhidrosis¹³ is a rare syndrome characterized by severe, universal impairment of superficial and deep somatic and visceral pain and temperature sensibility while touch, proprioception, and tendon reflexes are intact. Sweating is absent and the patients are mildly mentally retarded. Absence of the small neurons of dorsal root ganglia and Lissauer's tracts of the spinal cord, and attenuation of the descending tract of trigeminal nerves has been observed on postmortem examination. Thus there is selective lack of development of the principle pain-conducting structure of nerve roots and spinal cord.

Certain types of polyneuropathies due to amyloidosis¹⁴ and a rare form of diabetic polyneuropathy¹⁵ are known to cause dissociated anesthesia, but the stocking-glove pattern of the distribution of sensory change is distinctive. Kocen et al¹⁶ described a patient with the Tangier disease (α -lipoprotein deficiency) who was seen with dissociated sensory loss over the head, face, neck, upper extremities, trunk, and most of the lower extremities except the lower parts of the legs and feet, which was due to peripheral neuropathy. Enlarged orange-colored tonsils and deficiency of plasma α -lipoprotein are the hallmarks of this disease.

An occasional case of syringomyelia extending into the medulla and the

thoracic and lumbar spinal cord can cause extensive dissociated anesthesia by interrupting the decussating nociceptive fibers and the spinothalamic tracts,¹⁷ but segmental amyotrophy and segmental loss of tendon reflexes distinguish this disorder. Dissociated anesthesia of all limbs and trunk occur in anterior spinal artery occlusion with infarction of the high cervical spinal cord,¹⁸ but the face is not affected and quadriplegia is present.

Dissociation of Superficial and Deep Pain

A remarkable feature in our patient is the intactness of deep somatic pain sensibility with marked impairment of superficial pain (dissociated analgesia). This is demonstrated by normal pain elicited by stimuli applied to the tendons, muscles, and periosteum and by the patient's experience of pain from trauma to soft tissues of the thigh and foot. Preservation of normal pain elicited by testicular compression and the experience of pain from the pleural inflammation indicates intact visceral pain. Thus, this patient demonstrates that superficial pain loss can be dissociated from deep somatic and visceral pain at some stage. Unfortunately, the deep pain perception was not tested until six years after the first stroke, so that we cannot determine whether both deep and superficial forms of pain were initially lost with preferential recovery of deep pain or whether these modalities of pain were differentially affected from the outset.

The information on the alterations of deep pain resulting from lesions of central pathways is scanty because it has not been examined systematically even when the patient's chief symptom is sensory loss. To our knowledge, there are no cases of cerebral hemispheric lesions where deep pain has been specifically probed. Only slightly more information is recorded in relation to lesions of the medulla. Soffin et al¹⁹ described the fascinating evolution of patterns of dissociated sensory loss from the PICA syndrome in several patients, but the fate of deep pain is not recorded. Nathan²⁰ alluded to two patients with PICA syndrome in whom deep painful stimuli to the analgesic side were referred to the *normal* side of the body. Patients who underwent lateral medullary tractotomy offer another opportunity to examine this situation. In this procedure, spinothalamic tracts in the retro-olivary segment of the medulla are cut to obtain relief from intractable pain in the upper extremity, shoul-

der, upper thorax, and neck. In most cases, deep pain is abolished along with cutaneous pain sensibility in the contralateral body to the neck but the original pain returns weeks, months, or a few years later. It is not known if superficial and deep pain sensibility recover hand in hand or differentially. White and Sweet²¹ refer to a patient where contralateral testicular pain was elicited even though there was complete cutaneous analgesia to the chin. To our knowledge, there are no reported cases of bilateral lateral medullary lesions, spontaneous or surgical.

Deep pain has been more extensively studied in patients who underwent anterolateral cordotomy for intractable pain, aimed at interrupting the lateral spinothalamic fibers. Most lesions are made in the thoracic spinal cord but some lesions are in the cervical spinal cord. The results are similar to medullary tractotomies in that cutaneous analgesia occurs along with abolition of deep pain for which the operation is indicated, but after weeks to years, original pain returns. Again the relationship between disappearing cutaneous analgesia and returning deep pain has not been recorded critically. Despite these general findings, White and Sweet²¹ and Hyndman and Wolkin²² observed that some of their patients with unilateral anterolateral cordotomies experienced deep pain in the parts of the body with cutaneous analgesia on compression of the testicle, squeezing of Achilles tendon, and bone pressure, and one felt the pain of a fractured ankle, another felt pain from contusion of the thigh. Nathan²⁰ noted that in patients who underwent unilateral cordotomy deep pain stimuli to the analgesic parts were referred to the normally innervated contralateral side or to the ipsilateral side above the sensory level. Nathan²⁰ also described a patient with destruction of *both* anterior quadrants of the spinal cord as a result of anterior spinal artery infarction in whom deep pain below the level of dissociated sensory loss was referred to the body above the sensory level. Thus, there is some evidence that medullary and spinal cord lesions in the vicinity of the lateral spinothalamic tracts can lead to a situation where cutaneous pain is abolished but deep pain is still felt either normally or distorted and referred to normally innervated parts of the body.

Little is known of the pathways in the CNS by which pain from deep somatic tissues and viscera is transmitted. It is generally stated that this

information travels with or in the spinothalamic system.²³ The retention of deep pain while cutaneous pain is lost, as in our patient, after bilateral lesions of spinothalamic tracts and spinal tracts of the trigeminal complex lends itself to several interpretations of its mechanism: it may be that all modalities of pain are, under normal circumstances, conveyed by spinothalamic tracts, but after injury deep pain recovers better and sooner than cutaneous pain. Alternatively, deep pain may be transmitted by tracts that are separate but in proximity to spinothalamic fibers such as spinotectal and spinoreticular tracts.²⁴ Tracts in the posterior half of the spinal cord may be involved in nociception either normally or when activated by interruption of spinothalamic tracts by disease or surgery. For instance, the dorsal intercuneal tract, a system of polysynaptic connections ascending in the gray matter of dorsal horns, has been proposed as a potential pathway.²⁴ Denny-Brown²⁵ proposed a similar pathway of pain transmission in a posterior spinal commissure interconnecting the substantia gelatinosa and spinocervical tracts of the two sides to explain the extraordinary results of cordotomies in the monkey. He showed that pain that was abolished by hemisection of the spinal cord returned after bilateral destruction of the ventral cord!

Careful evaluation of the state of deep somatic and visceral pain is indi-

cated in patients with disturbances of pain perception from CNS as well as peripheral nervous system lesions. This, we believe, will broaden the clinical spectrum in which deep pain is affected and will throw light on its mechanisms.

References

1. Luhan JA, Pollack SL: Occlusion of the superior cerebellar artery. *Neurology* 1953;3:77-89.
2. Freeman W, Jaffe D: Occlusion of the superior cerebellar artery: Report of case with necropsy. *Arch Neurol* 1941;46:115-126.
3. Gillian LA: The correlations of the blood supply to the human brain stem with clinical brain-stem lesions. *J Neuropathol Exp Neurol* 1964;23:78-108.
4. Currier RD, Giles CL, DeJong RN: Some comments on Wallenberg's lateral medullary syndrome. *Neurology* 1961;11:778-791.
5. Fisher CM, Karnes WE, Kubik CS: Lateral medullary infarction: The pattern of vascular occlusion. *J Neuropathol Exp Neurol* 1961;20:323-379.
6. Schilder P, Stengel E: Asymbolia for pain. *Arch Neurol* 1931;25:598-600.
7. Heceaen H, de Ajuriaguerra J: Asymbolie a la douleur, étude anatomodinique. *Rev Neurol* 1950;83:300-302.
8. Biemond A: The conduction of pain above the level of the thalamus opticus. *Arch Neurol* 1956;75:231-244.
9. Arbuse DI, Cantor MB, Barenberg PA: Congenital indifference to pain. *J Pediatr* 1949;35:221-226.
10. Baxter DW, Olszewski J: Congenital universal insensitivity to pain. *Brain* 1960;83:381-393.
11. Dehen H, Willer JC, Prier S, et al: Congenital insensitivity to pain and the "morphine-like" analgesic system. *Pain* 1978;5:351-358.
12. Hishashi Y: Congenital insensitivity to pain and naloxone. *Lancet* 1978;2:502-521.
13. Swanson AG: Congenital insensitivity to pain with anhidrosis. *Arch Neurol* 1963;8:299-306.
14. Andrade C: A peculiar form of peripheral neuropathy. *Brain* 1952;75:408-427.
15. Brown MJ, Marton JR, Asbury AK: Painful diabetic neuropathy: A morphometric study. *Arch Neurol* 1976;33:164-171.
16. Kocenc RS, Lloyd JK, Lascelles PT, et al: Familial alpha-lipoprotein deficiency (Tangier disease) with neurological abnormalities. *Lancet* 1967;1:1341-1345.
17. Adams RD, Victor M: Diseases of the spinal cord, in *Principles of Neurology*, ed 2. New York, McGraw-Hill Book Co, 1981, chap 35, p 643.
18. Moossy J: Vascular diseases of the spinal cord, in Baker AB, Baker LH (eds): *Clinical Neurology*. New York, Harper & Row Publishers Inc, 1983, vol 3, chap 46, p 13.
19. Soffin G, Feldman M, Bender MB: Alterations of sensory levels in vascular lesions of lateral medulla. *Arch Neurol* 1968;18:178-190.
20. Nathan PW: Reference of sensation at the spinal level. *J Neurol Neurosurg Psychiatry* 1956;19:88-100.
21. White JC, Sweet WH: Spinothalamic tractotomy: Comparison of the results of tractotomy at different levels of spinal cord and brain stem, in *Pain and the Neurosurgeon*. Springfield, Ill, Charles C Thomas Publisher, 1969, chap 15, pp 689-690.
22. Hyndman OR, Wolkin J: Anterior chordotomy. *Arch Neurol* 1943;50:129-148.
23. Mountcastle VB: Pain and temperature sensibilities, in Mountcastle VB (ed): *Medical Physiology*. St Louis, CV Mosby Co, 1974, vol 1, chap 11, p 369.
24. Kerr FWL, Fukushima T: New observation on the nociceptive pathways in the central nervous system, in Bonica JJ (ed): *Pain*. New York, Raven Press, 1980, pp 47-61.
25. Denny-Brown D: The enigma of crossed sensory loss with cord hemisection, in Bonica JJ, Leibeskin JC, Albe-Fessard DG (eds): *Advances in Pain Research and Therapy*. New York, Raven Press, 1979, vol 3, pp 889-895.

Isolated Cerebral Phycomycosis Presenting as Focal Encephalitis

Danny F. Watson, MD; Barney J. Stern, MD; Michael L. Levin, MD; Deepa Dutta, MD

● A patient with features of a focal encephalitis was found to have isolated cerebral phycomycosis. No risk factors for phycomycosis were present, and the diagnosis was made by brain biopsy.

(*Arch Neurol* 1985;42:922-923)

Accepted for publication Nov 8, 1984.
From the Department of Neurology, The Johns Hopkins Hospital, Baltimore (Drs Watson and Stern), and the Departments of Medicine (Drs Stern and Levin) and Pathology (Dr Dutta), Sinai Hospital of Baltimore.

Reprint requests to Division of Neurology, Sinai Hospital of Baltimore, Baltimore, MD 21215 (Dr Stern).

The patient with fever, confusion, and focal cerebral signs requires urgent diagnosis and treatment. When the course of the illness, results of cerebrospinal fluid (CSF) examination, and computed tomographic (CT) scans are compatible with a focal encephalitis, brain biopsy must be considered to investigate the possibility of herpes simplex encephalitis (HSE). We report a case in which brain biopsy for suspected HSE established the diagnosis of phycomycosis confined to the central nervous sys-

tem (CNS) in a patient without known risk factors.

REPORT OF A CASE

A 26-year-old woman developed fever, headache, nausea, vomiting, and lethargy that grew steadily worse. On the fourth day of her illness, she complained of diplopia. The next day, her family noted mild difficulty with her speech. On the sixth day, she was brought to the emergency room because of worsening confusion and inability to speak. Her medical history was notable only for asthma and allergic rhinitis. Her medications were oral contracep-