

20. Rosenberg NL, Koller R: Computerized tomography and pure sensory stroke. *Neurology (Ny)* **31**: 219–220, 1981
21. Landi G, Anzalone N, Vaccari U: CT scan evidence of posterolateral thalamic infarction in pure sensory stroke. *J Neurol Neurosurg Psychiatr* **47**: 570–571, 1984 (Letter)
22. Chiappa KH: Evoked potentials in clinical medicine. New York: Raven Press, 1983
23. Chiappa KH, Choi S, Young RR: Short latency somatosensory evoked potentials following median nerve stimulation in patients with neurological lesions. *Progr Clin Neurophysiol* **7**: 264–281, 1980
24. Goldie WD, Chiappa KH, Young RR, Brooks EB: Brainstem auditory and short-latency somatosensory evoked potentials in brain death. *Neurology (Ny)* **31**: 248–256, 1981
25. Chiappa KH, Ropper AH: Evoked potentials in clinical medicine (part 2). *New Engl J Med* **306**: 1205–1211, 1982
26. Celesia GG: Somatosensory evoked potentials recorded directly from human thalamus and sml cortical area. *Arch Neurol* **36**: 399–405, 1979
27. Manguiere F, Desmedt JE, Courjon J: Neural generation of N18 and P14 farfield somatosensory evoked potentials studied in patients with lesion of thalamus or thalamo-cortical radiations. *EEG Clin Neurophysiol* **56**: 283–292, 1983

Amnestic Syndrome and Vertical Gaze Palsy: Early Detection of Bilateral Thalamic Infarction by CT and NMR

R. A. SWANSON, M.D., AND J. W. SCHMIDLEY, M.D.

SUMMARY A 27 year old woman with mitral valve prolapse presented with somnolence, bilateral Babinski signs, and grasp reflexes. As somnolence cleared, vertical gaze palsy and Korsakoffian memory deficit were apparent. Initial CT scan was normal, but NMR scan 24 hours after the onset of symptoms revealed prolonged T2 relaxation in medial thalami bilaterally, facilitating diagnosis of bithalamic infarction. Subsequent CT scans delineated infarction in the vascular territory of the paramedian thalamic arteries. Previous clinical reports and the neuro- and vascular anatomy underlying this syndrome are reviewed, including cases that suggest a relationship to the syndrome of transient global amnesia.

Stroke Vol 16, No 5, 1985

IN 1978 MILLS AND SWANSON¹ described a patient with persistent vertical oculomotor apraxia, somnolence, and severe impairment of memory, presumably the result of bilateral medial thalamic infarction. Two and one-half years after the acute event a CT scan revealed a widened third ventricle, and small, approximately symmetric zones of low absorption in both dorsomedial thalami.

We have recently seen a patient with a nearly identical syndrome, and were able to use NMR imaging to detect bithalamic lesions within 24 hours of admission. High resolution CT scanning documented the evolution of bilateral dorsomedial thalamic infarctions over a ten day period.

Case Report

A 27 year old woman awoke on the day of admission complaining of headache, double vision, nausea and unsteadiness. She returned to bed and two hours later was barely arousable. She was taken to the emergency room where she was lethargic and vomited several times.

She did not use any medications, illicit drugs, or cigarettes. Blood pressure was 110/70, heart rate 80,

respiratory rate 18, and temperature 36°C. General physical examination was unremarkable with the exception of a late systolic click with grade 3/6 apical systolic murmur. Peripheral pulses were full throughout. There were no bruits or cutaneous lesions. Fundi were normal.

The patient was stuporous but arousable with vigorous verbal or physical stimuli. When awakened she was able to follow simple commands. She did not speak spontaneously but was able to nod "yes" or "no". Ocular axes were skewed in the vertical plane, the left eye resting lower than the right, with full horizontal extraocular movements to doll's head maneuver. Pupils were 3 mm bilaterally and reactive. Corneal responses were brisk. Palate was midline, with brisk elevation to gag. The limbs were paratonic. She moved all limbs spontaneously, and withdrew from noxious stimuli appropriately. The tendon reflexes were brisk; bilateral extensor plantar responses and grasp reflexes were present. There were no meningeal signs.

Twenty-four hours later the patient was much less obtunded and was able to answer questions, although still tending to sleep if not stimulated. She knew her name, the year, her home address, and that she was in a hospital. The skew deviation had resolved. Lateral gaze was normal but she was unable to voluntarily move her eyes up or down to command or pursuit. However, full ocular excursions in the vertical plane were obtained with vertical doll's head maneuver. Bell's phenomenon was present on attempted eye clo-

From the Department of Neurology, University of California, San Francisco, San Francisco, California.

Address correspondence to: R. A. Swanson, M.D., Department of Neurology, M-794, University of California, San Francisco, San Francisco, California 94143.

Received August 9, 1984; revision #1 accepted February 21, 1985.

sure and vertical optokinetic stimuli elicited nystagmus. There was mild ataxia of the right hand and leg with normal strength and sensory functions.

Intravenous heparin anticoagulation was begun. Over the next six days the ataxia and pathological reflexes resolved and the patient became gradually less somnolent. It became apparent that despite normal language, judgement, and arithmetic ability there was a profound memory deficit. She could not remember the names of test objects longer than two minutes. She was unable to recall events of the day and frequently confabulated answers. Long term memory was affected in an uneven fashion. Previous addresses, jobs, and acquaintances were recited accurately, but she was unable to give her phone number, and could not name present or past California governors or U.S. presidents. Digit span, however, was excellent — seven digits forward and five in reverse. Affect was characterized by indifference, facetiousness, and paucity of spontaneous speech. The vertical gaze abnormality resolved by the 11th day after the ictus.

At one month her roommate described her as “taking no interest in things” and as being deficient in personal grooming. She “was easily upset by [trite] TV shows.” At three months she was felt by friends and family to have entirely recovered, and on neurologic exam was normal.

Laboratory Studies

CBC, platelet count, sedimentation rate, urine homocysteine, serum protein electrophoresis, ANA titer, and EKG were normal. 2D-echocardiogram revealed mitral valve prolapse and mild aortic valve prolapse. Anti-thrombin III activity was slightly low at 75%. CSF obtained the day of admission and 9 days later was entirely normal, including electrophoretic pattern and IgG index. EEG (done on day 8) and visual evoked responses were normal.

Radiographic Studies

A noncontrast CT scan with 5 mm images of the posterior fossa (GE 8800 CT/T scanner) done on admission was normal. The following day a nuclear magnetic resonance (NMR) scan was done using a .35 Telsa cryogenic magnet (Diasonics MT/S imager) and spin-echo imaging technique.^{2,3} Using parameters of TE 2 sec, TR 28 and 56 msec, high signal intensity was seen from both medial thalami (fig. 1). There was no apparent abnormality in the midbrain although the 5 mm slices did not visualize the rostralmost area (red nucleus). In addition to the thalamic lesions, high intensity was seen from a 5 × 5 mm area in the peripheral right cerebellar cortex and from a smaller region in the anteromedial right cerebellum adjacent to the fourth ventricle.

Four days later a second noncontrast CT scan revealed low density in the same thalamic areas described above, which became isodense after contrast.

At eight days contrast CT showed ring-like enhancement of the thalamic lesions (fig. 1). Using the fornices, third ventricle, trigone, pineal body and basis

pedunculi as landmarks, the lesions were seen to involve the central nuclei bilaterally and the inferior and anterior portions of the median nuclei bilaterally, with extension into the ventrolateral formation on the left (classification of thalamic nuclei as by Van Buren and Borke).⁴ Both lesions in the right cerebellum also enhanced. Ventricular size was unchanged.

Vertebrobasilar angiography was performed on day 6. The left vertebral artery was small and could not be cannulated; the other posterior fossa vessels were considered uniformly narrow but not definitely abnormal. Following angiography heparin was discontinued and the patient was discharged on aspirin, 325 mg qd.

Four months later a contrast CT scan was performed with sagittal and coronal reconstructions (fig. 2). Standard axial views showed a widened third ventricle with nonenhancing lucencies in medial thalami bilaterally. Reconstructions placed the lesions primarily in the regions of the central and median nuclei, as observed in the earlier studies.

Discussion

This case illustrates a stroke syndrome with interesting clinico-anatomic implications with respect to eye movement and memory, and which can be difficult to diagnose at presentation. In our patient consideration was given to posterior fossa subdural hematoma, acute disseminated encephalomyelitis, brainstem or cerebellar hemorrhage, and ischemic stroke. The NMR scan was useful in the early diagnosis of ischemic vascular disease, at a time when the CT scan was unrevealing.

During the period of hospitalization the diagnosis of bithalamic stroke was confirmed. The patient's clinical course was that of infarction, with improvement over days and near complete recovery over weeks. CT studies documented the evolution of low density regions followed by contrast enhancement characteristic of infarction.⁵ Prolonged T2 relaxation on NMR imaging is also indicative of early infarct, signifying increased brain water.^{2,5,6} NMR has been shown to detect infarction within two hours of ischemia.⁷

The additional lesions seen in the cerebellum, combined with the history of diplopia and nausea as early symptoms, suggested an initial basilar artery occlusion which later fragmented and gave rise to distal emboli. At age 27, our patient's only apparent risk factor for stroke was mitral valve prolapse.

The clinical presentation and CT findings in our patient are similar to other cases recently published.^{1,8-13} These reports share radiographic evidence of bilateral medial thalamic infarction and a clinical picture of initial somnolence, Korsakoffian memory deficit, and vertical gaze palsy. The vascular supply to this region has been well described, consisting of perforating vessels originating from the arterial segment between the bifurcation of the basilar artery and the junction of the posterior communicating arteries.^{14,15} This segment has been designated the “mesencephalic artery” or, more recently, the “basilar communicating artery.”¹⁴ The perforating vessels, termed “thalamic paramedian arteries” by Percheron,¹⁵ can arise from

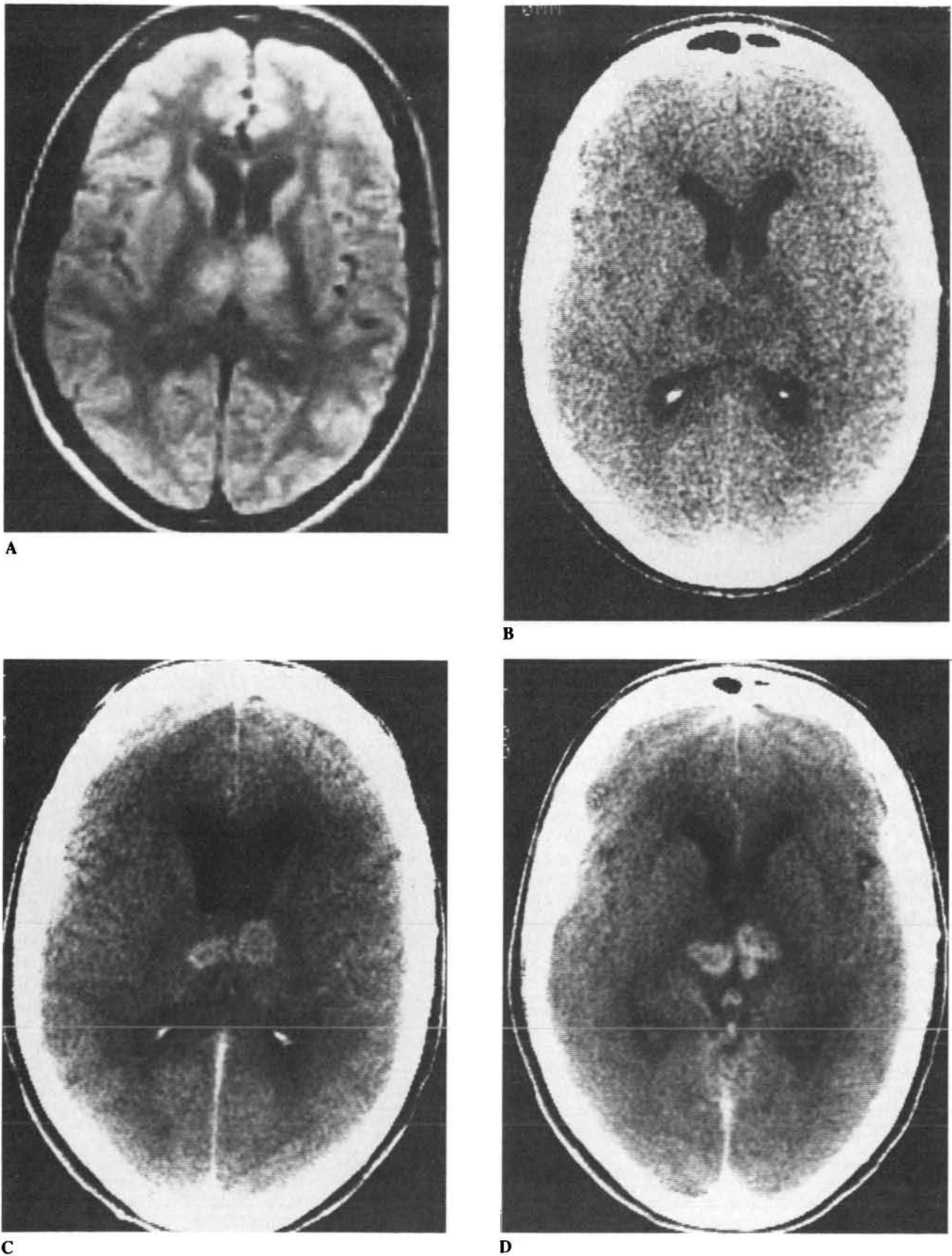


FIGURE 1. (A) NMR scan 24 hours after ictus revealing increased signal intensity from both medial thalami. TR 2.0 sec, TE 28 msec. (B) Noncontrast CT scan at 4 days. Subtle medial thalamic lucencies are now apparent. After contrast these became isodense with normal thalamus (not shown). (C) and (D) Contrast CT scan at 8 days.

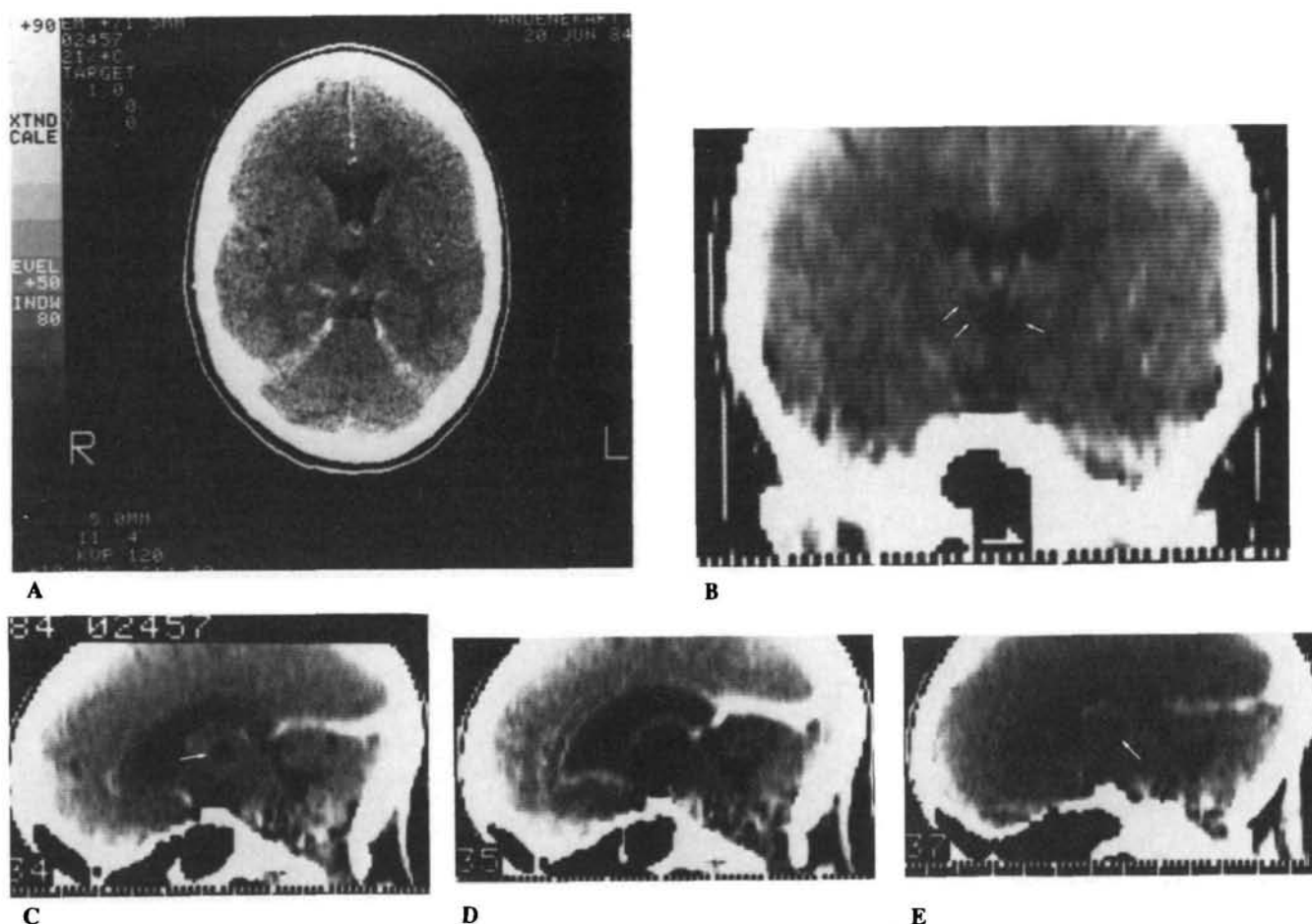


FIGURE 2. Contrast CT at 4 months. (A) Axial view showing widened third ventricle and bilateral thalamic lucencies. (B) Coronal reconstruction. (C) Sagittal reconstruction 1cm right of midline, (D) approximately at midline, and (E) 2cm left of midline. (Arrows indicate areas of infarction.)

this segment in several ways. Frequently both arise from a single common stem originating from one or the other basilar communicating artery such that occlusion of this stem can result in bilateral infarctions.

The territory supplied generally begins immediately superior to the red nucleus and extends superiorly and anteriorly into the thalamus to include the nuclei parafascicularis, mamillothalamic tracts, central nuclei, and the inferior portion of the median (dorsomedial) nuclei. In cases with pathologic confirmation, areas of infarct match the described vascular distribution.^{11, 16-19} Such lesions affect structures believed necessary for normal vertical eye movements as well as for memory function.

The terms "vertical gaze palsy," or "paralysis," are used by Buttner-Ennever and others²⁰ to describe an inability to voluntarily produce fast conjugate vertical eye movement. Mills and Swanson¹ employ the term "vertical gaze apraxia" to emphasize preservation of vertical eye movements with oculocephalic reflex or Bell's maneuver. Christoff,²¹ however, in a clinico-pathologic study, notes that there is not a consistent relationship between site or size of lesions and preservation of reflex vertical eye movements. Vertical gaze palsy has resulted from bilateral lesions of the rostral interstitial nucleus of the media longitudinal fasciculus

(dorsomedial to the anterior pole of the red nucleus) or unilateral lesions of the posterior commissure.^{11, 20, 22, 23} The vascular supply to these areas is derived from the same vessels as those supplying the medial thalamus, i.e., the thalamic paramedian arteries.¹⁵

Victor et al²⁴ has defined the amnesic syndrome (Korsakoff's psychosis) as (1) impaired ability to retrieve information acquired before the onset of the illness, invariably coupled with an inability to learn (i.e., to form new memories); (2) a relatively minor impairment of perceptual and conceptual functions; and (3) a diminution of initiative and spontaneity. Confabulation is a common but inconstant and often transient feature. The memory and affective disorder seen in the present case is well characterized by this description.

Pathologic study of patients with amnesic syndrome associated with alcohol abuse revealed invariable and extensive involvement of the median (dorsomedial) thalamic nuclei and suggested this as the lesion responsible for memory loss.²⁴ Other evidence points to a role for the hippocampus, mammillary bodies, and/or temporal stem and their connections to the thalamus.²⁵ In the present case the median thalamic nuclei appear less severely affected than the central nuclei and the mamillothalamic tracts. In clinically

similar cases this distribution of infarction has been confirmed pathologically.^{11, 16-19} Of note is that these lesions interrupt input to the median nuclei from limbic structures, perhaps resulting in a functional deficit of the median nuclei similar to that produced by destruction of the median nuclei per se.¹²

The occurrence of amnesia as a result of bithalamic stroke in this syndrome raises the possibility that transient memory loss may result from transient ischemia in this region. Transient global amnesia (TGA) is a well recognized clinical entity of unknown etiology; both seizure and bitemporal ischemia have been suggested.^{26, 27} Bithalamic stroke usually presents as amnesic syndrome plus vertical gaze palsy and an initial period of somnolence — the latter two features not generally associated with TGA. However, three cases of TGA with concomitant vertical gaze palsy have been reported.²⁸ Variations in the stroke syndrome are also seen; in some cases vertical gaze palsy is absent or subclinical^{12, 13} and in one case amnesic syndrome was the sole abnormality at onset.⁸ CT abnormalities in these patients appear to spare the inferior thalamic and subthalamic regions. These clinical variations presumably reflect the variable vascular anatomy of the region. Thus transient occlusion or near-occlusion of the paramedian thalamic arteries at a common stem might, on occasion, produce transient global amnesia.

Although concurrence of the amnesic syndrome and vertical gaze palsy is an unusual and almost pathognomonic entity, its recognition may be difficult when somnolence or coma dominate the clinical picture acutely. In the present case early diagnosis was facilitated by NMR scanning, and CT later localized bithalamic infarction with sufficient resolution to permit correlation of the clinical findings to the recently detailed vascular and neuro-anatomy of this region. In conjunction with reports of similar cases, commonality with transient global amnesia is apparent, and a possible etiology for that syndrome is suggested.

Acknowledgments

The authors thank Dr. Kenneth Nudleman, University of California Irvine, for follow-up data, and Dr. Jack DeGroot, of the Departments of Anatomy and Radiology, UCSF, and Drs. Robert O. Messing and Faith Allen of the Department of Neurology, UCSF, for their assistance.

References

- Mills RP, Swanson PD: Vertical oculomotor apraxia and memory loss. *Ann Neurol* **4**: 149-153, 1978
- Brant-Zawadzki M, Bartkowski HM, Pitts LH et al: NMR imaging of experimental and clinical cerebral edema. *Noninvasive Medical Imaging* **1**: 43-47, 1984
- Cooks LE, Mills CM, David PL et al: Visualization of cerebral and vascular abnormalities by NMR imaging. The effects of imaging parameters on contrast. *Radiology* **144**: 843-852, 1982
- Van Buren JM, Borke RC: Variations and connections of the human thalamus. Vol 1, The nuclei and cerebral connections of the human thalamus. Berlin, Springer, 1972
- Pykett IL, Buonanno FS, Brady TJ, Kistler JP: True three-dimensional nuclear magnetic resonance neuro-imaging in ischemic stroke: correlation of NMR, X-ray CT and pathology. *Stroke* **14**: 173-177, 1982
- Schmidley JW, Brito A, Chan PH, Fishman RA, Crooks L: Using nuclear magnetic resonance (NMR) imaging to study changes in brain water. *Neurology (suppl 2)*: 151, 1983
- Buonanno FS, Pykett IL, Brady RJ et al: Proton NMR imaging in experimental ischemic infarction. *Stroke* **14**: 178-184, 1983
- Barbizet J, Degos JD, Louam F, Nguyen JP, Mas JL: Amnesie par lesion ischémique bi-thalamique. *Rev Neurol (Paris)* **137**: 415-424, 1981
- Guberman A, Stuss D: The syndrome of bilateral paramedian thalamic infarction. *Neurology (Cleveland)* **33**: 430-446, 1983
- Petit H, Rousseaux M, Clarisse J, Delafosse A: Troubles oculocéphalomoteurs et infarctus thalamo-sous-thalamique bilatéral. *Rev Neurol* **137**: 709-722, 1981
- Pierrot-Deseilligny CH, Chain F, Gray F, Serdaru M, Escourolle R, Lhermitte F: Parinaud's syndrome. Electro-oculographic and anatomical analyses of six vascular cases with deductions about vertical gaze organization in the premotor structures. *Brain* **105**: 667-696, 1982
- Schott B, Manguiere F, Laurent B et al: L'amnesie thalamique. *Rev Neurol* **136**: 117-130, 1980
- Von Cramon D, Zihl J: Roving eye movements with bilateral symmetrical lesions of the thalamus. *Neurology* **22**: 105-112, 1979
- Percheron G: The anatomy of the arterial supply of the human thalamus and its use for the interpretation of the thalamic vascular pathology. *Z Neurol* **205**: 1-13, 1973
- Percheron G: Les artères du thalamus humain. II. Artères et territoires thalamiques paramédians de l'artère basilaire communicante. *Rev Neurol* **132**: 309-324, 1976
- Castaigne P, Buge A, Cambier J, Escourolle R, Brunet P, Degos PB: Démence thalamique d'origine vasculaire par ramollissement bilatéral, limitée au territoire du pédicule retro-mamillaire. *Rev Neurol* **114**: 84-107, 1966
- Castaigne P, Buge A, Escourolle R, Masson M: Ramollissement pedonculaire médian, tegmento-thalamique avec ophthalmoplie et hypersomnie. *Rev Neurol* **106**: 357-367, 1962
- Castaigne P, Lhermitte F, Buge A, Escourolle R, Hauw JJ, Lyon-Caen O: Paramedian thalamic and midbrain infarcts: clinical and neuropathological study. *Ann Neurol* **10**: 127-148, 1981
- Segarra JM: Cerebral vascular disease and behavior. I. The syndrome of the mesencephalic artery (basilar artery bifurcation). *Arch Neurol* **22**: 408-418, 1970
- Buttner-Ennever JA, Buttner U, Cohen B, Baumgartner G: Vertical gaze paralysis and the rostral interstitial nucleus of the medial longitudinal fasciculus. *Brain* **105**: 125-149, 1982
- Christoff N: A clinicopathologic study of vertical eye movements. *Arch Neurol* **31**: 1-8, 1974
- Bender MB: Brain control of conjugate horizontal and vertical eye movements: a study of the structural and functional correlates. *Brain* **103**: 23-69, 1980
- Nashold BS, Seaber JH: Defects of ocular motility after stereotactic midbrain lesions in man. *Arch Ophthalmol* **88**: 245-248, 1972
- Victor M, Adams RD, Collins G: The Wernicke-Korsakoff syndrome. (Volume 7 of the Contemporary Neurology Series). Philadelphia, F.A. Davis, 1971
- Horel JA: The neuroanatomy of amnesia. A critique of the hippocampal memory hypothesis. *Brain* **101**: 403-445, 1978
- Fisher CM, Adams RD: Transient global amnesia. *Acta Neurol Scand* **40** (suppl 9): 7-82, 1964
- Shuping JR, Rollinson RD, Toole JF: Transient global amnesia. *Ann Neurol* **7**: 281-285, 1980
- Collard M, Eber AM, Streicher D, Tritschler JL: Syndrome de Parinaud, nystagmus vertical et ictus amnésique. *Oto-Neuro-Ophthalmol* **49**: 47-55, 1977