

Bilateral Occlusions In The Cervical Portion of the Internal Carotid Arteries in a Child

TETSUZO TAGAWA, M.D., TAKASHI MIMAKI, M.D., HYAKUJI YABUUCHI, M.D., YOSHIKAZU IWATA, M.D.,*
AND ATSUFUMI MAKINO, M.D.†

SUMMARY An 8-year-old boy with a history of recurrent tonsillitis and cervical lymphadenopathy developed acute hemiplegia. Cerebral angiography revealed bilateral occlusions of the cervical portion of the internal carotid arteries. Cerebral arterial occlusion in childhood has been attributed to many causes, e.g., trauma and infections of the neck. In the present case, though not clearly proved, inflammatory processes may have been related to the occlusion.

Stroke Vol 16, No 5, 1985

A VARIETY OF PATHOLOGICAL PROCESSES produce acute hemiplegia. Arterial occlusion in adults occurs frequently in the cervical carotid artery, but mostly in the intracranial portion in children. Occlusion of the cervical carotid artery is uncommon in childhood. Bilateral occlusions are very rare. In this report we describe a child with bilateral occlusions of the cervical portion of the internal carotid arteries.

Case Report

An 8-year-old boy was admitted to the Osaka University Hospital on June 8, 1980, with recurrent right hemiplegia, right facial palsy, aphasia. He was born at term and his neonatal course was uneventful. His past medical history was unremarkable except for an episode of fever with lymphadenopathy, suspected of being due to infectious mononucleosis which occurred 4 years prior to admission. He had no history of recent trauma or cardiac diseases.

Beginning in February 1980, he had recurrent tonsillitis and complained of intermittent ophthalmic pain. In March 1980 he was admitted to another hospital and was treated with antibiotics for 20 days for a streptococcal infection. During this hospitalization his neurological evaluation revealed no abnormality except EEG asymmetry and transient anisocoria.

Ten days before admission to our hospital, he abruptly developed right hemiplegia at school. This improved spontaneously within a few hours. One week later, when he was taking a bath, the right hemiplegia reappeared along with right facial palsy and aphasia. Following this episode a right unilateral convulsion occurred and continued for about 5 minutes. His clinical symptoms progressed over several days to complete paralysis of his right side.

On admission he was alert and responsive. His pupils were round, equal and reactive to light. Extraocular movements were normal and fundoscopic examination revealed no papilledema or retinal hemorrhage. No nuchal rigidity or enlargement of the cervical

lymph nodes was seen. No bruit was audible in the neck or skull. Radial and femoral pulses were easily palpable and equal in both sides. Blood pressure was 110/70 mmHg in both arms. Cardiac sounds were normal. Neurological examination disclosed a right facial palsy, right hemiplegia with a right Babinski sign, and exaggerated tendon reflexes in the right arm and leg. There was a questionable right hemihypesthesia which was uncertain because of his aphasia.

Numerous laboratory tests were normal including blood cell counts and differentials, platelet counts, coagulation tests, serum immunoelectrophoresis, and CSF. Cardiac examinations including electrocardiogram, echocardiogram and chest films, revealed no abnormal findings. The erythrocyte sedimentation rate was 20 mm/hr and CRP was positive. ASO titer was mildly elevated. EEG showed high voltage slow wave in the left parieto-occipital area. CT scan demonstrated a low density area in the distribution of the left middle cerebral artery, which was markedly enhanced after the contrast infusion, suggesting a cerebral infarction.

Right and left carotid arteriograms demonstrated bilateral internal carotid artery occlusions just above the carotid bifurcation (fig. 1). In addition, the right carotid angiogram demonstrated retrograde filling of the right ophthalmic artery. A vertebral angiogram revealed that both anterior cerebral arteries (ACA) and the right middle cerebral artery (MCA) were filled through the right posterior communicating artery and the left MCA filled retrogradely via the anastomosis of the left posterior cerebral artery (PCA) (fig. 2). These findings suggested the occlusion of the left internal carotid artery extended to the origin of the left MCA.

After the angiographic studies, urokinase was administered for one month. The motor disturbance and aphasia gradually improved. Two months after the onset of the hemiplegia an anastomosis between the left superficial temporal and middle cerebral arteries was performed. The postoperative left carotid angiogram showed excellent filling of the region of the left MCA via the anastomosis (fig. 3). At the time of this report the patient can walk unaided and speak fluently. A mild right hemiparesis remains.

Discussion

Postnatally acquired hemiplegia in a child previously neurologically unimpaired, is not a specific disease

From the Department of Pediatrics, and from the Department of Neurosurgery,* Osaka University Medical School, Osaka, Japan; and the Department of Pediatrics, Kinki Chuo Hospital, Itami, Japan.†

Address correspondence to: Dr. Tetsuzo Tagawa, Osaka University Medical School, 1-1-50 Fukushima, Osaka, Japan.

Received December 19, 1984; revision #1 accepted February 28, 1985.

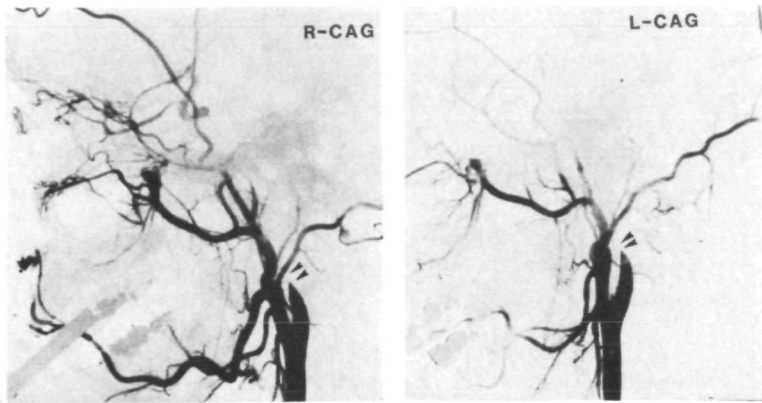


FIGURE 1. Right (R-CAG) and left (L-CAG) carotid angiograms. Both the right and left internal carotid arteries occluded just above the carotid bifurcation. (Double arrow heads)

but rather the nonspecific response of the central nervous system to injury produced by various etiologies.^{1,2} Using modern neuroradiological diagnostic techniques, cerebrovascular diseases have been frequently found in hemiplegic children.³ Cerebral arterial occlusions occur commonly extracranially in adults, while they are principally intracranial in children.⁴⁻⁷ Occlusion in the cervical portion is uncommon in childhood. Bilateral occlusions are very rare. We have been unable to find other reported children with bilateral extracranial occlusions of the carotid arteries. Mymin reported a 2-year-old girl with common carotid occlusions and congenital heart disease.⁸ Autopsy findings revealed coarctation of the aorta, patent ductus arteriosus and bilateral common carotid thrombosis. The author speculated the etiology of the thrombosis might have been aortic dissecting aneurysms. In our case there were no evidence of dissection on the angiogram and no blunt trauma was reported in the days prior to the onset of symptoms. Although mitral valve

prolapse has recently been described as a cause of stroke in childhood,^{9,10} no evidence of the disease were found in this boy.

The risk factors for occlusion of the cervical carotid arteries in children are different from those in adults. In adults the most important factor is atherosclerosis; in children trauma to the neck and infections of the neck or throat are important.⁴ Spontaneous dissection and premature atherosclerosis have been reported but were not apparent in the radiological studies in this patient. Infection in the neck or throat has long been implicated as a cause of carotid occlusion from an arteritis produced by direct extension of the inflammatory process and proximity of the internal carotid system. Our patient had had recurrent tonsillitis with culture proven group A β -hemolytic streptococci, a positive CRP and an elevated titer of ASO. Therefore, in this case, the inflammatory processes may have been related to the occlusions, as previous authors suggested.^{6,11-13}

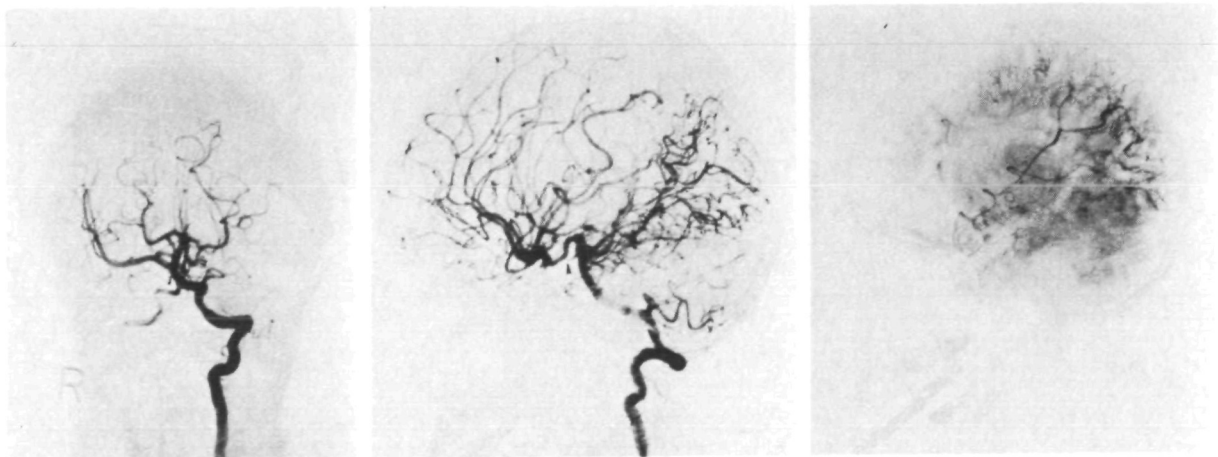


FIGURE 2. The vertebral angiogram. 2a and 2b: arterial phase. 2c: venous phase. The anterior cerebral arteries on both sides and the right middle cerebral artery can be visualized on figure 2a and 2b. Occlusion of the left posterior communicating artery is demonstrated. (Arrow head) In the venous phase (fig. 2c) the left middle cerebral artery is seen to be filled through the peripheral anastomosis via the left posterior cerebral artery.

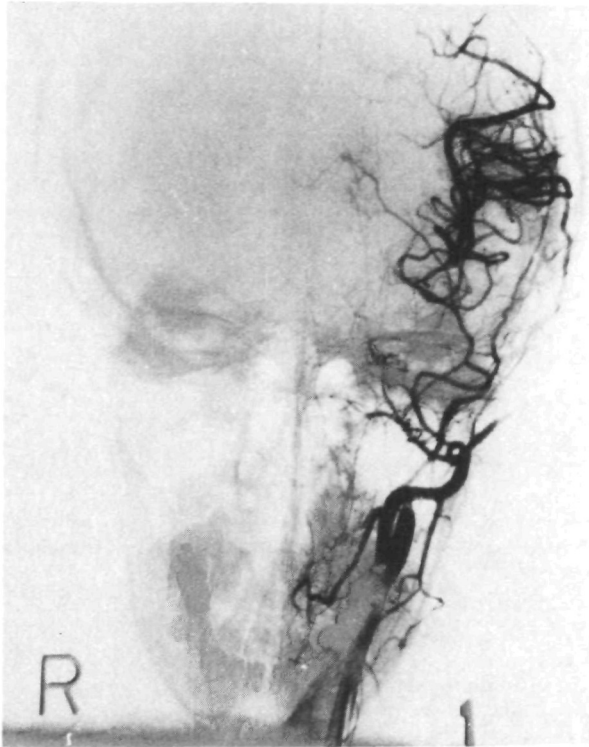


FIGURE 3. The postoperative angiogram of the left carotid artery. The region of the left middle cerebral artery is well filled through the anastomosis by the external carotid artery.

References

1. Carter S, Gold AP: Acute infantile hemiplegia. *Pediatr Clin N Amer* **14**: 851-858, 1967
2. Gold AP, Carter S: Acute hemiplegia of infancy and childhood. *Pediatr Clin N Amer* **23**: 413-433, 1976
3. Scheffner D, Wille L: Acute infantile hemiplegia due to obstruction of intracranial vessels. *Neuropädiatrie* **4**: 7-19, 1973
4. Gold AP, Challenor YB, Gilles FH, et al: Stroke in children (Part 1). *Stroke* **4**: 835-894, 1973
5. Hawood-Nash DC, McDonald P, Argent W: Cerebral arterial diseases in children. An angiographic study of 40 cases. *Am J Roentgenol* **11**: 672-686, 1971
6. Shillito J: Carotid arteritis. A cause of hemiplegia in childhood. *J Neurosurg* **21**: 540-551, 1964
7. Harvey FH, Alvord EC Jr: Juvenile cerebral arteriosclerosis and other cerebral arteriopathies of childhood — six autopsied cases. *Acta Neurol Scandinav* **48**: 479-509, 1972
8. Mymin D: Carotid thrombosis in childhood. *Arch Dis Child* **35**: 515-518, 1960
9. Rice GPA, Boughner DR, Stiller C, Ebers GC: Familial stroke syndrome associated with mitral valve prolapse. *Ann Neurol* **7**: 130-134, 1980
10. Rice GPA, Ebers GC, Bondar RL, Boughner DR: Mitral valve prolapse: a cause of stroke in children? *Develop Med Child Neurol* **23**: 352-368, 1981
11. Bickerstaff ER: Aetiology of acute hemiplegia in childhood. *Brit Med J* **11**: 82-87, 1964
12. Davie JC, Coxe W: Occlusive disease of the carotid artery in children. Carotid thrombectomy with recovery in 2-year-old boy. *Arch Neurol* **17**: 313-323, 1967
13. Hilal SK, Solomon GE, Gold AP, Carter S: Primary cerebral arterial occlusive disease in children. Part 1 Acute acquired hemiplegia. *Radiology* **99**: 71-86, 93-94, 1971