

\* Rosomoff HL, Malinin TI. Freeze-dried allografts of dura mater—20 years' experience. *Transplant Proc* 1976;8:2 suppl 1:133-8.

† Landesman SH, Corrado ML, Shah PM, Armangaud M, Barza M, Cherubin CE. Past and current roles for cephalosporin antibiotics in treatment of meningitis. *Am J Med* 1981;71:693-703.

<sup>10</sup> Rahal JJ, Simberkoff MS. Host defense and antimicrobial therapy in adult Gram-negative bacillary meningitis. *Ann Int Med* 1982;96:468-74.

<sup>11</sup> Sande MA. Antibiotic therapy of bacterial meningitis: Lessons we've learned. *Am J Med* 1981;71:507-10.

<sup>12</sup> Jones RN, Thornsberry C. Cefotaxime: A review of in vitro antimicrobial properties and spectrum of activity. *Rev Inf Dis* 1982;4(S):S300-S315.

Accepted 16 February 1984.

### High-resolution CT scan in pontine ataxic hemiparesis

Sir: In 1978, Fisher demonstrated pathologically that lacunar infarcts of the basis pontis can produce ataxic hemiparesis.<sup>1</sup> Two cases with this syndrome caused by pontine infarcts, confirmed by CT scan, have been reported.<sup>2,3</sup> We report a third case documented by high-resolution CT brain scan.

A hypertensive man, aged 40 yr, was admitted to hospital with sudden onset of weakness of the left limbs and unsteadiness of gait. Examination showed a very slight weakness of the left side of the face and grade 4/5 power in the left upper and lower extremities. The tendon jerks were brisker on the left, and a left Babinski's sign was present. Dysmetria, intention tremor and adiadochokinesis on the left limbs were prominent. There was horizontal nystagmus on both sides on lateral gaze. No other neurological sign was seen. Somatosensory cortical evoked potentials to digital nerve stimulation were normal. The CSF, CT brain scan, echocardiography and vertebral angiography were normal. Examination a month later showed slight spasticity of the left limbs. Power and coordination were normal. A high-resolution CT brain scan demonstrated two small areas of the low density in the right basis pontis, at about the junction of the upper one third and lower two thirds of the pons (figure).

In this patient, the presence of nystagmus and the normal somatosensory cortical responses suggested a lesion in the pons rather than in corona radiata or internal capsula.<sup>2</sup> The first CT brain scan excluded

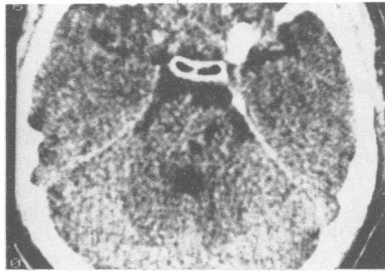


Fig High resolution CT brain scan without contrast. Axial view.

pontine haemorrhage and a supratentorial lesion. The high resolution CT brain scan demonstrated clearly the existence of two small adjacent infarcts in the basis pontis one month later. Our case closely resembles case 1 of Fisher.<sup>1</sup> The vessel most likely occluded is a lateral penetrating artery arising from short circumferential branches of the basilar artery.<sup>1,2</sup> High-resolution CT brain scan allowed accurate clinico-anatomical correlation in this patient and confirmed Fisher's original finding, which indicated that a lesion of the basis pontis at the junction of the upper one third and lower two thirds of pons.<sup>1</sup> Why the ataxia is not bilateral is still unknown.<sup>1,2</sup>

GABRIEL DELGADO,  
JAIME GÁLLEGO,  
JOSÉ LUIS ZUBIETA  
*Servicios de Neurología,  
Hospital de Navarra y Neuroradiología de  
la Clínica Universitaria,  
Pamplona, Spain*

### References

- <sup>1</sup> Fisher CM. Ataxic hemiparesis. A pathologic study. *Arch Neurol* 1978;35:126-8.
- <sup>2</sup> Huang CY, Chang KH. Pontine ataxic hemiparesis, a lateral penetrator syndrome? *J Neurol Neurosurg Psychiatry* 1984;47:1046-7.
- <sup>3</sup> Sakai T, Murukami S, Ito K. Ataxic hemiparesis with trigeminal weakness. *Neurology (NY)* 1981;31:635-6.

Accepted 9 February 1985

### Pseudoankylosis of the mandible following a fronto-temporal craniotomy

Sir: Head injuries with evidence of intracranial haemorrhage, intracranial aneur-

ysms and tumours are the more common indications for a neurosurgical procedure. If the procedure involves sectioning of the temporalis muscle, fibrosis of the muscle give rise to complications during and after healing of the surgical wound. Since the temporalis muscle is one of the principal elevators of the mandible, a restriction of its action can result in pseudoankylosis of the mandible and atrophy of the muscle may also occur. In spite of the large number of neurosurgical procedures undertaken, the incidence of pseudoankylosis is very low.<sup>1-4</sup> A further case, in this instance following fronto-temporal craniotomy, is reported. It is of interest to note that while the previous cases in the literature were treated surgically, this patient was managed conservatively with satisfactory results.

In September, 1983, a 48-year-old white female patient was referred by a neurosurgeon for a maxillofacial surgical opinion regarding limitation in mouth opening which was affecting her mastication. The patient had undergone a right fronto-temporal craniotomy to clip an aneurysm arising from the internal carotid artery on that side in August, 1982. Immediately following this, the patient experienced limitation in opening her mouth which persisted. The past medical history indicated that she had been in good health until she developed the symptoms which led to neurosurgical intervention.

Clinical examination revealed an obvious depression in the region of the craniotomy site. On palpation, there was neither tenderness nor a sensation of stretching of fibres of the temporalis muscle when the patient attempted to open her mouth. She had a near full complement of permanent teeth and an interincisal opening of 10 mm. The mandible deviated slightly to the right side on opening. Palpation of the temporomandibular joint during movement of the mandible suggested that this was not a case of true ankylosis. Radiographic examination showed no bony changes in the joint or the surrounding structures and a diagnosis of pseudoankylosis of the mandible due to temporalis muscle fibrosis was made.

Although coronoidectomy to detach the temporalis muscle from the mandible was considered, it was decided initially to treat the patient by conservative measures. A trismus screw made out of hard acrylic was provided and instructions given to use it gradually to produce progressive opening of the mouth by distraction in the incisor region. Over a six month period, the mouth