

Superior sagittal sinus thrombosis associated with Evans' syndrome of haemolytic anaemia

Z. Shiozawa¹, R. Ueda², T. Mano², R. Tsugane³, and N. Kageyama³

¹Third Department of Internal Medicine, Neurology, Yamanashi Medical University, Yamanashi, 409-38, Japan

²First Department of Internal Medicine and

³Department of Neurosurgery, Nagoya University School of Medicine, Nagoya, 466, Japan

Summary. A case of superior sagittal sinus thrombosis associated with Evans' syndrome of immune haemolytic anaemia is reported. The neurological symptoms and signs were headaches, right quadrant hemianopia, dyslexia without agraphia, motor aphasia, numbness in and weakness of the right upper extremity, papilloedema and coma. The cerebral venous sinus thrombosis, involving cerebral veins, superior sagittal sinus and straight sinus, was diagnosed by cerebral angiography. It is noteworthy that the superior sagittal sinus thrombosis occurred during a haematological recovery period, with rapid responses to treatment with 6-mercaptopurine and high doses of adrenocorticosteroids. Following a reduction in the doses of these drugs, the symptoms and signs related to the superior sagittal sinus thrombosis gradually subsided, and the haematological pictures remained in remission.

Key words: Superior sagittal sinus thrombosis – Cerebral angiography – Evans' syndrome – Immune haemolytic anaemia – Adrenocorticosteroid therapy

Introduction

Cerebral venous sinus thrombosis is generally secondary to disease elsewhere in the body. It appears, therefore, that the problem of the aetiology of cerebral venous sinus thrombosis is similar to that of thrombosis in veins anywhere, because they occur under similar circumstances [13]. Since major dural sinus thrombosis may result in an increase in intracranial pressure (which may be due to factors such as venous congestion, brain oedema, and impaired absorption of cerebrospinal fluid from arachnoid villi), knowledge of the conditions which may give rise to this condition is essential.

We report a case of superior sagittal sinus thrombosis associated with Evans' syndrome of idiopathic autoimmune haemolytic anaemia [10]. As far as we know, the association of superior sagittal sinus thrombosis with haemolytic anaemia is extremely rare [12, 14], and there has been no report describing superior sagittal sinus thrombosis as a complication of the therapeutic use of adrenocorticosteroids and 6-mercaptopurine for idiopathic immune haemolytic anaemia. It should be noted that the superior sagittal sinus thrombosis developed when this patient's haematological condition had already returned to normal following good response to therapy.

Offprint requests to: Z. Shiozawa (address see above)

Case report

A 31-year-old man had been well until February 1977, when he began to complain of anorexia, general malaise and headaches. On 4 April, he was found to have severe anaemia, haematuria and fever, and was admitted to Nagoya University Hospital.

Past history and family history were unremarkable. Physical examination on admission revealed an alert, but weak and pale man with slight cutaneous and scleral icterus. Generalized purpura and petechiae were found. Blood pressure was 120/70 mm Hg. Heart rate was 90/min and regular. There was no cardiomegaly, hepatosplenomegaly or lymphadenopathy, and no pitting oedema was found. The neurological examination gave normal results at this time.

Laboratory examination on admission showed the following: red blood cells (RBCs) $128 \times 10^4/\text{mm}^3$, haemoglobin 4.6 g/dl, haematocrit 0.16 l/l, white blood cells (WBCs) $15,700/\text{mm}^3$, platelets $4.0 \times 10^4/\text{mm}^3$ and reticulocytes 32.2%. The white cell differential counts showed basophils 0.5%, eosinophils 21.5%, myelocytes 3.5%, Stab 16.0%, II 26.0%, III 10.0%, IV 2.5%, lymphocytes 18.5% and monocytes 1.5%. A bone marrow aspirate revealed the following: total nucleated cell counts $380,500/\text{mm}^3$, megakaryocytes $313/\text{mm}^3$ and erythropoietic series 66.8%, granulopoietic series 26.4%, monocytes 0.4% and lymphocytes 3.2%, resulting in a myeloid/erythroid ratio of 1:2.5. RBCs showed marked anisocytosis and poikilocytosis. Red cell osmotic fragility studies revealed initial haemolysis at 0.48% (normal 0.44%–0.42%), complete at 0.36% (normal 0.34%–0.32%). A red cell survival study using DFP³² (di-isopropylfluorophosphate) revealed the red cell half-life to be 7.5 days.

Blood chemistry showed: total bilirubin 3.1 mg/dl with 2.3 mg/dl indirect fraction, total protein 7.2 g/dl, albumin 3.7 g/dl with normal globulin electrophoresis, thymol turbidity test 0.8 units (normal 0–5 units), zinc sulfate test 11.1 units (normal 4–12 units), GOT 30 units, GPT 38 units (normal 9–31 units), LDH 465 units (normal 130–286 units), alkaline phosphatase 6.0 units (normal 3.2–10.5 units), and cholesterol 171 units. The blood urea nitrogen and serum amylase were normal. Erythrocyte sedimentation rate was 154 mm in the first hour. Results of several lupus erythematosus cell tests and rheumatoid factors were negative. The serological tests for syphilis were also negative. The initial Coombs' tests, both direct and indirect, were 3+ positive for IgG, and later the indirect Coombs' tests became negative. Indirect antiglobulin con-

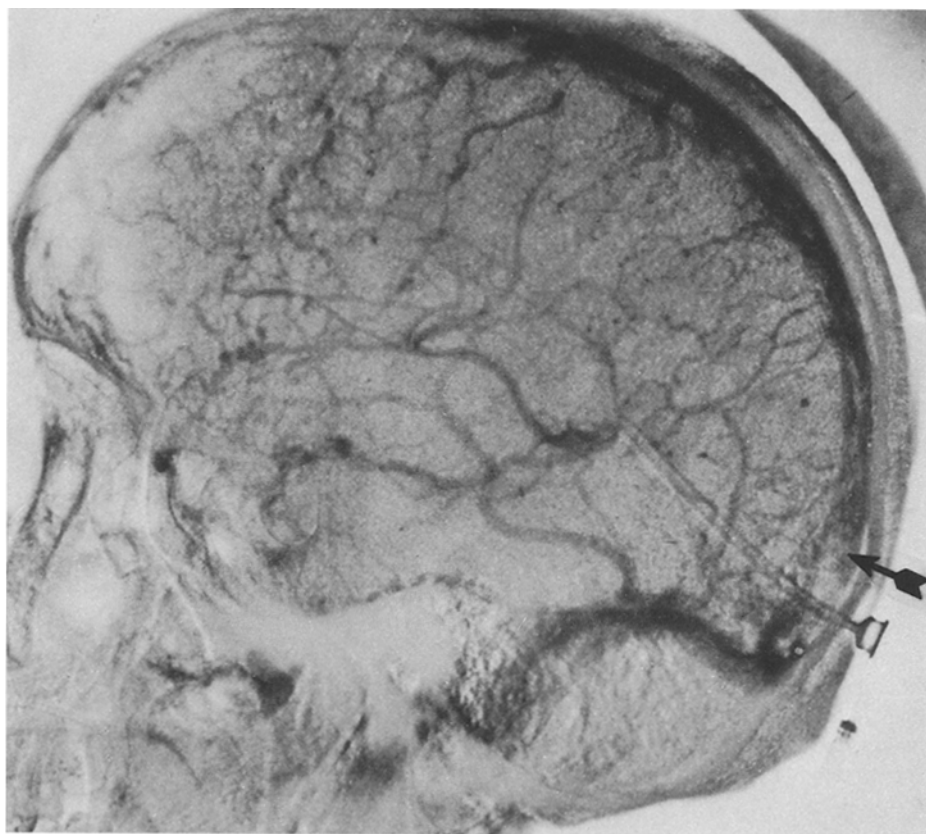


Fig. 1. Left carotid angiogram, venous phase, lateral view. The posterior part of the superior sagittal sinus (*arrow*) and straight sinus are extremely narrow. Dilated, engorged tortuous anastomotic venous channels, diverting the venous blood into superficial sylvian veins and the vein of Labbé. Many occluded superior cortical veins can be seen

sumption tests for thrombocytes [18] were positive. Urinalysis was normal. Consequently, this patient was diagnosed as having an Evans' type of idiopathic autoimmune haemolytic anaemia.

After admission, blood transfusion was given with no improvement of the haematological picture. On 1 May treatment began with administration of folic acid and adrenocorticosteroid hormone preparations. Daily doses of 45 mg dexamethasone and 60 mg 6-mercaptopurine were administered orally for 2 months. During this period the patient's physical condition improved: fever and purpura disappeared, his haematological picture on 21 June showed marked improvement, resulting in RBCs $350 \times 10^4/\text{mm}^3$, haemoglobin 13.0 g/dl, haematocrit 0.38 l/l, WBCs $5400/\text{mm}^3$, platelets $14 \times 10^4/\text{mm}^3$, bleeding time 2 min, clotting time 16 min (Lee-White: normal 5–15 min), prothrombin time 12.7 s (Quick: contrast 12.9 s), thrombotest 63.2% (Owren: normal 46.2%), partial thromboplastin time (PTT) 120 s (normal 40–100 s), anti-thrombin III 40% (normal 70%–130%), and fibrinogen 449 mg/% (normal 200–400 mg/%). In addition, thrombophlebitis was found in the popliteal region of his left leg.

Two weeks after the initiation of 6-mercaptopurine and adrenocorticosteroids, the patient became depressed and thereafter complained of severe headaches. Examination revealed right upper quadrant homonymous hemianopia, and numbness, weakness and hyperactive deep tendon reflexes in his right upper extremity. Papilloedema was observed in both optic fundi on 1 June. When the patient was asked to read Japanese words aloud, he could read correctly words written in Kana (phonic symbols for syllables) but failed to read aloud words in Kanji (Chinese characters which are semantic in nature). Thereafter his headaches increased, followed by

generalized convulsive seizures several times. He lapsed into coma on 21 June.

Lumbar puncture showed clear cerebrospinal fluid but an increased pressure, 330 mm H₂O. A ventriculoperitoneal shunt was inserted on 29 June. The ventriculogram showed normal ventricles, and several petechial haemorrhages were seen through the burrhole, on the surface of the brain. Following this procedure, the patient became alert, but severe motor aphasia, dyslexia, dysgraphia and dyscalculia were revealed. On EEG, these were 4–5 Hz 60 μV theta activities, predominantly over the left hemisphere, and poor alpha activities on the left occipital areas. Bilateral serial cerebral carotid angiography was performed. There were no obvious abnormalities in the arterial phase. However, there were a fair number of small, tortuous, engorged, superficial cortical veins, partly occluded, in the frontoparietal regions, particularly on the left. Anastomotic veins, superficial sylvian veins, basal vein of Rosenthal and vein of Labbé were prominent. Straight sinus and the posterior part of the superior sagittal sinus appeared markedly narrow and slightly opacified even 15 s after the beginning of injection of contrast medium (Fig. 1).

Thereafter, the dose of dexamethasone was gradually decreased and 6-mercaptopurine was discontinued. Headaches, papilloedema, numbness and weakness of the right upper extremity disappeared, but the patient still had dyslexia, dyscalculia and dysphasia. The haematological findings were: WBCs $408 \times 10^4/\text{mm}^3$, haemoglobin 13.6 g/dl, WBCs $5600/\text{mm}^3$ and platelets $15.1 \times 10^4/\text{mm}^3$. The patient was discharged on 24 October, continuing medication with small doses of adrenocorticosteroids. The patient still attends the outpatient clinic.

Discussion

Evans and Duane [10] drew attention to the presence of idiopathic autoimmune haemolytic anaemia and thrombocytopenia in 1949. This association is now well recognized and frequently referred to as Evans' syndrome. In our case the specific antibody for immunoglobulins, erythroid hyperplasia and increased megakaryocytosis in the bone marrow aspirate, as well as thrombocytopenia with purpura, were characteristic abnormalities. Thrombotic thrombocytopenic purpura with microangiopathic haemolysis, haemolytic uraemic syndrome and disseminated intravascular coagulation were ruled out.

Many haematological disorders (sickle cell disease [15], leukaemia [3, 4, 5, 8, 19], primary or secondary polycythaemia [4], thrombocytopenia [2], thrombocytosis [11], cryofibrinogenemia [7, 9], chlorosis or iron deficiency anaemia [1, 13, 16], haemolytic anaemia [12] including paroxysmal nocturnal haemoglobinuria [14], and therapeutic use of androgen for hypoplastic anaemia [17]) have been described with superior sagittal sinus thrombosis as a complication.

The first case of the association of superior sagittal sinus thrombosis with haemolytic anaemia was described by Krayenbühl [14] in 1967, but the clinical and laboratory description of the haemolytic anaemia was not recorded. Johnson et al. [12] presented clinical and pathological findings in a patient with paroxysmal nocturnal haemoglobinuria associated with superior sagittal sinus thrombosis, which had a tendency to occur shortly after periods of increased haemolysis.

However, it was noted in our patient that when superior sagittal sinus thrombosis developed, his haematological condition had already returned to normal following good response to the therapy. In particular, the platelet count increased remarkably and bleeding time was also sufficiently near normal to allow us to perform cerebral angiography. Thrombophlebitis of the left leg was observed during the same period as the occurrence of cerebral venous sinus thrombosis. The pathogenesis was obscure in this case. Although there is a possibility that a hypercoagulability of the blood, which can occur with prolonged use of high doses of adrenocorticosteroids [6], facilitated propagation of cortical vein thrombi, leading to a further venous sinus stasis and infarction, a hypercoagulable state seems to occur in the period of recovery from haemolytic anaemia and thrombocytopenia, in some way resulting from the therapeutic acceleration of haematopoiesis. We have reported angiographically proven superior sagittal sinus thrombosis during similar haematological recovery from hypoplastic anaemia due to androgen therapy [17].

Superior sagittal sinus thrombosis should be considered if neurological symptoms and signs develop following correction of anaemia.

Acknowledgement. We thank Dr. Charles B. Stacy for preparing this manuscript.

References

- Andrew (1865) Thrombosis of cerebral sinuses, with apoplexy of optic thalami, consequent on anaemia. *Trans Pathol Soc (Lond)* 16:27-28
- Averback P (1978) Primary cerebral venous thrombosis in young adults: the diverse manifestations of an under recognized disease. *Ann Neurol* 3:81-86
- Ballard JO, Towfighi J, Brennan RW, Saleem S, Eyster ME (1978) Neurologic complications of acute myelomonoblastic leukemia of four years' duration. *Neurology (Minneapolis)* 28:174-178
- Barnett HJM, Hyland HH (1953) Non-infective intracranial venous thrombosis. *Brain* 76:36-49
- Byers RK, Hass GM (1933) Thrombosis of the dural venous sinuses in infancy and in childhood. *Am J Dis Child* 45:1161-1183
- Cosgriff SW (1951) Thromboembolic complications associated with ACTH and cortisone therapy. *JAMA* 147:924-926
- Dagenais GB, Barbeau A, Delorme P (1968) Cryofibrinogenemia and cerebrovascular accident. *Can Med Assoc J* 98:475-478
- David RB, Hadfield MG, Vines FS, Maurer HM (1975) Dural sinus occlusion in leukemia. *Pediatrics* 56:793-796
- Dunsker SB, Torres-Reyes E, Peden JC Jr (1970) Pseudotumor cerebri associated with idiopathic cryofibrinogenemia. Report of a case. *Arch Neurol* 23:120-127
- Evans RS, Duane RT (1949) Acquired hemolytic anemia. I. The relation of erythrocyte antibody production to activity of the disease. II. The significance of thrombocytopenia and leukopenia. *Blood* 4:1196-1213
- Iob I, Scanarini M, Andrioli GC, Pardatscher K (1979) Thrombosis of the superior sagittal sinus associated with idiopathic thrombocytosis. *Surg Neurol* 11:439-441
- Johnson CR, Kaplan SR, Blalock ZR (1970) Cerebral venous thrombosis in paroxysmal nocturnal hemoglobinuria. Marchiafava-Micheli syndrome. *Neurology (Minneapolis)* 20:681-686
- Kalbag RM, Woolf AL (1967) Cerebral venous thrombosis: with special reference to primary aseptic thrombosis. Oxford University Press, London
- Krayenbühl HA (1967) Cerebral venous thrombosis. *Clin Neurosurg* 14:1-24
- Schenk EA (1964) Sickle cell trait and superior longitudinal sinus thrombosis. *Ann Intern Med* 60:465-470
- Schweitzer H (1898) Thrombose bei Chlorose. *Virchows Arch Pathol Anat* 152:337-397
- Shiozawa Z, Yamada H, Mabuchi C, Hotta T, Saito M, Sobue I, Huang YP (1982) Superior sagittal sinus thrombosis associated with androgen therapy for hypoplastic anemia. *Ann Neurol* 12:578-580
- Steffen C (1960) Results obtained with the antiglobulin consumption test and investigations of autoantibody eluates in immunohematology. *J Lab Clin Med* 55:9-28
- Steinherz PG, Miller LP, Ghavimi F, Allen JC, Miller DR (1981) Dural sinus thrombosis in children with acute lymphoblastic leukemia. *JAMA* 246:2837-2839

Received October 30, 1984 / Revised March 4, 1985 / Accepted June 14, 1985