

## Short communications

# Bilateral traumatic extracranial aneurysms of the internal carotid artery with delayed brain infarction

J.-P. Malin<sup>1\*</sup>, H. Becker<sup>2</sup>, and J. Abicht<sup>1</sup>

<sup>1</sup>Neurology Clinic and

<sup>2</sup>Neuroradiology Department, Medizinische Hochschule Hannover, Konstanty-Gutschow-Str. 8, D-3000 Hannover 61, Federal Republic of Germany

**Summary.** A 24-year-old woman with a left-sided cerebral infarction presented with hemiplegia and aphasia. Five months earlier she had had a closed head injury. Angiography revealed bilateral extracranial post-traumatic aneurysms of the internal carotid artery at the atlanto-axial level. There was full recovery without operative treatment within a week.

**Key words:** Head injury, closed – Carotid artery, internal – Aneurysm, bilateral extracranial – Cerebral infarction

Injuries to the internal carotid artery following head trauma are well known. Traumatic thrombosis of the internal carotid artery, arteriovenous fistulas of the cavernous sinus, and traumatic aneurysms of the intracranial arteries have been reported as a complication of head injury [2, 3]. Aneurysms of the cervical segments of the carotid arteries resulting from non-penetrating injuries are, however, quite rare. Schmidt [7] reported six cases of unilateral extracranial aneurysms. Further cases have been reported by several authors [4–6, 9]. Fleisher et al. [2] summarized 41 cases of intracerebral traumatic aneurysms, collected from the world literature. However, we could not find a case report of a bilateral traumatic extracranial aneurysm of the internal carotid artery at the atlanto-axial level, secondary to closed head injury. We describe, therefore, a 24-year-old woman who was examined because of cerebral infarction in the left hemisphere in the territory of the middle cerebral artery.

### Case report

A 24-year-old woman had an accident on 20 March 1984. During a climbing tour in Spain she fell from a rock, from a height of about 8 m. Immediately after the fall she was unconscious; 2–3 h later she was observed to be in a semi-comatose state, unable to give any information about the accident. On admission to hospital the following injuries were noted: fracture of the left floor of the orbit and left zygoma, pelvic fracture with involvement of the hip, fracture of the right radius, splenic rupture, kidney trauma and pulmonary

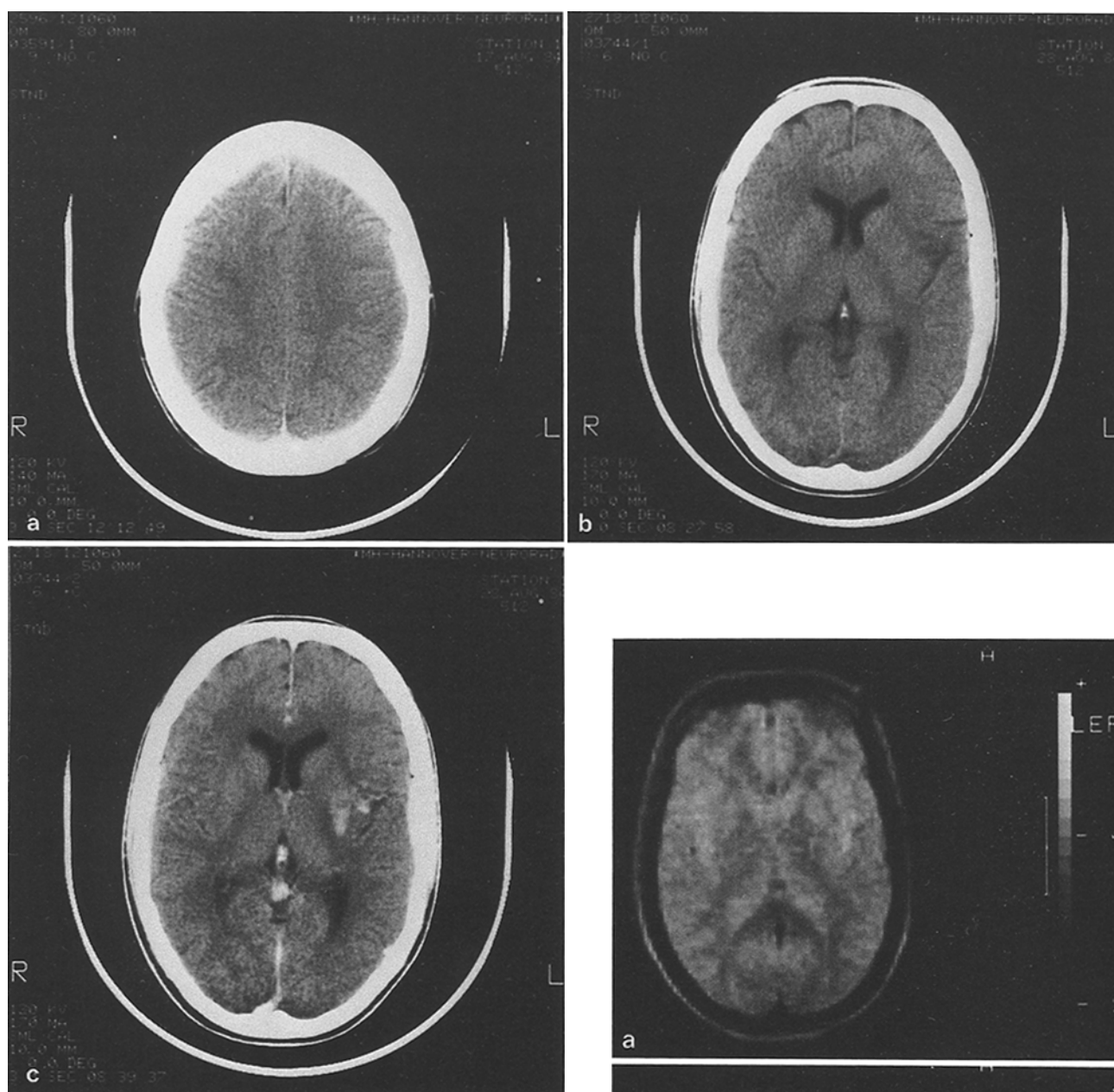
contusion. The patient was discharged in April 1984. During the hospital stay no neurological disturbances were noted. She became conscious and alert within a few days after the accident. After discharge, she continued studying veterinary medicine and preparing for an examination. On the morning of 17 August 1984 a right-sided hemiplegia and aphasia suddenly occurred.

*Neurological evaluation on 17 August.* The woman was conscious and well orientated. A right-sided hemiplegia with central facial nerve paresis was noted. She had severe aphasia, agraphia and dyslexia. Examination revealed no other abnormalities; in particular, cardiac auscultation and auscultation of the carotid arteries were normal. Blood pressure was 120/80 mm Hg on both sides. Doppler sonography of both internal carotid arteries was normal. The electrocardiogram and echocardiography revealed no abnormalities. Further laboratory investigations, including blood and plasma viscosity, showed no abnormality. There was no diabetes. The patient did not smoke or use oral contraceptives.

*X-ray examination.* Cranial computed tomography (CT) on 17 August, 6 h after onset of hemiplegia, revealed an old encephalomalacia (1 cm in diameter) on the right side, i.e. ipsilateral to the hemiplegia (Fig. 1a). Eleven days later the CT scan showed an infarction of 3 cm in diameter, located in the left insula. In the plain CT the infarct area was hypodense and isodense (“fogging effect”; [1]; Fig. 1b,c). After intravenous injection of contrast medium marked enhancement appeared. A further CT on the 21st day showed the whole infarction area to be hypodense in the plain CT scan with marked enhancement following contrast medium injection. Magnetic resonance (MR) examination revealed an extensive area of increased signal intensity in the left insula and a smaller area in the right parietal lobe (Fig. 2a, b). The examination was done by spin-echo and inversion recovery technique. Left carotid angiography revealed an aneurysm 1 cm in diameter at the atlanto-axial level. The lumen of the internal carotid artery was narrowed near to the aneurysm. Occlusion of vessels in the region of the insula was not shown. Right carotid angiography revealed a nearly identical aneurysm of the right internal carotid artery (Fig. 3a, b).

The patient recovered very quickly: hemiplegia and aphasia disappeared within the 1st week after onset. On 13 September

\* Corresponding author

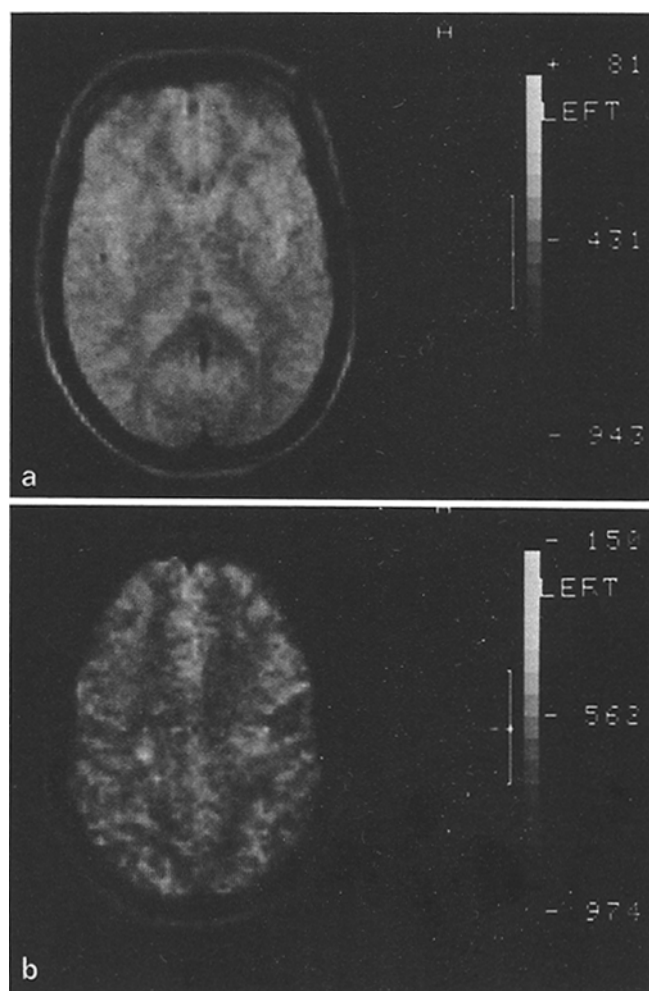


**Fig. 1.** **a** CT scan: small old infarction in the right parietal lobe. **b** CT: unenhanced scan shows a small hypodense infarcted area only in the left insula 11 days after the acute onset. **c** CT: after injection of contrast medium the whole area of infarction is visible

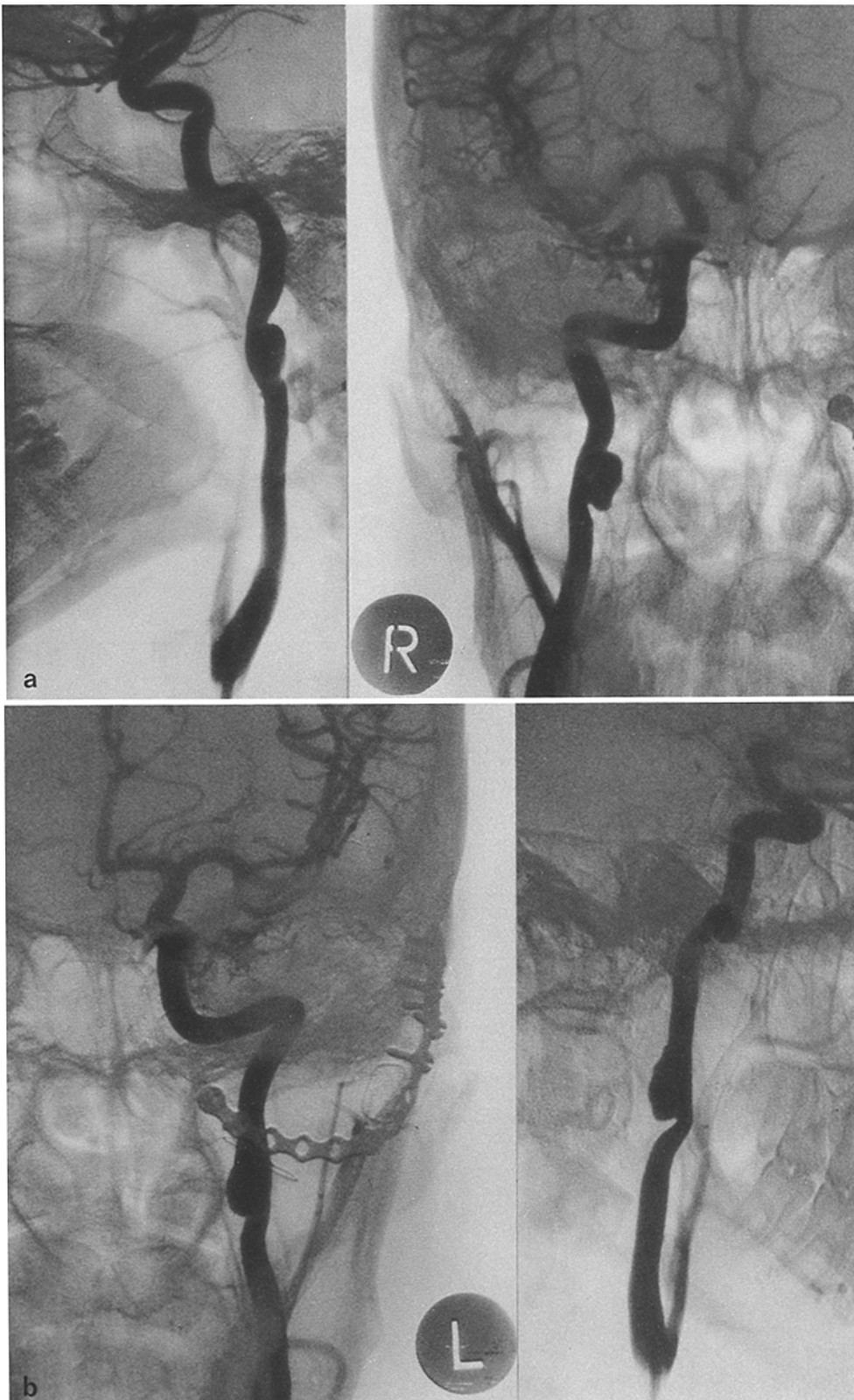
in the tests for aphasia (Aachen Aphasia Test) no disturbances could be detected. The patient left hospital to take an examination at the university and passed. Treatment was restricted to physiotherapy in the acute phase, together with speech therapy. Operation was refused. At a follow-up examination in December 1984 the patient was completely normal.

### Discussion

Aneurysms of the internal carotid artery secondary to non-penetrating head injuries are typically located at the atlanto-axial level [4, 7, 8], near the base of the skull. Such extra-



**Fig. 2.** **a** MR (SE,  $T_R$  1600,  $T_E$  68): increased signal intensity in the left insula, for comparison with Fig. 1b and c. **b** MR (SE,  $T_R$  1600,  $T_E$  68): small area of increased signal intensity in the right parietal lobe, for comparison with Fig. 1a.



**Fig. 3. a** Right carotid angiography: aneurysm of the internal carotid artery at the atlanto-axial level. **b** Left carotid angiography: nearly identical aneurysm at the same level

cranial aneurysms are not common. In the literature we were not able to find a case of bilateral extracranial aneurysm. The mechanism of development is the same as in unilateral aneurysms. We assume that an acute, severe “hyperextension”

of the carotid artery occurred at the atlanto-axial level. Here, the transverse process of the first cervical vertebra acted as a hypomochlion [6, 8]. Fractures of the upper part of the cervical spine are not uncommon in such cases [4, 5]. The primary

vascular lesion is a tear in the vessel wall, leading to occlusion of the vessel lumen or to an aneurysm [8, 9]. The clinical symptomatology of traumatic aneurysms of the cervical internal carotid artery varies. Traumatic aneurysms can develop without clinical symptoms. However, neurological disturbances, such as hemiplegia, hemiparesis and aphasia, may be the initial symptoms [5]. Following neck trauma, aneurysms commonly present as a mass in the neck. In such cases dysphagia, dyspnoea, vertigo or tinnitus occur. The symptom-free interval between trauma and onset of neurological disturbances is very variable, intervals between a few weeks and 2 years being recorded. In our case the interval between trauma and cerebral infarction was 5 months. The right-sided parietal infarction [Fig. 1 a) obviously occurred asymptotically.

Repeated angiographic examinations have demonstrated an increase in size of the aneurysm in addition to spontaneous thrombosis [7]. Undoubtedly, such an aneurysm is a considerable risk for the (commonly young) patient. Only exceptionally is cerebral angiography with visualization of the cervical vessels performed in the early stage of a closed head injury. Therefore, if there has been appropriate trauma (e.g. fractures of the upper cervical spine), the possibility of an extracranial aneurysm should be considered. In patients with cerebral infarction without clear risk, but with an appropriate history of trauma in the past, late infarction from post-traumatic extracranial aneurysm should be considered in differential diagnosis.

Therapy may initially be surgical and eventually a by-pass operation may be necessary. With an aneurysm on both sides

the difficulties involved in operating are considerable, and the decision regarding operative treatment is problematic.

## References

1. Becker H, Desch H, Hacker H, Pencz A (1979) CT fogging effect with ischemic cerebral infarcts. *Neuroradiology* 18:185-192
2. Fleisher AS, Patton JM, Tindall GT (1975) Cerebral aneurysms of traumatic origin. *Surg Neurol* 4:233-239
3. Huber P (1977) Angiographie beim Schädel-Hirntrauma. *Aktuel Neurol* 4:41-60
4. Lai MD, Hoffman HB, Adamkiewicz JJ (1966) Dissecting aneurysm of internal carotid artery after non-penetrating neck injury. *Acta Radiol [Diagn] (Stockh)* 5:290-295
5. Margolis MT, Stein RL, Newton TH (1972) Extracranial aneurysms of the internal carotid artery. *Neuroradiology* 4:78-89
6. New PF, Momose KJ (1969) Traumatic dissection of the internal carotid artery at the atlanto-axial level, secondary to non-penetrating injury. *Radiology* 93:41-49
7. Schmidt RC (1978) Extrakranielle Aneurysmen der A. carotis interna bei stumpfen Schädelhirntraumen. *Neurochirurgia* 21:139-145
8. Simon RS, Schramm J, Bradac GB (1976) Carotis-Läsion bei stumpfem Halstrauma. *Aktuel Neurol* 3:191-196
9. Teal JS, Bergeron RT, Rumbaugh CL, Segall HD (1972) Aneurysms of the cervical portion of the internal carotid artery associated with non-penetrating neck trauma. *Radiology* 105:353-358

Received March 8, 1985/Accepted May 13, 1985