

to his cardiac disease or his weak respiratory musculature. At 28 months he developed congestive heart failure that was controlled with medication. In fact, he was asymptomatic of heart failure at the time of admission for cardiac catheterization.

Central core and multicore disease have some striking similarities in their pathologic lesions⁸ and this could suggest related pathogenetic mechanisms resulting in these two diseases. Central core disease has been associated with malignant hyperthermia syndrome during anesthesia.¹⁴⁻¹⁷ Problems with anesthesia have not previously been described in any patients with multicore disease.

Our patient had a high, unexplained fever, acidosis, and tachycardia after receiving lidocaine and ketamine, agents previously associated with malignant hyperthermia.^{18,19} Hyperthermia could have been precipitated by medication or the stress of cardiac catheterization.^{18,20} Our patient did not have muscle rigidity, elevated creatine kinase levels, or myoglobinuria, as would have been expected for malignant hyperthermia. However, nonrigid forms of the syndrome have been described.²¹ Laboratory tests cannot identify all patients with this condition.²² Although the cause of death could have been an allergic reaction to the contrast media,²³ or

from sepsis, the clinical and autopsy findings do not support these diagnoses and the cause of death is more likely related to anesthesia.

We would like to acknowledge Barbara Pepper and Lou Grubbs for their technical assistance, and John Whitaker, MD, for reviewing the manuscript.

References

- Engel AG, Gomez MR, Groover RV: Multicore disease: A recently recognized congenital myopathy with multifocal degeneration of muscle fibers. *Mayo Clin Proc* 1971;46:666-681.
- Mukoyama M, Matsuoka Y, Kato H, et al: Multicore disease. *Rinsho Shinkeigaku* 1973;13:221-227.
- Tanimura R, Suzuki H, Yokota J, et al: Multicore myopathy: A case of congenital non-progressive myopathy with 'multicore' changes of muscle fibers. *Rinsho Shinkeigaku* 1974;14:613-622.
- Currie S, Noronha M, Harriman D: 'Multicore disease,' in Bradley WG (ed): *III. International Congress on Muscle Disease* (International Congress Series, No. 334). Amsterdam, Excerpta Medica, 1974, p 12.
- Heffner R, Cohen M, Duffner P, et al: Multicore disease in twins. *J Neurol Neurosurg Psychiatry* 1976;39:602-606.
- DeLumley L, Vallat JM, Catanzano G: Etude clinique et ultrastructure d'un cas myopathie congenitale a foyers multiples. *Ann Pediatr* 1976;23:333-336.
- Taratuto AL, Sfaello ZM, Rezzonico C, et al: Multicore disease: Report of a case with lack of fibre type differentiation. *Neuropediatrics* 1978;9:285-297.
- Dubowitz V: Muscle disorders in childhood, in *The Congenital Myopathies*. Philadelphia, WB Saunders Co, 1978, vol 16: *Muscle Disorders in Children*, pp 73-77.
- Ricoy JR, Cabello A, Goizueta G: Myopathy with multiple minicores: Report of two siblings. *J Neurol Sci* 1980;48:81-92.
- Isaacs H, Badenhorst M: Multicore disease. *S Afr Med J* 1980;57:543-546.
- Bonnette H, Roelofs R, Olson WH: Multicore disease: Report of a case with onset in middle age. *Neurology* 1974;24:1039-1044.
- Brooke MH, Engle WK: The histographic analysis of human muscle biopsies with regard to fiber types: I. Adult male and female. *Neurology* 1969;19:221-233.
- Brooke MH, Engle WK: The histographic analysis of human muscle biopsies with regard to fiber types: IV. Children's biopsies. *Neurology* 1969;19:591-605.
- Eng GD, Epstein BS, Engel WK, et al: Malignant hyperthermia and central core disease in a child with dislocating hips. *Arch Neurol* 1978;35:189-197.
- Denborough MA, Dennett X, Anderson RMCD: Central core disease and malignant hyperpyrexia. *Br Med J* 1973;1:272-273.
- Harati Y, Butler FI, Scott CI, et al: Central core disease and malignant hyperthermia syndrome. *Neurology* 1978;28:405.
- Frank JP, Harati Y, Butler IJ: Central core disease and malignant hyperthermia syndrome. *Ann Neurol* 1980;7:11-17.
- Stehling LC: Anesthesia update #6. *Orthop Rev* 1980;9:33.
- Roervik S, Stovner J: Ketamine induced acidosis, fever, and creatine kinase rise. *Lancet* 1974;2:1384.
- Wingard DW: Malignant hyperthermia: A human stress syndrome. *Lancet* 1974;2:1450-1451.
- Britt BA, Kalow W: Malignant hyperthermia: A statistical review. *Can Anesth Soc J* 1970;17:293-315.
- Roland LP: Malignant hyperpyrexia: A reply. *Muscle Nerve* 1980;3:443-444.
- Lalli AF: Contrast media reactions: Data analysis and hypothesis. *Radiology* 1980;134:1-12.

Blepharospasm With Bilateral Basal Ganglia Infarction

James R. Keane, MD, James A. Young, MD

● Severe, involuntary, forceful closure of both eyelids, along with dystonia and rigidity, followed hypoxic encephalopathy in a young man whose computed tomographic scan showed symmetric infarcts of the corpus striatum. Symptomatic blepharospasm can result from bilateral damage to the basal ganglia.

(*Arch Neurol* 1985;42:1206-1208)

Accepted for publication Aug 4, 1984.
From the Department of Neurology, Los Angeles County-University of Southern California Medical Center, Los Angeles.
Read in part before the Federation of Western Societies of Neurological Science Meeting, Napa, Calif, Feb 25, 1984.
Reprint requests to 1200 N State St, Los Angeles, CA 90033 (Dr Keane).

Essential blepharospasm^{1,2} is considered to be a focal dystonia of organic origin by most neurologists.^{2,3} Some experienced students of this condition, however, maintain a belief in a predominantly psychogenic cause.⁴ Even staunch members of the organic camp acknowledge that, on occasion, blepharospasm can be mimicked by psychogenic blinking.⁵ Features of blepharospasm and other proposed focal dystonias that might suggest a psychiatric cause include the following: (1) the movements can be duplicated voluntarily, (2) they follow an unpredictable course with worsening under stress or observation, (3) they are not associated with structural lesions on computed tomographic

(CT) scanning or at autopsy, (4) their onset may appear to be precipitated by an emotional crisis, and (5) the symptoms often are ameliorated by certain "trick" maneuvers that the patient has discovered.

The case for an organic cause of a focal dystonia, such as essential blepharospasm, is based chiefly on the occasional appearance of identical symptoms with idiopathic parkinsonism,⁶ postencephalitic parkinsonism,^{7,8} and other basal ganglia diseases,⁹ as well as their association with antipsychotic drug therapy and as a side effect of levodopa therapy. Spontaneous blepharospasm following focal central nervous system lesions is decidedly rare, but a series of six such

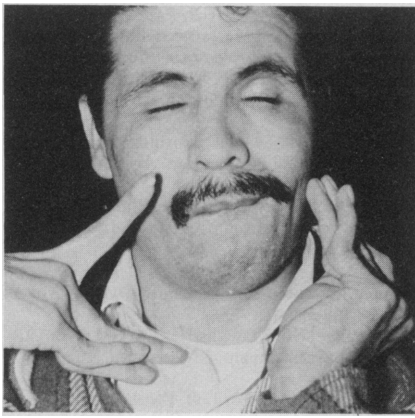


Fig 1.—Patient opens blepharospastic eyelids with dystonic fingers.

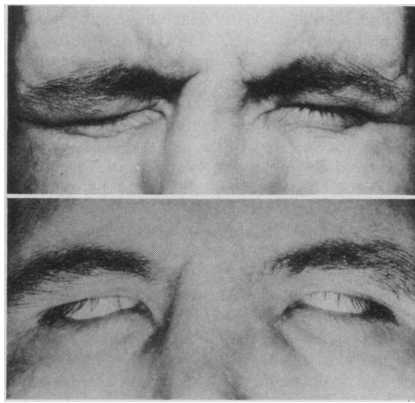


Fig 3.—Blepharospasm (top) is relieved following serial orbicularis denervations (bottom) but upward eye deviation associated with Bell's phenomenon persists (bottom).

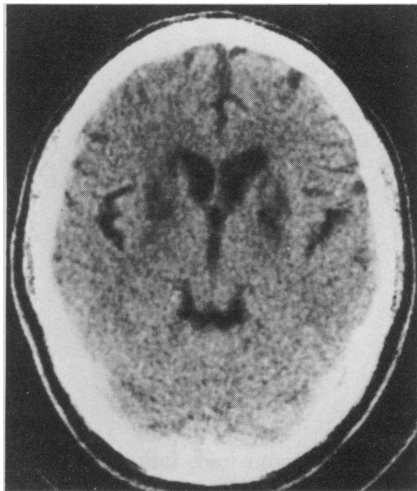


Fig 2.—Computed tomographic scan shows symmetric low-density lesions involving the caudate nucleus, putamen, and globus pallidus.

patients has been reported recently in association with rostral brain-stem damage.¹⁰

The following patient, who developed severe blepharospasm in association with bilateral basal ganglia damage, lends further support to an extrapyramidal cause of essential blepharospasm.

REPORT OF A CASE

A 31-year-old man arrived at a local hospital apneic and pulseless following an intravenous self-injection of rat poison, containing warfarin sodium, taken on a dare.

Following successful resuscitation, he remained comatose with minimally reacting pupils and a temperature of 41 °C. His CT scan was normal and an electroencephalogram showed diffuse slowing.

After three days, he began to respond purposefully. When discharged six weeks after admission, he was weak and required assistance to eat or dress.

His strength and coordination slowly

improved, but six months after discharge, he developed progressive basal ganglia symptoms including blepharospasm.

He was first seen in neurologic consultation at our hospital 16 months after cardiac arrest because forceful bilateral eyelid squeezing had rendered him functionally blind, and he was unable to continue his program of physical therapy.

Examination showed an alert individual able to comprehend and follow complex commands and to perform simple memory and arithmetical tests. His voice was slow, monotonous, and poorly articulated. Moderate bradykinesia and severe truncal and extremity rigidity were present, and he walked stooped over with small steps and a tendency to festinate. Both hands were distorted by severe dystonic posturing (Fig 1). No definite weakness, sensory loss, or cerebellar imbalance could be demonstrated.

His eyelids were in a state of almost constant closure. At times he was able to extend his neck and peer out through a small aperture on the left, but usually he had to manually elevate the eyelids to see at all (Fig 1). Any attempts by others to manipulate his eyelids increased the intensity of blepharospasm; when the contractions were severe, his lower facial muscles participated to a slight extent. The mouth, tongue, and neck were not involved with involuntary movements. The CT scan now showed symmetric low-density infarctions of the corpus striatum superimposed on mild diffuse cerebral atrophy (Fig 2).

Nearly a year of medical therapy with increasing doses of diazepam (to 30 mg/day), trihexyphenidyl hydrochloride (to 18 mg/day), and clonazepam (to 3 mg/day) provided only slight and inconstant relief. He then underwent serial surgical denervation of the facial nerve branches to the orbicularis oculi muscles with successful relief of blepharospasm.

However, six months following surgery, he continued to experience a central epiphenomenon of blepharospasm. During intense "spasms" revealed by fasciculations of his few innervated orbicularis muscle fibers, his eyes rolled up with Bell's

phenomenon, causing transient functional blindness (Fig 3). In addition, relaxation of his eyelids has revealed the presence of an intermittent bilateral horizontal ocular tremor coordinated with contraction of his orbicularis muscles.

Despite these problems, the patient has been satisfied with the results of surgery and is now taking levodopa (Sinemet) with some slight improvement of his parkinsonian symptoms.

COMMENT

Following severe cerebral hypoxia, our patient experienced the delayed onset of severe, continual blepharospasm that sharply reduced his useful vision. Additional basal ganglia signs included parkinsonian postural defects and rigidity, as well as severe dystonic posturing of the hands.

Symmetric basal ganglia infarcts similar to our patient's have been reported with hypoxic encephalopathy principally after carbon monoxide poisoning,¹¹ but also following near-drowning¹² and strangulation.¹³ Selective basal ganglia damage following ischemic-hypoxic insult has been confirmed by neuropathologic examination.¹³ Occasional parkinsonian symptoms associated with hypoxic encephalopathy provide further clinical evidence of sensitivity of the deep gray matter to ischemia.¹⁴

Essential blepharospasm and blepharospasm associated with orofacial dystonia (Meige syndrome),¹⁵ like torsion dystonia, are not associated with structural central nervous system pathology. Postencephalitic parkinsonism and other basal ganglia diseases occasionally associated with blepharospasm^{7,8} generally do not show sufficiently discrete pathologic lesions for clinicopathologic correlation.

However, three of Jankovic and Patel's¹⁰ six patients with symptomatic blepharospasm showed CT evidence of thalamic/upper midbrain infarcts and all displayed symptoms pointing to this general anatomic area. Their patients developed blepharospasm after delays ranging from two days to three years following infarction (four patients) and involvement with multiple sclerosis (two patients).

The present treatment of blepharospasm is empirical and generally unsatisfactory. Many medicines, seemingly without regard to a simple pharmacologic explanation for blepharospasm, provide some relief, for some time, for some patients. No drug provides predictable long-lasting relief. Surgical therapy can alleviate orbicularis spasm either through selective facial nerve denervation or

by directly cutting the muscle. Use of botulinum toxin to weaken the orbicularis muscle is a recently described alternative to surgical myectomy.¹⁶ Our patient failed to respond to medical therapy and underwent bilateral upper facial denervation. Although he, himself, is satisfied with the surgical outcome, "squeezeless" episodes with Bell's phenomenon persist.

This patient, with unusually severe extrapyramidal deficits following cardiac arrest, adds further support to a basal ganglia origin of essential blepharospasm.

References

1. Henderson JW: Essential blepharospasm. *Trans Am Ophthalmol Soc* 1956;54:453-520.
2. Jankovic J, Havins WE, Wilkins RB: Blink-

ing and blepharospasm: Mechanism, diagnosis, and management. *JAMA* 1982;249:3160-3164.

3. Marsden CD: The problem of adult-onset idiopathic torsion dystonia and other isolated dyskinesias in adult life (including blepharospasm, oromandibular dystonia, dystonic writer's cramp, and torticollis, or axial dystonia), in Eldridge R, Fahn S (eds): *Advances in Neurology*. New York, Raven Press, 1976, vol 14, pp 259-276.

4. Trobe JD: Blepharospasm. *Audio-Digest Ophthalmol* 1984;22:5.

5. Lesser RP, Fahn S: Dystonia: A disorder often misdiagnosed as a conversion reaction. *Am J Psychiatry* 1978;135:349-352.

6. Klawans HL, Erlich MA: Observations on the mechanism of parkinsonian blepharospasm and its treatment with L-dopa. *Eur Neurol* 1970;3:365-372.

7. Metz LN, Magee KR: Postencephalitic blepharospasm. *Arch Neurol* 1960;60:692-697.

8. Alpers BJ, Patten CA: Paroxysmal spasm of the eyelids as a postencephalitic manifestation. *Arch Neurol Psychiatry* 1927;18:427-433.

9. Zeman W, Kaebkins R, Pasamanick B: Idiopathic dystonia musculorum deformans: II. The formes frustes. *Neurology* 1960;10:1068-1074.

10. Jankovic J, Patel SC: Blepharospasm associated with brainstem lesions. *Neurology* 1983;33:1237-1240.

11. Choi IS: Delayed neurologic sequelae in carbon monoxide intoxication. *Arch Neurol* 1983;40:433-435.

12. Murray RR, Kapila A, Blanco E, et al: Cerebral computed tomography in drowning victims. *AJNR* 1984;5:177-179.

13. Dooling EC, Richardson EP: Delayed encephalopathy after strangling. *Arch Neurol* 1976;33:196-199.

14. Ringel SP, Klawans HL: Carbon monoxide-induced parkinsonism. *J Neurol Sci* 1972;16:245-251.

15. Jankovic J, Ford J: Blepharospasm and orofacial-cervical dystonia: Clinical and pharmacological findings in 100 patients. *Ann Neurol* 1983;13:402-411.

16. O'Connor PS: An oculinum report, editorial. *J Clin Neuro Ophthalmol* 1983;3:227-228.

Paraneoplastic Cerebellar Disease

Remission With Excision of the Primary Tumor

John H. Kearsley, MB; Peter Johnson, MB; G. Michael Halmagyi, MB

● We describe two patients with paraneoplastic cerebellar syndromes who gained clinically useful neurologic remissions following radical excision of the primary cancer. In both patients the syndrome was characterized by the rapid onset of gait ataxia, nausea, postural vertigo, central positional nystagmus, and saccadic oscillations. These observations encourage radical treatment of the primary cancer in patients with advanced malignant neoplasms who are disabled by cerebellar dysfunction, and lend support to a current hypothesis that paraneoplastic cerebellar degeneration is due to anticerebellar Purkinje cell antibodies elaborated by the primary cancer.

(*Arch Neurol* 1985;42:1208-1210)

A progressive cerebellar syndrome, due in some cases to cerebellar cortical degeneration, has been well described in cancer patients, commonly in those with lung cancer, ovarian

cancer, or neuroblastoma.^{1,4} In most patients the neurologic deficit accumulates over several months and indicates diffuse cerebellar dysfunction.^{1,4}

In others, however, the onset is abrupt,^{1,5,7} and gait ataxia, nystagmus, myoclonic jerks, and saccadic oscillations are prominent features.^{1,3,8-11}

Most authorities accept that the cerebellar syndrome in such cases is somehow caused by the remote cancer,^{1,2,4,11} and mechanisms suggested include the following: (1) cerebello-toxic substances, in particular anti-Purkinje cell antibodies elaborated by the tumor,¹²⁻¹⁵ (2) opportunistic viral infections,^{1,16} and (3) nutritional deficiencies perhaps due to the metabolic activity of the malignant neoplasm.^{12,17}

Remission of the cerebellar syndrome with treatment of malignant neoplasms has been rarely reported.^{5-7,17,18} Such cases are important, however, as they support the hypothesis that primary cancers can cause cerebellar dysfunction by elaborating cerebellotoxic substances such as anti-Purkinje antibodies. In support of this hypothesis, we describe two patients with advanced malignant

neoplasms who had, following extirpation of the primary cancer, gained temporary near-complete remissions from disabling cerebellar syndromes.

Report of Cases

CASE 1.—A previously well 63-year-old man suddenly developed intense nausea, vertigo, and inability to stand and was brought to a hospital. On examination, he appeared acutely sick and lay immobile on his right side. In the sitting posture, he had first-degree nystagmus to the right and to the left, and visual fixation was interrupted by frequent bursts of ocular flutter. Smooth pursuit and vestibulo-ocular reflex suppression were absent in the horizontal and vertical planes. Saccadic velocities appeared clinically normal, and there was no oculomotor paresis. Rapid supine positioning with the right ear down elicited, after a latent period of about five seconds, a ten- to 15-second burst of counterclockwise nystagmus with intense vertigo. Caloric tests showed symmetrical responses, unsuppressed by fixation. There was a moderately severe high-tone sensorineural hearing loss on the right. There was no weakness or incoordination of the limbs, but a profound inability to stand unaided, with a tendency to fall backward. Tendon reflexes were normal and symmetrical, and the plantar responses were flexor. Sensation was normal.

In the anterior compartment of the left

Accepted for publication July 3, 1984.

From the Department of Neurology, Royal Prince Alfred Hospital, Missenden Road, Camperdown, New South Wales.

Reprint requests to Department of Neurology, Royal Prince Alfred Hospital, Missenden Road, Camperdown, New South Wales 2050, Australia (Dr Halmagyi).