

Seizures in Pregnancy

ROBERT SHESSER, MD,* PRUDENCE KLINE, MD,*
LYNDON GOODWIN, MD†

CASE PRESENTATION

Dr. Prudence Kline: A previously healthy 37-year-old right-handed woman (G3 P2 O12) presented to the George Washington University Medical Center Emergency Department complaining of a severe headache ten days after a natural term vaginal delivery of a healthy infant.

One day after delivering she was told that her blood pressure was elevated, but she was not treated and the pressure normalized. Four days after delivering (while still in the hospital) her temperature rose to 38.3°C, and she experienced a shaking chill and developed the gradual onset of an intense, pounding, bitemporal headache. Five days after delivering, the fever abated, the headache improved, and she was discharged from the hospital. On the following day, the headache recurred, and for the next four days she experienced a severe headache refractory to barbiturates and narcotic analgesics. She also indicated having nasal stuffiness during this period. Eventually, she presented to the emergency department seeking relief from the pain.

On physical examination, the patient appeared to be in severe distress from pain. Her blood pressure was 140/90, pulse was 90 per minute, temperature was 37°C orally, and respiratory rate was 16 per minute.

Results of her general physical examination were otherwise unremarkable except for trace ankle edema. On neurological examination, she was alert and oriented, with normal cognitive function. Her strength was 5/5 throughout, and light touch, vibratory, position sense, and two-point discrimination were normal. There was no tremor or drift. Cerebellar function was normal. Reflexes were 3+ in the upper extremities and 2+ in the lower extremities, and no pathological reflexes were noted.

A neurology consultant examined the patient and expressed the opinion that the headache was "benign." Before discharge from the emergency department the patient complained of loss of vision, and approximately 30 seconds later

she had a witnessed, generalized, tonic-clonic seizure. After the seizure, her blood pressure was 230/130 mm Hg, fundi were unchanged, and repeat neurological examination revealed no localizing neurological deficits. She received 6 g of magnesium sulfate intramuscularly. No further seizures occurred, and her sensorium cleared in one hour. The patient was admitted to the hospital.

Results of a computerized tomographic (CT) scan of the head without contrast were normal. Her lumbar puncture had a normal opening pressure. The first tube of cerebrospinal fluid (CSF) had a pinkish tone with 655 erythrocytes/mm³ and 2 leukocytes/mm³, both lymphocytes. The third tube had 10 erythrocytes/mm³ and no leukocytes. No xanthochromia was noted. Glucose and protein levels were normal, and a gram stain was negative. A diagnostic procedure was then performed.

DISCUSSION

Dr. Robert Shesser: The patient is a 37-year-old woman who had an uneventful vaginal term delivery. Between the fourth and tenth days after delivering she had a severe headache, and at ten days after delivering she had a tonic-clonic seizure without evidence of a focal neurological deficit.

The differential diagnosis can be analyzed by starting with consideration of structural problems that could produce this syndrome. The first of these are problems in the cerebral arteries where the three major pathological events are thrombosis, emboli, and hemorrhage. An arterial thrombosis has an increased incidence in pregnancy, and happens in about one in 20,000 patients.¹ It presents as a stroke syndrome with a predilection for the middle cerebral artery distribution.² This patient's lack of focal neurological findings allows us to exclude an arterial thrombosis. Cerebral emboli are also seen with increased incidence in pregnancy, and there have been reports of paradoxical emboli from pelvic veins through a patent foramen ovale leading to neurological symptoms.¹ Lack of focal symptoms again allows us to exclude an embolic stroke.

Cerebral hemorrhage from either a ruptured arterial aneurysm or arteriovenous malformation must be considered in view of the headache, seizure, and the 600

From the Departments of *Emergency Medicine and †Radiology, George Washington University Medical Center, Washington, DC, and the Georgetown-George Washington-MIEMSS Affiliated Emergency Medicine Residency Program.

Manuscript received; accepted

Address reprint requests to Dr. Kline: 2140 Pennsylvania Ave., NW, Washington, DC 20037.

Key Words: Pregnancy, seizures, thrombosis.

TABLE 1. Subarachnoid Hemorrhage in Pregnancy

	Aneurysm	Arteriovenous Malformation
Maternal age	30–35 years	20–25 years
Parity	Multiparous	Primiparous
Onset of bleeding	Third trimester	Post-partum or second trimester
Prognosis	Poor	Good

erythrocytes/mm³ found on her lumbar puncture. There is an increased incidence of subarachnoid hemorrhage in pregnancy (1 in 10,000 pregnancies), which results from increased rupture of both arterial aneurysms and arteriovenous malformations.³

Aneurysms are formed by several different processes. They can be congenital, where there is either a weakness in the arterial wall or a post-stenotic dilation. They can also result from degenerative diseases (cystic medial necrosis), inflammatory diseases (arteritis), infectious diseases (mycotic aneurysms), and trauma. The reasons pregnancy *per se* predisposes toward aneurysm formation and rupture are two-fold. The hormones of pregnancy induce both an intimal hyperplasia and a weakening of the arterial media, which lead to aneurysm development. The increased cardiac output of pregnancy then results in aneurysm rupture.⁴ Studies have shown that the puerperium is actually an unusual time for rupture. Of aneurysms that rupture in pregnancy, 6% do so in the first trimester, 31% in the second trimester, 55% in the third trimester, and only 8% after delivery.⁴ Aneurysms are most frequently located in the circle of Willis, and there is about a 20% incidence of multiple aneurysms.³

Arteriovenous malformations bleed during pregnancy because the elevated levels of circulating steroid hormones weaken the smooth-muscle wall of these hemangiomas. Table 1 compares the demography and prognosis of pregnancy-associated subarachnoid hemorrhage resulting from rupture of an arterial aneurysm with that observed in bleeding from arteriovenous malformations.

Recommended management of a subarachnoid hemorrhage in the pregnant patient is early angiography with surgery as indicated. The presence of a pregnancy should affect neither the decision to do an angiogram nor to perform early surgery when necessary.

I do not think this patient had a subarachnoid hemorrhage, as it would be very unusual to have a week's symptoms from a leaking aneurysm or arteriovenous malformation without either abnormal CT scan results or the presence of a significant number of CSF red blood cells or xanthochromia. Also, the headache's onset was gradual, whereas subarachnoid hemorrhage usually presents with the sudden onset of a headache.

I will defer the discussion of structural problems that can occur in the cerebral veins. Other structural problems include a mass lesion such as a tumor, or an abscess. These should have been seen on the CT scan, so I will exclude them.

Complicated migraine can be considered a structural problem of the cranial vessels, but it would be fairly unusual to have seizures secondary to migraines. Some patients with complicated migraines, however, can experience a loss of consciousness and a number of other significant neurological sequelae as part of their headache pattern. The usual course of migraine in pregnancy is to worsen in the first trimester, but then improve.²

There are also metabolic processes that can cause seizures in pregnancy. Many pregnant patients receive vasopressin and may become sufficiently hyponatremic to present with seizures, headache, and abnormal mental status secondary to water overload. The patient's normal levels of serum electrolytes exclude this problem in this case.

A metabolic problem that must be excluded is eclampsia. This is the combination of seizures associated with edema, hypertension, and proteinuria, and is seen in the peripartum period. It can be seen in the postpartum patient, but it would be very unusual for eclampsia to first present more than 36 hours after delivery.⁵ Because this patient had minimal edema and no proteinuria, eclampsia can be excluded.

Infectious processes, such as meningoencephalitis, should be considered, particularly if there is a history of fever and chills. However, the history, physical examination, and near-normal spinal fluid results help us rule out infectious causes of seizures and a fever.

There is a possibility that the patient had a "benign" headache and experienced a seizure from an idiopathic epileptic diathesis unrelated to the headache. Pregnant patients are prone to several types of seizure disorders. Gestational epilepsy is a condition in which patients have seizures during pregnancy, and then proceed to have no further seizures after the termination of the pregnancy. They usually have only one or two seizures during pregnancy.⁶ If a patient with gestational epilepsy remains seizure-free after delivery, it is not possible to predict whether that patient will have a seizure in a subsequent pregnancy.

Pregnancy has a variable effect on idiopathic epilepsy. In pregnant patients with a previously well-defined seizure focus, 45% will develop an increase in their seizure frequency during pregnancy. This increase usually occurs during the first trimester.⁶ Mothers carrying male fetuses seem to have an increased frequency of seizures.¹ Women who have a seizure frequency of greater than one per month before their pregnancy tend to develop an increase in frequency, whereas women with a less serious seizure

diathesis tend not to have an increase in their seizures.⁶ No change in seizure frequency is experienced by 50% of women, and about 5% actually get better. After delivery the seizure pattern tends to revert to the pre-pregnancy pattern.

There are several reasons for poor seizure control during pregnancy of patients with pre-existing idiopathic epilepsy: 1) medication discontinuation; 2) increased anticonvulsant metabolism; and 3) dilution of anticonvulsants by an increase in blood volume. Because of the latter two reasons, patients taking either phenytoin or phenobarbital require increased dosages during pregnancy.

Some unique pharmacological properties of phenytoin in the pregnant patient should be noted. Many pregnant patients are given supplemental folate that will lower serum phenytoin levels through a poorly understood mechanism. There is also a risk in giving either phenytoin or phenobarbital to a pregnant patient that there will be an increased incidence of congenital heart disease, cleft palate, and cleft lip.⁷ Though the risk is higher with phenytoin than phenobarbital, the combination of the two drugs markedly increases the risk of these congenital deformities.⁷ Decreased serum folate level has also been implicated as a cause of this teratogenesis.⁷

A hemorrhagic diathesis in neonates born to a mother who has been taking either phenytoin or phenobarbital has been seen.⁷ The syndrome resembles vitamin-K deficiency, with decreases in factors II, VII, IX, and X seen during the first 24 hours after birth. The babies tend to bleed into unusual places such as the pleural and peritoneal cavities. They can be treated with vitamin K and fresh-frozen plasma. The physician should be careful to check the prothrombin time on the cord blood of any neonate born to a mother on anticonvulsants.

In reviewing the list, we have eliminated cerebral arterial pathology, a mass lesion, a migraine, an infection, and any of the metabolic derangements that may cause such a picture. Though new onset of idiopathic epilepsy has not yet been excluded, there is a more likely explanation for this problem if we consider a disease process involving the cerebral veins.

The cerebral veins are drained by an interlocking system of thin-walled venous sinuses, which lie in the dura mater. These sinuses have no valves and they drain through the jugular venous system.

Patients late in pregnancy and the puerperium have an increased incidence of cerebral venous thrombophlebitis with thrombosis caused by their hypercoagulable state and endothelial damage sustained in vascular insults (such as pre-eclampsia) earlier in the pregnancy. Initially, there will be focal damage in one of the sinuses, followed by initiation of thrombosis and clot propagation throughout the sinuses and jugular

system.⁸ The exact degree and location of thrombus propagation will dictate the order and nature of the symptoms that are seen. For example, if the superior sagittal sinus is involved, initially one will see papilledema and headache.⁸ If the cavernous sinus is involved, the eyes will be more severely affected, leading to chemosis and proptosis. As thrombosis of the superior sagittal sinus has been known to give epistaxis, I wonder whether the nasal engorgement and stuffiness described by this patient were not clues to superior sagittal sinus thrombosis.

Researchers feel that certain people may have a congenital anatomical predisposition to cerebral venous thrombosis, such as the presence of multiple trabeculae in their sinuses.⁹ Spread of bacterial sinusitis from one of the facial sinuses through the facial bones can also lead to cerebral venous phlebitis and thrombosis. Physicians should suspect this entity in patients with a history of otitis media of one or two weeks' duration, who then develop headache and seizures.

Cerebral venous thrombosis occurs in between 1/1,500 to 1/3,000 pregnancies.⁹ It is seen most frequently either during the third trimester or between seven and fourteen days after delivery. Cerebral venous thrombosis can occur in patients taking oral contraceptives or in patients with dehydration, hemolytic anemia, congestive heart failure, sickle cell anemia, paroxysmal nocturnal hemoglobinuria, ulcerative colitis, or diabetes mellitus.⁹

There is a great variability in presenting symptoms because of the great variability in origin and the spread of thromboses. About 45% will present with paresis caused by focal tissue death that follows a decrease in perfusion pressure to cerebral parenchyma, and 40% will present with a headache from the increased intracranial pressure. About a third will present with seizures, a quarter with speech deficits, and a lesser number with confusion, paresthesias, vomiting, or visual changes.⁸ This patient experienced a sudden episode of blindness before her seizure, which is consistent with the history of a venous thrombosis involving the eye's venous drainage system. Patients can also have mild pyrexia and waxing and waning hypertension. Secondary subarachnoid hemorrhage is frequent with cerebral venous thrombosis, because the walls of the sinuses become necrotic and red blood cells can extravasate into the subarachnoid space, resulting in bloody cerebrospinal fluid. In about a third of the cases the results of the spinal tap will be normal, in 40% there will be increased opening pressure, and in a quarter there will be some red blood cells in the spinal fluid, although only 7% of the patients will have frankly bloody spinal taps. Leukocyte count will be increased in 15%, and in about 10% there will be some xanthochromia.⁸ The definitive diagnosis is made by CT scan and angiogram.

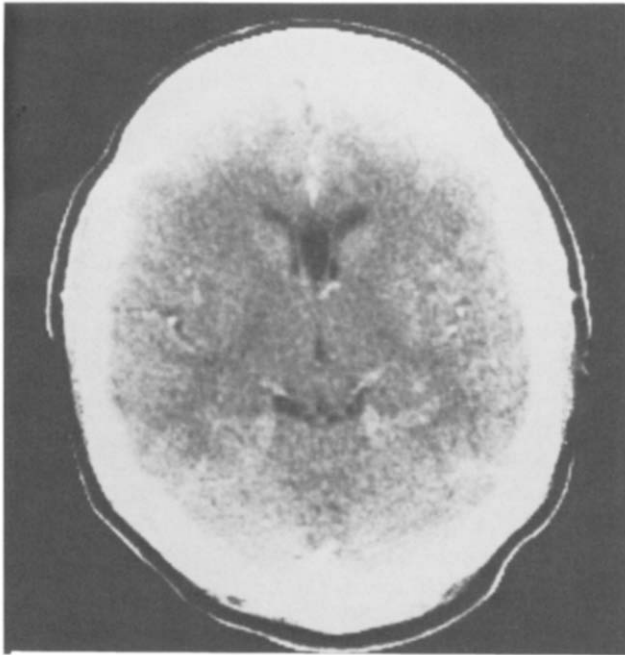


FIGURE 1. Normal computerized tomographic scan.

The natural history and prognosis of this disease is variable. The clinical course can be entirely benign, but there is said to be a 33% mortality rate, and there will be persistence of neurological defects in 20% of the patients.⁸ There have been no comparative studies about the various treatments, but most authors⁸⁻¹⁰ agree that patients should be vigorously treated with anti-edema agents such as mannitol (although I would avoid mannitol in the pregnant patient because it can lead to fetal dehydration) or dexamethasone, and anticonvulsants. Heparin is contraindicated, as its administration predisposes to a much higher incidence of hemorrhagic strokes leading to greater morbidity without lowering mortality.⁸ Most authorities⁸⁻¹⁰ do not recommend terminating the pregnancy if cerebral venous thrombosis is confirmed, but indicate that the condition may occur in subsequent pregnancies.

In conclusion, I think that this patient had a cerebral venous thrombosis. I am puzzled as to why the neurologist was ready to send the patient out with such a severe clinical presentation. I suspect that the diagnostic procedure used was a cerebral arteriogram.

Dr. Shesser's diagnosis: cerebral venous thrombosis.

Dr. Prudence Kline: The diagnostic study was actually a CT scan with contrast. Dr. Lyndon Goodwin will review the radiographic studies.

Dr. Lyndon Goodwin: The CT scan patterns of patients with classic cerebral venous thrombosis are highly variable. The classic CT finding, called a "delta" sign (seen only on a contrast scan) is seen in the region of the torcula, which is the confluence of venous sinuses in the occipital area. Because the sinus

contains clots, contrast will not enter the region, and the area appears lucent in the contrast. The presence and location of cerebral infarction is another way of making the diagnosis. The venous system of the brain is generally divided into the superficial and deep systems. The deep system consists of the vein of Galen with the deep cerebral veins that drain the deeper structures, such as the basal ganglia and the thalamus. The superficial system serves most of the cerebral hemispheres, and drainage is through the venous sinuses. Most thromboses occur in surface veins or in the venous sinuses, and the infarcts that are seen from those are generally on the surface. The superficial cortical infarcts may be either bland or hemorrhagic. This patient's CT scan is normal (Fig. 1). However, we have another scan (Fig. 2) that demonstrates the classic pattern of cortical vein thrombosis.

Question: Does a normal contrast scan rule out cortical vein thrombosis?

Dr. Lyndon Goodwin: No, it does not, and I think that in this age of easily available CT, we will see many more cases that have positive findings on angiography but normal findings on CT scan.

Question: Could you discuss the role of digital venous imaging versus conventional angiography?

Dr. Lyndon Goodwin: Digital imaging gives very good contrast, so digital imaging is very effective when asking a specific question, such as whether the superior sagittal sinus is open. It also shows venous structures well, which conventional arteriography tends to obscure. Actual image resolution, however, is not particularly high, and arteriography is preferable for answering a more general question, such as whether a process could be an arteritis or whether a vascular blush is present.

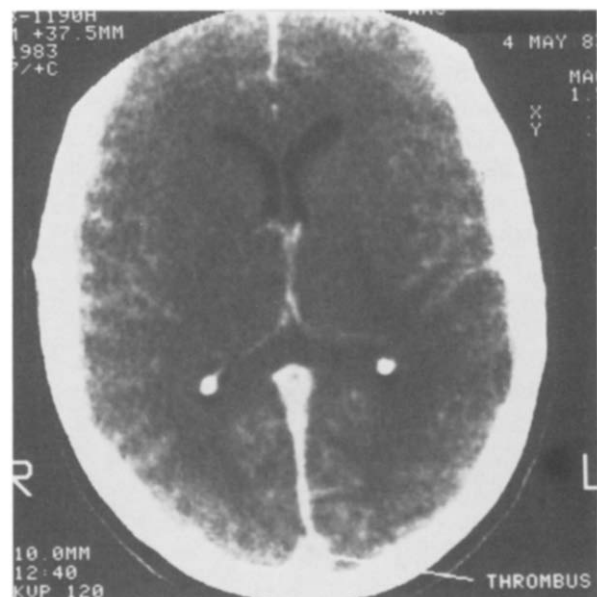


FIGURE 2. Computerized tomographic scan demonstrating thrombus in torcula (contrast).

Dr. Prudence Kline: One study that addresses the question of the superiority of digital venous angiography versus arteriography in the diagnosis of sagittal sinus thrombosis demonstrated the superiority of digital venous angiography.¹¹

Question: If the results of the CT scan were negative, how was the diagnosis made?

Dr. Prudence Kline: The diagnosis can be made by the clinical syndrome of headache and seizures in a patient without focal neurological findings when non-invasive diagnostic studies fail to demonstrate other serious pathology.

For many years, the assumption was made that all neurological catastrophes during pregnancy resulted from venous thrombosis. In the late 1960s, however, this concept was challenged by two major studies, those by Cross² and Amias.^{12,13} In Cross' study,² there were 31 patients, 18 of whom had arterial thrombosis documented either on arteriogram or post-mortem examination. Only three had venous occlusion demonstrated either arteriographically or by post-mortem examination. The investigators noticed that those with proven venous thromboses tended to have the symptom complex of headaches, seizures, and altered mental status, whereas those with arterial thromboses had a more classic hemiparetic picture without a change in mental status. The second study, that of Amias^{12,13} in 1970, included 18 patients. Fifteen had arteriograms, and the results of six of those were positive for arterial occlusions, whereas the results of four were negative. There were four patients with post-mortem examination results that were consistent with venous thrombosis. Therefore, those two studies tended to dispell the earlier myths that all clots in pregnancy must be venous in origin. They also emphasized the need for definitive diagnostic studies in patients with focal findings, because those patients were more likely to have arterial lesions, whereas those without focal findings tended to have venous thrombosis. Both of these studies also emphasized the neurosurgical considerations over the obstetric considerations. There is no urgent need to deliver an infant under

these circumstances. One simply treats the woman as one would in the absence of pregnancy.

CLINICAL COURSE

Dr. Prudence Kline: Immediately after her seizure, she was catheterized and was found to have 3+ proteinuria. The initial clinical impression was eclampsia, so she was given magnesium sulfate. She then received a loading dose of phenytoin. Her blood pressure then came down to about 140/90 mm Hg, her mental status cleared, and she improved dramatically. Her proteinuria cleared. She received no medication except phenytoin, and she did not receive anticoagulation therapy.

REFERENCES

1. Hopkins A. Neurologic disorders. *Clin Obstet Gynaecol* 1977;4:419-433.
2. Cross JN, Castro PO, Jennett WB. Cerebral strokes associated with pregnancy and the puerperium. *Br Med J* 1968;3:214-218.
3. Robinson JL, Chir B, Hall CJ, et al. Subarachnoid hemorrhage in pregnancy. *J Neurosurg* 1972;36:27-33.
4. Barrett JM, Van Hooydonk JE, Boehm FH. Pregnancy-related rupture of arterial aneurysms. *Obstet Gynecol Surv* 1982;37:557-566.
5. Pritchard JA, Stone SR. Clinical and laboratory observations on eclampsia. *Am J Obstet Gynecol* 1967;99:754-765.
6. Knight AH, Rhind EG. Epilepsy and pregnancy. *Epilepsia* 1975;16:99-110.
7. Nau H, Kuhn W, Egger HJ, et al. Anticonvulsants during pregnancy and lactation. *Clin Pharmacokinet* 1983;7:508-543.
8. Gettelfinger DM, Kokmen E. Superior sagittal sinus thrombosis. *Arch Neurol* 1977;34:2-6.
9. Carroll JD, Leak D. Cerebral thrombophlebitis in pregnancy and the puerperium. *Q J Med* 1966;35:347-368.
10. Aminoff MJ. Neurologic disorders and pregnancy. *Am J Obstet Gynecol* 1978;132:325-333.
11. Barnes B, et al. Digital subtraction angiography in the diagnosis of superior sagittal sinus thrombosis. *Neurology* 1983;33:508-510.
12. Amias AG. Cerebral vascular disease in pregnancy: I. Hemorrhage. *J Obstet Gynecol Br Commonwealth* 1970;77:100-120.
13. Amias AG. Cerebral vascular disease in pregnancy: II. Occlusion. *J Obstet Gynecol Br Commonwealth* 1970;77:312-325.