

*Short report*

## Syndrome of the mesencephalic artery: report of a case with CT and necropsy findings

M SETH HOCHMAN, JORGE J SOWERS, JOCELYN BRUCE-GREGORIOS

*From the Departments of Neurology, Radiology and Pathology, University of Miami School of Medicine and Mercy Hospital, Miami, Florida, USA*

**SUMMARY** The syndrome of the mesencephalic artery refers to the clinical constellation of akinetic mutism and third nerve palsy which results from occlusion of one or more of the posterior thalamoperforating arteries that arise from the proximal posterior cerebral artery. A patient with this syndrome is described in whom a bilateral paramedian midbrain infarct was shown by computed tomography and confirmed pathologically. To our knowledge, this is only the second reported case of mesencephalic infarct shown by computed tomography and the first in which the CT findings have been corroborated by pathological examination.

The syndrome of the mesencephalic artery<sup>1</sup> is the clinical constellation of akinetic mutism and third nerve palsy which results from occlusion of one or more of the posterior thalamoperforating arteries of Percheron:<sup>2,3</sup> these are the anterior and posterior thalamo-subthalamic paramedian and superior and inferior mesencephalic paramedian arteries. All of these penetrating branches arise from the proximal three or four millimeters of each posterior cerebral artery which has been variously named the basilar communicating artery and the mesencephalic artery.<sup>1</sup> The resulting infarct involves the midbrain, subthalamus and/or the thalamus and typically has a butterfly shape because a penetrating branch from one mesencephalic artery may supply both paramedian areas.

The syndrome of the mesencephalic artery is not well-known to neurologists, in part because of the rarity of the infarct, but also because of the difficulties of diagnosis. According to Fisher,<sup>3</sup> infarcts in the distribution of the mesencephalic artery are not usually disclosed on CT scan. We now describe a patient with the syndrome of the mesencephalic artery in whom a bilateral paramedian midbrain infarct was documented by computed tomography and confirmed pathologically. To our knowledge, this is

only the second reported case of mesencephalic tegmental infarct demonstrated by computed tomography and the first in which the CT findings have been corroborated by the post-mortem examination.

### Case report

The patient is a 69-year-old white male who was brought to the Emergency Room after having been found unresponsive on the floor of the office building in which he worked. Initially, the patient appeared comatose with 5 mm diameter mid-position fixed pupils which did not react to light directly or consensually and closed eyes which did not open spontaneously or on verbal command. Eyes were maintained at the extremes of lateral gaze. No change in the position of either eye was noted after unilateral and simultaneous bilateral ice water caloric irrigation in the head-hanging and 30° head-elevated positions. No vocalisation, spontaneous speech or extremity movements were noted. However, on external stimulation, the patient was observed to move his extremities. An axial CT scan of the brain, before and after contrast-enhancement with routine consecutive 10 mm sections of the posterior fossa were considered normal, although considerable artifact-induced image degradation was present. Repeat routine CT scan performed one week following admission was again normal. A third CT scan performed three weeks following admission with 5 mm contiguous sections of the brain stem revealed a well-defined butterfly-shaped area of decreased absorption coefficient within the tegmental area of the upper and lower mesencephalon (fig 1). During eight weeks in hospital the patient manifested a low level of intermittent response to sensory stimuli. Although he remained akinetic and mute, rarely following repeated

Address for reprint requests: M Seth Hochman, MD, 3661 South Miami Avenue, Miami, Florida 33133, USA.

Received 4 January 1985 and in revised form 1 March 1985.  
Accepted 8 March 1985.

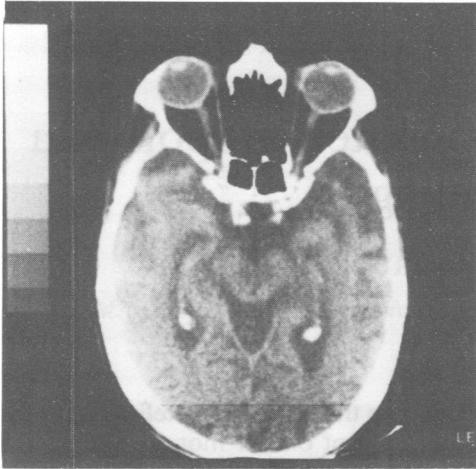


Fig 1 CT 5 mm contiguous axial section, before injection of contrast, at caudal mesencephalic level. Note the well-defined bilateral paramedian tegmental areas of low absorption coefficient corresponding to the ischaemic infarct, adjoining each other at the midline.

verbal commands, he would move his extremities and when asked to open his eyes, at times, contract the frontalis muscle. Occasionally, he would utter unintelligible vocalisations when his tracheostomy tube was occluded. The patient was discharged to a nursing home where he died four weeks later.

#### Neuropathological findings

Gross appearance of the carotid and vertebrobasilar arterial system showed moderate atherosclerosis. No site of local occlusion could be identified. Focal leptomeningeal fibrosis, mild cortical atrophy and slight ventricular enlargement were present. The major pathology was seen in the mid-brain: (fig 2) within the central tegmental area, there was a well-defined organising infarct which extended throughout the entire length of the mid-brain. The focus of necrosis and cavitation was contiguous with an organising haemorrhagic lesion in the left pretectal region extending

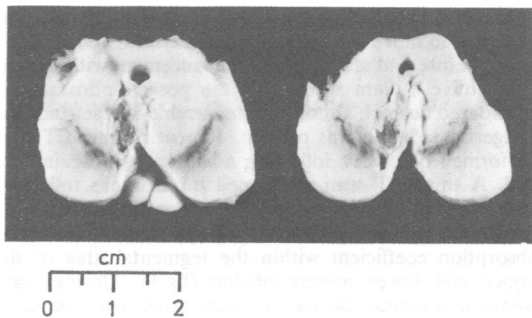


Fig 2 Paramedian mesencephalic infarct.

upward to form cavitory lesions in the posterior medial thalamus. Small bilateral relatively symmetrical infarcts were seen in the intralaminar thalamic areas. Microscopically, the central tegmental area of the mid-brain at the level of the pretectal region showed a large organising slightly haemorrhagic infarct extending ventrally to the involved red nucleus bilaterally, as well as the medial portion of the cerebral peduncles. Some outline of the ventral tegmental tracts remained in the central portion of the infarct. Exiting oculomotor nerve tracts showed extensive Wallerian degeneration.

#### Discussion

Although our patient occasionally would utter unintelligible vocalisations and rarely move his extremities following repeated verbal commands and at times contract the frontalis muscle when asked to open his eyes, for most of the time he satisfied the criteria for the hypersomnolent type of akinetic mutism set forth by Plum and Posner.<sup>9</sup> Akinetic mutism in humans has been observed with lesions in the walls of the third ventricle and following bilateral brain damage to the anterior cingulate gyri, globus pallidus and paramedian diencephalic and mesencephalic reticular formation as in the present case. Biller and colleagues<sup>4</sup> have recently described a patient in whom a mesencephalic tegmental infarct was shown radiographically by high-resolution computed tomography. Clinically their patient exhibited bilateral ptosis, internuclear ophthalmoplegia and somnolence which occurred immediately following percutaneous transluminal coronary artery angioplasty. A cranial CT scan obtained several hours following onset of symptoms was normal. Repeat CT with 2 mm sections of the upper brain stem at a 30° angle to the orbital meatal line 96 hours after onset of symptoms revealed a non-enhancing focal area of lucency consistent with infarction in the rostral mesencephalic dorsal tegmentum in the area of the oculomotor nuclear complex and the median longitudinal fasciculus. Whether a CT scan with contiguous thin sections of the mid-brain, subthalamus and thalamus would show small circumscribed paramedian infarcts in the first hours following the onset of the syndrome of the mesencephalic artery cannot be answered. Only routine 10 mm sections were obtained on the first negative CT scan performed on our patient on the first hospital day and also on the second CT scan one week later. The fact that on the third scan the infarct was noted on only two contiguous 5 mm slices suggests that contiguous thin-section technique is important in demonstrating these infarcts. Thin sections will reduce the partial volume effect and the induced artifacts resulting from the dense osseous and air-contrasting structures at the base of the skull.<sup>5</sup>

Increase in milliamperage and scanning time will reduce the quantum noise inherent in these thin sections. Special scanning plane<sup>6</sup> (minus 15° to the infra-orbital meatal line) will further reduce bone-induced artifacts and better demonstrate mesencephalic anatomy.<sup>7</sup> The reported sensitivity of CT in detecting ischaemic cerebral infarcts has ranged from as low as 10% during the first 48 hours to as high as 84% after this period of time has elapsed following the onset of symptoms.<sup>8</sup> It is possible, then, that even with careful CT scanning technique, demonstration of the syndrome of the mesencephalic artery may be delayed. Therefore, if there is evidence of fluctuating or incomplete neurological deficit in the distribution of the branches of the mesencephalic artery and no infarct or haemorrhage is demonstrated on contiguous thin sections of the vascular territories of these branches, anticoagulation may be warranted in attempt to prevent further ischaemic infarction. Care must be taken not to confuse the normal low density of the decussation of the superior cerebellar peduncles with an infarct within the caudal mesencephalon.<sup>7</sup> The low density of the superior cerebellar peduncular decussation does not extend to the rostral mesencephalic level. Although there was no pathological confirmation that the area of mid-brain lucency in the case of Biller *et al* was the anatomical site of an infarct, nonetheless, the fact that this abnormality was limited to the rostral mesencephalon clearly distinguishes it from the normal low attenuation decussation of the superior cerebellar peduncles. In our own case, the areas of low attenuation involved both the upper and lower mesencephalon and extended to

the midline (fig 1). As the low density of the superior cerebellar peduncular decussation does not extend to the midline, this subtle but important differential point helped in defining the lower limits of the infarct radiographically. Post-mortem examination confirmed that the infarct extended throughout the *entire length* of the midbrain.

#### References

- <sup>1</sup> Segarra JM. Cerebrovascular disease and behaviour. The syndrome of the mesencephalic artery. *Arch Neurol* 1970; **22**:408-18.
- <sup>2</sup> Castaigne P, Lhermitte F, Buge A, *et al*. Paramedian thalamic and midbrain infarcts: clinical and neuropathological study. *Ann Neurol* 1981; **10**:127-48.
- <sup>3</sup> Fisher CM. Lacunar strokes and infarcts: a review. *Neurology (NY)* 1982; **32**:871-6.
- <sup>4</sup> Biller J, Shapiro R, Evans L, *et al*. Oculomotor nuclear complex infarction: clinical and radiological correlation. *Arch Neurol* 1984; **41**:985-7.
- <sup>5</sup> Earnest F, McCullough EC, Frank DA. Fact or artifact: an analysis of artifact in high-resolution computed tomographic scanning of the sella. *Radiology* 1981; **140**:109-13.
- <sup>6</sup> Rosenbloom S, Bucholz D, Kumar AJ, *et al*. Evolution of central pontine myelinolysis on CT. *AJNR* 1984; **5**:110-12.
- <sup>7</sup> Berns TF, Daniels DL, Williams AL. Mesencephalic anatomy: demonstration by computed tomography. *AJNR* 1981; **2**:65-7.
- <sup>8</sup> Wall SD, Brant-Zawazki M, Brooke JR, *et al*. High frequency CT findings within 24 hours after cerebral infarction. *AJNR* 1981; **2**:553-7.
- <sup>9</sup> Plum F, Posner JB. *Diagnosis of Stupor and Coma*. 3rd ed. Philadelphia: FA Davis Co, 1980:107.