

# Transient Global Amnesia Associated with Bilateral Subdural Hematomas

Peggy-Elizabeth Chatham, M.D., and Jon Brillman, M.D.

*Division of Neurology, Allegheny General Hospital, Pittsburgh, Pennsylvania*

An elderly man presenting with an episode of transient global amnesia was found to have bilateral subdural hematomas. The entity of transient global amnesia, its relationship to structural brain disease, and its possible pathogenesis are discussed. (*Neurosurgery* 17:971-973, 1985)

**Key words:** Subdural hematoma, Transient global amnesia

## INTRODUCTION

Transient global amnesia (TGA) is a unique disorder of memory characterized by sudden amnesia for recent events lasting one-half to several hours. It was first described by Fisher and Adams (8). The spell is followed by retrograde amnesia for a variable length of time, which usually contracts to include the amnesic episode only. During the spell of TGA, the patient may be able to carry on some normal activities, but often appears bewildered and distressed, asks repetitive questions regarding his plight, and is unable to retain new information. Ordinarily, these attacks are solitary and rarely recur.

The pathology of TGA is not known with certainty, but it has been described in association with a number of other conditions. These include migraine (3), dominant hemisphere glioma (14), pituitary tumor and cerebral angiography (4). We report a unique case of TGA associated with bilateral subdural hematomas.

## CASE REPORT

A 74-year-old, right-handed, retired salesman with a history of mild hypertension was in excellent health. He was relaxing at home when he suddenly seemed confused and repeatedly asked his son where he had obtained the newspaper, even though it was delivered on a daily basis to the home. He then went outside and checked the trunk of the car several times, but did not know what he was looking for.

Throughout this period, which lasted approximately 4 hours, the patient was completely oriented to person. After this period, he returned to his normal state, but was totally amnesic for the event. He denied headache, focal neurological symptoms, and dizziness and seemed otherwise alert and normal. After visiting his family physician, he was referred for neurological evaluation.

The patient had no history of trauma or of symptoms consistent with transient ischemic attacks or suggesting cardiac disease. There was no history of any confusional or amnesic episodes. For approximately 1 week preceding the episode, he had complained of mild, retrobulbar discomfort with eye movement.

Physical examination revealed a mildly obese man. He was completely alert and oriented, and he exhibited perfectly normal and appropriate responses to questioning. Remote and recent memory were intact with the exception of total amnesia for the 4-hour event described. The findings of a mental status examination were otherwise within normal

limits. There was mild diastolic hypertension, with a blood pressure of 170/100. The physical examination was otherwise normal. The cranial nerves were normal, and the optic fundi were normal without papilledema. Motor, sensory, and cerebellar examinations showed entirely normal results. The reflexes were symmetrical. The plantar reflexes were flexor, and there were no pathological reflexes. No bruits were audible in the neck.

An electroencephalogram was within normal limits. A computed tomographic (CT) scan of the head showed bilateral subdural hematomas with effacement of the cortical sulci and some ventricular compression (Fig. 1). No other abnormalities were noted.

After admission to the hospital, the patient was taken to the operating room, where bilateral subdural collections of thick fluid, as commonly seen with chronic subdural hematomas, were removed. The patient tolerated the procedure

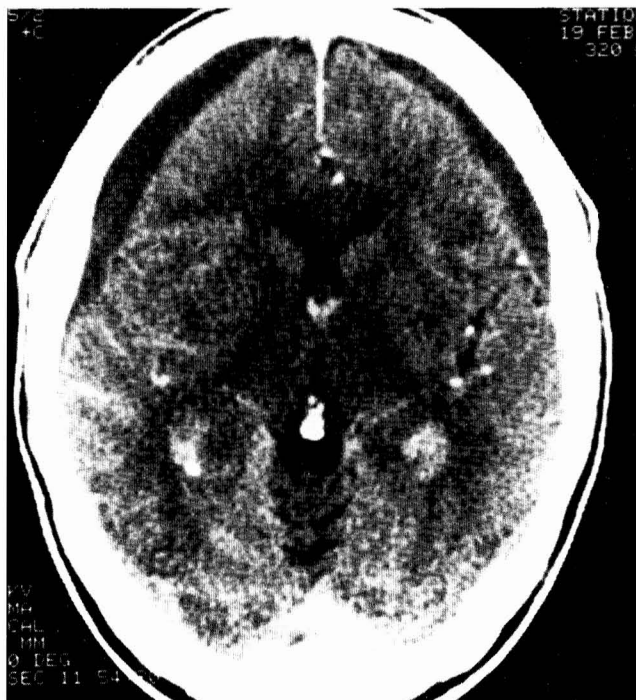


FIG. 1. CT scan shows bilateral subdural hematomas, effacement of the cortical sulci, and ventricular compression.

well, and the postoperative course was uneventful. The results of neurological examination, including memory testing and mental status evaluation, were entirely normal postoperatively.

DISCUSSION

The pathogenesis of TGA is still speculative. As the process is transitory and totally reversible, its cause should fall into one of three broad categories: epileptic, transient ischemic, or migrainous. The evidence supporting an epileptogenic cause of TGA is not convincing. Although amnesia, occasional electroencephalogram abnormalities, and the association of TGA with temporal lobe tumors are reminiscent of complex partial epilepsy, the nonrecurrence of the episodes, the absence of impaired consciousness, the long length (hours) of the spells, and the lack of other features of complex partial epilepsy all argue strongly against TGA being an epileptic phenomenon (21). Fisher noted the common association of emotionally disturbing events preceding attacks of TGA and suggested that this favors an epileptogenic pathogenesis (9). Upsetting events, however, can be followed by transient ischemic or migrainous attacks as well.

TGA has been associated with the vasoconstrictive phase of migraine. This has been supported by cerebral blood flow studies (23) and the similarity between TGA and some atypical migrainous syndromes (5). The isolated nature of the spells is also consistent with migraine. In some elderly patients with TGA, however, migraine seems an unlikely cause. In these individuals, the reported high incidence of risk factors for cerebral vascular disease (20) and the occurrence of TGA during cerebral angiography (4) suggest a mechanism similar to that of transient ischemic attacks, particularly those in the vertebral basilar territory.

As noted in the introduction, TGA has been reported with a variety of clinical phenomena (Table 1). It has been speculated that the TGA in these individuals is due to a disturbance of function of the fornices or the limbic system, where lesions may be associated with memory loss (22). The precise mechanism is likewise conjectural in our patient.

TABLE 1  
Conditions Associated with TGA

Condition	Author, Year	Reference
Temporal arteritis	Bolwig, 1968	1
Sensory stimulation	Martin, 1970	15
	Mayeux, 1979	16
	Fisher, 1982	9
Spinal anesthesia	Dykes, 1972	6
Diazepam toxicity	Gilbert, 1972	10
Prosthetic aortic valve	Steinmetz, 1972	19
Angiography	Shuttleworth, 1973	18
	Cochran, 1982	4
Pituitary tumor	Hartley, 1974	12
Bradycardia with digitalis toxicity	Greenlee, 1975	11
Dominant hippocampal glioma	Boudin, 1975	2
	Shuping, 1980	17
Dominant temporoparietal tumor	Lisak, 1977	14
Dominant temporal lobe hemorrhage	Landi, 1982	13
Nondominant parietal lobe metastasis	Findler, 1983	7
Bilateral subdural hematomas	Chatham, 1985	

In a patient with subdural hematomas, seizures (particularly complex partial ones) are rarely seen. This fact argues against a seizure mechanism. It is possible, although beyond proof, that increased intracranial pressure due to the subdural hematomas impaired cerebral blood flow, particularly in the posterior cerebral arteries, which led to a transient episode of ischemia. Whatever the mechanism, this report demonstrates that TGA can be associated with a variety of intracerebral processes and quite likely has more than one pathogenesis.

Received for publication, April 26, 1985; accepted, August 2, 1985.

Reprint requests: Jon Brillman, M.D., Allegheny Neurological Associates, Suite 200, Allegheny Professional Building, 490 East North Avenue, Pittsburgh, Pennsylvania 15212.

REFERENCES

- Bolwig TG: Transient global amnesia. *Acta Neurol Scand* 44:101-106, 1968.
- Boudin G, Pepin B, Mikol J, et al: Gliome de systeme limbique posterieur revele par une amnesie globale transitoire: Observation anatomo-clinique d'un cas. *Rev Neurol* 131:157, 1975.
- Caplan L, Chedru F, Lhermiere F, Mayman C: Transient global amnesia and migraine. *Neurology (NY)* 31:1167, 1981.
- Cochran JW, Morrell F, Huckman MS, Cochran EJ: Transient global amnesia after cerebral angiography. *Arch Neurol* 39:593-594, 1982.
- Croft PB, Healthfield KWG, Swash M: Differential diagnosis of transient amnesia. *Br Med J* 4:593-596, 1973.
- Dykes MHM, Sears BR, Caplan LR: Transient global amnesia following spinal anesthesia. *Anesthesiology* 36:615, 1972.
- Findler G, Feinsod M, Lijovetzky G, Hadani M: Transient global amnesia associated with a single metastasis in the non-dominant hemisphere. *J Neurosurg* 58:303-305, 1983.
- Fisher CM, Adams RD: The transient global amnesia syndrome. *Acta Neurol Scand* 40(suppl 9):7-82, 1964.
- Fisher CM: Transient global amnesia: Precipitating activities and other observations. *Arch Neurol* 39:605-608, 1982.
- Gilbert JJ, Benson DF: Transient global amnesia: Report of two cases with definite etiologies. *J Nerv Ment Dis* 154:461-464, 1972.
- Greenlee JE, Crampton RS, Miller RQ: Transient global amnesia associated with cardiac arrhythmia and digitalis intoxication. *Stroke* 6:513-516, 1975.
- Hartley TC, Heilman KM, Garcia-Bengochea F: A case of transient global amnesia due to a pituitary tumor. *Neurology (NY)* 24:998-1000, 1974.
- Landi G, Guisti MC, Guidotti M: Transient global amnesia due to left temporal haemorrhage. *J Neurol Neurosurg Psychiatry* 45:1062-1063, 1982.
- Lisak RP, Zimmerman RA: Transient global amnesia due to a dominant hemisphere tumor. *Arch Neurol* 34:317-318, 1977.
- Martin EA: Transient global amnesia: A report of 11 cases, including 5 of amnesia at the seaside. *Irish J Med Sci Eighth series* 3:331-335, 1970.
- Mayeux R: Sexual intercourse and transient global amnesia. *N Engl J Med* 300:864, 1979.
- Shuping JR, Toole JF, Alexander EJ: Transient global amnesia due to glioma in the dominant hemisphere. *Neurology (NY)* 30:88-90, 1980.
- Shuttleworth EC, Wise GR: Transient global amnesia due to arterial embolism. *Arch Neurol* 29:340-342, 1973.
- Steinmetz EF, Vroom FQ: Transient global amnesia. *Neurology (NY)* 22:1193-1200, 1972.
- Shuping JR, Rollinson RD, Toole JF: Transient global amnesia. *Ann Neurol* 7:281-285, 1980.
- Tharp BR: The electroencephalogram in transient global amnesia. *Electroencephalogr Clin Neurophysiol* 26:96, 1969.
- Victor M, Angevine JB Jr, Mancall EL, Fisher CM: Memory loss with lesions of hippocampal formation. *Arch Neurol* 5:244-263, 1961.
- Wood F, et al: Regional cerebral blood flow response in a patient with remitted global amnesia. *Brain Lang* 9:123, 1979.

COMMENT

The transient global amnesia syndrome is being reported increasingly, with most neuroclinicians having experience with several patients. Clinical series from individual institutions with 30 to 150 patients now exist. TGA is truly a syndrome, occurring in many clinical situations and probably with several mechanisms (some ischemic and some epileptic, among others), with the common denominator of mesial temporal lobe dysfunction. In addition to the structural pre-

cipitants noted in this report, transient global amnesia has been related to mitral valve dysfunction, prolapse, polycythemia vera, whiplash injury, and perhaps sexual intercourse. Any attempt at a unifying explanation for its occurrence must consider the usual occurrence in the relatively elderly patient (in contrast to epilepsy and migraine) and the usual lack of recurrence. This case report offers further food for thought.

Robert Hart, M.D.  
*San Antonio, Texas*