

STUTTERING AS A MANIFESTATION OF STROKE

G. A. DONNAN, M.B., B.S.*

Austin Hospital, Heidelberg

Med. J. Aust., 1979, 1: 44-45.

Two cases are described of stuttering as a manifestation of cerebral ischaemia in previously stutter-free individuals. In the first case, stuttering suddenly ceased after carotid endarterectomy; the second patient developed stuttering after a period of three days of complete aphasia after which the stutter gradually improved. Aetiological possibilities are discussed in the light of current theories.

SEVERAL CASES of stuttering as a result of cerebral damage have been reported previously, but rarely in association with stroke, and, to our knowledge, no reported cases have undergone immediate and complete remission after carotid endarterectomy.

CLINICAL RECORDS

CASE 1: The patient was a 65-year-old female pensioner who had no history of childhood stuttering or of speech disturbance. There was no family history of stuttering. There was a past history of 15 years of treated hypertension and documented migraine.

In November, 1976, the patient developed right upper limb transient paraesthesia particularly involving the hand. There was no weakness and she was thought to be suffering from the carpal tunnel syndrome. In January of 1977, she again had an episode of right upper limb paraesthesia that was now associated with both weakness and clumsiness, which lasted for a period of several days. Concurrently, sudden, severe and persistent stuttering commenced. In February, 1977, she experienced an episode of amaurosis fugax in the left eye which lasted for 10 minutes. At this stage she was referred to the Department of Neurology, Austin Hospital. On presentation the stutter was observed to be characterized by rapid easy repetition of the initial sound syllable of every other word. Most frequently this occurred at the beginning of sentences. There were no facial grimaces or sound blocks which are frequently associated with habitual stutterers. Some slight word finding difficulty was also in evidence. Further examination failed to reveal any abnormalities of gnosis or praxis.

She was both right handed and right footed. There were slight right upper motor neurone signs of the right arm and leg, but these did not involve the face, and there was no sensory loss. Blood pressure was 150/80 mmHg, and the pulse was a regular 65 beats/min. There was a loud left carotid bruit and fundi showed grade II hypertensive changes, but there was no evidence of retinal embolism.

Neuropsychological assessment did indicate some fall-off in left hemisphere function. When tested on the Wechsler Adult Intelligence Scale (WAIS), the patient showed considerable difficulty with new verbal material whereas other aspects of verbal memory and over-all performance quotient were adequate. Performance quotient (PQ) was 82, verbal quotient (VQ) was 105, and memory quotient (MQ) was 97. Psychiatric assessment revealed a stable personality type with no suggestion of neurosis. A diagnosis of left cortical infarction, probably of embolic aetiology, was made.

Carotid angiography was performed immediately upon the patient's admission to hospital and revealed a tight left internal carotid stenosis (Figure 1), and mild right internal carotid stenosis with some mild atheromatous ulceration. The results of both EEG and cerebral CAT scan were within normal limits. Routine investigations did not reveal serum lipid abnormalities or evidence of vasculopathy. Left carotid endarterectomy was performed on the third day after admission and revealed subintimal haemorrhage beneath an atheromatous plaque, which resulted in the elevation of the plaque with consequent stenosis clearly seen on angiography. Upon recovering from anaesthesia the patient was found to be completely free from stutter. Postoperative angiogram (Figure 2) showed uninterrupted left carotid blood flow.

Right carotid endarterectomy was carried out two months later, and when reassessed at that time the patient was still found to be completely stutter free and has remained so for the 12 months after the stuttering episode.

CASE 2: A 60-year-old female switchboard operator also had no history of childhood stuttering or of speech disturbance, nor did she have a family history of stuttering. Her past history was unremarkable.

In February of 1978, she developed sudden onset of weakness in the right leg and arm with complete expressive aphasia. There were no sensory symptoms and there was no history of amaurosis fugax. Over the next two days she regained almost complete power in the right hand and leg, but was unable to speak until the third day when her husband noted a marked stutter.

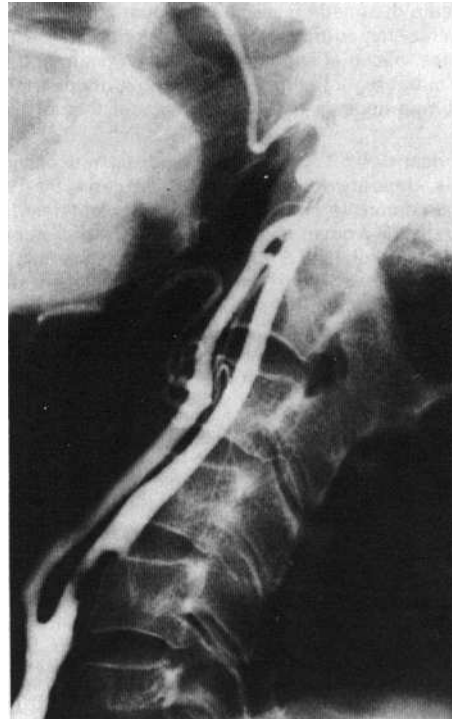

FIGURE 1: Case 1. Left common carotid angiogram preoperatively reveals left carotid stenosis. Plateau elevation of plaque can be seen. This was later found to be due to haemorrhage beneath the plaque.

On March 29, 1978, a further episode of transient right-sided weakness occurred which lasted for approximately one hour. This resulted in an exacerbation of her stutter and led to her admission to Austin Hospital for further investigation on April 11, 1978.

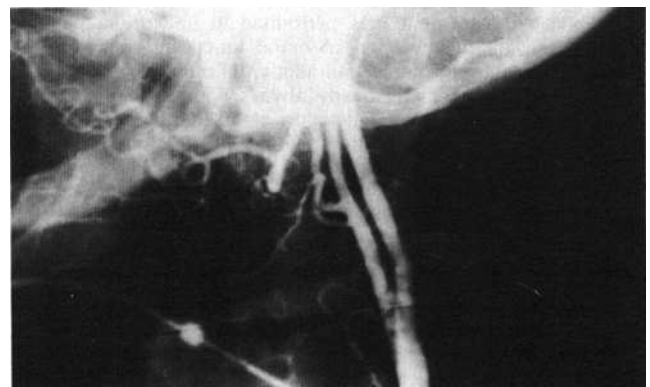


FIGURE 2: Case 1. Postoperative angiogram showing good flow after correction of stenosis.

Examination revealed a well orientated, slightly anxious woman, normotensive (blood pressure 130/70 mmHg) with a regular pulse. She was both right handed and right footed. There was a residual right lower limb cortical weakness, but both plantar responses were flexor. There was no evidence of disturbance of gnosis or of praxis but a marked stutter was

* Neurology Registrar.

Address for reprints: Dr G. A. Donnan, Austin Hospital, Heidelberg, Vic. 3084.

present characterized by repetition of initial phonemes. There was some slight word finding difficulty, but she did not exhibit any of the behavioural signs seen with habitual stutterers. Neuropsychological assessment indicated considerable fall-off in left hemisphere function. Difficulty was found with new verbal memory and recognition. Her Weschler Adult Intelligence scale scores were: VQ, 134; PQ, 97; MQ, 118. Psychiatric assessment revealed a relatively stable personality type.

A diagnosis of left cortical infarction, probably of embolic aetiology, was made. Bilateral carotid angiogram was performed, the results of which were within normal limits. The results of both EEG and CAT scan were also unremarkable. Serum lipid levels were within normal limits, the ESR was not elevated, and testing for antinuclear factor yielded a negative result. During the patient's stay in hospital and subsequent follow-up, the stutter gradually improved, such that repetition of initial phonemes occurred much less frequently, being heard on every third word when she was admitted and decreasing in incidence to only once every dozen words after a period of two weeks.

DISCUSSION

Stuttering is an uncommon presentation of stroke. It has been described on previous occasions by Arend,¹ Canter,² and Quinn and Andrews.³ As far as can be ascertained there have been no reports of complete and sudden remission of stutter and certainly no reference to sudden cessation of stutter after carotid endarterectomy. Neurological stuttering as an entity has been recently reviewed by Quinn and Andrews.³ It is a rare syndrome, not universally recognized by all clinicians, but has been reported after the development of varying cerebral pathologies including thalamotomy, head injury, presenile dementia, and Alzheimer's disease by Quinn and Andrews,³ and after meningitis,⁴ and subdural haematoma.⁵ Canter² in his view of neurogenic stuttering recognized three subclasses:

1. The dysarthric group which may be seen in both Parkinson's disease and cerebellar dysfunction.
2. Apraxic stuttering may be seen more commonly in Broca's aphasia where the problem is one of loss of autonomy in translation of verbal symbols into motor speech pattern.
3. Finally, dysnomic stuttering where the problem is one of word retrieval and is usually in association with aphasia.

However, in spite of the apparent order of the classification, the cause of stuttering remains obscure. Renewed interest has now developed in the Orton-Travis theory^{6, 7} which was first propounded in the 1930s and suggested that stutterers lacked the lateralization of cerebral dominance. Renewed interest in this theory developed in 1966 when Jones⁸ demonstrated that his four cases of stuttering all showed incomplete dominance as shown by intracarotid amygdala hemisphere ablation (WADA testing).

Further work by Walle and Luessenhop in 1971, and also Andrews,³ showed that stutterers have no evidence of bilateral speech representation or of incomplete cerebral dominance. Development of the dichotic word listening test which can establish cerebral speech dominance also suggests that stutterers do not lack cerebral dominance.¹⁰ Early reports that stuttering is more common in left-handed people¹¹ has been refuted by more recent series, and furthermore Andrews and Harris¹² showed that, in a population of left-handed or ambidextrous people, there was no increased incidence of stutterers.

The first case falls into the dysnomic group described by Canter² and the clinical pattern of the development of stutter followed by its sudden and complete remission leads to interesting speculation in the light of current theories. Left cortical infarction probably occurred because of embolism of both platelets and lipid material from the atheromatous left internal carotid artery, and also sudden reduction of left carotid blood flow at the time of the subintimal haemorrhage in the left internal carotid artery. Sudden left cortical damage may have resulted in an element of dysphasia and perhaps an ambivalence of cerebral dominance in a previously left hemisphere dominant person. At this time stuttering commenced. Sudden remission after endarterectomy may have been due to sudden increase in cerebral blood flow to the left hemisphere improving speech function and reversing the state of incomplete cerebral dominance as postulated by Orton and Travis.^{6, 7} Obviously many other factors must be considered as contributing to the remission of stutter, such as emotional changes in the patient wrought by operative intervention and relief at completion of

correction of arterial defect. The situation is an intriguing one, however, and it is of interest that no change in speech was noted after the second operation performed some two months later. It is noted that our patient is right handed and hence she still is most likely to be left hemisphere dominant, since bilateral representation has been very rarely reported in right-handed people. The second case also falls into the dysnomic group and the gradual improvement of the stutter after its sudden onset could be explained by reduction in cerebral oedema and hence some return of neuronal function in the left parietal region. As this occurs, the change in cerebral dominance pattern could also be reverted, as in the initial case, although in a much more gradual fashion. The improvement in stutter also parallels the improvement in dysphasia as noted by Arend.¹

These cases draw attention to a relatively rare presentation of stroke; the sudden onset of stuttering in mature adults may represent the development of underlying ischaemic neuropathology and this cause should seriously be considered by both physicians and speech pathologists.

ACKNOWLEDGEMENTS

I am indebted to Dr Peter F. Bladin, Senior Neurologist, Austin Hospital, for his advice and stimulation in the production of this manuscript, and to Miss Kay Stancombe.

REFERENCES

- 1 AREND, R., HANDZEL, L., and WEISS, B., Dysphatic stuttering, *Folia Phoniat*, 1962, 14: 55.
- 2 CANTER, G. J., Observations on neurogenic stuttering: A contribution to differential diagnosis, *Brit. J. Disor. Commun.*, 1971, 6: 139.
- 3 QUINN, P. T., and ANDREWS, G., Neurological stuttering—A clinical entity?, *J. Neurol. Neurosurg. Psychiat.*, 1977, 40: 699.
- 4 GODA, S., Stuttering manifestations following spinal meningitis, *J. Speech Dis.*, 1961, 26: 392.
- 5 ABBOT, W. E., DUE, O. F., NOSIK, W. A., Subdural haematoma as a result of blast injuries, *J. Amer. med. Ass.*, 1943, 121: 644; 739.
- 6 ORTON, S. T., A physiological theory of reading disability and stuttering in children, *New Engl. J. Med.*, 1928, 199: 1046.
- 7 TRAVIS, L. E., *Speech Pathology*, Appleton-Century-Crofts, New York, 1931.
- 8 JONES, R. K., Observations on stammering after localized cerebral injury, *J. Neurol. Neurosurg. Psychiat.*, 1966, 29: 192.
- 9 ANDREWS, G., QUINN, P. T., and SORBY, W. A., Stuttering: An investigation into cerebral dominance for speech, *J. Neurol. Neurosurg. Psychiat.*, 1972, 35: 414.
- 10 QUINN, P. T., Stuttering cerebral dominance and the dichotic word test, *Med. J. Aust.*, 1972, 2: 639.
- 11 BRYNGELSON, B., Sidendnes as an etiological factor in stuttering, *Proc. Amer. Speech Correction Ass.*, 1932, 2: 91.
- 12 ANDREWS, G., and HARRIS, M., *The Syndrome of Stuttering (Clinics in Developmental Medicine No. 17)*, Heinemann, London, 1964.

Short Papers

STABILITY OF ORAL PANCREATIN POWDERS

Med. J. Aust., 1979, 1: 45-46.

In-vitro study which duplicated the conditions to which the orally administered pancreatin is exposed in the human stomach showed that the oral administration of pancreatin in uncoated powder form could result in a substantial loss of enzymic activity. Therefore, it may not be an efficacious replacement therapy in pancreatic disorders where pancreatin secretion is reduced.

THE STABILITY of the lipase, amylase and protease enzymes in two brands of porcine pancreatin powder, which are currently available as Pharmaceutical Benefits, were examined *in vitro* and the results of these examinations are described here.