

Successful Surgical Treatment of Pontine Vascular Malformation in a 3-Year Old

Case Report

Narayan Sundaresan, Joseph Galicich, George Krol and Gerald Rosen

Department of Neurosurgery and Pediatrics,
Memorial Sloan-Kettering Cancer Center, New York, N.Y.

Key Words. Vascular malformation · Pons · Surgical treatment

Abstract. A 3-year-old male presented with progressive right hemiparesis. Clinical and radiological studies suggested the diagnosis of brain stem glioma. At surgery, a small vascular malformation of the pons was encountered. Although rare, vascular malformations must be considered in the differential diagnosis of brain stem masses.

Introduction

Vascular malformations of the pons are rare and most of them remain asymptomatic during life [2, 25]. These lesions are regarded as hamartomas rather than true neoplasms although there has been a single case report of an intrapontine hemangioblastoma [20]. *McCormick* [18] has suggested that small lesions under 3 cm in diameter should be regarded as 'cryptic' malformations. Cryptic malformations tend to be equally common in the supratentorial and infratentorial compartments; in several autopsy series [18, 27], the pons is the single most common site of telangiectases. Most spontaneous intrapontine hematomas are presumed to be due to small vascular malformations especially in young patients without systemic disease. We wish to record successful surgical treatment in a 3-year-old child presenting with symptoms suggesting a pontine tumor.

Case Report

The patient was a 3-year-old Hispanic male who was admitted to Memorial Sloan-Kettering Cancer Center with a 2-month history of progressive weakness on the right side.

His mother had noted that the child first developed a limp in his right leg. This leg became progressively weaker so that he began crawling upstairs instead of being able to walk normally. This was followed by weakness of the right arm manifest by increasing use of his left hand in reaching for objects although he was ordinarily right-handed. The child also complained of some nonspecific occipital headaches. His past history was unremarkable. The child had been born at term by cesarean section and developmental milestones were normal till the present.

Neurological examination showed a well-developed child who walked with a broad-based gait and an added limp on the right side. His speech appeared appropriate for his age. Cranial nerve examination showed full extraocular movements with no papilledema. There was a mild right facial weakness with deviation of the tongue to that side. The motor examination showed a moderate right hemiparesis with hyperreflexia and a right Babinski. The sensory examination and cerebellar systems were normal.

Plain x-rays of the skull and a technetium pertechnetate brain scan were normal. Computerized tomography (CT) scan showed an increased density on the left side of the pons which enhanced after administration of contrast (fig. 1A, B). Cerebral angiography showed backward displacement of the basilar artery and the anterior pontomesencephalic vein. No tumor blush or abnormal vascularity were noted. A pneumoencephalogram showed non-filling of the left cerebellopontine angle cistern and a slight left-to-right displacement of the proximal fourth ventricle. No hydrocephalus was present.

A posterior fossa craniotomy was performed and at surgery a bluish-colored cyst was

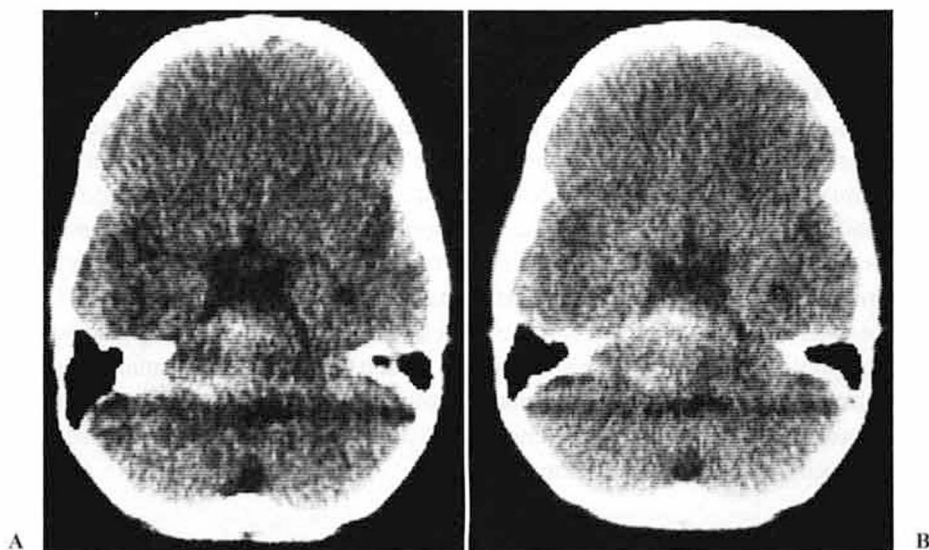


Fig. 1. **A** Preinfusion CT scan showing increased density in left side of pons extending to the cerebellopontine angle. **B** Postinfusion CT scan showing enhancement of density in above-noted pontine lesion.

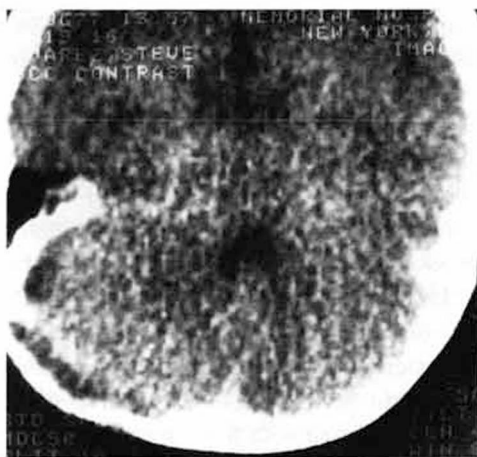


Fig. 2. Postoperative CT scan (with infusion) showing resolution of previous density.

noticed on the ventrolateral aspect of the pons. This was evacuated and 3–4 cm³ of liquefied blood were removed. A biopsy of the wall was taken.

Postoperatively, the child did well with marked resolution of the right hemiparesis over the next few weeks. Repeat CT scanning showed resolution of the previously noted high density (fig. 2).

Permanent sections of the biopsy revealed abnormal collection of blood vessels and connective tissue containing hemosiderin-laden macrophages consistent with a small arteriovenous malformation.

Discussion

Hemangiomas of the pons were first described in 1851 by *Virchow* [27] as an incidental finding at autopsy. The true incidence of these lesions is unknown as most of them are asymptomatic during life and may be missed at autopsy unless a careful search is made.

Teilman [25] reviewed the world literature up to 1953 and was able to find 42 reported cases of vascular malformations of the pons and added 3 of his own. In nearly half of these, the tumors seem to have been telangiectases; one-third were cavernous hemangiomas and the rest were divided between venous hemangiomas and arteriovenous malformations. In his review, 9 patients were asymptomatic during life; 18 had symptoms suggesting diffuse cerebral pathology including dementia, generalized seizures or other mental

symptoms; 4 had focal brain stem as well as diffuse symptoms and only 15 had symptoms suggesting a pontine lesion. In the latter group, he noted a characteristic clinical picture: the course was intermittent with acute or subacute attacks of pontine symptoms; after each of these attacks, the patients recovered although the recovery was incomplete; the disease was most common in young persons or children. Others [1, 6, 13, 23, 26] have noted that these lesions may present with a subacute onset with lower cranial nerve palsies and crossed hemiplegia. Occasionally, a small lesion might obstruct the aqueduct and produce hydrocephalus [2]. Although a subarachnoid hemorrhage was noted in 4 of 7 cases of brain stem angiomas reported by *Logue and Monckton* [14], these lesions were large and cannot be considered true cryptic malformations. In 1 case [15], the clinical course suggested demyelinating disease. Our patient presented with a progressive hemiparesis and this led to the presumptive diagnosis of brain stem glioma elsewhere. While it is not generally appreciated that angiomas of the brain stem may present with progressive neurological deficit, it has been stressed in the French literature [23] that these lesions may present in a 'tumor-like' fashion in young patients.

Although *Logue and Monckton* [14] and *Hierons* [7] have demonstrated brain stem angiomas by angiography, we would agree with *Krayenbuhl and Yazargil* [10] that most cryptic malformations are not detectable by angiography. They may, however, cause enlargement of the brain stem outline on pneumography or on ventriculography. Even with CT scanning, it was not possible to make a correct preoperative diagnosis in our case.

The most important differential diagnosis is that from a pontine glioma. Both lesions are found in childhood and may present with cranial nerve palsies, pyramidal tract signs and ataxia. *Lassman and Arjona* [12] have stated that the diagnosis of brain stem tumors can be made on radiological grounds alone and suggested that radiation therapy be given without biopsy. *Lassiter et al.* [11] stressed the need for surgical exploration in the hopes of finding a neoplastic cyst which could be decompressed. *Matson* [17] suggested exploration in all those cases in which there was a doubt and recommended radiation therapy be given in only those cases with multiple cranial nerve palsies, pyramidal signs and ataxia. Even though symptoms may regress following radiation, this cannot be taken as presumptive evidence of tumor. Several cases have been noted [1, 13] where angiomas regressed temporarily following radiotherapy.

Dandy [5] first reported successful removal of an intrapontine hematoma in 1932 which he speculated was due to a vascular malformation. Since that

time there have been several reports [6, 8, 9, 16, 19, 21, 24, 26] of successful surgical evacuation of brain stem hematomas. Most of these cases were in older patients in whom the onset was either acute or subacute suggesting some form of vascular insult. *Matson* [17] has reported a case in which a blood clot was evacuated from the brain stem, which he presumed was due to an angioma although no further details are given. *Pouyanne et al.* [23] emphasized the need for surgical exploration in young patients presenting with cranial nerve palsies and pyramidal syndromes as these may be due to vascular malformations. We believe our case represents the youngest case in whom successful surgical intervention and histological confirmation was made during life.

Surgical intervention in our case was prompted by the slightly atypical clinical and radiological findings. While pontine hemangiomas are admittedly rare lesions, we would urge that surgical exploration be considered in all those cases with atypical findings before accepting a radiological diagnosis of brain stem glioma.

References

- 1 Bergman, P.S.: Hemangioma of the pons. *Mount Sinai Hosp. J.* 17: 119–131 (1950).
- 2 Courville, C.B.: Angioma of the pons. *Bull. Los Ang. neurol. Soc.* 2: 78–84 (1937).
- 3 Courville, C.B.: Obstructive hydrocephalus incident to small vascular anomaly of midbrain. *Bull. Los Ang. neurol. Soc.* 27: 41–45 (1962).
- 4 Crawford, J.V. and Russel, D.S.: Cryptic arteriovenous and venous hamartomas of the brain. *J. Neurol. Neurosurg. Psychiat.* 19: 1–11 (1956).
- 5 Dandy, W.: Surgery of the brain; in Lewis, Lewis' practice of surgery, vol. 12, pp. 642–643 (Prior, Hagerstown 1932).
- 6 Gros, C.; Giraud, G., and Latour, H.: Hématome spontané de la calotte protubérantielle opéré et guéri. *Presse méd.* 56: 890 (1948).
- 7 Hierons, R.: Brain stem angioma confirmed by arteriography. *Proc. R. Soc. Med.* 46: 195–196 (1953).
- 8 Kempe, L.G.: Surgical removal of an intramedullary hematoma simulating Wallenburg's syndrome. *J. Neurol. Neurosurg. Psychiat.* 27: 78–80 (1964).
- 9 Koos, W.T.; Sunders-Plassman, M., and Salah, S.: Successful removal of a large intrapontine hematoma. *J. Neurosurg.* 31: 690–694 (1969).
- 10 Krayenbuhl, H. und Yasargil, M.G.: Die vaskulären Erkrankungen im Gebiet der Arteria vertebralis und arteria basalis, pp. 125–126 (Thieme, Stuttgart 1957).
- 11 Lassiter, K.R.L.; Alexander, E., jr., and Davis, C.H., jr.: Surgical treatment of brain stem gliomas. *J. Neurosurg.* 34: 719–725 (1971).
- 12 Lassman, L.P. and Arjona, V.E.: Pontine gliomas of childhood. *Lancet* i: 913–915 (1967).

- 13 Lindheimer, J.H. and Barrows, H.S.: Recurrent pontine hemorrhage incident to venous angioma of the pons: report of a case. *Bull. Los Ang. neurol. Soc.* 27: 128–133 (1962).
- 14 Logue, V. and Monckton, G.: Posterior fossa angiomas. *Brain* 77: 252–273 (1954).
- 15 Martin, J.P.: Angiomatous malformations. *Proc. R. Soc. Med.* 44: 845–847 (1954).
- 16 Martin, P.: Operative medullopontine hematoma. *Acta neurol. belg.* 71: 261–268 (1971).
- 17 Matson, D.D.: Surgery of posterior fossa tumors in childhood. *Clin. Neurosurg.* 13: 263–264 (1968).
- 18 McCormick, W.F. and Nofzinger, J.D.: Cryptic vascular malformations of the central nervous system. *J. Neurosurg.* 24: 865–875 (1966).
- 19 Murphy, M.G.: Successful evacuation of acute pontine hematoma. Case report. *J. Neurosurg.* 37: 224–225 (1972).
- 20 Myers, J.; Scott, M., and Silverstein, A.: Cystic hemangioblastoma of pons. *J. Neurosurg.* 18: 694–697 (1961).
- 21 Obrador, S.; Dierssen, G., and Odoriz, B.J.: Surgical evacuation of a pontine medullary hematoma. Case report. *J. Neurosurg.* 33: 82–84 (1970).
- 22 Pool, J.L.: Gliomas in the region of the brain stem. *J. Neurosurg.* 29: 164–167 (1968).
- 23 Pouyanne, M.H.; Grot, M.; Julien, J.; Riemens, V., and Paoli, M.: Two cases of operated intrapontine hematomas: critical study. *Neurochirurgie* 13: 738–742 (1962).
- 24 Scoville, W.B. and Poppen, J.L.: Intrapeduncular hemorrhage of the brain: successful operative approach with evacuation of clot and seven and one-fourth year observation period. *Archs Neurol. Psychiat., Chicago* 61: 618–694 (1949).
- 25 Teilman, K.: Hemangioma of the pons. *Archs Neurol. Psychiat., Chicago* 69: 208–223 (1953).
- 26 Tommasi, M.: Vascular malformation and latero-pontine lipoma. *Neurochirurgie* 9: 440–446 (1963).
- 27 Virchow, R.: Über die Erweiterung kleinerer Gefässe. *Arch. Path. Anat.* 3: 427 (1851).
- 28 White, R.J.; Kernohan, J.W., and Wood, M.W.: A study of fifty intracranial vascular tumors found incidentally at autopsy. *J. Neuropath. exp. Neurol.* 17: 392–398 (1958).

Joseph Galicich, MD, 1275 York Avenue, New York, NY 10021 (USA)