

## CUING AND MEMORY DYSFUNCTION IN ALEXIA WITHOUT AGRAPHIA A CASE REPORT<sup>1</sup>

BY

LOUIS R. CAPLAN<sup>2</sup> AND TESSA HEDLEY-WHYTE

*(From the Stroke Service, Massachusetts General Hospital and the Departments of Neurology and Pathology, Beth Israel Hospital, Harvard Medical School)*

DÉJÉRINE (1892) described the clinical syndrome of alexia without agraphia (pure word blindness) occurring in a man with infarction in the territory of the left posterior cerebral artery. Geschwind (1965) and Geschwind and Fusillo (1966) have recently called attention to and supported the explanation of the syndrome as a disconnexion between the visual input in the right hemisphere and the language region of the left hemisphere. The present case report concerns a patient with alexia without agraphia studied clinically over a three-year period, shown at post-mortem to have an extensive unilateral infarction in the territory of the left posterior cerebral artery. Her capabilities with visual symbols when naming was not required or when prompting or cuing was introduced, may shed some additional light on the nature of the visual defect in alexia without agraphia. Furthermore, this is the first known documented example of a severe memory disturbance lasting for six months related to a unilateral infarction.

### *Case*

In November 1969 a 68-year-old right-handed lady suddenly developed numbness of the right arm. She had had rheumatic fever as a child, and had been admitted to the Massachusetts General Hospital in June 1967, with ankle œdema and dyspnoea, at which time the diagnosis of rheumatic heart disease with mitral insufficiency and congestive heart failure was made. There were no previous neurological symptoms, and her deficit appeared abruptly and without warning after rising. Blood pressure was 140/85, pulse was 90 and regular. There was a pan-systolic mitral apical murmur. No signs of congestive heart failure were present. Neck pulses were normal. No bruits were audible. There was a complete, congruous right hemianopsia without macular sparing. Optokinetic nystagmus was absent to the right. The right corneal reflex was reduced and pain, temperature, and touch perception were diminished on the right face. Pupils and eye movements were normal. Her face was symmetrical. Movements of the right limbs were slow and clumsy but good strength was gradually mobilized at all joints. Deep tendon reflexes were brisker on the right, and both plantar reflexes were extensor. No response to pin, touch, cold, vibration, or alteration

<sup>1</sup>Read in part at the American Academy of Neurology, St. Louis, Missouri, April 27, 1972.

<sup>2</sup>Present Address: Neurology Service, Beth Israel Hospital, Boston, Massachusetts 02215.

of joint position could be elicited in the right limbs. A severe pinch on the right evoked a poorly localized weak tingling sensation.

**Cortical function:** She was alert and spoke normally. She could accurately repeat sounds, words and phrases; spelled normally and identified words spelled to her readily. She wrote slowly and clumsily to dictation with her left hand. Her writing was accurate except for occasional misspellings and mirror writing errors; she correctly copied words, numbers and symbols. She had no difficulty reciting lists or series from memory, e.g. months, colours, flowers, animals. The following higher cortical function deficits were consistently demonstrated while she was in hospital:

(1) **Reading:** She could read no words and incorrectly named written numbers, letters and musical and arithmetical symbols. She wrote but could not later read what she had written nor identify it as her own writing.

(2) **Memory:** She had a profound recent memory disturbance. She could recall having seen the examiner before, but never recalled his name nor where she had seen him even after scores of meetings. At best, she was able to recall one or two facts in a ten-part story after three minutes, but seldom recalled any of the story after ten minutes. Even when given alternative choices in relationship to a story told her ten minutes previously, she could only on rare occasion select one or two facts correctly. She was given repeated batteries of tests in a specially prepared room on twelve different days, but never recalled being in the room before nor doing any of the tests previously.

(3) **Colour naming:** She named correctly only one-fourth of the colours presented to her yet was able to match colours, to name colours of familiar objects, and to name objects that characteristically are of a given colour.

(4) **Visual naming:** She failed to name approximately one-half of objects or pictures of objects presented to her, yet she was able to quickly name the same objects presented tactually to her left hand and to find names for objects described verbally. She used objects in her environment normally. The following are representative responses to large pictures shown her:

A. *Bus*—A map, no, I know it, of course, ought to be able to say it. Not a map.

*What do you do with it?* It's a road, you use it on a road. *Is it a chair, is it a car, is it a horse, is it a bus?* No. *Is it a bus?* It could be a bus, yes, yes, that's what it is, a bus.

B. *Belt*.—Like a map, no, I know what it is, I can't say it. *What do you do with it?* You measure something with it. *Is it a tape measure?* No. *Is it a belt?* Yes, more like a belt.

C. *Banana*—Fruit, it's a measure, no. *What do you do with it?* Eat it. *Is it an apple, a prune, a pear, a banana?* No. *Is it a banana?* No, more like a pineapple.

D. *Bathtub*—It's for water, you measure water with it, a sink, no you have it near a sink like a faucet, a drain, it has another name, I know. *What do you do with it?* Take a bath in it, wash. *Is it a bathtub?* Yes, it could be, yes.

E. *Cane*—It's a drain, a sink, no like a sink. *What do you do with it?* It's a . . . *Is it a cane, a bed, a chair?* No. *Is it a cane?* No.

F. *Cigarette*—A water, it's a water, it's a shadow, a shade. *What do you do with it?* I can't tell you. *Is it a horse, a cigarette, a chair?* No. *Is it a cigarette?* It might be a cigarette.

G. *Clock*—A shade, it's a shade, I know what it is, a shade. *Is it a floor, a table, a clock?* No, it's a shade.

Though she could not name some objects when visually presented, she was able to name the same objects on verbal questioning. For example, to the question what objects would you use to cut your lawn? she replied "lawnmower" or "shears." What would you cut with? "A knife or scissors." Yet she did not name scissors when the object or a picture of the object was shown to her.

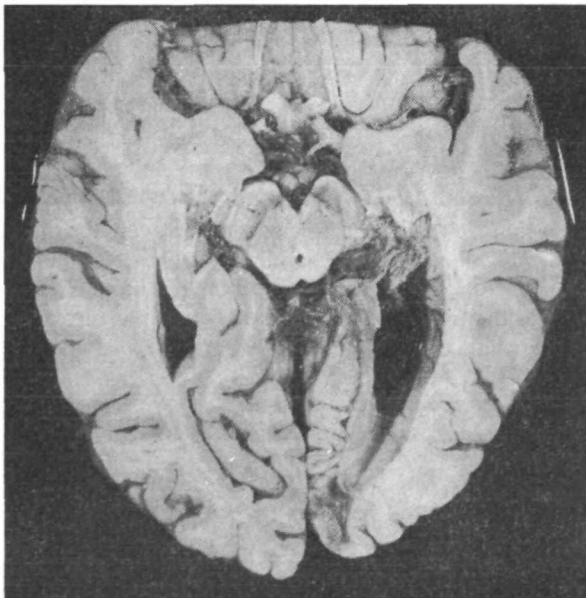
(5) **Right-left confusion, dyscalculia, and finger agnosia** were present. Spontaneous drawings were poorly formed with her left hand, and she copied pictures and matchstick constructions poorly.

**Laboratory tests:** An EEG showed left-sided theta and delta slowing. CSF pressure 130 mm; 28 RBC per c.mm, protein 27 mg per cent, sugar 77 mg per cent. BUN 41, electrolytes normal. Skull X-ray was normal.

**Clinical course:** The constructional dyspraxia, right-left confusion, finger agnosia, dyscalculia, and left Babinski sign cleared within the first month. The profound recent memory disturbance gradually improved. Three months after her stroke, she still could not recall the name of the examiner (L. R. C.) after five minutes, and recalled no facts of a ten-part story after ten minutes. By seven months, she spontaneously reported all four parts of her breakfast ingested hours before, could repeat my name after five minutes, and could repeat seven of ten facts in a story given ten minutes before. She was able to spontaneously recall two out of three names of objects told her five minutes before, and could readily choose the third object if given alternative choices. Subsequent memory testing over the three-year period did not change. She never regained memory of the onset of her illness nor of her first months in hospital. After six months, optokinetic nystagmus responses were symmetrical, though there was no improvement in her complete right homonymous hemianopsia. The remainder of her deficit did not substantially change after the original stroke. She remained at home after discharge from the hospital and was able to do minor household chores. In December 1972 she suddenly became dyspnoeic and had cardiac arrest.

#### *Neuropathology*

At the time of autopsy, which was limited to the cranial vault, the brain was of normal size with minimal atrophy of superior anterior aspects of both frontal lobes. The arteries of the circle of Willis were moderately atherosclerotic but otherwise were within normal limits. The brain was sectioned horizontally and sections were stained with hæmatoxylin and eosin, luxolfast blue, Bodian's stain for axons and phosphotungstic acid-hæmatoxylin. A large old infarct in the distribution of the left posterior cerebral artery extended from the mid-portion of the temporal lobe into the occipital lobe around the calcarine fissure, including the white matter, the splenium, posterior hippocampus and geniculate bodies (fig. 1). The left optic radiation was 1 mm in



**FIG. 1.**—Horizontal section of brain viewed from the base with an old infarct involving the medial aspect of the left occipital and posterior temporal lobe. Note the atrophic left hippocampus and mammillary body and lack of pigmentation of the posterior left substantia nigra. The occipital horn of the left lateral ventricle is markedly dilated. The atherosclerosis of the internal carotid arteries is representative of that seen in the other vessels of the circle of Willis.

greatest width whereas the right optic radiation was 3 mm. A similar aged infarct involved part of the posteroventral lateral nucleus of the left thalamus (fig. 2). The remainder of the left thalamus was unremarkable. The left fornix and mammillary body were markedly atrophic as was the right forceps major of the corpus callosum (figs. 1 and 2). The right thalamus, hippocampus, fornix and mammillary body were grossly and microscopically normal.

No Alzheimer-like changes were found either in the hippocampus or in the multiple sections of cerebral cortex. Other small old infarcts were found in the right parietal (angular gyrus) and occipital lobes and a small recent (week to ten days old) infarct involved the anterior limb of the left internal capsule and putamen at the level of the anterior commissure (fig. 2). The posterior third of the left substantia nigra was pale (fig. 1) and microscopically numerous macrophages were filled with melanin. The remainder of the brain-stem and cerebellum was unremarkable.

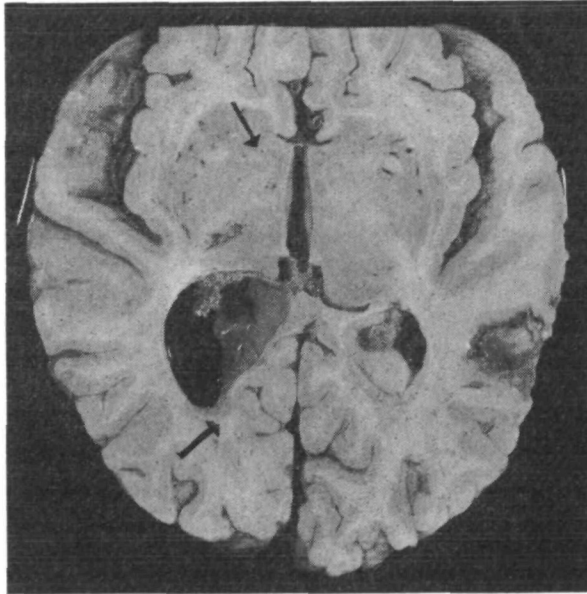


FIG. 2.—Dorsal view of same horizontal section as fig. 1 showing the discoloration and atrophy of the splenium of the corpus callosum extending into the right occipital lobe (thick arrow). The old infarct in the left thalamus is seen together with a more recent infarct in the right parietal lobe and a small acute infarct in the left putamen (thin arrow). Note the absent left fornix and the atrophic left temporal lobe.

#### *Results of Special Cortical Function Investigations*

(1) Capabilities with visual symbols: When presented a letter, word or symbol, she invariably gave a letter name. When given a number, she would also give a letter name unless directed to name a number, in which case she would correctly name approximately 50 per cent of single digits. If the number had a dollar or cents sign, she would then usually give a price name. Repeated testing over a thirty-month period demonstrated that despite her inability to name letters, the patient could:

A. count the number of letters or words present;

B. correctly position individual plastic letters or numbers when these were aligned incorrectly; for example fig. 3:



FIG. 3.

C. correctly order letters alphabetically when a limited number were given (less than 10) despite frequently misnaming aloud the letters as she proceeded with the ordering. For example, P N Q O S R M—→she aligned M N O P Q R S;

D. identify extra letters in a word without being given the word name; for example:

C A T A T. Patient covered the last AT, saying "Boy." "This part doesn't belong."

X E D O G. Covering the XE as being wrong, yet not being able to name the remainder.

E. identify misaligned letters or non letters in words without being given the word name. For example,

B O O X, "The P (the patient pointing to the backward K) is backward."

G O □ D. The patient said the word dog and pointed to the □, saying "That is not right."

G O J D. While pointing to the J, she stated "This is backwards."

F. Complete letters in a word. For example,

E A T=EAT

R A C F - should be RACE (though she read the word as "dog").

(2) Capabilities with words when cuing was introduced: the patient was presented with a list of single words printed in capital letters one below the other (*see* Tables I and II). She would

TABLE I.—PATIENT'S RESPONSE TO A LIST OF WORDS

	<i>Spontaneous reading</i>	<i>Any alike?</i>	<i>Any colours?</i>	<i>Any temperatures?</i>	<i>Select word I say</i>
Red	H	No		Warm	+
Hot	O	No			+
Cold	M	No		Cold	+
Brown	Boy	No	Tan		-
Warm	W	No		Hot	+
Pink	C	No	Tan		-
Yellow	E	No	Brown		+

TABLE II.—PATIENT'S RESPONSES TO A LIST OF WORDS

	<i>Spontaneous</i>	<i>Any alike?</i>	<i>Any flowers?</i>	<i>Any persons?</i>	<i>Select word I say</i>
Red	R	No			+
Rose	R	No	Hyacinth		+
Chair	AH	No			-
Tulip	B	No			-
Boy	HT	No		Boy	+
Daisy	DAT	No	Flower		+

spontaneously proceed down the list giving each word a letter name or series of letter names or volunteering an incorrect word name. She would then be asked a general question, e.g. Are any alike? Later more specific queries, for example, are there any colours? would be directed to her.

On rare occasions, this degree of prompting would be followed by a correctly read word. With the more direct queries, she was often able to point to a word in the correct category despite the fact that she often incorrectly named the word. For example, when seeking a colour, she would point to brown and utter the word tan. When she was then asked even more directly to find the spoken word, she would correctly identify about two-thirds of the words.

## DISCUSSION

Holmes in 1950, and more recently Benson and Geschwind (1969), have reviewed the morbid anatomy in cases of alexia without agraphia. Lesions in the left occipital

lobe, generally in the lingual or fusiform gyri or their subjacent white matter were universally found. In addition, the splenium of the corpus callosum, thalamus, and mesial temporal lobe were often infarcted in the distribution of the left posterior cerebral artery. In our present case, a severe persistent hemisensory loss with incoordination indicated a thalamic lesion in addition to the expected occipital lobe infarction. The clinical diagnosis, an embolus from her rheumatic heart to the proximal left posterior cerebral artery, was consistent with the post-mortem observations. A large infarction had virtually destroyed the left occipital lobe, left mesial temporal lobe, left hippocampal region, and splenium of the corpus callosum. The left fornix and mammillary body were atrophied. No pathological changes were identified in the right temporal lobe or in the right thalamus.

Several aspects of the case merit further comment:

*Gerstmann's syndrome.*—Gerstmann (1930) identified the angular gyrus and occipital convexity as sites where damage might produce finger agnosia, right-left confusion, agraphia, and dyscalculia. He listed the following as symptoms frequently associated with the Gerstmann's syndrome: right hemianopsia, diminished right optokinetic nystagmus, amnesic aphasia, impairment of reading capacity, colour recognizing disturbance, dyspraxia, and disordered equilibrium. Pözl (1937) and Critchley (1953) also have cited cases of parieto-occipital damage producing the Gerstmann's syndrome. It should be emphasized that Gerstmann's syndrome does occur with lesions of the posterior cerebral artery as well as with the more commonly recognized infarction of the angular gyrus occurring with middle cerebral artery disease, producing the alexia with agraphia syndrome. In our case the Gerstmann's syndrome was transient. Posterior lesions may undercut the angular gyrus and produce a more transient Gerstmann's syndrome.

*Amnesic disturbance.*—Bilateral damage in the mesial temporal lobe clearly may produce a severe memory disturbance which is characterized by failure to evoke memories, lack of improvement in performing a new task even after continued practice, and retrograde amnesia with retention of otherwise normal intelligence and verbal skills. Bechterew (1900) was the first to report amnesia as a sign of medial temporal lobe damage produced in his case by bilateral infarction in hippocampus and subjacent white matter. Victor *et al.* (1961) and Van Buren and Borke (1972) report examples of severe, permanent memory disturbance in three patients with bilateral mesial temporal lobe infarctions.

Geschwind and Fusillo (1966) reported a case of alexia without agraphia in which unilateral infarction involving the left occipital lobe, left hippocampal region, and left thalamus had been associated with a transient disturbance of memory lasting seven weeks. Van Buren and Borke (1972) further described and diagrammed the pathology of this case. Mohr *et al.* (1971) reported an example of left hippocampal region infarction producing a severe recent memory disturbance which lasted until death approximately twelve weeks after onset. Geschwind (1965), Geschwind and Fusillo (1966), and Mohr *et al.* (1971) each suggested the possibility that unilateral dominant temporal lobe ischaemia could produce a severe memory disturbance. Our

patient is a further example of severe temporary memory disturbance related to a unilateral temporal infarction; the duration of this disturbance (six months) is the longest reported to date in unilateral temporal infarction unassociated with significant disease of the contralateral temporal lobe.

The thalamus has been thought by some to play an important role in memory function. Victor *et al.* (1961) have argued for the importance of bilateral thalamic lesions in Korsakoff's syndrome. Stimulation in the left lateral thalamus may have an effect on verbal recall performance (Ojemann, Blick and Ward, 1969) giving weight to the speculation that the thalamus may have an alerting function in regard to verbal memory. The cases of Mohr *et al.* (1971), Geschwind and Fusillo (1966), and the present case are all examples of left thalamic dysfunction co-existent with left temporal lobe infarction. Might the unique summation of thalamic and dominant temporal lobe pathology produce a memory disturbance of a degree of severity not found in cases of unilateral temporal lobectomy or unilateral damage limited to the temporal lobe (Milner, 1966)?

*Optokinetic nystagmus.*—Cogan's rule states that in the presence of a hemianopsia produced by an occipital lobe mass lesion, optokinetic nystagmus is reduced to the side of the lesion; but, if the occipital lobe lesion is vascular, symmetrical optokinetic nystagmus is found (Smith, 1963). Ling and Gay (1968) in their analysis of anatomical pathways responsible for optokinetic nystagmus, point out that a lesion in one occipital lobe which extends forward into the corpus callosum to involve fibres from the other occipital lobe would produce asymmetrical optokinetic nystagmus. The reduced optokinetic nystagmus found in our patient may be related to callosal infarction. The patient initially provided an exception to Cogan's rule.

*Visual agnosia.*—An unusual feature of this case was the presence of the syndrome of "associative visual agnosia" as described originally by Lissauer (1890). In this syndrome, in the absence of a severe generalized intellectual disturbance or encephalopathy, the patient has normal visual perception of an object but fails to appreciate its character and meaning; but when appeal is made to another sensory modality such as touch, the patient names and employs the object correctly. The term associative was used by Lissauer to refer to a disorder interfering with connexions between cortical regions as contrasted to "apperceptive visual agnosia" in which there was an interference with the processing of primary visual information. The intactness of our patient's visual perception was demonstrated by normal picture, face, and object matching, and normal diagram copying. Tactile naming of objects was immediate despite the fact that the same objects could not be identified when shown visually. Naming of objects described to her verbally was also intact. Rubens and Benson (1971) have recently reported a case of associative visual agnosia and have reviewed the literature. Their patient had difficulty recognizing faces and visual objects after a hypotensive episode. As in our patient, alexia without agraphia, right hemianopsia, and colour naming deficits were also present. The syndrome which has been called associative visual agnosia thus can be associated with the syndrome of alexia without agraphia, though this is rare. Much recent debate has

centred about the validity of the concept of visual agnosia. Bay (1953) has emphasized the difficulties in assessing "primary visual perception". Teuber (1965, 1968) and Bender and Feldman (1972) have been impressed with the combination of intellectual defects, naming disorders, and altered primary perception in patients with "so-called visual agnosia." Our patient certainly had difficulties with visual objects disproportional to her defect in visual perception, but did not have a pure naming difficulty or a generalized severe intellectual disturbance.

*Number reading.*—The reading of numbers is often preserved in cases of alexia without agraphia. In Déjérine's (1892) original case, number reading was normal. Symonds (1953) and Geschwind (1965) emphasize the sometimes striking preservation of the capability of reading complex numbers in patients with severe letter and word naming defects. Geschwind (1965) speculated that use of somæsthetic features of number concepts (in early life numbers are learned by counting on fingers) could allow the patient to utilize alternate non-visual somatosensory pathways for identification of written numbers. Our patient's inability to name numbers is unusual in the alexia without agraphia syndrome. Could the absence of available somæsthetic pathways in relation to her severe right hemianæsthesia be related?

*Non-verbal visual capabilities with letters and numbers.*—Numerous examples have been given of our patient's non-verbal capabilities with letters, words and numbers. Is this performed by the virtually intact right hemisphere? Data regarding the right hemisphere handling of linguistic material is fragmentary. Dimond, Gibson and Gazzaniga (1972) examined normal patients' capabilities of matching four letter nouns given sequentially in either visual field, and found matching in the left visual field (right hemisphere) equal to that in the right visual field. They speculated that word matching might be done by physical characteristics independent of language. In commissurotomed patients, Teng and Sperry (1973) found essentially correct verbal identification of 20 per cent of letters and 35 per cent of digits presented to the left visual field. Gazzaniga and Hillyard (1971) demonstrated that some commissurotomed patients, when a single noun was flashed to the left visual field, could select with the left hand the correct object from a series of objects placed out of view. In addition, if a simple picture of a boy were shown in the left visual field, some subjects could retrieve a card with the word Boy printed on it, or correctly choose the spoken word "Boy" when a series of alternatives was read aloud. One of their patients could name aloud numbers in the left visual field, though in a delayed fashion. This patient's explanation gives insight into his method: "What I do is to count up until I hit a number that sticks out—then I stop and tell you what it is." Thus this "speech function", i.e. verbal identification, may be done by using matching strategy. The right hemisphere may have some non-verbal capabilities with visual symbols. In addition, the left hemisphere may be able to generate, with the aid of cues, pictures of visual symbols which subsequently can be matched to visual percepts analysed by the right hemisphere.

*Cuing.*—Kreindler and Ionasescu (1961), using a technique they called auditory and visual unblocking, analysed the performance of their patient with alexia without



agraphia who had normal picture naming. Their patient when shown a single picture of an object could correctly choose the correct single written word description from a written list of words, but could not choose the correct picture from a group, when given only a single written word description. Their patient could also select the correct sentence from a group, when the sentence was spoken aloud. The authors suggested that "the pictures of the symbols of language were not destroyed but merely could not be evoked visually".

Kreindler and Ionasescu's patient could read (i.e. select a correct written word from alternatives) when given a verbal language input. Since he was also able to accurately name and describe pictures and give synonyms for spoken words a picture input was similar to giving him a word name. One could interpret the data from their patient and ours, in the language of the disconnection hypothesis, as demonstrating a unidirectional type of disconnection, i.e. visual language input was disconnected from spoken language output but spoken language input was not disconnected from visual selection output. It is possible that many cortical pathways are not representable by equidirectional equilibrium (Geschwind and Fusillo, 1966; Mohr, 1972).

The capabilities of patients when cuing is introduced bring up the important question of why patients are able to perform a task under certain circumstances and not under others. Fatigue, perseveration, lack of co-operation, or other non-specific factors are applicable but may be partially avoided by altering the timing and pace of the examination, and by testing on multiple occasions. Cuing seems to have improved our patient's and Kreindler and Ionasescu's patient's performance reliably and reproducibly. This would be difficult to explain if verbal behaviour was anatomically disconnected from visual behaviour bidirectionally. A unidirectional disconnection is one explanation as outlined above. An alternative idea is that the visual-verbal disconnection is one of interference with the general process of obtaining visual information.

Ramon y Cajal and Polyak (Brindley, 1970) identified anatomically fibres in the optic nerve going to the retina from the central nervous system. Granit (1955, 1962), Brindley (1970) and others have shown that stimulation within the central nervous system can potentiate or inhibit responses of the retinal ganglion cell to light; that is, that there are centrifugal pathways to the primary visual receptor effecting or regulating the stream of afferent impulses. This would be an example of how the brain may be able to help set, tune or filter the mass of incoming sensory data from primary receptors, to help answer specific queries or interests. In the visual sphere, what one sees depends to a great extent on what one "looks for". Tyler (1968) has recently reviewed the interactions between "looking" and "seeing": Luria (1966) has divided the process of visual perception into a step process, the first step of which is scanning of a visual object for a "dominant cue". This cue then allows a definite visual hypothesis to form in which the object is classified into a particular category. Perceived cues continue to evoke a number of alternatives which are explored visually by palpatory eye movements allowing perception of

visual stimuli with continuous checking of changing hypotheses until an answer is reached.

Our patient seemed to have a defect in her spontaneous approach to visual objects, especially written symbols, which at times was helped by verbal cuing. Kreindler and Ionasescu's patient had a similar defect with written symbols. A patient of Albert *et al.* (1973) had a similar defect in spontaneous naming of a written word yet could correctly match words to pictures, choose a word correctly within a spoken semantic category, and could eliminate the single odd word in a group of written words. An insight into our patient's difficulties is given by the patient's own reports early in her course. She had just successfully completed matching a picture of an object in the centre box to its identical counterpart on the periphery. Now instead of a picture, a simple word like "man" or "hen" appeared in the centre of the screen, the task being to match the word with the appropriate picture.<sup>1</sup> She failed on 20 such matches, each time repeating that "nothing looks like the thing in the centre". She did not acknowledge that the thing in the centre was a word, a symbol for something. A patient of Casey and Ettlinger (1960) with alexia without agraphia is quoted as saying, "The words didn't mean anything—the shapes definitely seem familiar. Given Greek and Latin letters mixed, I would have known which were which—the sound belonging to the letters did not get confused, I got stuck on the visual side."

It seems clear that the disorder in alexia without agraphia is a modality specific visual disturbance. The defect in this syndrome may be one of faulty visual tuning, of not "knowing what to look for". In Luria's terms, there may be difficulty in isolating the initial "dominant cue". The fault may be helped by cuing or prompting the patient to seek specific words, sentences, or categories of words. These cues evoke visualized symbols from the left hemisphere speech region which are correctly matched to percepts visualized by the right hemisphere. The left calcarine or paracalcarine cortex, or the thalamus may take part in setting or tuning the visual analyser.

#### SUMMARY

A 68-year-old female with rheumatic heart disease suddenly developed a right hemianopsia, right hemisensory loss, and complete alexia. An embolic occlusion of the left posterior cerebral artery had caused a large infarction involving the left temporal and occipital lobes and their subjacent white matter. A small infarction was seen in the left thalamus. Unusual features of this case included faulty number naming, disordered visual object and picture identification, and a severe defect in recent memory function which lasted six months. Emphasis is placed on the patient's capabilities with visual symbols when naming was not required, and on her behaviour when cuing or prompting was introduced. The defect in alexia without agraphia may involve faulty visual exploration of a written word symbol, and not merely a pure disconnection between visual input in the right hemisphere and the language region of the left hemisphere.

<sup>1</sup>Performed in the Behavior Research Laboratory, Massachusetts General Hospital, under the direction of Dr. M. Sidman.

## ACKNOWLEDGMENT

We acknowledge the advice of Drs. C. Miller Fisher, N. Geschwind, M. Ginsburg, H. R. Tyler, M. Sidman and J. P. Mohr.

## REFERENCES

- ALBERT, M. L., YAMADORI, A., GARDNER, H., and HOWES, D. (1973) Comprehension in alexia. *Brain*, **96**, 317-328.
- BAY, E. (1953) Disturbances of visual perception and their examination. *Brain*, **76**, 515-550.
- BECHTEREW, W. v. (1900) Demonstration eines Gehirns mit Zerstörung der vorderen und inneren Theile der Hirnrinde beider Schläfenlappen. *Neurol. Zentbl.*, **19**, 990-991.
- BENDER, M. B., and FELDMAN, M. (1972) The so-called "visual agnosias." *Brain*, **95**, 173-186.
- BENSON, D. F., and GESCHWIND, N. (1969) The alexias. In: "Handbook of Clinical Neurology." Edited by P. J. Vinken and G. W. Bruyn. Amsterdam: North-Holland, vol. 4, pp. 112-140.
- BRINDLEY, G. S. (1970) "Physiology of the Retina and Visual Pathway." 2nd edition. London: Arnold, pp. 107-115.
- CASEY, T., and ETTLINGER, G. (1960) The occasional "independence" of dyslexia and dysgraphia from dysphasia. *J. Neurol. Neurosurg. Psychiat.*, **23**, 228-236.
- CRITCHLEY, M. (1953) "The Parietal Lobes." London: Arnold, pp. 203-224.
- DÉJÉRINE, J. (1892) Contribution à l'étude anatomo-pathologique et clinique des différentes variétés de cécité verbale. *C. r. Séanc. Soc. Biol.*, **4**, 61-90.
- DIMOND, S. J., GIBSON, A. R., and GAZZANIGA, M. S. (1972) Cross field and within field integration of visual information. *Neuropsychologia*, **10**, 379-381.
- GAZZANIGA, M. S., and HILLYARD, S. A. (1971) Language and speech capacity of the right hemisphere. *Neuropsychologia*, **9**, 273-280.
- GERSTMANN, J. (1930) Zur Symptomatologie der Hirnläsionen im Übergangsbereich der unteren parietal- und mittleren Occipitalwindung. *Nervenarzt*, **3**, 691-695.
- GESCHWIND, N. (1965) Disconnexion syndromes in animals and man. *Brain*, **88**, 237-294 and 585-644.
- , and FUSILLO, M. (1966) Color-naming defects in association with alexia. *Archs Neurol., Chicago*, **15**, 137-146.
- GRANT, R. (1955) Centrifugal and antidromic effects on ganglion cells of retina. *J. Neurophysiol.*, **18**, 388-411.
- (1962) The visual pathway. In: "The Eye." Edited by H. Davson. New York: Academic Press, vol. 2, 537-563.
- HOLMES, G. (1950) Pure word blindness. *Folia psychiat. neurol. neurochir. neerl.*, **53**, 279-288.
- KREINDLER, A., and IONASESCU, V. (1961) A case of "pure" word blindness. *J. Neurol. Neurosurg. Psychiat.*, **24**, 275-280.
- LING, W., and GAY, A. J. (1968) Optokinetic nystagmus: a proposed pathway and its clinical application. In: "Neuro-ophthalmology." Edited by J. L. Smith. St Louis: Mosby, Vol. 4, pp. 117-123.
- LISSAUER, H. (1890) Ein Fall von Seelenblindheit nebst einem Beitrage zur Theorie derselben. *Arch. Psychiat. Nervkrankh.*, **21**, 222-270.
- LURIA, A. R. (1966) "Human Brain and Psychological Processes." New York: Harper and Row, pp. 467-473.
- MILNER, B. (1966) Amnesia following operation on the temporal lobes. In: "Amnesia." Edited by C. W. M. Whitty and O. L. Zangwill. London: Butterworths, pp. 109-133.
- MOHR, J. P., LEICESTER, J., STODDARD, L. T., and SIDMAN, M. (1971) Right hemianopia with memory and color deficits in circumscribed left posterior cerebral artery territory infarction. *Neurology, Minneap.*, **21**, 1104-1113.
- (1972) Personal communication.
- OJEMANN, G. A., BLICK, K. I., and WARD, A. A., Jr. (1969) Improvement and disturbance of short-term verbal memory during human ventrolateral thalamic stimulation. *Trans. Am. neurol. Ass.*, **94**, 72-75.
- PÖTZL, O. (1937) Zum Apraxieproblem. *Jb. Psychiat. Neurol.*, **54**, 133-149.

- RUBENS, A. B., and BENSON, D. F. (1971) Associative visual agnosia. *Archs Neurol., Chicago*, **24**, 305–316.
- SMITH, J. L. (1963) "Optokinetic Nystagmus." Springfield: Thomas, pp. 68–92.
- SYMONDS, C. P. (1953) Aphasia. *J. Neurol. Neurosurg. Psychiat.*, **16**, 1–6.
- TENG, E. L., and SPERRY, R. W. (1973) Interhemispheric interaction during simultaneous bilateral presentation of letters or digits in commissurotomed patients. *Neuropsychologia*, **11**, 131–140.
- TEUBER, H. L. (1965) Somatosensory disorders due to cortical lesions; disorders of higher tactile and visual functions. *Neuropsychologia*, **3**, 287–294.
- (1968) Alteration of perception and memory in man. In: "Analysis of Behavioral Change." Edited by L. Weiskrantz. New York: Harper and Row, pp. 288–375.
- TYLER, H. R. (1968) Looking and seeing and their relation to visual cognition. In: "Neuro-ophthalmology." Edited by J. L. Smith. St. Louis: Mosby, Vol. 4, pp. 249–265.
- VAN BUREN, J. M., and BORKE, R. C. (1972) The mesial temporal substratum of memory. *Brain*, **95**, 599–632.
- VICTOR, M., ANGEVINE, J. B., Jr., MANCALL, E. L., and FISHER, C. M. (1961) Memory loss with lesions of hippocampal formation. *Archs Neurol., Chicago*, **5**, 244–263.

(Received September 19, 1973)