

# "TRANSCORTICAL" FEATURES OF APHASIA FOLLOWING LEFT THALAMIC HEMORRHAGE

Stefano F. Cappa and Luigi A. Vignolo

(Centro di Neuropsicologia, Clinica Neurologica, Milano)

The role of the thalamus in language mechanisms is still little known (Lennenberg, 1967; Ojemann, 1975). The main evidence in this regard comes from studies of language changes due to stereotaxic destruction (Riklan and Levita, 1969) and stimulation (Ojemann, 1977) of thalamic targets. Language disturbances following spontaneous thalamic lesions, both neoplastic (Arseni, 1958; Cheek and Taveras, 1966; Smyth and Stern, 1938) and vascular (Ciemins, 1970; Fazio, Sacco and Bugiani, 1973; Mohr, Watters and Duncan, 1975; Reynolds, Harris, Ojemann and Turner, 1978; Samarel, Wright, Sergay and Tyler, 1976), have also been reported. To our knowledge, there are to-date 15 cases on record of aphasia following vascular lesions of the left thalamus. However, language testing was incomplete in most of them, and localizing procedures were inadequate in some.

We present here the results of a screening for thalamic hemorrhages at the Clinica Neurologica of the University of Milano from September 1976 to June 1978. The main purpose of this note is to describe three cases of aphasia following left thalamic hemorrhage. Clinical records and language testing in these patients were sufficiently detailed to supply evidence of the type of language defect, which presented some striking similarities with the so-called "transcortical" aphasias.

## MATERIALS AND METHODS

The clinical records and CT scan photographs of 160 patients with intracerebral hemorrhages, hospitalized in the Neurological and Neurosurgical Departments, were analysed. The site and extent of the hemorrhage was assessed by means of an EMI scanner CT 1000 with water bag. A standard CT scan procedure yields eight Polaroid pictures, each representing a 13 mm thick horizontal section of the head. Aphasia was assessed in all cases by a clinical, non formal bedside language examination, and, whenever possible, by a standard language examination currently used at our Aphasia Unit. This provides a quantitative score of performance on the main aspects of language, such as oral expression, auditory verbal comprehension, repetition, written expression, reading comprehension, reading aloud, dictation and copying — as well as a qualitative record of the type of speech errors. The standard examination was supplemented

by the Token Test (TT) (De Renzi and Vignolo, 1962) in a shortened, 36 items form (De Renzi and Faglioni, 1978), the Performance Scale of the WAIS, Raven's Coloured Progressive Matrices (PM), and by apraxia tests, yielding scores on the patient's ability to carry out oral and intransitive upper limb movements on imitation, to show the use of actual objects, and to copy geometrical drawings.

## RESULTS

Seventeen thalamic hemorrhages were found, nine on the left and eight on the right side. Three of them (one left, two right) were excluded due to incomplete clinical records. The relevant neurological data of the remaining 14 cases are summarized in Table I. Aphasia was present in all patients with left thalamic hemorrhage except one (case 8), while it was absent in all patients with right thalamic involvement, two of whom had a mild, transient dysarthria. Four patients of the left group underwent a non-quantitative language examination at the bedside; standard testing could not be administered for a number of reasons (confined to bed, worsening of general condition shortly after admission etc.). The findings of the complete standard language examination and supplementary tests were available for three patients, cases 1, 2 and 3, who will be described in detail.

### *Case 1*

A 62 year old right-handed housewife with eight years of schooling was hospitalized on October 4, 1977. The previous day, while cooking, she suddenly fell to the ground, lost control of sphincters and vomited. There was no loss of consciousness. A relative noticed loss of strength on the right side of the body and brought her to the hospital. Her past medical history was not contributory, except for arterial hypertension of a few years duration.

On admission, her blood pressure was 215/130. On neurological examination, the patient was cooperative, but slightly drowsy, showing a severe reduction of spontaneous speech, adequate naming of common objects (with neither anomias nor paraphasias) and apparently intact comprehension. Extreme expressive inertia despite prompting by the examiner was the main characteristic of her verbal behavior. There was a right spastic hemiparesis, more marked in the arm, with increased deep tendon reflexes but no clear cut Babinski sign. No visual field or sensory defect was found.

The standard language examination was administered four days post-onset. The subtest scores are shown in Table II.

Oral expression lacked initiative and was markedly reduced, without, however, disorders of articulation. Description of an event (how to cook spaghetti) was extremely poor. Single word choice, though generally acceptable, was rather vague, with occasional semantic paraphasias, e.g. "plate rack" for "colander". Words were combined in short, syntactically correct but scarcely informative sentences. There were no phonemic errors. The patient tended to stop talking after every utterance, and continuous prompting by the examiner was necessary. On visual naming of realistic pictures, she gave 65 per cent correct responses, with a few anomic errors and semantic paraphasias. Automatic sequences (numbers from one to 20, days of the week, months) were intact. Auditory

TABLE I  
Main Clinical Features of 14 Patients with CT Scan Evidence of Thalamic Hemorrhage\*

	Left thalamic hemorrhage (N = 8)								Right thalamic hemorrhage (N=6)					
	1	2	3	4	5	6	7	8	9	10	11	12	13	14
Patient No.	1	2	3	4	5	6	7	8	9	10	11	12	13	14
Age	62	76	65	45	74	82	71	76	82	49	66	76	56	64
Sex	F	M	F	F	F	F	F	M	F	F	F	F	M	M
Time from onset to CT scan	7	5	17	4	3	5	13	10	23	20	3	2	18	3
Disturbance of consciousness	+	-	-	+	+	+	-	-	-	-	-	-	-	+
Aphasia	+	+	+	+	+	+	+	-	-	-	-	-	-	-
Dysarthria	-	+	-	-	-	-	-	-	+	-	-	+	-	-
Visual field defect	-	+	-	?	+	+	?	-	-	-	-	-	+	+
Gaze disturbance	-	-	+	+	+	+	-	-	+	-	-	-	-	-
Motor defect	+	+	+	+	+	+	+	+	+	+	+	+	+	+
Sensory defect	-	-	-	?	-	+	+	+	+	-	+	+	+	+

\* Disturbance of consciousness (on admission) varied from mild drowsiness to coma (case 4). Gaze disturbances ranged from lateral deviation to the side of the lesion to failure of upward gaze. Findings on sensory defect should be evaluated with caution, as impaired vigilance sometimes prevented a reliable assessment.

TABLE II  
*Standard Language Examination and Token Test Scores\**

	Case 1	Case 2	Case 3
Oral expression			
Description of an event	0	0	0
Naming	65	62	60
Automatic sequences	100	100	100
Auditory comprehension			
Words	87	75	45
Semantically related words	65	37	60
Oral commands	90	70	55
Token Test	44	47	58
Repetition			
Letters	100	100	95
Syllables	100	100	90
Words	100	82	100
Sentences	100	90	80
Written expression			
Signature	+	—	—
Naming	7	22	0
Writing a letter	0	0	0
Reading comprehension			
Words	82	85	12
Semantically related words	95	42	0
Written commands	100	100	0
Reading aloud			
Letters	95	90	0
Syllables	100	65	0
Words	100	100	0
Sentences	100	80	0
Dictation			
Letters	80	90	0
Syllables	90	10	0
Words	55	20	0
Sentences	90	0	0
Copying			
Words	80	30	0
Transcription from print to script	85	25	0

\* All scores are expressed in percentages of correct responses, except Description of an event and Writing a letter scores which range from 0 to 3 and Signature which is marked +/— (correct/incorrect). For a qualitative description of speech errors, see text.

comprehension of single words, evaluated by means of a picture pointing task, was better for unrelated than for semantically related words (87 vs. 65 per cent).

Carrying out oral commands (of the type “knock on the table”) was virtually perfect (90 per cent) while performance was distinctly less efficient on the Token Test (16/36). Repetition was perfect for letters, syllables, words and sentences. Writing was extremely poor: when asked to write a letter home she merely

traced a few, partly incomprehensible words and then refused to go on. Written naming was defective in 83 per cent of responses, due to motor execution defects, misspellings and a few verbal paraphasias. She could write her name. Reading comprehension and reading aloud were comparable to repetition. On dictation, the patient did well for letters, syllables and sentences, but failed in half of the words. Copying was fair (80 per cent), and so was transcription from print to script (85 per cent). Performances on the WAIS (P.I.Q. = 93) and on Raven's PM (26/36) were within the expected range for a patient with mild aphasia. The apraxia tests were carried out without errors.

CT scans were performed seven and 24 days post-onset (Figure 1): a small left thalamic hemorrhage, encroaching into the adjacent internal capsule, was present. The well-known changes in lesion density due to time elapsed since onset

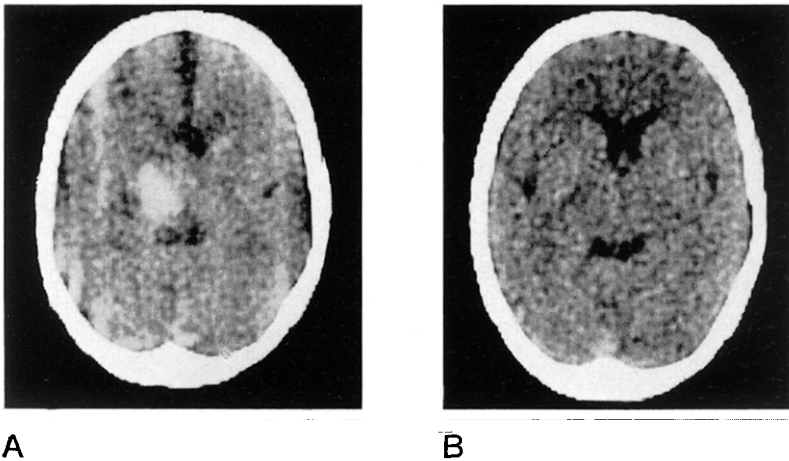


Fig. 1 — Case 1. CT scan pictures showing left thalamic hemorrhage at different times post-onset; A, 7 days. B, 24 days.

(Bergström, Ericson, Levander, Svendsen and Larsson, 1977) are apparent in the figure. Such changes, however, do not correspond to significant variations in lesion size (Caillé, Constant, Dop, Latinville, Laporte and Henry, 1976).

The aphasic disorder showed marked spontaneous recovery. A repeat language examination 24 days post-onset disclosed improvement of oral expression and spontaneous writing; therefore, language therapy was considered unnecessary. The patient was discharged 38 days post-onset. Three months later she was examined again at the outpatient clinic. A mild right hemiparesis was still present. She did not complain of any language problem in everyday life and was not aphasic (TT score = 33/36). On Raven's PM she scored 28/36.

#### Case 2

A 76 year old right-handed retired clerk with 11 years of schooling was hospitalized on July 15, 1978. In the morning of the same day he suddenly fell

to the ground without losing consciousness. The relatives reported that "his mouth was twisted, he could not stand and mumbled incomprehensibly". Past medical history was not contributory. On admission, the patient was alert, aphasic and had a right-sided spastic hemiparesis, with increased deep tendon reflexes and a Babinski sign. There was a right homonymous hemianopia on confrontation. No gross sensory deficit was found. Blood pressure was 180/90.

The standard language examination was administered four days post-onset. The subtest scores are shown in table 2. Oral expression was markedly reduced, with frequent perseverations and echolalic repetitions of the examiner's words. Occasional slurring of speech was noticed. On visual naming he gave 62 per cent correct responses, with anomias, semantic paraphasias and perseverations. Automatic sequences were preserved. On the picture pointing task, the patient kept repeating the stimulus word to himself while looking for the appropriate picture, and gave 75 per cent correct responses. He could carry out 70 per cent oral commands; the TT score was 17/36. Repetition was excellent, but for some articulatory distortions. Writing was severely impaired. When asked to write a letter home he stopped after a few words ("I am well I am very well") and refused to go on. The signature was unintelligible, and so were most of the words on the written naming task.

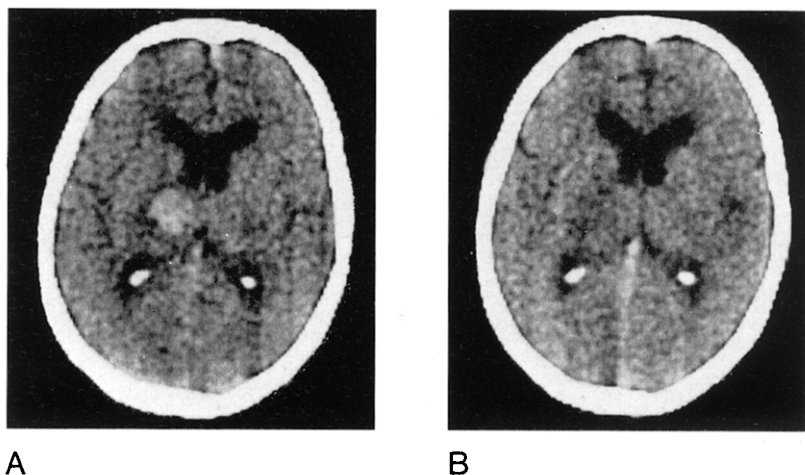


Fig. 2 — Case 2. CT scan pictures showing left thalamic hemorrhage 5 (A) and 18 (B) days post-onset.

Reading comprehension and reading aloud were sufficient. Dictation was possible for single letters only (90 per cent). Copy and transcription from print to script were poor. His P.I.Q. on the WAIS was 81, on Raven's PM he scored 12/36. He showed neither oral nor limb apraxia. Copying of geometrical drawings was correct.

CT scans were performed five and 18 days post-onset (Figure 2); a hemorrhage involving the left thalamus and internal capsule was apparent, showing the expected reduction in lesion density according to time post-onset.

A repeat language examination 24 days post-onset disclosed a slight

improvement in oral expression and auditory verbal comprehension (100 per cent of words, 100 per cent of oral commands, TT 21/36). On Raven's PM he scored 17/36. The patient was discharged 26 days post-onset, and attended our Aphasia Unit for language therapy as an outpatient for three months, showing only a slight improvement; then he moved to another town.

### *Case 3*

A 65 year old right-handed housewife, with three years of schooling, was hospitalized on September 17, 1977. The previous day she suddenly fell to the ground, without losing consciousness. The relatives noticed that she was confused and had difficulty expressing herself. She had been suffering from mild hypertension for several years, and two years before she had been hospitalized due to a transient right hemiparesis and aphasia.

On admission, she was alert but disoriented for time and space. Speech was fluent with several paraphasias and comprehension was impaired. She had right spastic hemiparesis with increased deep tendon reflexes and a positive Babinski sign, reduced response to pin prick on the right side of the body and right homonymous hemianopia.

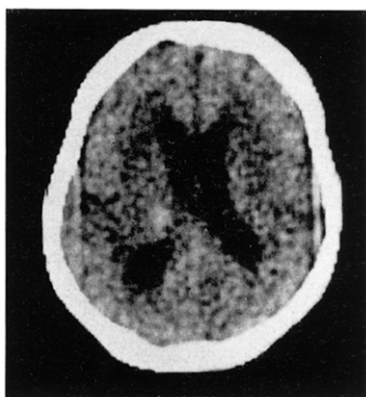

Fig. 3 — Case 3. CT scan picture showing left thalamic hemorrhage 17 days post-onset.

The standard language examination was administered 13 days post-onset. The results are summarized in Table II. Oral description of an event was scanty with marked inertia in the foreground and a mild tendency to perseveration. Prompting by the examiner was necessary after nearly every sentence. There were no phonemic errors. Visual naming was impaired by anomias and verbal paraphasias. Automatic sequences were intact. Auditory verbal comprehension was moderately defective; the TT score was 21/36. By contrast, repetition was strikingly good for letters, syllables, words and sentences. On occasions, the patient displayed echolalia. Performance on the written language subtests was nil. She was unable to perform the WAIS and obtained score 3/36 on Raven's PM. Marked apraxic difficulties in imitating limb movements and in demonstrating the use of actual objects were present. Copying geometrical drawings was also defective.

A CT scan was performed 17 days post-onset, showing a left thalamic hemorrhage undergoing reabsorption (Figure 3).

The clinical course of the patient was stormy, with bouts of agitation alternating with stupor. A repeated language examination 32 days post-onset showed slight improvement of oral expression, but no changes in the remaining aspects of verbal behavior. The patient's condition ran a progressively downhill course and she died shortly afterwards.

## DISCUSSION

This study indicates that thalamic hemorrhage accounts for 10.6 per cent of all intracerebral hemorrhages demonstrated by CT scan; this figure agrees on the whole with those of Miller Fisher (1959) (13 per cent), and Fazio et al. (1973) (8 per cent). Aphasia was present in seven out of eight patients with left lesions, while it was consistently absent in six patients with right lesions.

The main features of aphasia associated with left thalamic hemorrhage in the three cases with detailed testing were reduction of spontaneous speech, preserved repetition and varying degrees of auditory comprehension impairment. Marked inertia was present in two cases (1 and 3). Writing was grossly defective in all three patients, while reading impairment was marked in case 3 only: low educational level, however, can probably account for this finding. In case 1, detailed assessment of written language showed a clear-cut dissociation between poor spontaneous writing and good dictation and copying.

We cannot draw any conclusion from our patients as to prognosis. Case 1 recovered spontaneously in about one month, case 2 has been followed only for three months, and case 3 died in little over one month. Speech disorders following left unilateral thalamotomy for Parkinson's disease tend to recover quite well (Riklan and Levita, 1969), and this has led to the common view that the prognosis for thalamic aphasia is always good. Although several cases of aphasia following left thalamic hemorrhage have recovered completely or have been left with mild disorders, some reports suggest that persistent language deficits may occur (Fazio et al., 1970; Mohr et al., 1975; Reynolds et al., 1978; Samarel et al., 1976). Whether the overall prognosis is better than for other forms of aphasia will be determined only as more cases are collected.

The clinical picture in our three patients is similar to that of the classical "transcortical" aphasias, associated with lesions of the marginal language zones (i.e. frontal lobe anterior to Broca's area, temporo-parieto-occipital junction posterior to Wernicke's area). Good repetition, with little or no phonemic paraphasias in spontaneous speech (Vignolo, 1968) and occasional echolalias are typical features of the "transcortical" aphasias, while poor repetition is usually seen in lesions of the central language zones which lie along the sylvian fissure (Benson and Geschwind, 1971). Among the cases of thalamic aphasia described in the literature, repetition was impaired in one case only (Luria, 1977), in whom, however, deep brain structures other than the thalamus had been damaged by surgery.

The presence of these "transcortical" features following left thalamic hemorrhage suggests that the integrity of the thalamus is not crucial for intentional repetitive speech and the phonemic level of verbal behavior. It would rather appear that the linguistic role of the thalamus is related to that of the marginal language areas, which presumably subserve the use of words as meaningful units.



## SUMMARY

In a series of 14 thalamic hemorrhages documented by Computerized Axial Tomography (CT) scans, aphasia was present in seven out of eight patients with left lesions while it was absent in the six patients with right lesions. In three cases where detailed language testing was performed, aphasia was characterized by reduction of spontaneous speech with semantic paraphasias, preserved repetition and partially defective auditory verbal comprehension. The language disturbance was persistent in two patients, while it recovered spontaneously within four weeks in one patient. The clinical picture in these patients is similar to the classical "transcortical" aphasias, which are usually due to damage of the marginal language areas. It is suggested that the left thalamus contributes to the semantic level of verbal behavior, which is possibly subserved by these areas.

*Acknowledgement.* We wish to thank Dr. Norman Geschwind for his helpful suggestions on the manuscript.

## REFERENCES

- ARSENI, C. (1958) *Tumors of the basal ganglia*, A.M.A. Arch. Neurol. Psychiat., 80, 18-26.
- BENSON, D.F., and GESCHWIND, N. (1971) *The aphasias and related disturbances*, in Clinical Neurology, ed. by A.B. Baker and L.H. Baker, Harper and Row, Hagerstown.
- BERGSTRÖM, M., ERICSON, K., LEVANDER, B., SVENDSEN, P., and LARSSON, S. (1977) *Variation with time of the attenuation values of intracranial hematomas*, J. Computer Assisted Tomography, 1, 57-63.
- CAILLÉ, J.M., CONSTANT, P., DOP, A., LATINVILLE, D., LAPORTE, A., and HENRY, P. (1976) *Accidents vasculaires cérébraux, aspects évolutifs*, J. Neuroradiol., 3, 297-312.
- CHEEK, W.R., and TAVERAS, J. (1966) *Thalamic tumors*, J. Neurosurg., 24, 505-513.
- CIEMINS, V. (1970) *Localized thalamic hemorrhage. A cause of aphasia*, Neurology, 20, 776-782.
- DE RENZI, E., and VIGNOLO, L.A. (1962) *The Token Test: a sensitive test to detect receptive disturbances in aphasics*, Brain, 85, 665-678.
- , and Faglioni, P. (1978) *Normative data and screening power of a shortened version of the Token Test*, Cortex, 14, 41-49.
- FAZIO, C., SACCO, G., and BUGIANI, O. (1973) *The thalamic hemorrhage*, Eur. Neurol., 9, 30-43.
- LENNENBERG, H.E. (1967) *Biological Foundations of Language*, Wiley, New York.
- LURIA, A.R. (1977) *On quasi-aphasic speech disturbances in lesions of the deep structures of the brain*, Brain Lang., 4, 432-459.
- MILLER FISHER, C. (1959) *The pathological and clinical aspects of thalamic hemorrhage*, Trans. Am. Neurol. Assoc., 84, 56-59.
- MOHR, J.P., WATTERS, W.C., and DUNCAN, G.W. (1975) *Thalamic hemorrhage and aphasia*, Brain Lang., 2, 3-17.
- OJEMANN, G.A. (1975) *Subcortical language mechanisms*, in Studies in Neurolinguistics, ed. by H. Whitaker and H. Whitaker, vol. 1, Academic Press, New York.
- (1977) *Asymmetric function of the thalamus in man*, Ann. N.Y. Acad. Sci., 299, 380-396.
- REYNOLDS, A.F., HARRIS, A.B., OJEMANN, G.A., and TURNER, P.T. (1978) *Aphasia and left thalamic hemorrhage*, J. Neurosurg., 48, 570-574.
- RIKLAN, M., and LEVITA, E. (1969) *Subcortical Correlates of Human Behavior*, Williams and Wilkins, Baltimore.
- SAMAREL, A., WRIGHT, T.L., SERGAY, S., and TYLER, R.H. (1976) *Thalamic hemorrhage with speech disorder*, Trans. Am. Neurol. Assoc., 101, 283-285.
- SMYTH, G.E., and STERN, K. (1938) *Tumors of the thalamus: a clinico-pathological study*, Brain, 61, 339-374.
- VIGNOLO, L.A. (1968) *The relationship between the repetition defect and the type of speech errors in fluent aphasia: cross sectional and longitudinal findings*, in Proceedings of the Conference on Language Retraining for Aphasics, ed. by J.W. Black and E.G. Jancosek, Ohio State University (mimeographed).