

Clinical and scientific communications

Cerebellar Infarction

Michael P. Feely, M.Ch.

Department of Neurosurgery, College of Medicine, University of South Alabama, Mobile, Alabama

Cerebellar infarction has been inadequately recognized by clinicians. A review of 75 cases showed that in 55 of them the infarct acted as an expanding mass lesion and compressed the brain stem. Once this occurred, the mortality without operation was very high. With surgical treatment, the mortality was reduced considerably. The computerized tomographic scan is the diagnostic test of choice.

Key words: Brain stem compression, Cerebellar infarction, Computerized tomographic scan, Emergency surgery, Posterior fossa mass

Infarction in a cerebellar hemisphere is considered to be a rare occurrence. Three cases have been treated recently by the staff of the Department of Neurosurgery at this university. These, together with 20 case reports from the literature (3, 4, 9, 10, 12, 15) and a large series (13) in which the diagnosis was made at postmortem examination, provide 75 cases for analysis.

Two distinct clinical syndromes have been described in the literature. The first is cerebellar infarction with brain stem compression (9). In this syndrome infarcted cerebellar tissue acts as a rapidly expanding posterior fossa mass lesion, signs of brain stem compression develop, and the outcome almost invariably is fatal unless surgical intervention alters the course. The second type of cerebellar infarction is described as being in the territory of the posterior inferior cerebellar artery (PICA) (3) and it is apparently more benign, resembling acute labyrinthitis. The symptoms may resolve spontaneously.

This distinction may be both artificial and dangerous. Patients presenting to the internist, family physician, or otolaryngologist with symptoms and signs of benign labyrinthitis may progress in hours or days, developing signs of brain stem compression. When this happens, unless the diagnosis is made correctly and prompt action is taken, the mortality is exceedingly high. Although the diagnosis is possible on clinical grounds, it may be very difficult and apparently has been overlooked frequently. The computerized tomographic (CT) scan has proved invaluable in making the diagnosis.

My analysis and discussion center on 55 patients who developed signs of brain stem compression. A brief mention is made of 20 additional cases of cerebellar infarction, including Case 3, in which signs of brain stem compression did not occur.

CASE REPORTS

Case 1

An 18-year-old woman was admitted to the hospital with drowsiness and slurred speech. She had been in good health and had been taking a low dose contraceptive pill for 15 months before admission. No focal neurological findings were detected. A lumbar puncture was performed and showed clear fluid (cells, 0; protein, 40 mg/100 ml) with an opening pressure of 160 mm of cerebrospinal fluid (CSF).

The next day, the patient remained drowsy but would answer

simple questions. Except for her eyes, which were deviated to the right, the patient had full voluntary movement to command. The eyes did not move on cold caloric irrigation in the ears. There was unsustained clonus at the right ankle.

Over the next 3 hours, the patient's condition deteriorated. She ceased to follow commands, and decerebrate posturing on stimulation appeared on the right side. Four-vessel cerebral angiograms showed no abnormality. The next morning decerebrate posturing was present bilaterally on stimulation. Her eyes were in midposition, and the pupils were small and minimally reactive to light. A CT scan showed a large infarct in the left cerebellar hemisphere (Fig. 1).

An emergency suboccipital craniectomy was performed. The left cerebellar hemisphere was swollen and friable. The cerebellar tonsil was herniated to the level of the arch of C-1. A subtotal resection of the cerebellar hemisphere was performed on the left side and included the tonsil. Only a thin rim of tissue around the outer margin of the hemisphere was left. Histological examination confirmed the diagnosis of cerebellar infarction.

Postoperatively, the patient made an uneventful recovery, and she has resumed her previous occupation as a housewife without any disability.

Case 2

This previously healthy 63-year-old woman developed recurrent episodes of dizziness for 1 week before admission to the hospital. She was admitted complaining of severe headaches and dizziness of 24 hours duration. On physical examination, the patient was drowsy but responsive to command. Her pupils were small and reacted feebly to light. Her eyes were in fixed conjugate deviation to the left. There was a moderate symmetrical hyperreflexia.

Lumbar puncture revealed clear spinal fluid (protein, 36 mg/100 ml; red blood cells, 0/cu mm; monocytes, 6/cu mm) with an opening pressure of 410 mm of CSF.

The next day a ventriculogram was performed. This demonstrated that the 4th ventricle was displaced forward and to the left, suggesting a mass in the right cerebellar hemisphere.

An emergency suboccipital craniectomy was performed. The right cerebellar hemisphere was enlarged, soft, and partially liquified. The cerebellar tonsil had herniated down to the level

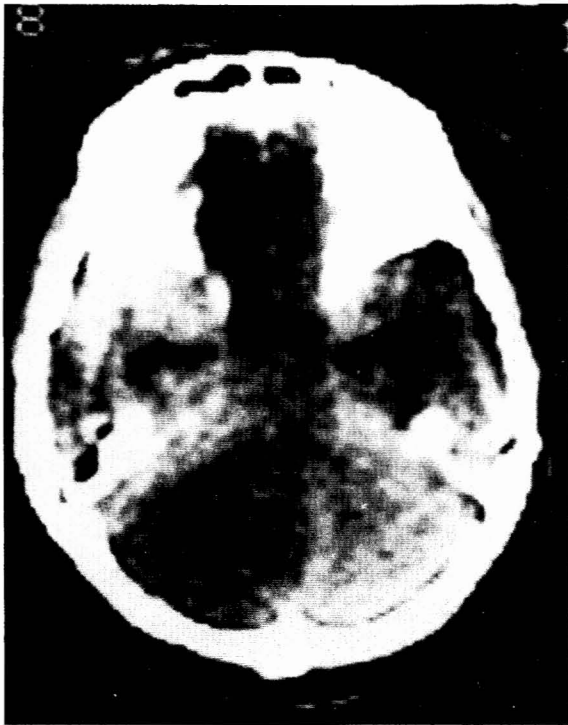

FIG. 1. Case 1. CT scan showing a massive left cerebellar infarction. Comparison between the right and left cerebellar hemispheres shows a large, low density area in the left cerebellar hemisphere.

of the arch of C-2. The infarcted tissue was resected. Histological examination confirmed the diagnosis of cerebellar infarction.

The patient made an uneventful recovery.

Case 3

This 66-year-old woman had previously been in good health. She stood up to cross a room and immediately experienced a severe attack of vertigo and fell to the floor. She was admitted to the hospital, where she complained of constant vertigo and inability to stand.

Physical examination revealed acute distress with frequent vomiting. There was rotary nystagmus on right lateral gaze. The patient was unable to stand unaided. There was no dysmetria of the arms, but heel to shin testing revealed bilateral dysmetria of the legs.

A diagnosis of acute labyrinthitis was made. The patient was treated with bedrest, and her symptoms cleared sufficiently so that she could be discharged from the hospital 6 days after admission. She was seen again in the outpatient clinic 3 weeks later, when examination demonstrated a marked cerebellar ataxia and inability to walk without support. The initial diagnosis of acute labyrinthitis was thought to be incorrect, and the patient was readmitted to the hospital; a CT scan demonstrated an infarct in the right cerebellar hemisphere. The patient made a full recovery during the next 3 months.

ETIOLOGY

Based on the pathological investigations by Sybert and Alvord (13), the majority of cases of cerebellar infarction seem to be secondary to arteriosclerotic arterial occlusion. In their study of 28 patients dying acutely after cerebellar infarction, the vertebral or posterior inferior cerebellar artery was occluded

in approximately 90% of cases. A superior cerebellar artery occlusion occurred in approximately 10% of cases. Twenty-two per cent (6 of 28) of these occlusions were embolic, as were 2 of 3 cases in another series (3). As would be expected in this series, because the majority of patients were in the older age group, a number of them had other manifestations of occlusive vascular disease, particularly cerebral and cardiac. Other factors were: pre-existing hypertension, 16 cases; diabetes mellitus, 5 cases; polycythemia, 2 cases; and the contraceptive pill (2, 14), 1 case.

CLINICAL FINDINGS

The age and sex distributions of the clinical series (21 cases of cerebellar infarction with brain stem compression) are depicted in Figure 2. All patients with cerebellar infarction presented initially with the rapid onset of vertigo and ataxia. Many also had headache and vomiting. One of three courses then followed.

1. Rapid onset of brain stem compression occurred, manifested by alteration of consciousness, long tract motor signs, and oculomotor or gaze palsies that began within 24 hours of the onset of the symptoms (Case 1).

2. The onset of brain stem compression was more delayed, developing between 24 and 96 hours after the onset of symptoms. The manifestations were essentially the same as those of the first variety; once brain stem compression occurred, deterioration could be rapid (Case 2).

3. Cerebellar infarction mimicked a benign labyrinthine disorder, with the sudden onset of vertigo, ataxia, vomiting, and nystagmus. Brain stem compression did not develop, and recovery was the rule (Case 3).

The "motor" abnormalities that developed in the 21 clinical cases with signs of brain stem compression are outlined in Table 1.

Detailed lists of different physical findings have been compiled (9, 13). However, the physician must consider cerebellar infarction in the differential diagnosis of any patient presenting with ataxia and dizziness and a course suggestive of a rapidly expanding posterior fossa mass lesion; the physician will find this to be a more useful and practical approach than trying to remember a detailed analysis of occasional findings.

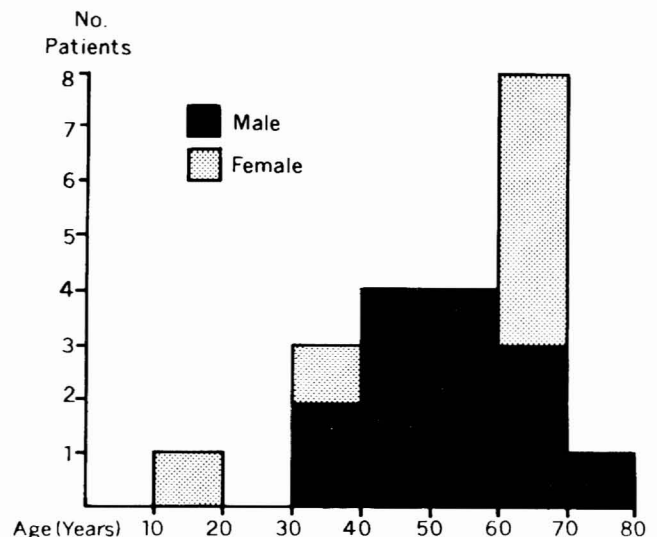


FIG. 2. Cerebellar infarction with brain stem compression. Age and sex distributions of 21 clinical cases.

TABLE 1
 "Motor" Abnormalities among 21 Clinical Cases of Cerebellar Infarction with Brain Stem Compression

"Motor" Abnormality	No. Cases
Gaze palsy or 6th nerve palsy	14
Extensor plantar response, bilateral	11
Cerebellar ataxia	6
Decerebrate posturing	5
Facial palsy	2
Extensor plantar response, unilateral	1

INVESTIGATIONS

A CT scan should be performed immediately when cerebellar infarction is suspected. It not only localizes the lesion and suggests the pathological process, but it also shows any associated hydrocephalus. Lumbar puncture showed an elevated CSF pressure in approximately half of the cases reviewed. The fluid was usually clear, although there were up to 1000 red blood cells/cu mm on microscopic examination. Lumbar puncture adds little to the diagnosis and it may be dangerous in the presence of an expanding posterior fossa mass lesion. This is supported by a report that mentions one patient, fully alert at the time of the lumbar puncture, who died within an hour afterwards (13). Posterior fossa angiography, pneumoencephalography, and ventriculography have all proved to be helpful in diagnosis, when used.

NEUROPATHOLOGY

The diagnosis of infarction was proven either by surgical biopsy or by autopsy in every case in this series except Case 3, in which it was made by CT scan. I could not determine the exact size and extent of the infarction from the surgical reports. Apparently the necrotic areas were large, and descriptions such as "most of the cerebellar hemisphere" and "the entire inferolateral aspect" were commonly used to indicate the extent of infarction.

Autopsy reports on those patients dying acutely of brain stem compression indicate that the infarction was at least one-third the volume of the cerebellar hemisphere in all cases and frequently was from one-half to two-thirds the volume of the hemisphere (3, 9, 13). Herniation of the cerebellar tonsil below the foramen magnum was described, either at operation or at autopsy, in 41 of the 55 cases with signs of brain stem compression. A few of these cases had bilateral cerebellar infarction. No information is available on cases in the remainder of this group.

Pathological information concerning the patients who did not develop signs of brain stem compression is less detailed (13). Apparently the volume of the infarct was considerably smaller in those cases. Interestingly, "moderate hydrocephalus" was found in more than half (13 of 24) of the patients in the autopsy series who had prolonged survival after cerebellar infarction (13).

TREATMENT AND OUTCOME

A depressed level of consciousness varying from stupor to coma developed in 55 patients in this series. These patients also had long tract motor signs and cranial nerve palsies. The treatment and outcome in these 55 cases are reported in Table 2. The operation performed in all cases was suboccipital craniectomy and resection of the necrotic cerebellar tissue. A sufficient volume of tissue was resected to provide an adequate decompression of the posterior fossa.

TABLE 2
 Treatment and Outcome in 55 Cases of Cerebellar Infarction with Brain Stem Compression

Treatment	No. Cases	Outcome		
		Full recovery	Partial recovery	Death
No operation	37	6	0	31
Operation	18	8	5	5

In the group of patients who developed signs of brain stem compression, 5 of the 18 treated surgically and 31 of the 37 not treated surgically died. The neurological deficits in the 5 patients who made an incomplete recovery after operation were usually of mild or moderate severity. However, 1 patient was described as being "disoriented" 1 year after operation. Of the 20 patients not developing signs of brain stem compression, 19 made a satisfactory recovery without operative treatment. One patient died 7 days after the onset of symptoms of an acute myocardial infarction (3).

DISCUSSION

Infarction of the cerebellum is an entity that has received little attention in the literature and is overlooked in some standard works (1, 17). The true incidence is difficult to ascertain. In one series, 4 cases were seen in a 1000-bed general hospital over a 10-year period (9). However, Sybert and Alvord indicate that 52 cases were found at autopsy during the same period in three general hospitals associated with a university medical center (13). In another investigation specifically studying brain stem vascular phenomena no case of cerebellar infarction was found among 1687 autopsies (5). It is likely that the incidence of clinical cases will increase as CT scanning is used more frequently in the assessment of patients with stupor and coma.

Cerebellar infarction with brain stem compression can be differentiated from acute hypertensive cerebellar hemorrhage, which may have similar symptoms and signs. Pre-existing hypertension makes the latter more probable, and patients with hemorrhage show a more rapid clinical deterioration in many instances (6, 11). Patients with a subdural or epidural hematoma in the posterior fossa are likely to have a history of trauma (16). A rapidly expanding tumor or an abscess in the cerebellar hemisphere may also present in a manner similar to that of infarction. Brain stem infarction can be differentiated from cerebellar infarction by the greater variety of cranial nerve palsies (Table 1), particularly those other than ocular and facial palsies, or by the immediate appearance of the complete deficit (7). The CT scan is quite helpful in differentiating these conditions.

However, if the clinical situation is sufficiently critical and the diagnosis of cerebellar infarction is suspected, one should not delay for radiological confirmation but should proceed with emergency posterior fossa decompression. This should be done even when the patient is in extremis because dramatic improvement has occurred in several cases, including Case 1. The situation here seems remarkably similar to that described by Fisher et al. in relation to cerebellar hemorrhage, where a "critical state (decerebrate posture, cessation of respiration, fixed pupils) which in other conditions is nearly always fatal, can be relieved" by surgical decompression (6). "It is our observation that the hopeless state of cerebellar hemorrhage may be more apparent than real" (6). This seems to apply equally to cerebellar infarction.

The etiology of cerebellar infarction does not seem remark-

ably different from that of infarction in other regions of the brain. The age distribution is also similar to that for other cases of cerebral infarction.

The evidence points to the fact that a cerebellar infarct may act as a progressively enlarging mass lesion in the posterior fossa; the clinical course is indicative of progressive brain stem compression. Twenty patients showed radiological evidence of either hydrocephalus, displacement of the 4th ventricle, or aqueductal occlusion. These findings suggest a posterior fossa mass lesion. Herniation of a cerebellar tonsil below the level of the foramen magnum was found either at operation or at autopsy in 41 cases.

Fluid accumulation begins soon after ischemic injury to the brain. As necrosis of cerebral tissue proceeds, water uptake and recognizable brain edema increase greatly (8). Progressive expansion of the infarct in the narrow confines of the posterior fossa compresses the brain stem; for this reason the onset of symptoms and signs of brain stem compression may be delayed for several days after the onset of the infarction.

I find no report of attempts to treat the cerebral edema in these cases by nonsurgical means such as steroids, diuretic agents, and hyperventilation. Provided that the correct diagnosis has been made and that other expanding mass lesions in the posterior fossa have not been overlooked, this form of treatment may be appropriate, particularly in those cases in which the signs do not suggest that brain stem compression is severe. As indicated in Table 2, surgical decompression is mandatory when deterioration is occurring or if brain stem compression is already advanced. With prompt diagnosis and early treatment, we should be able to reduce the mortality considerably from the present levels.

ACKNOWLEDGMENT

I thank Dr. R. H. Mudd for permission to present Case 2.

Received for publication, April 15, 1978; accepted, July 22, 1978.

Presented at the Third Joint Meeting on Stroke and Cerebral Circulation, New Orleans, Louisiana, February 17, 1978 (Feely, M. P. and Dempsey, P. J. Acute cerebellar infarction—A surgical emergency. *Stroke*, 9: 96, 1978 (abstr.).)

Reprint requests: Michael P. Feely, M.Ch., Department of Neurosurgery, College of Medicine, University of South Alabama, 2451 Fillingim Street, Mastin Building 712, Mobile, Alabama 36617.

REFERENCES

- Baker, A. B. and Baker, L. H. *Clinical Neurology*. Hagerstown, Maryland, Harper and Row, 1971. Updated with revisions: 1976.
- Collaborative Group for the Study of Stroke in Young Women. Oral contraception and increased risk of cerebral ischemia or thrombosis. *N. Engl. J. Med.*, 288: 871-878, 1973.
- Duncan, G. W., Parker, S. W., and Fisher, C. M. Acute cerebellar infarction in the PICA territory. *Arch. Neurol.*, 32: 364-368, 1975.
- Fairburn, D. and Oliver, L. C. Cerebellar softening: A surgical emergency. *Br. Med. J.*, 1: 1335-1336, 1956.
- Fang, H. C. H. and Palmer, J. J. Vascular phenomena involving brainstem structures: A clinical and pathologic correlation study. *Neurology (Minneapolis)*, 6: 402-419, 1956.
- Fisher, C. M., Picard, E. H., Polak, A., Dalal, P., and Ojemann, R. G. Acute hypertensive cerebellar hemorrhage: Diagnosis and surgical treatment. *J. Nerv. Ment. Dis.*, 140: 38-57, 1965.
- Gilroy, J. and Meyer, J. S. *Medical Neurology*. 2nd Ed. New York, MacMillan and Co., 1975, pp. 509-589.
- Klatzo, I. Pathophysiologic aspects of cerebral ischemia. In *The Basic Neurosciences*, edited by Brady, R. O., pp. 313-322, New York, Raven Press, 1975. (*The Nervous System*, Vol. 1)
- Lehrich, J. R., Winkler, G. F., and Ojemann, R. G. Cerebellar infarction with brain stem compression: Diagnosis and surgical treatment. *Arch. Neurol.*, 22: 490-498, 1970.
- Lindgren, S. O. Infarctions simulating brain tumors in the posterior fossa. *J. Neurosurg.*, 13: 575-581, 1956.
- McKissock, W., Richardson, A., and Walsh, L. Spontaneous cerebellar haemorrhage: A study of 34 consecutive cases treated surgically. *Brain*, 83: 1-9, 1960.
- Plum, F. and Posner, J. B. *Diagnosis of Stupor and Coma*. 2nd Ed. Philadelphia, F. A. Davis Co., 1972, p. 137.
- Sypert, G. W. and Alvord, E. C. Cerebellar infarction: A clinicopathological study. *Arch. Neurol.*, 32: 357-363, 1975.
- Vessey, M. P. Oral contraceptives and thromboembolic disease. *Am. Heart J.*, 77: 153-157, 1969.
- Wood, M. W. and Murphey, F. Obstructive hydrocephalus due to infarction of a cerebellar hemisphere. *J. Neurosurg.*, 30: 260-263, 1969.
- Wright, R. L. Traumatic hematomas of the posterior cranial fossa. *J. Neurosurg.*, 25: 402-409, 1966.
- Youmans, J. R. *Neurological Surgery: A Comprehensive Reference Guide to the Diagnosis and Management of Neurosurgical Problems*. Philadelphia, W. B. Saunders, 1973.

COMMENTS

The author summarizes the relatively small number of reported cases of cerebellar infarction, adds three new cases, and again calls attention to the importance of early recognition and surgical treatment of this problem when brain stem compression occurs. He also demonstrates the CT scan findings of cerebellar infarction.

The real incidence of cerebellar infarction will probably only be obtained at a center in which a large number of CT scans are performed for cerebrovascular disease. It is not known how many patients have a small area of infarction in the territory of the PICA that resolves spontaneously.

Table 2 records 37 cases with brain stem compression that were not operated upon. Because this includes a number of cases from the autopsy series, the true incidence of full and partial recovery in this group is not known.

It is possible that the CT scan could be negative early in the course of the illness. I would completely agree with the author's statement, "... if the clinical situation is sufficiently critical and the diagnosis of cerebellar infarction is suspected, one should not delay for radiological confirmation but should proceed with emergency posterior fossa decompression."

Robert G. Ojemann, M.D.
Boston, Massachusetts

In spite of rapid advances in the diagnosis and treatment of neurological diseases, acute vascular mass lesions of the cerebellum often remain undiagnosed during life and are not recognized as potentially treatable neurological emergencies in patients with stroke syndromes. Acute massive cerebellar infarction has been thought to be rare compared with infarction elsewhere in the brain. In addition, early attempts at recognizing a reliable clinical syndrome have been unsuccessful, as the signs and symptoms are considered too protean. However, the author clearly documents that this pathological state is not rare and that early diagnosis and prompt surgical attention are mandatory before the development of irreversible brain stem damage. Furthermore, the author is first to demonstrate the importance of computed tomography in the early diagnosis of this potentially rapidly expanding posterior fossa mass lesion. Our experience with early computed tomographic evaluation of these cases is consistent with the author's conclusion that the CT scan is the diagnostic test of choice. A high index of suspicion, an early diagnosis, and prompt surgical decompression will certainly result in a reduced mortality; many patients will recover with little or no disability.

Dr. Feely does suggest that attempts to treat the cerebellar edema in these cases by nonsurgical means such as steroids,

diuretic agents, and hyperventilation may have a place in the treatment of acute cerebellar infarction associated with massive cerebellar swelling. If instituted early in the course, it is possible that this form of management will be beneficial. However, if brain stem compression occurs, it is exceedingly unlikely, with current techniques, that a significant decompression of the brain stem can be obtained by these nonsurgical methods. There is no evidence to suggest that glucocorticoids will have any significant effect on the swelling associated with cerebellar infarction. Furthermore, the small confines of the posterior fossa will make diuretic agents and hyperventilation as modes

of therapy not particularly effective because they seem to work primarily on normal cerebral structures. In the case of acute massive cerebellar infarction, a majority of the posterior fossa cerebral tissue has been infarcted and is, thus, unlikely to respond to these modes of management. Therefore, it is most probable that, in patients with evidence of brain stem compression, prompt surgical decompression will be required and that any delay for other modes of management will probably culminate in an unsatisfactory result for the patient.

George W. Sypert, M.D.
Gainesville, Florida