

## **The Results of Operating upon Cerebral Aneurysms and Angiomas in Children and Adolescents**

### **II. Cerebral Angiomas**

*A. Loren Amacher, Charles G. Drake and Laila Hovind*

Departments of Paediatrics and Clinical Neurological Sciences,  
University of Western Ontario, London, Ont.

**Key Words.** Angiomas, cerebral · Children · Surgical treatment · Results

**Abstract.** Symptomatic angiomas of the brain, brain stem or cerebellum are uncommon in all age groups. They usually present by subarachnoid and intraparenchymatous hemorrhage, but they may act as expanding mass lesions, as causes of ingavescent neurological deficit ('steal phenomenon'), as epileptogenic foci, or as a source of relentless headache. We have operated upon 20 patients, 18 years of age or less, with symptomatic angiomas. There has been no surgical mortality, and no patient has been made worse by operation.

### **Introduction**

Symptomatic angiomas are uncommon at any age. In the young, they are an important differential diagnosis in subarachnoid hemorrhage or intraparenchymal hematoma. They may present, less commonly, as mass lesions, epileptogenic foci, causes of transient ischaemic attacks or progressive neurological deficit, or as a cause of severe migraine-like headache [1].

It is the purpose of this paper to discuss the results of operating upon angiomas in young patients.

### **Clinical Material**

All young patients operated upon in this center, with an angiographic and pathological diagnosis of intracranial angiomas are included. The clinical data are summarized in table I.

**Table 1.** Clinical data, angiomas in the young

Case	Sex	Age	Presentation	Site	Operation	Postoperative angiogram	Result	Comment
1 N.S.	F	9	headache, IICP (mass lesion)	lt. cerebellum	excision	not done	excellent	see text
2 K.J.	F	14	SAH numbness rt. leg. incont.	lt. parietal	excision	obliterated	excellent	small ICH
3 R.D.	M	3.5	seizure, SAH	rt. rolandic	excision	not done	excellent	small ICH
4 C.K.	M	0.75	seizures	lt. cerebral, diffuse	hemispherectomy (3 opns)	obliterated	fair	retarded, seizures reduced
5 T.D.	M	1	Skull erosion	rt. parietal	excision	obliterated	excellent	
6 N.S.	M	13	SAH (×5) stupor, postfossa signs	rt. CPA	excision	obliterated	excellent	clot in angle
7 J.P.	M	17	SAH 4 years prev. rt. brain stem signs	rt. brain stem, surface	excision	obliterated	good	slow resolution of rt. cranial nerve signs and lt. hemiparesis
8 C.P.	M	18	SAH (×2)	rt. trigone	excision	obliterated	excellent	ventricular clot
9 B.B.	F	5	SAH + ICH	lt. frontal	excision	obliterated	excellent	frontal ICH
10 M.G.	F	17	SAH + ICH	rt. occipital	excision	obliterated	excellent	large ICH
11 J.F.	M	14	SAH lt. ICH	rt. parietal	1. partial excision 2. excision	residual, larger obliterated	good excellent	see text
12 J.C.	F	11	SAH + ICH	rt. parietal	excision	small residual	excellent	10 years, no recurrence
13 G.K.	M	3	seizure	lt. parietal	excision	obliterated	good	slow, no fits
14 A.B.	F	9	SAH	corpus. call.	excision	residual	excellent	see text
15 L.G.	F	18	SAH	rt. occipital	excision	obliterated	excellent	inferior surface
16 C.S.	F	18	SAH parinauds	quad. plate	excision	obliterated	excellent	see text
17 R.E.	M	17	TIA 'steal'	lt. rolandic	exploration	not done	no change	
18 C.M.	F	18	SAH + ICH	rt. frontal	excision	obliterated	excellent	large ICH
19 J.C.	M	6	SAH brain stem signs	rt. cerebellum brain stem	clip feeders	no change	no change	see text
20 J.F.	M	17	SAH + ICH	rt. cerebellum	excision	obliterated	excellent	cerebellar ICH

SAH = Subarachnoid hemorrhage; ICH = intracerebral hematoma; IICP = increased intracranial pressure; TIA = transient ischemic attack.

Note: Since submission, a further 12 cases have been operated upon, without mortality or increased morbidity, ages 5–16 years.

(1) *Symptomatology*: Of the 20 patients, 15 had experienced intracranial bleeding. Of these, 8 had preoperative clinical indications of intraparenchymal clots, confirmed at operation, while a further 3 had small, asymptomatic clots. In 1 case (7, J.P.), the SAH had occurred 4 years previously, whereas ongoing symptoms were due to brain stem compression.

In 2 cases, seizures were the principal clinical manifestation. In 1 case each, headache of increased intracranial pressure, skull erosion, and transient ischaemic attacks prompted operation.

(2) *Sex and age*: There was no sex predilection. 4 patients presented at 0-4 years, 4 at 5-9 years, 4 at 10-14 years, and 8 at 15-18 years.

(3) *Sites*: 14/20 lesions were supratentorial. Five were parietal, two were frontal, two occipital, two rolandic, one intraventricular, one in the corpus callosum, and one was pan-hemispheric.

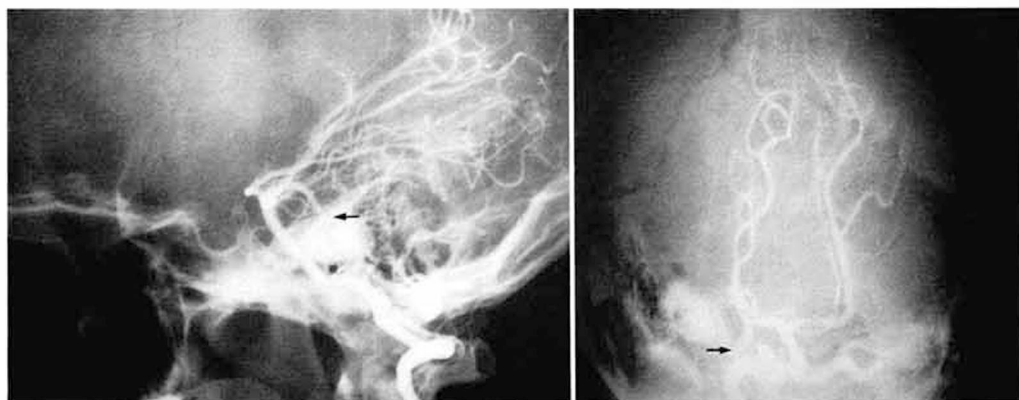
Three lesions were in the cerebellum, two on the brain stem, and one in the cerebello-pontine angle.

(4) *Case reports*: Certain interesting and important features of angiomas and their surgical treatment can best be illustrated by case summaries.

#### *Case 1*

A 9-year-old girl was admitted because of increasingly severe headache for several weeks, accompanied by papilledema and split coronal sutures. Preoperative angiography and computerized tomography suggested a left cerebellar mass, showed a 'cut off' vessel, and hydrocephalus (fig. 1). At a left suboccipital craniotomy, a thrombosed venous angioma was encountered and excised. Postoperatively, her headache disappeared, and the hydrocephalus subsided.

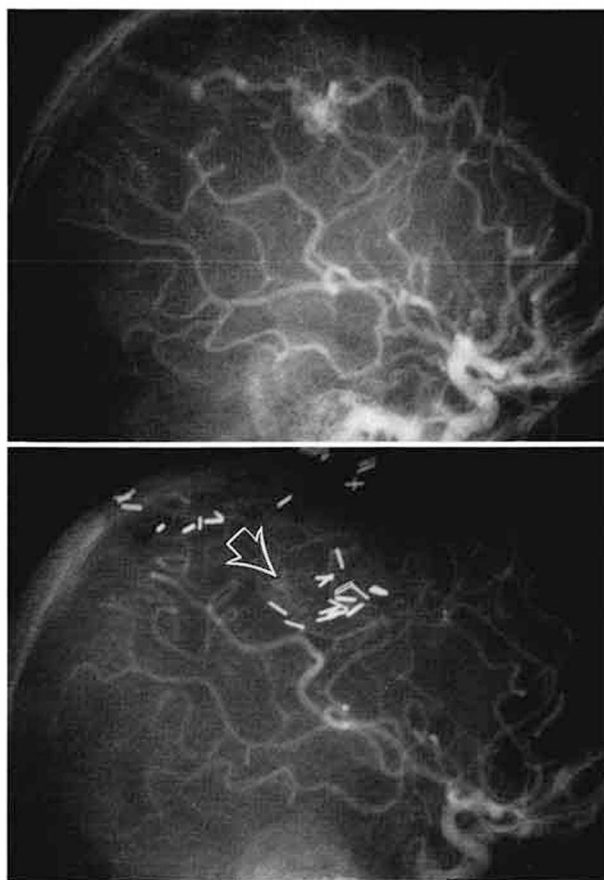
*Comment*. It is well to remember that not all angiomas are diagnosed preoperatively, and that one should be prepared for anything until the pathology is established.



**Fig. 1.** Vertebral angiogram, lateral (left) and Towne's views. Note the 'cut-off' artery (arrows).

*Case 11*

This 14-year-old boy was struck down by a sudden subarachnoid and right parietal hemorrhage that produced brief coma and a left hemiparesis. He recovered quickly. Angiography showed an angioma of the right parietal lobe (fig. 2). The lesion was removed, but postoperative angiography revealed residual angioma, enlargement of the previously normal middle cerebral artery, and a previously unseen deeper component to the lesion (fig. 2). 6 months later, an angiogram revealed even further growth of the residual angioma. This time, complete excision was accomplished, and proven by postoperative angiography. All feeders returned to normal calibre.



**Fig. 2.** Carotid angiograms, lateral views. Preoperative view (top) of angioma: note the large anterior cerebral feeder. Postoperative (bottom) view: note normal size of anterior cerebral artery, enlarged middle cerebral feeder, and previously unseen angioma component (arrow).

*Comment.* This case illustrates: (1) incompletely excised angiomas may enlarge again; (2) when the lesion is incompletely removed, feeding arteries may persist in their enlarged state; (3) the full extent of an angioma may not be visualized, even by complete angiography; (4) postoperative angiography is important in the assessment of results of surgery for angioma, and (5) once an angioma is obliterated, feeding arteries return to normal size.

#### Case 14

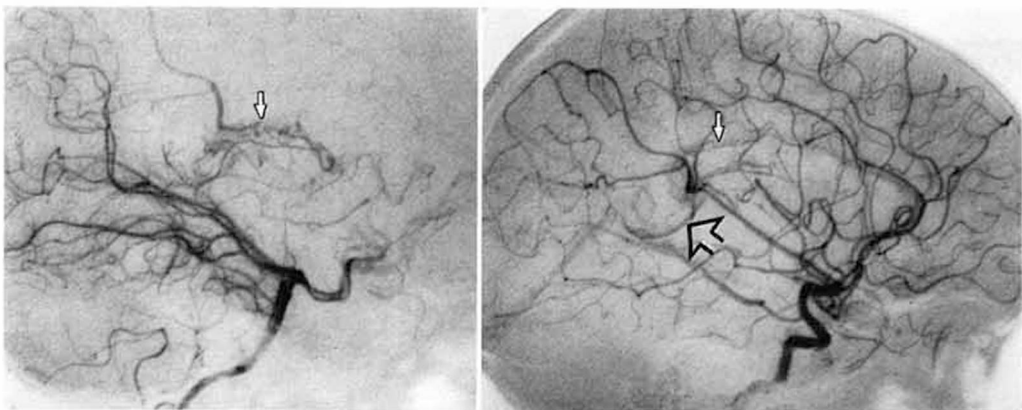
A.B., a 9-year-old girl, was awakened from sleep by a severe apical headache, accompanied by vomiting. Computerized tomography showed clotted blood in the pineal region, and in the left lateral ventricle. Angiography demonstrated a fine-vessel angioma of the corpus callosum, posteriorly (fig. 3). The lesion was approached between the hemispheres. The part above and within the corpus callosum was removed, but a small portion extending posteriorly, under the corpus callosum splenium and onto the left fornix, was left in place. Residual angioma was confirmed by angiography.

*Comment.* Previous experience would suggest that this residual angioma may regrow and rebleed [1]. Repeat angiography is planned at intervals. If enlargement or further hemorrhage occur, total excision may be attempted, in spite of a rather hazardous location.

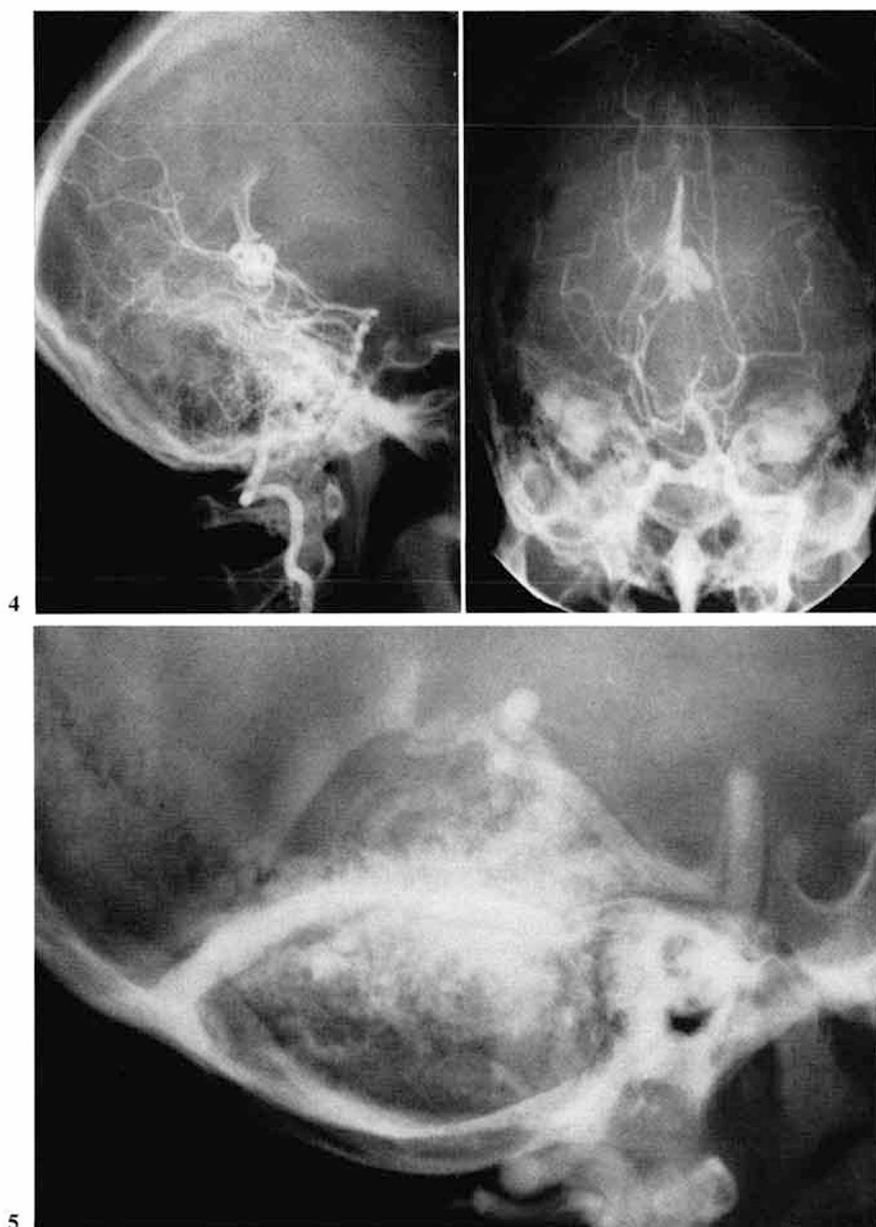Not all residuals of small volume cause further trouble. In case 12, repeat angiography has indicated no further growth, and she remains very well.

#### Case 16

An 18-year-old girl, C.S., developed a sudden headache, followed by a left hemiparesis, a Parinaud's Syndrome, and mild pupillary asymmetry. An angioma was seen at angiography, fed largely from the superior cerebellar arteries and draining to the vein of Galen (fig. 4). There was mild hydrocephalus. The lesion appeared to be in the region of



**Fig. 3.** Lateral vertebral (left) and lateral carotid (right) angiograms, showing fine vessel angioma (arrows) feeding from both circulations, and draining through the galenic system (open arrow).



**Fig. 4.** Vertebral angiogram, lateral (left) and Towne's (right) views of angioma in quadrigeminal cistern and draining into Galenic system.

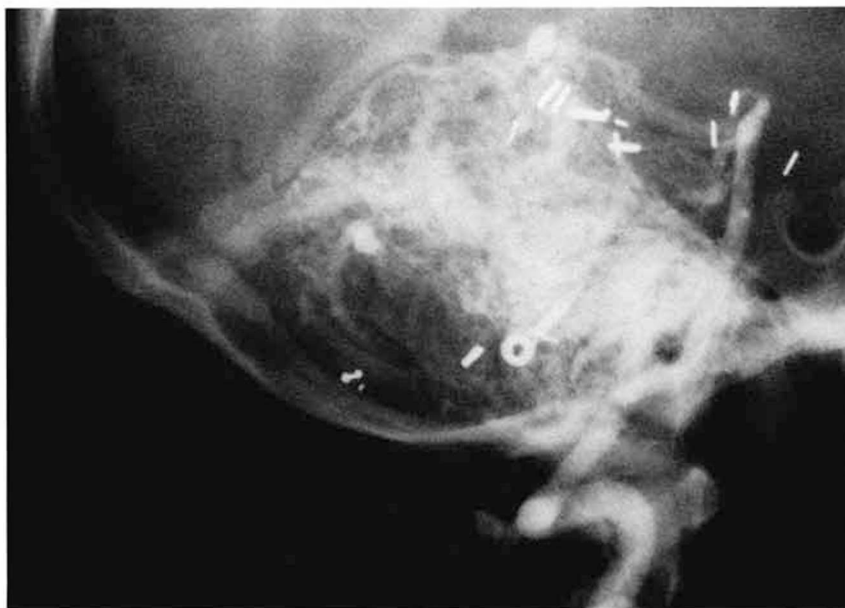**Fig. 5.** Vertebral angiogram, lateral. Huge angioma occupying right cerebellum.

the quadrigeminal cistern and plate. Through a supracerebellar approach, the angioma was excised from the quadrigeminal plate. The patient returned to a normal neurological state.

*Comment.* Angiomas may be removed from difficult areas, by microsurgical technique, with safety. In this case, the dilatation of the vein of Galen was secondary to a nearby angioma, and does not qualify as a vein of Galen aneurysm [2].

#### *Case 19*

This 6-year-old boy was rendered unconscious and apneic by a subarachnoid hemorrhage. Coma persisted for 4 days. He slowly improved, but was left with a right hemiparesis, bilateral arm intention tremor, and right ataxia. A bruit could be heard over right frontal and occipital areas. The angiogram showed a huge angioma, with large feeders from superior and posterior inferior cerebellar arteries (fig. 5), occupying the right cerebellum. A combined right suboccipital and subtemporal approach was used. Excision was deemed impossible. Clips were placed on the right superior and posterior inferior cerebellar arteries, close to the lesion. The subsequent angiogram showed the angioma to be unchanged, with copious alternate blood supply (fig. 6). The boy has shown slow improvement in neurological function.



**Fig. 6.** Vertebral angiogram, lateral, postoperative. Note the occlusive clips, and the unchanged size of the angioma.

*Comment.* This and previous experiences [1] indicate that the simple clipping of feeding vessels to angiomas is ineffectual as treatment. Unheralded and unseen feeders simply open up, to maintain the arterial inflow.

## Results

The results are summarized in table I. An excellent result indicates return to presymptomatic status. A good result indicates persistence of mild neurological or intellectual deficit, present preoperatively.

The points to be emphasized are: (1) there was no surgical mortality in 23 procedures done on 20 patients; (2) no patient was made worse by operation; (3) postoperative angiography was done 18 times on 17 patients, confirming surgical obliteration in 14 procedures, residual angioma in 4, and (4) to date, recurrent hemorrhage has not occurred from residual angiomas; but, at least 2 patients had suffered at least one repeat hemorrhage prior to operation: thus, we do not consider patients with residual angiomas safe from future catastrophe [1].

## Conclusions

Symptomatic angiomas are unusual in young people. They can be surgically obliterated with a very low mortality. Postoperative angiography is important in the assessment of surgical therapy, and, in the follow-up of patients with residual angioma.

## References

- 1 Amacher, A.L.; Allcock, J.M., and Drake, C.G.: Cerebral angiomas. The sequelae of surgical treatment. *J. Neurosurg.* 37: 571-575 (1972).
- 2 Amacher, A.L. and Shillito, J., jr.: The syndromes and surgery of aneurysms of the great vein of Galen. *J. Neurosurg.* 39: 89-98 (1973).

A. Loren Amacher, Victoria Hospital, 375 South Street, London,  
Ont. N6A 4G5 (Canada)