

# Acute pulmonary edema following venous air embolism during a neurosurgical procedure

## Case report

WILLIAM F. CHANDLER, M.D., DONALD G. DIMCHEFF, M.D.,  
AND JAMES A. TAREN, M.D.

*Section of Neurosurgery and Pulmonary Division, Department of Internal Medicine,  
University of Michigan Medical Center, Ann Arbor, Michigan*

✓ A case of venous air embolism during a procedure in the sitting position is reported in which the patient developed fulminant pulmonary edema within 2 hours of the embolus. Possible cause and effect relationships are discussed.

KEY WORDS · venous air embolism · pulmonary edema · wet lung syndrome

**A**CUTE pulmonary edema following neurosurgical procedures is uncommon, but well documented.<sup>1,22</sup> Venous air embolism during neurosurgical procedures in the sitting position has a reported incidence of from 1.6% to 15%,<sup>12,13</sup> and a mortality rate, generally from hypotension and cardiac arrest,<sup>6</sup> of up to 93% in untreated cases,<sup>4</sup> and from 0 to 28% in treated cases.<sup>9,14</sup> In surveying the literature we were unable to find any cases where acute pulmonary edema, or the "wet lung" syndrome, was associated with venous air embolism. We are reporting such a case in which we verified the diagnosis of venous air embolism by fortuitously noting air in the dural sinuses during routine fluoroscopy and video taping.

### Case Report

At the age of 10 years this 27-year-old

left-handed man noted increased tone and athetoid movements in his right arm and leg which progressed slowly over a 10-year period, and stabilized so that his right arm was virtually useless. The abnormal movements were accentuated by stress, and caused him to avoid social situations. The patient was diagnosed as having dystonia musculorum deformans and admitted for a left stereotaxic thalamotomy to decrease the tone and abnormal movements.

*Examination.* The positive neurological findings were confined to the right arm and leg and included marked increase in tone, minimal hypesthesia to pinprick, and athetoid movements, more marked distally; all of these findings were greater in the right arm. Cerebellar testing was normal; there was no specific weakness and the deep tendon reflexes were 2+ bilaterally. The general physical examination was normal.

## Acute pulmonary edema following venous air embolism

On the day before surgery the patient underwent a pre-thalamotomy pneumoencephalogram during which 110 cc of oxygen were instilled via a 20-gauge spinal needle at L3-4, and 55 cc of CSF were removed. The patient tolerated the procedure well, and the study demonstrated slightly enlarged ventricles with no cortical atrophy.

**Operation.** The patient was placed in the sitting position and given 4 cc of Innovar\* intravenously. As it was necessary for the patient to be conscious and cooperative for neurological examination, neither a "G suit" nor an esophageal stethoscope was used. Under local lidocaine anesthesia a left occipital trephine opening was made and bone wax was applied; the dura appeared sunken and pulsatile. A Guiot-Gillingham stereotaxic apparatus was then applied; the patient was talkative and able to move all extremities. As a small cruciate incision was made in the dura he complained of neck pain, and his pulse rate fell from 80 to 40 with no change in blood pressure. Atropine, 0.4 mg, abolished the bradycardia. At this point, two attempts were made to enter the left lateral ventricle with the use of the stereotaxic ventricular needle, but the ventricles were not encountered and, therefore, no air was injected. By using the "C-arm" fluoroscopy unit and video taping, the trajectory of the needle was checked and appeared appropriate. It was noted on the TV monitor that air was streaming over the convexities from the vertex region, flowing posteriorly and inferiorly toward the base of the skull. This was thought initially to be subarachnoid air. However, at the same time, the patient became increasingly drowsy, and subsequently unarousable; the procedure was terminated immediately. During the closing procedure, the blood pressure dropped from 140 to 90 systolic, but responded to 30° semi-Fowler's position. Several premature ventricular contractions were noted on the EKG monitor.

**Postoperative Course.** In the recovery room the patient was unresponsive and intermittently decerebrate in response to

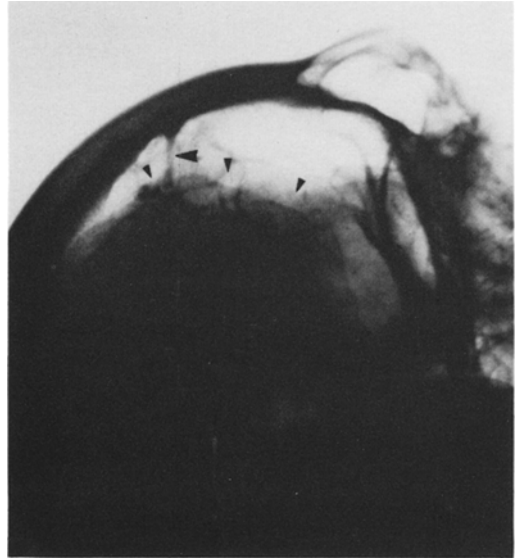


FIG. 1. Left carotid arteriogram, brow-up venous phase, demonstrating retraction of frontal lobes (small arrowheads) and stretching of a bridging vein (large arrowhead).

noxious stimuli. The blood pressure was stable at 150/80, and an EKG showed sinus tachycardia of 160. Physical examination demonstrated marked tachypnea and bilateral rales. The patient had small minimally reactive pupils but maintained the oculoccephalic reflex. A nasotracheal tube was placed, and emergency left carotid and vertebral arteriograms showed no intra- or extracerebral hematoma but did show considerable air subdurally; the frontal lobes appeared retracted from the skull, and the bridging veins were stretched (Fig. 1); minimal transtentorial herniation was also demonstrated. During the arteriogram the patient was dusky, his arterial blood dark, and he showed signs of peripheral vasoconstriction. Arterial blood gases drawn while the patient was receiving 100% oxygen revealed a  $pO_2$  of 51 and  $pCO_2$  of 28. A chest film showed bilateral pulmonary edema (Fig. 2). A central venous catheter was placed, and the central venous pressure was found to be 3 cm of water. A review of the video tape at this point showed that the streaming air appeared to be in the dural sinuses (Fig. 3). The chest film was taken 2½ hours after the air had been seen on fluoroscopy.

\*Innovar (fentanyl 0.05 mg and droperidol 2.5 mg per cc) manufactured by McNeil Laboratories, Inc., Fort Washington, Pennsylvania 19034.

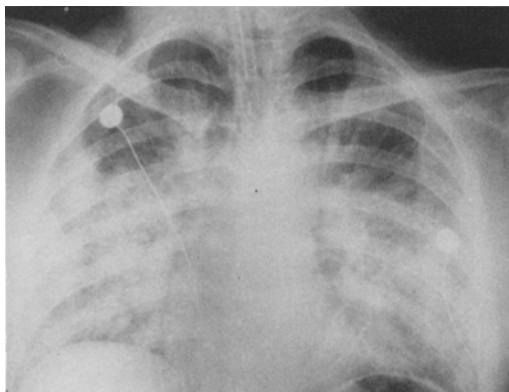


FIG. 2. Chest film 2 hours postoperatively showing bilateral pulmonary edema.

The "wet lung" syndrome<sup>11</sup> was treated by using a volume cycle respirator with large tidal volumes (18 cc/kg) and positive end expiratory pressure (PEEP) of 10 cm H<sub>2</sub>O. Pancuronium was used for neuromuscular paralysis. Within 6 hours, the percentage of inspired oxygen (FIO<sub>2</sub>) was progressively decreased from 100% to 40%, so that adequate peripheral oxygen transport was

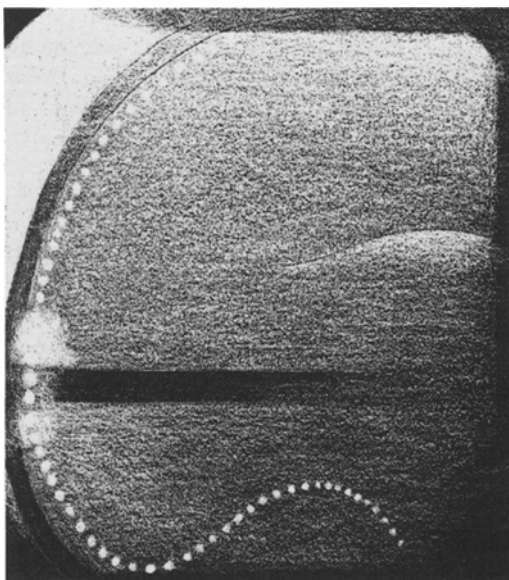


FIG. 3. Medical illustrator's drawing of the television videotape of fluoroscopy during the operation. The posterior portion of the skull is to the left; and the *white dots* represent air seen traveling in the dural sinuses and internal jugular vein. Air is also seen in the lateral ventricles.

assured; *i.e.*, an arterial pO<sub>2</sub> of 75 to 85, O<sub>2</sub> saturation of 90% to 95%, normal pH, and normal hemoglobin concentration. Fluid management was monitored with hourly urinary output, together with central venous pressure, pulse, blood pressure, and body weight. A daily weight loss of at least 0.5 kg was maintained so that any increase in lung water from fluid management was negligible.<sup>21</sup> Furosamide was used intermittently to assure this weight loss. Physiological and roentgenographic evidence of pulmonary improvement appeared slowly. The PEEP and paralysis were discontinued on the 5th day of mechanical ventilation, and he was weaned from the ventilator by the 8th day.

It was difficult to assess the patient neurologically while paralyzed with pancuronium, but he was able to protrude his tongue on command on the first postoperative day as the drug effect subsided, although he maintained decerebrate posture. Pupils were equal and reactive, and the EEG showed moderate diffuse slowing, consistent with hypoxic changes. After the pancuronium was stopped on the 5th postoperative day he could follow with his eyes, protrude his tongue, but had no spontaneous movements of his extremities. Gradually over the next 4 weeks, his mental status progressed from stupor to confusion to complete normalcy. The cranial nerve and sensory examination was normal within 2 weeks. He progressed from decerebrate rigidity to generalized spasticity, with motor function appearing first in the left arm at 3 weeks, and in his legs by 4 weeks.

Three months postoperatively, his left arm is normal, he walks unassisted with a slightly spastic gait, and his right arm remains spastic and flexed at the elbow, with only minimal function. He is able to feed and dress himself.

## Discussion

Precise interpretation of the sequence of events in this patient is difficult and not entirely conclusive, but we believe the relationship between the events is as follows: the preoperative pneumoencephalogram, with a large exchange of air and CSF, plus a postulated continuous leak

## Acute pulmonary edema following venous air embolism

from the lumbar subarachnoid space, removed the normal fluid cushion of the brain, and allowed caudal displacement in the sitting position. This was evidenced by the markedly sunken dura seen on completing the craniectomy. We believe that when the dura was opened this served as a vent, allowing air to enter the subdural space, and in turn produced a further caudal shift of the brain. Since air was visualized in the superior sagittal sinus over the vertex at this point, we conclude that the caudal movement of the brain caused tearing of a bridging vein, and allowed the ready access of subdural air into the venous sinus. Although an esophageal stethoscope was not available for evaluation of cardiac murmurs, the bradycardia,<sup>5</sup> hypotension,<sup>6</sup> and premature ventricular contractions<sup>15</sup> are all consistent with the venous air embolism documented on the TV monitor.

Shortly after the air embolism, the patient developed severe pulmonary edema, due either to the air embolism or a neurogenic stimulus. The pathophysiology of these two entities involve distinctly different mechanisms. Clinically, neurogenic pulmonary edema has been associated with trauma, intracranial hematoma or neoplasm, and seizures.<sup>1</sup> It has been seen experimentally following sudden increase in intracranial pressure,<sup>2</sup> bilateral lesions in the preoptic areas,<sup>22</sup> hypothalamic lesions,<sup>17</sup> and intracisternal injection of fibrin<sup>19</sup> or endotoxin.<sup>20</sup> Whatever the initial lesion, most investigators have recorded intense sympathetic overactivity leading to redistribution of blood volume to the pulmonary circuit, with systemic and pulmonary arterial hypertension, left atrial and pulmonary venous hypertension, and subsequent pulmonary edema.<sup>2,3,16,22</sup>

On the other hand, pulmonary edema following air embolism has not been documented in humans, but has been well studied in dogs.<sup>18,23</sup> Following large air emboli, a foamy mixture of air, blood, fibrin, and fat are seen in the right heart and pulmonary arterial tree.<sup>8</sup> Initial cardiopulmonary responses include bradycardia, systemic hypotension, and pulmonary arterial hypertension, with no left atrial or pulmonary venous hypertension.<sup>8</sup> The pathophysiology of the subsequent pulmonary

edema observed is not completely understood, but may involve mechanisms similar to blood clot emboli.<sup>7,24</sup> Theoretically, then, measurement of the pulmonary wedge pressure as an estimation of the left atrial and pulmonary venous pressure should differentiate the pulmonary edema due to air emboli from that due to neurogenic stimuli.

Because of the lack of increased intracranial pressure, the initial bradycardia and hypotension, and the documentation of large air embolism on video tape, we favor air embolism as the cause of pulmonary edema in this patient. Since left atrial pulmonary capillary wedge pressures were not measured, exclusion of brain stem injury as a cause of "neurogenic" pulmonary edema is impossible.

The exact etiology of the brain stem injury is not apparent, but may also have been due to the sudden caudal displacement of the brain. As the patient appeared in the immediate postoperative period to have a "Count of Monte Cristo" syndrome,<sup>10</sup> being able to move only his eyes and tongue, we believe the brain stem injury was in the ventrorostral pons. A lesion here, be it traumatic, hemorrhagic, or hypoxic, may involve the corticospinal tracts, but spare the aberrant pyramidal tracts to any or all cranial nerve nuclei.<sup>10</sup>

We believe that the rapid onset of pulmonary edema following a neurosurgical procedure in the sitting position should suggest the diagnosis of air embolism as well as a "neurogenic" etiology, and in either case, should be treated by mechanical ventilation and positive end expiratory pressure. This case suggests that procedures in the sitting position the day following pneumoencephalography should be carefully considered.

### References

1. Ducker TB: Increased intracranial pressure and pulmonary edema. Part 1: Clinical study of 11 patients. *J Neurosurg* 28:112-117, 1968
2. Ducker TB, Simmons RL: Increased intracranial pressure and pulmonary edema. Part 2: The hemodynamic response of dogs and monkeys to increased intracranial pressure. *J Neurosurg* 28:118-123, 1968
3. Ducker TB, Simmons RL, Martin AM Jr:

- Pulmonary edema as a complication of intracranial disease. **Am J Dis Child** 118: 638-641, 1969
4. Ericsson JA, Gottlieb JD, Sweet RB: Closed-chest cardiac massage in the treatment of venous air embolism. **New Engl J Med** 270:1353, 1964
  5. Gilbert RGB, Brindle F, Galindo A: **Anesthesia for Neurosurgery**. Boston, Little, Brown, 1966, p 39
  6. Gottlieb JD, Ericsson JA, Sweet RB: Venous air embolism: a review. **Anesth Analg** 44:773-779, 1965
  7. Gurewich V, Cohen ML, Thomas DP: Humoral factors in massive pulmonary embolism: an experimental study. **Am Heart J** 76:784-794, 1968
  8. Hartveit F, Lystad H, Minken A: The pathology of venous air embolism. **Brit J Exp Path** 49:81-86, 1968
  9. Hunter AR: Air embolism in the sitting position. **Anaesthesia** 17:467-472, 1962
  10. Kahn EA, Crosby EC, DeJonge BR: Tumors of the posterior fossa, in Kahn EA, Crosby EC, Schneider RC, et al (eds): **Correlative Neurosurgery**. Springfield, Ill, Charles C Thomas, 1969, ed 2, pp 211-213
  11. Kumar A, Konrad BS, Falke KJ, et al: Continuous positive-pressure ventilation in acute respiratory failure. Effects on hemodynamics and lung function. **New Engl J Med** 283:1430-1436, 1970
  12. Marshall BM: Air embolus in neurosurgical anaesthesia: its diagnosis and treatment. **Canad Anaesth Soc J** 12:255-261, 1965
  13. Michenfelder JD, Martin JT, Altenburg BM, et al: Air embolism during neurosurgery: an evaluation of right-atrial catheters for diagnosis and treatment. **JAMA** 208:1353-1358, 1969
  14. Michenfelder JD, Terry HR Jr, Daw EF, et al: Air embolism during neurosurgery: a new method of treatment. **Anesth Analg** 45:390-395, 1966
  15. O'Higgins JW: Air embolism during neurosurgery. A case report. **Brit J Anesth** 42:459-462, 1970
  16. Paine R, Smith JR, Butcher HR, et al: Heart failure and pulmonary edema produced by certain neurologic stimuli. **Circulation** 5:759-765, 1952
  17. Reynolds RW: Pulmonary edema as a consequence of hypothalamic lesions in rats. **Science** 141:930-932, 1963
  18. Richardson HF, Coles BC, Hall GE: Experimental gas embolism. I. Intravenous air embolism. **Current Med Ass J** 36:584-588, 1937
  19. Sarnoff SJ, Sarnoff LC: Neurohemodynamics of pulmonary edema. II. The role of sympathetic pathways in the elevation of pulmonary and systemic vascular pressures following the intracisternal injection of fibrin. **Circulation** 6:51-62, 1952
  20. Simmons RL, Ducker TB, Martin AM, et al: Intrathecal endotoxin: the role of the central nervous system in septic shock. **Surg Forum** 28:12-14, 1967
  21. Sladen A, Laver MB, Pontoppidan H: Pulmonary complications and water retention in prolonged mechanical ventilation. **New Engl J Med** 279:448-453, 1968
  22. Urabe M, Segawa Y, Tsubokawa T, et al: Pathogenesis of the acute pulmonary edema occurring after brain operation and brain trauma. **Jap Heart J** 2:147-169, 1961
  23. Wycoff CC, Cann JE: Experimental pulmonary air embolism in dogs. **Calif Med** 105:361-367, 1966
  24. Yuceoglu YZ, Rubler S, Eshwar KP, et al: Pulmonary edema associated with pulmonary embolism: a clinicopathological study. **Angiology** 22:501-510, 1971

---

*Address reprint requests to:* William F. Chandler, M.D., Department of Surgery, Section of Neurosurgery, University of Michigan Medical Center, Ann Arbor, Michigan 48104.