

- taneous transfemoral technique. *Radiology* 89:815-824, 1967
- 5 Ziegler EE: Infectious mononucleosis: Report of a fatal case with autopsy. *Arch Path* 37:196-201, 1944
 - 6 Custer RP, Smith EB: The pathology of infectious mononucleosis. *Blood* 3:830-857, 1948
 - 7 Fish M, Barton HR: Heart involvement in infectious mononucleosis. *Arch Int Med* 101:636-644, 1958
 - 8 Hoagland RJ: The clinical manifestations of infectious mononucleosis; a report of 200 cases. *Am J Med Sci* 240, 21-29, 1960
 - 9 Niederman JC, McCollum RW, Henle G, et al: Infectious mononucleosis: clinical manifestations in relation to EB virus antibodies. *JAMA* 203:205-209, 1968
 - 10 Webster BH: Cardiac complications of infectious mononucleosis. A review of the literature and report of five cases. *Am J Med Sci* 234:62-70, 1957
 - 11 Abelmann WH: Myocarditis. *New Eng J Med* 275:832-833, 944-945, 1966
 - 12 de la Chapelle CE, Rossmann CE: Myocarditis. *Circulation* 10:747-765, 1954
 - 13 Sidd JJ, Kemp HG, Gorlin R: Acute myocardial infarction in a nineteen-year-old student in the absence of coronary obstructive disease. *New Eng J Med* 282:1306-1307, 1970
 - 14 Likoff W: Myocardial infarction in subjects with normal coronary arteriograms (editorial). *Am J Cardiol* 28:742-743, 1971
 - 15 Nizet PM, Robertson L: Normal coronary arteriogram following myocardial infarction in a 17-year-old boy. *Am J Cardiol* 28:715-717, 1971
 - 16 Houck GH: Involvement of the heart in infectious mononucleosis (editorial). *Am J Med* 14:261-264, 1953

Ouabain-Induced Hypertension in a Patient with Decompensated Hypertensive Heart Disease*

Raj Kumar, M.D., Nicholas A. Yankopoulos, M.D., and Walter H. Abelmann, M.D.

Increased systemic blood pressure after the administration of digitalis glycosides has been described both in clinical and experimental studies carried out under anesthesia. In awake and conscious man, digitalis-induced hypertension has been reported only rarely. However, hypertension occurs more often in conscious man in the presence of cardiovascular disease. To draw attention to the possibility of undesirable and even life-threatening complications, a patient is reported who developed accelerated hypertension and a stroke after the administration of ouabain. The possible mechanisms and therapy of digitalis-induced hypertension are discussed.

*From the Thorndike Memorial Laboratory, Harvard Medical Unit, Boston City Hospital, and the Department of Medicine, Harvard Medical School, Boston.
Supported in part by Grants HE 5244 and HE 10539 from the National Heart and Lung Institute, National Institutes of Health, by Public Health Service Research grant FP-76 from the Division of Research Facilities and Resources, and Grant No. 853 from the Massachusetts Heart Association.
Reprint requests: Dr. Abelmann, Thorndike Memorial Laboratory, Boston City Hospital, Boston 02118

The purpose of this presentation is to draw attention to the hypertensive effect of digitalis in patients with cardiovascular disease, to discuss its possible mecha-

For editorial comment, see page 2

nisms and therapy and to report a patient who developed a stroke associated with acute exacerbation of hypertension after administration of ouabain.

CASE REPORT

A 57-year-old Negro man was admitted for evaluation and treatment of chronic congestive heart failure in September, 1963. This was his twelfth admission to Boston City Hospital. The patient had known hypertension for 32 years, but remained asymptomatic until 1957, when he was admitted for cough and dyspnea on exertion of one month's duration. The blood pressure was 210/120 mm Hg, and pretibial edema was present. Circulation time of 25 seconds and venous pressure of 21 cm of water verified moderately severe congestive cardiac failure, which regressed on anticongestive therapy. The blood pressure decreased to 140/100 mm Hg with bed rest. The electrocardiogram suggested combined atrial enlargement. A phentolamine (Regitine) test was negative, and an intravenous pyelogram was normal. Digitalis leaf, 0.1 gm per day, was prescribed at the time of discharge.

In 1961, the patient was admitted with right hemiparesis; he recovered in 48 hours. A differential kidney function test (Howard) and renal arteriogram were within normal limits.

In July of 1962, atrial fibrillation was noted for the first time, and this arrhythmia was converted to sinus rhythm with quinidine. Five months later he was admitted for treatment of hypertension and congestive heart failure. A right lumbosacral sympathectomy was performed, as well as a transurethral resection of the prostate.

In April 1963, he was admitted with left hemiparesis and aphasia, in congestive heart failure with anasarca. The blood pressure was 220/110 mm Hg. The electrocardiogram showed atrial fibrillation and left ventricular hypertrophy. Chest roentgenograms showed a large left ventricle, a tortuous, dilated aorta and pulmonary congestion. On a low sodium diet, digitalis, and chlorothiazide, the patient did well and recovered almost completely from the hemiparesis. The blood pressure fell to 180/100 in the hospital.

The subsequent failure of the medical treatment of this patient's hypertension—which generally could be controlled in the hospital—was attributed to his inability to adhere to the prescribed medications. Prior to the present admission, he again developed orthopnea and pedal edema.

Examination revealed an obese man with orthopnea. The blood pressure was 200/120 and 180/120 mm Hg, standing and supine, respectively. The heart was irregularly irregular at 100-110 beats/min. The neck veins were distended and pulsatile. The fundi showed arteriolar narrowing without exudate or hemorrhage. The thyroid gland was enlarged without bruit. The lungs were clear. The heart was enlarged, and the apex beat was diffuse. A grade 3/6 blowing, systolic murmur was heard at the lower left sternal border and apex. A grade 2/6 systolic ejection murmur was audible at the base and left parasternal area. The second heart sound was equally loud in the aortic and in the pulmonic area. The liver was enlarged 4 inches below the right costal margin and tender. There was 3 to 4+ pitting edema up to the knees.

On low sodium diet, chlorothiazide 500 mg twice daily, and occasional mercurial diuretic injection, the patient improved steadily and recovered from overt congestive heart failure without clinical residua. Three weeks after admission,

cardiac catheterization was performed for hemodynamic evaluation and to rule out significant aortic stenosis. Informed consent to a study of the effects of ouabain had been obtained. The blood pressure before catheterization was 160/105 mm Hg. Under local anesthesia and without sedation, a No 8 Cournand catheter was inserted into the left antecubital vein. A second catheter was inserted into the right femoral artery by the Seldinger technique and advanced to the left ventricle. After measurements of control pressure and cardiac output, 0.75 mg of ouabain was given intravenously over three minutes. Hemodynamic data are presented in Table 1. Hemodynamic measurements were made using methods described in a previous communication from this laboratory,¹ in which this patient constituted Case 22. There was no systolic pressure gradient across the aortic valve.

Measurements were made 10 and 20 minutes after administration of ouabain. Approximately 23 minutes after ouabain administration, the patient became suddenly aphasic and left hemiparesis was observed. By this time, the blood pressure had increased significantly, but other vital signs were unaltered. Blood pressure continued to increase, and mean aortic pressure was 190 mm Hg one hour after ouabain (Table 1).

In view of the previous episodes of hemiparesis, neurologists advised against carotid angiogram. A lumbar puncture revealed clear fluid and a pressure of 22 cm of saline. Three hours after ouabain, the blood pressure was 230/150 mm Hg. Reserpine 5 mg IM was given in two doses. Eleven hours after ouabain, the blood pressure was 210/120 mm Hg. Thirty-four hours after ouabain the patient was found gasping and died, notwithstanding resuscitation measures. Permission for autopsy was refused.

DISCUSSION

The patient reported had hypertensive cardiovascular and cerebrovascular disease. The hemodynamic pattern

was that of biventricular low output failure, associated with systemic and pulmonary hypertension. Following administration of ouabain, cardiac output did not change, but aortic pressure increased steadily, indicative of progressive peripheral vasoconstriction. Heart rate decreased, but right atrial pressure did not change. The inotropic response to ouabain was indeterminate.¹

Acute left hemiparesis and aphasia could be caused by either cerebral embolization, thrombosis, or hemorrhage. In the absence of congenital heart disease, mitral valvular disease, myocardial infarction, or cardiomyopathy, intracardiac thrombosis as a source of cerebral embolization is unlikely. The size of the lesion, as well as its recurrent nature, also argue against embolization. It should be noted that complications of cardiac catheterization involving the central nervous system are relatively rare.² Among 12,367 procedures, only 24 such complications were observed. Of these, only two had arteriosclerotic heart disease. Focal cerebral dysfunction was noted in only 13 patients and, with one exception, cleared up within a few days. Thus, the clinical recurrence of left hemiparesis and aphasia was most likely related to the ouabain-induced hypertension, even though this may not have represented a new anatomic lesion.

The hypertensive effect of digitalis glycosides has been known for some time. Digitalis-induced increase in blood pressure has been observed frequently in anesthetized animals³⁻⁵ and man. However, in awake animals^{7,8} and in conscious, healthy man, this hypertensive effect of digitalis has not been observed as readily.^{9,10,13} On the other hand, the hypertensive effect of digitalis glycosides has often been noted in

Table 1—Serial Hemodynamic Data Before and After Administration of Ouabain 0.75 mg Intravenously (Body Surface Area 1.94 M²)

Time (minutes)	Before Ouabain			After Ouabain		
	-30	-10	10	20	30	57
Heart rate (beats/min)	140	148	137	119	119	125
Brachial arterial pressure (mm Hg)						
Systolic	175	180	215	230	258	255
Diastolic	120	130	140	150	156	145
Mean	140	148	173	164	178	190
Right atrial mean pressure (mm Hg)	24	25	24	29	30	23
Pulmonary arterial pressure (mm Hg)						
Systolic	85	78	90	91	96	
Diastolic	48	45	52	52	60	
Mean	56	60	67	71	75	
Left ventricular end-diastolic pressure (mm Hg)	27	26	33	34	40	32
Cardiac output (L/min)	3.35	3.60			3.84	3.43
Stroke volume (ml/beat)	23.9	24.4			32.3	27.5
Total peripheral resistance (dynes sec cm ⁻⁵)	3350	3289			5124	4431
Left ventricular work (kg/m)	6.20	7.65			10.63	9.84
Left ventricular stroke work (g-m)	44	52			89	79

clinical and experimental studies in the presence of heart disease.^{11,14}

The fact that the pressor effect is rapid and generally precedes any increase in cardiac output, as well as its magnitude suggest that blood pressure rises largely as a result of an increase in peripheral vascular resistance. This is borne out by studies during cardiopulmonary bypass at constant perfusion rates: a significant increase in arterial pressure has been observed in man⁶ as well as in the dog.⁵ In the latter, digitalis-induced vasoconstriction was not abolished by ganglion blockade with hexamethonium or by adrenalectomy, suggesting a direct action of digitalis upon arteriolar smooth muscle. Mason and Braunwald,¹⁵ by means of plethysmographic studies, confirmed such direct peripheral action of digitalis in conscious, healthy man: the ouabain-induced increase in vascular resistance of the forearm was not prevented by pretreatment with the adrenergic blocking agent guanethidine. In patients with congestive heart failure and already increased peripheral resistance, ouabain was followed by a decrease in forearm vascular resistance.

Recent studies in this laboratory^{7,8,16} have shed further light upon the mechanism of the peripheral vasoconstrictor effect of digitalis glycosides and suggest a pathway by which this effect may be modulated. In conscious, awake dogs, acetyl strophanthidin induced vasoconstriction and increased arterial blood pressure only after cholinergic blockade with atropine.^{7,16} The fact that this diminution of parasympathetic tone brings out digitalis-induced vasoconstriction suggests a modulating role for the parasympathetic nervous system. Under alpha blockade by means of phenoxybenzamine, the atropinized dog failed to increase peripheral resistance in response to acetyl strophanthidin,¹⁶ indicating that digitalis-induced vasoconstriction is mediated by alpha receptors. Blockade of beta receptors by means of propranolol reduced, but did not prevent digitalis-induced vasoconstriction,¹⁶ suggesting a limited role for beta receptors in this effect of digitalis. It seems likely, then, that in the conscious state the potential rise in blood pressure after digitalis may be prevented or modulated by an increased parasympathetic tone. Anesthesia and cardiovascular disease-states associated with low cardiac output and presumably with decreased parasympathetic tone may facilitate digitalis-induced hypertension. A major role of the parasympathetic nervous system in digitalis-induced vasoconstriction is also evident from recent studies in decerebrate cats.¹⁷ Whereas ouabain failed to increase arterial pressure in control animals, a hypertensive effect was observed after section of carotid sinus and vagus nerves. In agreement with our studies, pretreatment with phenoxybenzamine or phentolamine reduced the pressor response. However, section of the spinal cord also reduced the pressor response, suggesting that at least part of the pressor effect of ouabain is of central origin and transmitted via the sympathetic nervous system. A small residual pressor response to ouabain, observed in decapitated, spinal cord-pithed cats and not affected by alpha adrenergic blockade, was

attributed to direct action of ouabain upon vascular smooth muscle.

The present case report indicates that the hypertensive effect of ouabain may reach a magnitude which has significant clinical implications. Cerebrovascular complications must be added to acute heart failure and pulmonary edema,^{11,12} already reported as clinical complications of digitalis-induced systemic arterial hypertension.

It behooves the clinician to be aware of this effect and its possible complications, especially in regard to intravenous administration of digitalis glycosides to hypertensive patients. The prevention of digitalis-induced hypertension in the experimental animal by means of phenoxybenzamine¹⁶ suggests the possible clinical trial of alpha adrenergic blocking agents in the therapy of digitalis-induced hypertension of clinical significance.

REFERENCES

- 1 Yankopoulos NA, Kawai C, Federici EE, et al: The hemodynamic effects of ouabain upon the diseased left ventricle. *Am Heart J* 76:466-480, 1968
- 2 Swan HJC: Complications involving the nervous system. Chapter 8 *In* Cooperative Study on Cardiac Catheterization. E Braunwald, Ed, *Circulation* 37: (supplement III) 42-45, 1968
- 3 Dock W, Tainter ML: Circulatory changes after full therapeutic doses of digitalis, with critical discussion of views on cardiac output. *J Clin Invest* 8:467-484, 1930
- 4 Cotten MdeV, Stopp PE: Action of digitalis on the non-failing heart of the dog. *Am J Physiol* 192:114-120, 1958
- 5 Ross J Jr, Waldhausen JA, Braunwald E: Studies on digitalis. I. Direct effects on peripheral vascular resistance. *J Clin Invest* 39:930-936, 1960
- 6 Braunwald E, Bloodwell RD, Goldberg LI, et al: Studies on digitalis. IV. Observations in man on the effects of digitalis preparations on the contractility of the nonfailing heart and on total peripheral resistance. *J Clin Invest* 40:52-59, 1961
- 7 Kumar R, Hood WB Jr, Gilmour DP, et al: Effects of acetyl strophanthidin on cardiovascular function in intact, conscious dogs. *J Pharmacol Exp Ther* 180:24-30, 1972
- 8 Kumar R, Hood WB Jr, Joison J, et al: Experimental myocardial infarction. VI. Efficacy and toxicity of digitalis in acute and healing phase in intact conscious dogs. *J Clin Invest* 49:358-364, 1970
- 9 Selzer A, Hultgren HN, Ebnother CL, et al: Effect of digoxin in the circulation in normal man. *Br Heart J* 21:335-342, 1959
- 10 Williams MH Jr, Zohman LR, Ratner AC: Hemodynamic effects of cardiac glycosides on normal human subjects during rest and exercise. *J Appl Physiol* 13:417-421, 1958
- 11 Ahmed S, Bayliss RIS, Briscoe WA, et al: Action of ouabain (g-strophanthin) on circulation in man, and comparison with digoxin. *Clin Sci* 9:1-16, 1950
- 12 Bayliss RIS, Etheridge MJ, Hyman AL, et al: The effect of digoxin on the right ventricular pressure in hypertensive and ischaemic heart failure. *Br Heart J* 12:317-326, 1950
- 13 Kelly HG, Wong SY: Effect of intravenous digoxin on blood pressure, serum electrolytes, renal hemodynamics and excretory function in normal and hypertensive sub-

- jects, and subjects in congestive heart failure. *Canad Med Assoc J* 85:1131-1135, 1961
- 14 Cohn JN, Tristani FE, Khatri IM: Cardiac and peripheral vascular effects of digitalis in clinical cardiogenic shock. *Am Heart J* 78:318-330, 1969
 - 15 Mason DT, Braunwald E: Studies on digitalis. X. Effects of ouabain on forearm vascular resistance and venous tone in normal subjects and in patients in heart failure. *J Clin Invest* 43:532-543, 1964
 - 16 Kumar R, Hood WB Jr, Abelmann WH: Mediation of digitalis-induced peripheral vasoconstriction in dogs by alpha adrenergic mechanisms. Parasympathetic modulation in the intact conscious state. *J Clin Invest* 50:54a, 1970
 - 17 Gillis RA, Quest JA, Standaert FG: Depression by reflexes of the pressor and cardiotoxic responses to ouabain. *J Pharmacol Exper Therapeut* 170:294-302, 1969

Air Embolism Complicating Percutaneous Needle Biopsy of the Lung*

Jack L. Westcott, M.D.

Radiographically and pathologically documented air embolism occurred following percutaneous needle aspiration of the lung. While air embolism is uncommon, it is more likely to occur when the needle is inserted into a rigid portion of the lung as occurs with extensive consolidation, abscess formation, or extensive pleural disease.

Percutaneous needle biopsy and aspiration have gained wide acceptance for the diagnosis of pulmonary lesions. Minor complications such as pneumothorax and hemoptysis are common, but reported fatalities are rare. Only six cases have been found in which needle biopsy or aspiration resulted in the death of the patient.¹⁻⁵ The deaths were caused by bronchial hemorrhage (three cases), tension pneumothorax (one case), probable air embolism (one case), and unknown causes (one case).

In the past, air embolism was a well recognized complication of thoracentesis and therapeutic pneumothorax,⁶⁻¹² but there have been no prior reports of confirmed fatal air embolism following diagnostic aspiration or biopsy of the lung. The purpose of this presentation is to report a case of radiographically and pathologically documented fatal air embolism which probably occurred during percutaneous needle aspiration of the lung. The mechanisms of pulmonary embolism and possible ways to minimize its occurrence are also presented.

CASE REPORT

A 62-year-old man had had chronic lymphocytic leukemia for 11 years. He entered the University of Utah Medical Center in November of 1971 with right lower lobe pneumonia which later progressed to abscess formation. The infection initially improved but then worsened and progres-

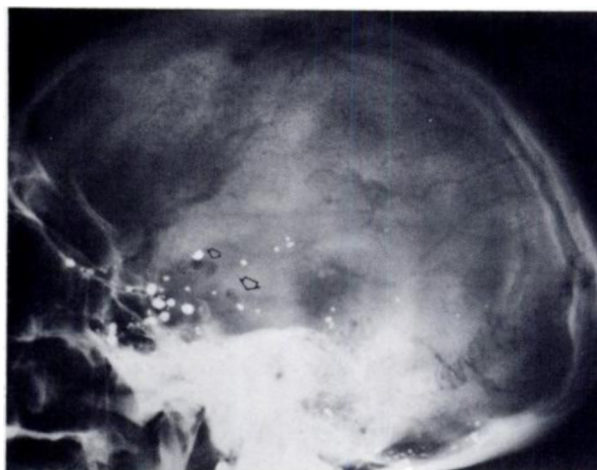


FIGURE 1. Lateral skull roentgenogram obtained immediately after death. Note air in basilar, posterior cerebral and middle cerebral arteries (arrows). Air in many smaller middle and anterior cerebral branches does not visualize on reproduction. Contrast material in subarachnoid cisterns is from previous myelography.

sively involved both lungs over the next six weeks. The sputum cultures consistently showed *Klebsiella* and *Proteus* bacteria which were "sensitive" to many antibiotics, but he did not respond to therapy. A lung needle aspiration was performed in hopes of finding another organism.

Under fluoroscopic control with the patient in the prone position, an 18 gauge 10 cm needle and stylet were inserted to an estimated depth of 3 to 4 cm into the superior segment of the left lower lobe. Upon insertion of the needle, the patient coughed. When the coughing subsided, the stylet was removed, a syringe was attached, and the needle was removed while continually aspirating. The patient coughed approximately 2 to 3 tablespoons of blood and was instructed to move his head to the side. He did not respond, and immediately urinated and defecated. His pulse was weak, and within a few seconds it was not palpable. External cardiac massage, assisted ventilation, and later defibrillation and resuscitative measures were all unsuccessful, and the patient was pronounced dead approximately 30 minutes later.

Roentgenograms of the skull were obtained immediately and showed air in the basilar artery and in numerous large and small branches of the middle cerebral arteries (Fig 1).

Postmortem examination revealed approximately 350 ml of bloody fluid in the left pleural cavity. There was extensive bilateral bronchopneumonia, and there was an old abscess cavity in the right lower lobe. There was a small puncture wound in the superior segment of the left lower lobe which was approximately 3 cm deep, and there appeared to be a communication between the puncture wound, a small peripheral bronchus, and a peripheral pulmonary vessel. There was some blood in the bronchi adjacent to the puncture. A frothy mixture of air and blood was present in the cardiac chambers, and numerous air bubbles were seen in the coronary arteries (Fig 2).

Histologic examination revealed lymphocytic infiltration of the lungs, liver, spleen, kidneys, lymph nodes, adrenals, and bone marrow. Bronchopneumonia was present in the lungs, but cultures revealed only rare *Enterobacter* and *Enterococci*.

DISCUSSION

In a discussion of air embolism, it is important to

*From the Department of Radiology, University of Utah Medical Center, Salt Lake City.
Reprint requests: Dr. Westcott, Hartford Hospital, Hartford, Connecticut 06115